FOURTH EDITION

AN ATLAS OF GYNECOLOGIC ONCOLOGY

Investigation and Surgery

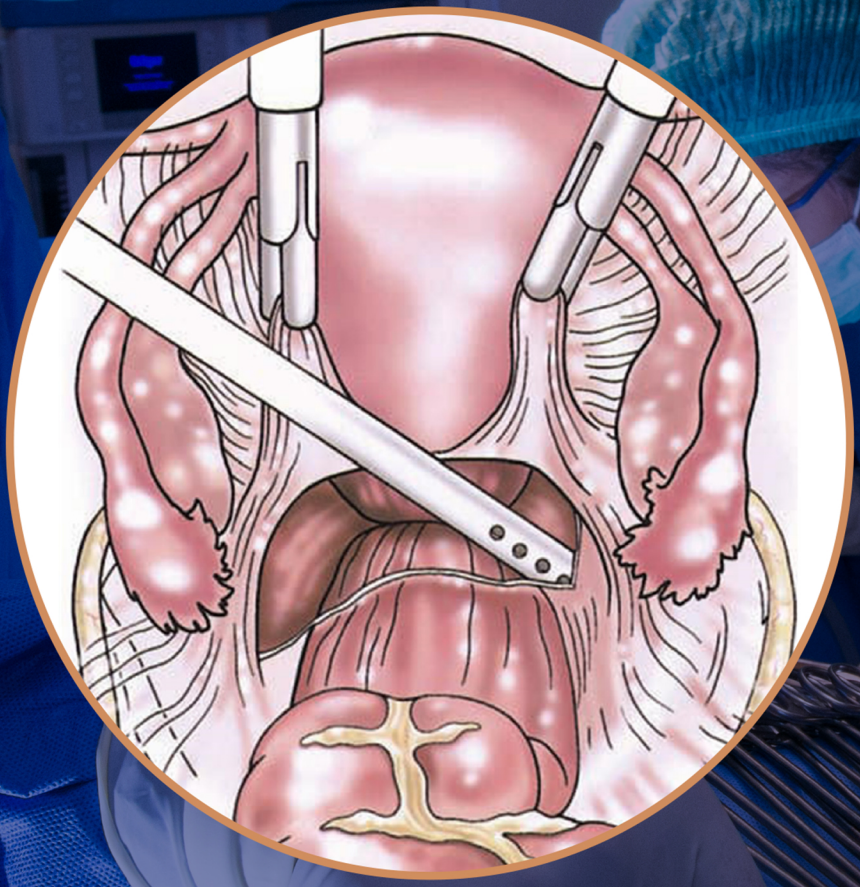

Edited by

J. RICHARD SMITH • GIUSEPPE DEL PRIORE

ROBERT L. COLEMAN • JOHN M. MONAGHAN

CRC Press

Taylor & Francis Group

FOURTH EDITION

AN ATLAS OF GYNECOLOGIC ONCOLOGY

To my four children, Cameron, Victoria, Madeleine and Lara, thank you for being there for Dad.

JRS

To my family—from the smallest latest joyous addition, to the oldest and wisest, some departed, and in the center of them all, my wife, Men-Jean Lee.

GDP

To my extraordinary wife, Fay, for her unwavering support and understanding, mentorship, love and friendship and to our six blessing children, of whom I could not be prouder. And, to my Parents, who through their years of sacrifice and guidance enabled me to pursue my dreams.

RLC

FOURTH EDITION

AN ATLAS OF GYNECOLOGIC ONCOLOGY

Investigation and Surgery

Edited by

J. Richard Smith, MBChB, MD, FRCOG
Consultant Gynaecological Surgeon and Honorary Senior Lecturer in Gynaecology, West London Gynaecological Cancer Centre, Queen Charlotte's and Chelsea Hospitals, Imperial College NHS Trust London, UK, and Adjunct Associate Professor, NYU Medical Centre, New York City, New York, USA

Giuseppe Del Priore, MD, MPH
Professor, Morehouse School of Medicine, Department of Obstetrics and Gynecology, Division of Gynecological Oncology, Grady Memorial Hospital, Atlanta, Georgia, USA

Robert L. Coleman, MD
Professor and Executive Director, Cancer Network Research, Ann Rife Cox Chair for Gynecology, Department of Gynecologic Oncology and Reproductive Medicine, University of Texas, MD Anderson Cancer Center Houston, Texas, USA

John M. Monaghan, MB ChB, FRCS (Ed), FRCOG
Retired Consultant Gynaecological Oncologist and Senior Lecturer in Gynaecological Oncology University of Newcastle upon Tyne, Newcastle upon Tyne, UK



CRC Press
Taylor & Francis Group
Boca Raton London New York

CRC Press is an imprint of the
Taylor & Francis Group, an **informa** business

CRC Press
Taylor & Francis Group
6000 Broken Sound Parkway NW, Suite 300
Boca Raton, FL 33487-2742

© 2018 by Taylor & Francis Group, LLC
CRC Press is an imprint of Taylor & Francis Group, an Informa business

No claim to original U.S. Government works

Printed on acid-free paper

International Standard Book Number-13: 978-1-4987-2906-2 (Hardback)

This book contains information obtained from authentic and highly regarded sources. While all reasonable efforts have been made to publish reliable data and information, neither the author[s] nor the publisher can accept any legal responsibility or liability for any errors or omissions that may be made. The publishers wish to make clear that any views or opinions expressed in this book by individual editors, authors or contributors are personal to them and do not necessarily reflect the views/opinions of the publishers. The information or guidance contained in this book is intended for use by medical, scientific or health-care professionals and is provided strictly as a supplement to the medical or other professional's own judgement, their knowledge of the patient's medical history, relevant manufacturer's instructions and the appropriate best practice guidelines. Because of the rapid advances in medical science, any information or advice on dosages, procedures or diagnoses should be independently verified. The reader is strongly urged to consult the relevant national drug formulary and the drug companies' and device or material manufacturers' printed instructions, and their websites, before administering or utilizing any of the drugs, devices or materials mentioned in this book. This book does not indicate whether a particular treatment is appropriate or suitable for a particular individual. Ultimately it is the sole responsibility of the medical professional to make his or her own professional judgements, so as to advise and treat patients appropriately. The authors and publishers have also attempted to trace the copyright holders of all material reproduced in this publication and apologize to copyright holders if permission to publish in this form has not been obtained. If any copyright material has not been acknowledged please write and let us know so we may rectify in any future reprint.

Except as permitted under U.S. Copyright Law, no part of this book may be reprinted, reproduced, transmitted, or utilized in any form by any electronic, mechanical, or other means, now known or hereafter invented, including photocopying, microfilming, and recording, or in any information storage or retrieval system, without written permission from the publishers.

For permission to photocopy or use material electronically from this work, please access www.copyright.com (http://www.copyright.com/) or contact the Copyright Clearance Center, Inc. (CCC), 222 Rosewood Drive, Danvers, MA 01923, 978-750-8400. CCC is a not-for-profit organization that provides licenses and registration for a variety of users. For organizations that have been granted a photocopy license by the CCC, a separate system of payment has been arranged.

Trademark Notice: Product or corporate names may be trademarks or registered trademarks, and are used only for identification and explanation without intent to infringe.

Library of Congress Cataloging-in-Publication Data

Names: Smith, J. Richard, editor. | Del Priore, Giuseppe, editor. | Coleman, Robert L., editor. | Monaghan, John M., editor.
Title: An atlas of gynecologic oncology: investigation and surgery/edited by J. Richard Smith, Giuseppe Del Priore, Robert L. Coleman and John M. Monaghan.
Description: Fourth edition. | Boca Raton, FL: CRC Press/Taylor & Francis Group, [2018] | Includes bibliographical references and index.
Identifiers: LCCN 2017046627| ISBN 9781498729062 (hardback: alk. paper) | ISBN 9781351141680 (ebook: alk. paper)
Subjects: | MESH: Genital Neoplasms, Female—surgery | Atlases
Classification: LCC RC280.G5 | NLM WP 17 | DDC 616.99/46—dc23
LC record available at https://lccn.loc.gov/2017046627

Visit the Taylor & Francis Web site at
http://www.taylorandfrancis.com

and the CRC Press Web site at
http://www.crcpress.com

Contents

Contributors *vii*
Preface *xi*
Acknowledgments *xii*
In Memoriam: Andrew D. Lawson *xiii*

1 Introduction: Preparing a patient for surgery *1*
Srdjan Saso, Benjamin P. Jones, J. Richard Smith, and Giuseppe Del Priore

2 Preoperative workup *8*
Jessica Thomes-Pepin and Chris Stephenson

3 Complications *20*
David Warshal and James Aikins

4 Anatomy *25*
Ernest F. Talarico, Jr., Jalid Sehouli, Giuseppe Del Priore, and Werner Lichtenegger

5 Cross-sectional and molecular imaging *34*
Syed Babar Ajaz, Ruth Williamson, and Tara Barwick

6 Sigmoidoscopy, cystoscopy, and stenting *55*
Louis J. Vitone, Peter A. Davis, and David J. Corless

7 Tumor markers *60*
James Dilley and Usha Menon

8 Cone biopsy *69*
Giuseppe Del Priore

9 Radical abdominal hysterectomy *72*
J. Richard Smith, Deborah C.M. Boyle, and Giuseppe Del Priore

10 Laparoscopically assisted vaginal radical hysterectomy *79*
Daniel Dargent and Michel Roy

11 Radical vaginal trachelectomy *88*
Marie Plante and Michel Roy

12 Radical abdominal trachelectomy *95*
Laszlo Ungar, Laszlo Palfalvi, Srdjan Saso, Benjamin P. Jones, Giuseppe Del Priore, and J. Richard Smith

13 Central recurrent cervical cancer: The role of exenterative surgery *102*
John M. Monaghan

14 Total mesometrial resection *109*
Michael Höckel

15 Laterally extended endopelvic resection *117*
Michael Höckel

16 Vaginectomy *123*
John M. Monaghan

17 Radical vulvar surgery *127*
John M. Monaghan

18 Sentinel lymph node biopsy *132*
Michael Frumovitz, Robert L. Coleman, and Charles M. Levenback

19 Ovarian tissue cryopreservation and transplantation *148*
Giuliano Bedoschi and Kutluk Oktay

20 Uterine transplantation and lessons from transplant surgery *153*
Giuseppe Del Priore, Benjamin P. Jones, Srdjan Saso, and J. Richard Smith

21 Epithelial ovarian cancer *156*
Jane Bridges and David Oram

22 Upper abdominal cytoreduction for advanced ovarian cancers *163*
Scott M. Eisenkop, Christina L. Kushnir, and Nick M. Spirtos

23 Extraperitoneal approach to infrarenal, inframesenteric, and pelvic lymphadenectomies *169*
Katherine A. O'Hanlan

24 Vascular access and implantable vascular and peritoneal access devices *175*
Paniti Sukumvanich and Gary L. Goldberg

25 Surgical management of trophoblastic disease *184*
Srdjan Saso, Krishen Sieunarine, Benjamin P. Jones, Joseph Yazbek, Michael J. Seckl, and J. Richard Smith

26 Laparoscopy *189*
Farr Nezhat, Carmel Cohen, and Nimesh P. Nagarsheth

27 Humidification during surgery: Benefits of using humidified gas during laparoscopic and open surgery *208*
Maria Mercedes Binda

28 Robotic surgery *214*
Rabbie K. Hanna and John F. Boggess

29 Gastrointestinal surgery in gynecologic oncology *220*
Eileen M. Segreti, Stephanie Munns, and Charles M. Levenback

30 Urologic procedures *230*
Padraic O'Malley and Peter N. Schlegel

31 Fistula repair *239*
Paul Hilton

32 Treatment of vascular defects and injuries *255*
Karl A. Illig, Kenneth Ouriel, and Sean Hislop

33 Plastic reconstructive procedures *260*
Andrea L. Pusic, Richard R. Barakat, and Peter G. Cordeiro

34 Additional plastic surgery procedures *266*
Albert H. Chao, Georgia A. McCann, and Jeffrey M. Fowler

35 Fat transfer: Applications in gynecology *273*
Deborah C.M. Boyle and Simon H. Wood

36 Surgical management of postpartum hemorrhage *275*
Men-Jean Lee, Renata A. Sawyer, and Charles J. Lockwood

37 Brachytherapy *282*
Matthew Harkenrider, Fiori Alite, and William Small, Jr.

38 Innovative methods to teach and train minimally invasive surgery *293*
Helai Hesham, Thomas Lendvay, Ritu Salani, and Martin A. Martino

39 Meta-analysis of survival data *301*
Srdjan Saso, Jayanta Chatterjee, Ektoras Georgiou, Sadaf Ghaem-Maghami, Thanos Athanasiou, and Angeles Alvarez-Secord

40 Pain management *317*
Andrew Lawson and Paul Farquhar-Smith

41 Palliative care *322*
Sarah Cox and Catherine Gillespie

42 Doctor–patient communication *328*
J. Richard Smith, Krishen Sieunarine, Mark Bower, Gary Bradley, and Giuseppe Del Priore

Index *334*

Contributors

James Aikins
Division of Gynecologic Oncology
Cooper University Hospital, Voorhees
and
Robert Wood Johnson Medical School at Camden
Camden, New Jersey

Syed Babar Ajaz
Imaging Department
Hammersmith Hospital
Imperial Healthcare NHS Trust
London, United Kingdom

Fiori Alite
Chief Resident, Department of Radiation Oncology
Stritch School of Medicine
Loyola University Chicago
Cardinal Bernardin Cancer Center
Maywood, Illinois

Angeles Alvarez-Secord
Professor, Department of Obstetrics and Gynecology
Division of Gynecologic Oncology
Duke Cancer Institute
Duke University Medical Center
Durham, North Carolina

Thanos Athanasiou
Reader and Consultant Cardiothoracic Surgeon
Department of Biosurgery and Surgical Technology
Imperial College London
Imperial College Healthcare NHS Trust at St Mary's Hospital Campus
London, United Kingdom

Richard R. Barakat
Gynecology Service
Department of Surgery
Memorial Sloan-Kettering Cancer Center
New York City, New York

Tara Barwick
Imaging Department
Hammersmith Hospital
Imperial Healthcare NHS Trust
London, United Kingdom

Giuliano Bedoschi
Innovation Institute for Fertility and IVF
New York City, New York
and
Laboratory of Molecular Reproduction and Fertility Preservation, Obstetrics and Gynecology
New York Medical College
Valhalla, New York

Maria Mercedes Binda
Université Catholique de Louvain
Institut de Recherche Expérimentale et Clinique (IREC)
Pôle de Gynécologie
Bruxelles, Belgium

John F. Boggess
Rex Cancer Center
Raleigh, North Carolina

Deborah C.M. Boyle
Department of Obstetrics and Gynaecology
Royal Free Hampstead NHS Foundation Trust Hospital
London, United Kingdom

Mark Bower
Consultant Medical Oncologist
Chelsea & Westminster Hospital
London, United Kingdom

Gary Bradley
Vicar of Little Venice
London, United Kingdom

Jane Bridges
Unit of Gynaecologic Oncology
Royal Marsden Hospital
London, United Kingdom

Albert H. Chao
Associate Professor of Surgery and Microsurgery Fellowship Program Director
Department of Surgery
Ohio State University
Columbus, Ohio

Jayanta Chatterjee
Clinical Research Fellow, Division of Surgery, Oncology, Reproductive Biology and Anaesthetics
Institute of Reproductive & Developmental Biology
Imperial College London
Hammersmith Hospital Campus
London, United Kingdom

Carmel Cohen
Professor Emeritus, Department of Obstetrics, Gynecology, and Reproductive Science
Icahn School of Medicine at Mount Sinai
New York City, New York

Robert L. Coleman
Professor & Executive Director, Cancer Network Research
Ann Rife Cox Chair for Gynecology
Department of Gynecologic Oncology & Reproductive Medicine
University of Texas, MD Anderson Cancer Center
Houston, Texas

Peter G. Cordeiro
Plastic and Reconstructive Surgery Service
Memorial Sloan-Kettering Cancer Center
New York City, New York

David J. Corless
Consultant Surgeon
Mid Cheshire NHS Foundation Trust
Cheshire, United Kingdom

Sarah Cox
Consultant in Palliative Medicine
Chelsea and Westminster Hospital Foundation Trust
London, United Kingdom

Daniel Dargent†
Gynécologie Obstétrique
Hôpital Edouard Herriot
Lyon, France

Peter A. Davis
Department of Surgery
The James Cook University Hospital
South Tees Hospitals NHS Trust
Middlesbrough, United Kingdom

Giuseppe Del Priore
Professor, Morehouse School of Medicine
Department of Obstetrics and Gynecology
Division of Gynecological Oncology
Grady Memorial Hospital
Atlanta, Georgia

James Dilley
Department of Gynaecological Oncology
EGA Institute for Women's Health
University College London
London, United Kingdom

Scott M. Eisenkop
Women's Cancer Center of Nevada
Research Department
Las Vegas, Nevada

Paul Farquhar-Smith
Consultant in Pain Medicine and Anaesthesia
The Royal Marsden NHS Foundation Trust
London, United Kingdom

Jeffrey M. Fowler
Division of Gynecologic Oncology
The Ohio State University Medical Center
Columbus, Ohio

Michael Frumovitz
Professor and Fellowship Director
Department of Gynecologic Oncology & Reproductive Medicine
University of Texas, MD Anderson Cancer Center
Houston, Texas

Ektoras Georgiou
Clinical Research Fellow, Department of Biosurgery & Surgical Technology
Imperial College London
St Mary's Hospital Campus
London, United Kingdom

Sadaf Ghaem-Maghami
Senior Lecturer and Honorary Consultant in Gynaecological Oncology
Imperial College London Hammersmith House
Hammersmith Hospital Campus
London, United Kingdom

Catherine Gillespie
Assistant Executive Director of Nursing
National Centre for Cancer Care and Research
Hamad Medical Corporation
Doha, Qatar

Gary L. Goldberg
Department of Obstetrics and Gynecology and Women's Health
Albert Einstein College of Medicine and Montefiore Medical Center
Bronx, New York

Rabbie K. Hanna
Division of Gynecologic Oncology
Department of Women's Health Services
Henry Ford Hospital
Detroit, Michigan

Matthew Harkenrider
Assistant Professor, Department of Radiation Oncology
Stritch School of Medicine
Loyola University Chicago
Cardinal Bernardin Cancer Center
Maywood, Illinois

Helai Hesham
Clinical and Research Fellow, Department of Female Pelvic Medicine and Reconstructive Surgery
Massachusetts General Hospital
Boston, Massachusetts

Paul Hilton
Honorary Senior Lecturer
Urogynaecology Newcastle University
and
Retired Consultant Gynaecologist and Urogynaecologist
Latterly of Newcastle upon Tyne Hospitals NHS Foundation Trust
Newcastle upon Tyne, United Kingdom

Sean Hislop
Coastal Vascular and Vein Center
Charleston, South Carolina

Michael Höckel
Department of Obstetrics and Gynaecology
University of Leipzig
Leipzig, Germany

Karl A. Illig
Professor of Surgery, Division of Vascular Surgery
USF Morsani College of Medicine
Tampa, Florida

Benjamin P. Jones
Clinical Research Fellow
Division of Surgery and Cancer
Institute of Reproductive & Developmental Biology
Imperial College London
Hammersmith Hospital Campus
London, United Kingdom

Christina L. Kushnir
Women's Cancer Center of Nevada
Las Vegas, Nevada

Andrew Lawson
Formerly Consultant in Anaesthesia and Pain Management
Royal Berkshire Hospital
Reading, United Kingdom

† Deceased.

Men-Jean Lee
Kosasa Endowed Professor
Director, Maternal-Fetal Medicine
John A. Burns School of Medicine
University of Hawai'i
Honolulu, Hawaii

Thomas Lendvay
Professor, Department of Urology
University of Washington
and
Co-Director, Seattle Children's Hospital Robotic Surgery Center
Seattle, Washington

Charles M. Levenback
Dean, Morsani College of Medicine
and
Senior Vice President, USF Health
University of South Florida
Tampa, Florida

Werner Lichtenegger
Professor, Department of Gynecology
Center of Oncological Surgery (CVK)
Department of Gynaecology (CBF)
Charité – Universitätsmedizin Berlin
Berlin, Germany

Charles J. Lockwood
Dean, Morsani College of Medicine
University of South Florida
and
Senior Vice President, USF Health
University of South Florida
Tampa, Florida

Martin A. Martino
Professor, Department of OBGYN
Division of Gynecologic Oncology
University of South Florida College of Medicine
Tampa, Florida
and
Medical Director, Minimally Invasive Robotic Surgery
Lehigh Valley Cancer Institute: Lehigh Valley Health Network
Allentown, Pennsylvania

Georgia A. McCann
Department of Obstetrics and Gynecology
University of Texas Health Science Center
San Antonio, Texas

Usha Menon
Department of Gynaecological Oncology
EGA Institute for Women's Health
University College London
London, United Kingdom

John M. Monaghan
Retired Consultant, Gynaecological Oncologist
and
Senior Lecturer in Gynaecological Oncology
University of Newcastle upon Tyne
Newcastle upon Tyne, United Kingdom

Stephanie Munns
Obstetrician-Gynecologist
West Penn Hospital
Pittsburgh, Pennsylvania

Nimesh P. Nagarsheth
Associate Professor, Department of Obstetrics, Gynecology, and Reproductive Science
Icahn School of Medicine at Mount Sinai
New York City, New York
and
Englewood Hospital and Medical Center
Englewood, New Jersey

Farr Nezhat
Nezhat Surgery for Gynecology/Oncology
and
Weill Cornell Medical College of Cornell University
New York City, New York
and
School of Medicine at Stony Brook University
Stony Brook, New York
and
Minimally Invasive Gynecologic Surgery and Robotics
NYU Winthrop Hospital
Mineola, New York

Katherine A. O'Hanlan
Laparoscopic Institute for Gynecology and Oncology
Portola Valley, California

Kutluk Oktay
Professor, Obstetrics & Gynecology and Reproductive Sciences
and
Director, Laboratory of Molecular Reproduction and Fertility Preservation
Yale University School of Medicine
New Haven, Connecticut

Padraic O'Malley
Assistant Professor, Department of Urology
Dalhousie University
Nova Scotia, Canada

David Oram
Department of Gynaecology
Barts and the London NHS Trust
The Royal London Hospital, Whitechapel
London, United Kingdom

Kenneth Ouriel
President, Syntactx LLC
New York City, New York

Laszlo Palfalvi
Department of Obstetrics and Gynecology
St Stephen Hospital
Budapest, Hungary

Jessica Thomes-Pepin
Department of Obstetrics and Gynecology
Indiana University
Indianapolis, Indiana

Marie Plante
Professor, Gynecologic Oncology Division
L'Hôtel-Dieu de Québec
Laval University
Quebec City, Canada

Andrea L. Pusic
Chief of Plastic and Reconstructive Surgery at Brigham Health
Brigham and Women's Faulkner Hospital
Boston, Massachusetts

Michel Roy
Professor, Gynecologic Oncology Division
L'Hôtel-Dieu de Québec
Laval University
Quebec City, Canada

Ritu Salani
Associate Professor, Division of Gynecologic Oncology
Department of Obstetrics & Gynecology
The Ohio State University Comprehensive Cancer Center
Arthur G. James Cancer Hospital and Richard J. Solove Research Institute
Columbus, Ohio

Srdjan Saso
Honorary Clinical Lecturer & Subspecialty Trainee in Gynaecologic Oncology
Institute of Reproductive and Developmental Biology
Imperial College London
London, United Kingdom

Renata A. Sawyer
Adjunct Assistant Professor, Indiana University School of Medicine
Beacon Medical Group Maternal-Fetal Medicine
South Bend, Indiana

Peter N. Schlegel
Senior Associate Dean for Clinical Affairs and Chairman of Urology
Weill Cornell Medicine
New York City, New York

Michael J. Seckl
Professor of Molecular Cancer Medicine
Charing Cross Gestational Trophoblastic Disease Centre
Department of Medical Oncology
Imperial College Healthcare NHS Trust
Charing Cross Hospital
London, United Kingdom

Eileen M. Segreti
Associate Clinical Professor, Temple University
Philadelphia, Pennsylvania
and
Vice-Chair of Academics, Alleghany Health Network
Division of Gynecology Oncology
Pittsburgh, Pennsylvania

Jalid Sehouli
Medical Director, Department of Gynecology
Center of Oncological Surgery (CVK)
Department of Gynaecology (CBF)
Charité – Universitätsmedizin Berlin
Berlin, Germany

Krishen Sieunarine
Consultant Gynaecologist
Kettering General Hospital
Kettering, United Kingdom

William Small, Jr.
Professor and Chairman, Department of Radiation Oncology
Stritch School of Medicine
Loyola University Chicago
Chicago, Illinois
and
Cardinal Bernardin Cancer Center
Chair, Gynecologic Cancer InterGroup (GCIG)
Maywood, Illinois

J. Richard Smith
Consultant Gynaecological Surgeon and Honorary Senior Lecturer in Gynaecology
West London Gynaecological Cancer Centre
Queen Charlotte's and Chelsea Hospitals
Imperial College NHS Trust
London, United Kingdom
and
Adjunct Associate Professor
NYU Medical Center
New York City, New York

Nick M. Spirtos
Women's Cancer Center of Nevada
Research Department
Las Vegas, Nevada

Chris Stephenson
Cancer Treatment Centers of America
Boca Raton, Florida

Paniti Sukumvanich
Associate Professor, Gynecologic Oncology Fellowship Director
Division of Gynecologic Oncology
Department of Obstetrics, Gynecology, and Reproductive Science
Magee-Womens Hospital of the University of Pittsburgh Medical Center
Pittsburgh, Pennsylvania

Ernest F. Talarico, Jr.
Associate Professor of Anatomy & Cell Biology
Adjunct Faculty Radiologic Sciences
Indiana University School of Medicine Northwest Gary
Gary, Indiana

Laszlo Ungar
Department of Obstetrics and Gynecology
St Stephen Hospital
Budapest, Hungary

Louis J. Vitone
Consultant Surgeon
Mid Cheshire NHS Foundation Trust
Cheshire, United Kingdom

David Warshal
M.D. Anderson Cooper Cancer Center
Camden, New Jersey

Ruth Williamson
Imaging Department
Hammersmith Hospital
Imperial Healthcare NHS Trust
London, United Kingdom

Simon H. Wood
Plastic and Reconstructive Surgery Department
Imperial College Healthcare NHS Trust
Charing Cross Hospital
London, United Kingdom

Joseph Yazbek
Consultant Gynaecological Surgeon
Imperial College London Hammersmith House
Hammersmith Hospital Campus
London, United Kingdom

Preface

Welcome to the fourth edition of this Atlas. When we looked back to the first edition, instituted 20 years ago now, that text was approximately half the size of this current volume. Much of what is now included would have appeared to be science fiction 20 years ago, but it has become reality. Inevitably, the book gets larger with each expanding edition as the gynecologic oncologist's repertoire of operations gets progressively larger. There are virtually no operations which fail to remain in the skill set, only ever more to know about and ever more equipment and energy sources available. A number of the procedures described are nowadays often performed as laparoscopic or robotically assisted procedures; however, we are also aware that not all surgeons have access to the same equipment, and this is an international book designed for an international audience.

The "cookbook" formula of the previous editions remains; nobody is advising which operation to do, but you do get a "road map" to whichever operation you have decided upon. Many years ago, before satellite navigation systems in cars, if you were going on a long drive you would consult your road atlas the previous night; this book, it is hoped, fulfils a similar role, as well as opening our minds to new things, some of which we may develop, others not.

New chapters have been added and all the text updated by a combination of the chapter authors and the editors. As in previous editions, innovative surgeons have been keen to contribute. The wonderfully clear artwork of Dee McLean and Joanna Cameron continues to enhance this book, allowing easy step-by-step breakdowns of procedures.

Once again it has been a great pleasure and privilege to be the editors and to read so many clear expositions written by experts for experts. We hope you enjoy reading this book as much as we have enjoyed editing it.

J. Richard Smith
Giuseppe Del Priore
Robert L. Coleman
John M. Monaghan

Acknowledgments

J. Richard Smith would like to thank Miss Rodena Kelman and Miss Alison Irvine Smith for their secretarial support and Dr. Charles Lockwood and Professor Philip J. Steer for the academic environment which encouraged the editors in the early days. He would also like to express his gratitude to his research fellow, Mr. Benjamin Jones, for editorial assistance and also to Dr. David Keefe, of NYU Medical Center, for his ongoing support and collaboration. In addition, he thanks all his colleagues at the West London Gynaecological Cancer Centre, particularly Mr. Alan Farthing, Ms. Sadaf Ghaem-Maghami, Ms. Christina Fotopoulou, Ms. Maria Kyrgiou, Mr. Joseph Yazbek, and Professor Hani Gabra, for the supportive environment they engender for this project and many others.

Giuseppe Del Priore wishes to thank his family for indulging his trainees for constant inspiration to learn and teach more. He thanks his colleagues for their continued guidance and constructive feedback.

Robert L. Coleman would like to thank his wife, Fay, and his expanding family for their inspiration, sacrifice, and support to make this all possible; his colleagues and trainees who confidently and consistently ask "why?" and "what if?" as they care for our patients; his trusted friends and brilliant collaborators, Professors Anil Sood, Tom Herzog, and Bradley Monk, who continually challenge him to think bigger and reach deeper; and Ms. Kathleen Collins, Ms. Elizabeth DelBosque, Ms. Ljiljana Milojevic, Ms. Marlana Klinger, and the dedicated team of research nurses, data coordinators, and regulatory staff, whom he's been privileged to work alongside, for their tireless attention to their research program, which strives to better understand the disease process and move the needle on treatment efficacy and safety.

John M. Monaghan would like to thank his fellow editors for keeping him on side and for allowing him to use the experience of time to occasionally add a comment or two. He would particularly like to thank Maggie, his wife of over 50 years, for her continuing patience and encouragement. It has been a privilege to be involved in this book for over 20 years and to see how fully the field of gynecological oncology has progressed to be the major surgical care system for women. When the editors began, laparoscopic surgery was an occasionally used tool; it is now the major route of access for even the most massive of procedures. The resulting shortening of inpatient care and rapid discharge of patients has had many benefits but occasional problems. Careful scientific analysis of systems of care and techniques of management are now standard in gynecological oncology, yet the subject remains innovative and not confined by the stifling atmosphere of safety and nil risk. He sees a strong future of innovation and development for the subject and is happy to have contributed to this important text.

In Memoriam: Andrew D. Lawson

In 2014 Andrew Lawson, pain specialist, anesthetist, and ethicist, succumbed to a pleural mesothelioma after a 7-year battle with his disease. The editors wish to acknowledge his great contribution to the field of chronic pain management and to record his efforts for the first three editions of this book, the latter while very much under the cloud of his diagnosis. He was known personally to many involved with this book and is much missed.



Taylor & Francis
Taylor & Francis Group
http://taylorandfrancis.com

1 Introduction: Preparing a patient for surgery

Srdjan Saso, Benjamin P. Jones, J. Richard Smith, and Giuseppe Del Priore

INTRODUCTION

This chapter reviews three specific areas relevant to virtually all surgical procedures and surgeons: infection prophylaxis; deep venous thrombosis (DVT) prophylaxis; and universal precautions. Universal precautions facilitate the protection of surgeons and their assistants, medical and nursing, and patients. Preoperative and postoperative checklists now form a vital part of risk reduction. James Reason, PhD, formulated the "Swiss cheese theory" of risk. This is based on a piece of Swiss cheese with holes in it. The more slices one puts in the cheese, the less likely it is that an arrow could fly through the holes, and thus the holes are less likely to tally with each other. Therefore the more layers of checking that one puts in pre- and postoperatively, the less likely it is that the antibiotic prophylaxis will be forgotten or the postoperative DVT prophylaxis will not be given. A simple checklist is shown in Figure 1.1. The purpose of any such checklist is to systematically and efficiently ensure that all operative conditions are optimal with respect to patient safety. The hope is that by completing such a checklist, the lives and well-being of surgical and thus gynecological patients will be minimized as errors in patient identity, site, and type of procedure are avoided completely.

More well known is the surgical checklist published by the World Health Organization (WHO) in 2008 in order to increase the safety of patients undergoing surgery. It is officially known as the *WHO Surgical Safety Checklist and Implementation Manual.* It is now used in general surgery, orthopedics, and obstetrics and gynecology. The operation is divided into three distinct phases by the checklist. Each phase corresponds to one of the following periods: (a) before the induction of anesthesia, (b) before the skin incision (known as "time out"), and (c) before the patient leaves the operating facility (known as "sign out"). A "checklist coordinator" must confirm that the surgical team has completed a phase before moving on to the next. Only when all three phases have been completed can the procedure commence.

Phase I: Before Induction of Anesthesia. The following must be confirmed first: patient identity, site of operation, procedure to be carried out, and consent. Type of anesthetic required, allergies (if any), and expected blood loss should be discussed. Phase I is to be completed by the anesthetist.

Phase II: Time Out. This refers to a process before the first incision where all present in the room must introduce themselves by name and role. The patient name and the planned procedure are then confirmed as well as any surgical or anesthetic critical events that may occur. The need for antibiotics, DVT prophylaxis, and imaging is highlighted. Phase II is to be completed by the surgeon and anesthetist.

Phase III: Sign Out. The final phase is performed before the patient leaves the operating room. Swabs, instruments, and needle counts are done, the equipment is checked (including disposables), and the specimens are checked as properly labeled. The postoperative recovery process is discussed. Phase III is to be completed by the surgeon or nursing staff.

Figure 1.1 shows the checklist on admission for surgery.

THROMBOEMBOLIC DISEASE

Venous thromboembolic disease (VTE) is a significant cause of morbidity and mortality in gynecologic oncology patients. If sensitive methods of detection are employed and no preventive measures are taken, at least 20% and as many as 70% of gynecologic cancer patients may have some evidence of thrombosis. In certain situations, such as with a long-term indwelling venous catheter of the upper extremity, nearly all patients will have some degree of VTE, though it may not be clinically significant. On the other hand, lower extremity VTE has a much more certain and clinically significant natural history. Venous thromboses below the knee may spread to the upper leg in approximately 10% to 30% of cases or resolve spontaneously in approximately 30%. Once the disease has reached the proximal leg, the risk of pulmonary embolism (PE) increases from less than 5% for isolated below-the-knee VTE to up to 50% for proximal VTE. The mortality rate for an undiagnosed PE is high. Up to two-thirds of patients who die from PE do so in the first 30 minutes after diagnosis.

Early recognition and effective treatment can reduce this mortality. However, postoperative VTE is still a leading cause of death in gynecologic oncology patients. In the past, it was clear that only one-third of hospitalized high-risk patients received appropriate prophylaxis; this figure has now much improved, particularly with the use of checklists. Risk factors are listed in Table 1.1 (NICE 2015).

PREVENTION AND RISK ASSESSMENT

Patients may be considered for prevention of VTE based on their clinical risk category. Laboratory tests such as euglobulin lysis time do correlate with the risk of VTE but are no more helpful than clinical risk assessment in selecting patients for prophylaxis. Low-risk patients are young (less than 40 years old), undergoing short operative procedures (less than 1 hour), and do not have coexisting morbid conditions such as malignancy or obesity that would elevate the risk of VTE. Moderate-risk patients include those undergoing longer procedures, older or obese patients, and patients having pelvic surgery. High-risk patients include otherwise moderate-risk patients who have cancer and those with a previous history of VTE. Positioning for vaginal surgery lowers the risk of VTE when compared with the abdominal approach.

All patients should be assessed for risk of bleeding before being offered pharmacological VTE prophylaxis. This should not be offered to patients with any of the risk factors for

CHECKLIST FOR SURGERY ON ADMISSION
Date:

NAME: DATE OF BIRTH:

OPERATION PLANNED:

RISKS	
Infection	
Anesthetic	
Hemorrhage	
Deep Venous Thrombosis	
Uterine Perforation	
Other Organ Damage	
Others	

PAST GYNECOLOGICAL HISTORY	
Last Menstrual Period	
Contraception	
x/y	
Pregnancy Test	

PERTINENT MEDICAL/ANESTHETIC PROBLEMS

Signed _____

POST-OPERATIVE CHECKLIST	
Low molecular weight heparin or other measures prescribed	
Antibiotics prescribed	
Photographs taken and collected	

Signed _____

1

Figure 1.1 Checklist for surgery on admission.

Table 1.1 Risk Factors for VTE (NICE 2015)

- Active cancer or cancer treatment
- Age over 60 years
- Critical care admission
- Dehydration
- Known thrombophilias
- Obesity (body mass index [BMI] over 30 kg/m^2)
- One or more significant medical comorbidities (for example, heart disease; metabolic, endocrine, or respiratory pathologies; acute infectious diseases; inflammatory conditions)
- Personal history or first-degree relative with a history of VTE
- Use of hormone replacement therapy
- Use of estrogen-containing contraceptive therapy
- Varicose veins with phlebitis

bleeding shown in Table 1.2, unless the risk of VTE outweighs the risk of bleeding. Patients should be advised to consider stopping estrogen-containing oral contraceptives or hormone replacement therapy 4 weeks before elective surgery. If stopped, advice must be provided on alternative contraceptive methods (NICE 2015). All patients should have some form of VTE prevention. This first begins with risk reduction. Patients should not become dehydrated unless clinically indicated. They must mobilize as soon as possible. Aspirin or other antiplatelet agents should not be considered as adequate prophylaxis for VTE. Finally, temporary inferior vena caval filters should be offered to patients who are at very high risk of VTE (such as patients with a previous VTE event or an active malignancy) and for whom mechanical and pharmacological VTE prophylaxis are contraindicated (NICE 2015).

VTE prophylaxis can be in the form of mechanical or pharmacological prophylaxis. The ultimate decision is based on individual patient factors including clinical condition, surgical procedure, and patient preference. Mechanical prophylaxis can be anti-embolism stockings (thigh or knee length), foot impulse devices, or intermittent pneumatic compression devices (thigh or knee length). Pharmacological prophylaxis is based on local policies and individual patient factors, including clinical condition (such as severe renal impairment or established renal failure) and patient preferences (NICE 2015).

Table 1.2 Risk of Bleeding (NICE 2015)

- Active bleeding
- Acquired bleeding disorders (such as acute liver failure)
- Concurrent use of anticoagulants known to increase the risk of bleeding (such as warfarin with international normalized ratio [INR] higher than 2)
- Lumbar puncture/epidural/spinal anesthesia expected within the next 12 hours
- Lumbar puncture/epidural/spinal anesthesia within the previous 4 hours
- Acute stroke
- Thrombocytopenia (platelets less than 75×10^9/L)
- Uncontrolled systolic hypertension (230/120 mmHg or higher)
- Untreated inherited bleeding disorders (such as hemophilia and von Willebrand disease)

Low-risk patients, with an incidence of approximately 3% for VTE, may be adequately protected with early ambulation, elevation of the foot of the bed, and graduated compression stockings. "Early ambulation" has been defined by some investigators as walking around the nursing station at least three times within the first 24 hours. Graduated compression stockings are readily available; however, ensuring their proper application and size can be difficult. Obese patients may suffer from a "tourniquet" effect if the stocking rolls off the thigh; this may actually increase the risk of VTE, not prevent it.

Moderate-risk patients include the majority of general gynecology patients and have approximately 10% to 40% chance of developing VTE. These patients should receive the same measures as low-risk patients with the addition of low-dose unfractionated low molecular weight heparin (LMWH), 5000 units subcutaneously twice a day. An alternative to the administration of heparin is the application of pneumatic compression devices to the lower extremities. High-risk category patients require even more measures owing to the estimated 40% to 70% risk of VTE.

The vast majority of gynecologic oncology cases will fall into the high-risk category. Standard unfractionated heparin (UH) is ineffective in these cases in low doses; for example, 5000 units twice daily. If given three times daily, UH is effective but no better than pneumatic calf compression. Unfortunately, more frequent dosing is associated with significantly more wound hematoma formation and blood transfusions. It also requires additional nursing and pharmacy personnel time, and is more uncomfortable for the patient. These may be some of the reasons only a minority of surgeons regularly use UH prophylaxis. Unfortunately, although compression devices are effective in gynecologic oncology patients, the devices are somewhat cumbersome, and are disliked by patients and nursing staff. In fact, improper application of the devices occurs in approximately 50% of patients on routine inpatient nursing stations. Compression devices are also contraindicated in patients with significant peripheral vascular disease.

The LMWHs have many potential advantages over the previously cited alternatives. Excellent bioavailability allows for single daily dosing, which in turn reduces nursing effort while improving patient satisfaction. This form of prophylaxis is also associated with less thrombocytopenia and postoperative bleeding. Patients with UH-associated thrombocytopenia will usually tolerate LMWH. In summary, in high-risk patients such as gynecological patients, LMWH may be more efficacious, more cost-effective, and less toxic than the alternatives.

Many other agents have been tried in an attempt to overcome the imperfections of existing options. All have limitations and are not used routinely. However, all are effective to some degree and may be appropriate in highly selected patients. Some of these agents include aspirin, warfarin, and high molecular weight dextran. The most promising are direct thrombin inhibitors and oral factor Xa inhibitors such as Rivaroxaban. In comparison with LMWH, aspirin results in more bleeding complications and is less effective than heparin in preventing VTE. Warfarin has a prophylactic effect similar to aspirin, but again is less effective than heparin and is associated with a higher risk of complications and requires more intensive monitoring. Dextrans are effective but have been associated with rare cases of allergic reactions. Other complications reported include fluid overload and nephrotoxicity. Further research to avoid some of these limitations may improve the therapeutic value of these alternatives.

PREVENTION AND TREATMENT

The duration of prophylaxis has traditionally been limited to the duration of hospital stay. In many older studies, when health care was less cost-conscious, this may have been several days to weeks. Lengths of stay are now much shorter, and as a result so is the duration of VTE-preventive measures. Even before this forced change in clinical practice, it was recognized that a significant minority of VTE either developed or was diagnosed long after discharge from the hospital. The optimal duration of prophylaxis is still not known and depends on the method used. For instance, patients should be instructed to walk every day once discharged from the hospital. Similarly, graduated compression stockings may be worn after surgery until discharge with little risk and possibly some benefit. Some authors also advocate compression stockings to be worn at home following discharge. Conversely, pharmacologic therapies have side effects, may require some training (e.g., self or nurse injections), and are associated with considerable cost. General guidance used to be to use prophylaxis until the patient is fully mobile. However, following the demonstration that administering LMWH for 4 weeks, when compared to a single-week course, reduces VTE risk by 60% in postoperative cancer patients, generally a 4-week course is now prescribed (Bergqvist et al. 2002).

The agents discussed above are all designed to prevent VTE and thereby reduce the risk of developing a clinically significant PE. When these methods are used properly, most patients will not develop VTE and therefore will be at low risk for a PE. However, it is not uncommon for a gynecologic oncology patient to present with VTE as the first manifestation of disease. For instance, it is the presenting symptom in up to 10% of ovarian cancer patients. In these patients, and in those who develop VTE despite appropriate prophylaxis, something must be done to prevent the progression to a potentially fatal PE. This becomes especially difficult if the patient requires surgical treatment for the malignancy.

One common management technique for these difficult situations is mechanical obstruction of the inferior vena cava. This can be accomplished preoperatively via peripheral venous access and interventional radiologic techniques. Care must be taken to delineate the extent of the clot so that no attempt is made to pass the filtering device through an occluded vein. If peripheral caval interruption is not possible, a vena caval clip may be applied intraoperatively. However, large pelvic masses, not uncommon in gynecologic cancer patients, may prevent access. Additional problems with vena caval interruption include migration of the device, complete occlusion of the cava, perforation, and infection. In preoperative cases where the patient cannot have a filter or clip placed, one option is the discontinuation of intravenous UH 1 hour before the perioperative period, with resumption approximately 6 hours after completion of the surgery. Most patients will do well with this technique, but they are still vulnerable to intraoperative PEs. Another pharmacologic option may include the preoperative lysis of the thrombus with thrombolytic agents such as urokinase followed by resumption of standard prophylactic measures. Oral anticoagulation is used after caval interruption, if not contraindicated, to prevent postthrombotic venous stasis of the lower extremity. Therefore, mechanical devices, while reducing perioperative pulmonary emboli, do not obviate the need for long-term anticoagulation. It is vitally important if one is operating on patients who have traveled on long-haul flights that major surgery should be avoided within 48 hours of this flight. NICE guidance on venous thromboembolism in patients undergoing surgery (NICE 2012) states "immobility associated with continuous travel of more than three hours in the four weeks before or after surgery may increase the risk of VTE." For those patients traveling by airplane postoperatively, the relatively new oral preparations of Dabigatran and rivaroxaban, licensed for the prevention of VTE after hip and knee replacement surgery, may be prescribed (Gomez-Outes et al. 2009).

DIAGNOSIS

Given the imperfection of prophylaxis and the high risk of VTE in gynecologic oncology patients, all physicians caring for these women should be familiar with the treatment and diagnosis of VTE including PE. Fewer than one-third of patients with VTE of the lower extremity will present with the classic symptoms of unilateral edema, pain, and venous distension. A positive Homan sign (calf pain with dorsiflexion of the foot) is also unreliable and is seen in less than half of patients with VTE. Calf VTE occurs bilaterally in approximately 40% of cases and is more common on the left (40%) than on the right (20%). Only a high index of suspicion and objective testing can correctly identify patients with VTE.

In high-risk patients with a high baseline prevalence of VTE, sensitive but non-specific tests are useful owing to their high positive predictive value. To exclude disease in these same high-risk patients, repeat testing on subsequent days or more sensitive techniques are needed. Noninvasive diagnostic testing should always be considered before interventional techniques including venography and arteriography. Lower extremity Doppler and real-time two-dimensional ultrasonography scans are fairly sensitive (85%) and specific (>95%) for VTE. If results are positive in high-risk patients, including those with symptoms suggestive of PE, no further testing is indicated and therapy may be initiated. In the past, ventilation–perfusion scans and more recently spiral CT thoracic scanning may be used similarly in patients in whom PE is suspected. If the scan indicates an intermediate or high probability of PE, treatment is usually advisable. In patients at higher risk for hemorrhagic complications, such as during the immediate postoperative period where there is residual tumor, confirmatory tests may be indicated before therapy.

TREATMENT

If there is no contraindication to anticoagulation, therapy should be started as soon as the diagnosis of VTE is made. Outcomes are correlated with the time it takes to achieve therapeutic anticoagulation, so the fastest means available should be employed. LMWH has an advantage over UH in that a single daily dose of approximately 175 units/kg subcutaneously will be therapeutic almost immediately. Unfractionated heparin may require approximately 24 hours and repeated blood testing before becoming therapeutic. Treatment with warfarin can be started once the anticoagulation effect of either heparin is confirmed. With UH, this may be as early as day 1, although 2 to 3 days of therapy may be needed before anticoagulation is achieved. With LMWH, warfarin can be started within a few hours, and definitely on the same day. Either heparin should be continued until the warfarin has achieved an international normalized ratio of 2 to 3. Anticoagulation with warfarin should continue for at least 3 months. Patients with recurrent VTE or persistent precipitating events, e.g., vessel compression by tumor, may need indefinite anticoagulation.

Disseminated cancer and chemotherapy will unavoidably increase the risk of complications from anticoagulation. Cancer patients who have nutritional deficits, organ damage, and unknown metastatic sites are particularly vulnerable. Chemotherapeutic agents alter the metabolism of anticoagulants through their effect on liver and renal function, making dosing more difficult. Chemotherapeutic drugs may also share similar toxicities with anticoagulants and thereby worsen hemorrhagic complications from thrombocytopenia and anemia. For these reasons, treatment of VTE may be neither desired by the patient nor recommended by her physician in all situations.

INFECTION PROPHYLAXIS

Most gynecology units now routinely use antibiotic prophylaxis prior to both minor and major surgery. In the absence of such prophylaxis, abdominal hysterectomy is complicated by infection in up to 14% of patients, and following vaginal hysterectomy, infection rates of up to 38% have been reported (Sweet and Gibbs 1990). This results in much morbidity, increased length of hospital stay, increased prescribing of antibiotics, and a large financial burden. By its very nature, oncological surgery carries greater risks of infection than routine gynecological surgery, owing to the length of the procedures and increased blood loss (Table 1.3).

It is difficult to compare many of the studies on prophylaxis, as diagnosis and antibiotic regimens are not standardized. However, there seems to be general agreement that approximately 50% of infections are prevented in this way and that the potential dangers of increased microbial resistance do not justify withholding prophylaxis. Prophylaxis is thought to work by

Table 1.3 Risk Factors for Postoperative Infection

1	Hospital stay for more than 72 hours before surgery
2	Prior exposure to antimicrobial agents in the immediate preoperative period
3	Morbid obesity
4	Chronic illness, e.g., hypertension, diabetes
5	History of repeated infection
6	Prolonged operative procedure (>3 hr)
7	Blood loss in excess of 1500 mL

reducing, but not eradicating, vaginal flora. The antibiotic used, its dose, and the duration of therapy do not appear to influence results. It is therefore suggested that short courses of antibiotics should be used, involving a maximum of three doses. First-generation cephalosporins, broad-spectrum penicillins, and/or metronidazole are all reasonable choices on grounds of efficacy and cost. Antibiotic prophylaxis should not detract from good surgical technique, with an emphasis on strict asepsis, limitation of trauma, and good hemostasis.

INFECTION CONTROL

There is increasing awareness of the risks of transmission of blood-borne pathogens from surgeon to patient and vice-versa during surgical practice. These risks have been highlighted by the publicity surrounding human immunodeficiency virus (HIV), but are generally greater from other pathogens including hepatitis B virus (HBV). Infection with hepatitis C virus (HCV) also poses a risk of transmission from patient to surgeon. The prevalence of these viral infections varies widely with different populations, and this exerts an influence on the surgeon's risk, as does the number of needlestick (or sharps) injuries sustained and the surgeon's immune status. The risks of transmission of these viruses and their subsequent pathogenicity are discussed below. The necessity for universal precautions in surgical practice need not affect overmuch operator acceptability or cost.

Antenatal anonymous surveys have shown a seroprevalence of HIV in metropolitan areas of the United Kingdom to be as high as 0.26% (Evans et al. 2009). HIV prevalence has increased in the United Kingdom over the last decade, with an estimated 110,000 individuals living with HIV by 2013.

The risk of acquiring HIV from a single-needlestick injury from an infected patient is in the region of 0.10% to 0.36% (Cardo et al. 1997a,b). Pooled data from several prospective studies of healthcare personnel suggest that the average risk of HIV transmission is approximately 0.3% (95% confidence interval, 0.2–0.5) after a percutaneous exposure to HIV-infected blood and approximately 0.09% (95% confidence interval, 0.006–0.5) after a mucous-membrane exposure (Gerberding 2003). However, using mathematical models to predict lifetime risks of acquiring the infection in a population with a low HIV seroprevalence (0.35%), it has been suggested that 0.26% of surgeons would seroconvert during their working lives (Howard 1990). Needlestick injuries pose a significant occupational risk for surgical trainees. A study by Makary et al. (2007) in *The New England Journal of Medicine* found that virtually all surgical residents (99%) had had a needlestick injury by their final year of training, and concluded that needlestick injuries are common among surgeons in training and are often not reported. Improved prevention and reporting strategies are needed to increase occupational safety for surgical providers (Makary et al. 2007).

In December 2001, 57 healthcare workers in the United States had seroconverted to HIV as a result of occupational exposure. Of the adults reported with acquired immune deficiency syndrome (AIDS) in the United States through December 31, 2002, 24,844 had a history of employment in healthcare. These cases represented 5.1% of the 486,826 AIDS cases reported to the Centers for Disease Control and Prevention (CDC) for whom occupational information was known (www.cdc.gov). This website is a valuable resource, particularly with respect to new and ever-changing drug regimens currently in use in the management of blood-borne pathogens. Intact skin and mucous membranes are thought to be effective barriers against HIV. Only a very few cases of transmission via skin contamination are known to have occurred, and these healthcare workers had severe dermatitis and did not observe barrier precautions when exposed to HIV-infected blood (CDC 1987). Aerosol transmission of HIV is not known to occur, and the principal risks are related to injuries sustained from hollow-bore needles, suture needles, and lacerations from other sharp instruments. Infectivity is determined by the volume of the inoculum and the viral load within it: thus, a hollow-bore needlestick injury carries greater risk than injury from a suture needle. Prior to highly active antiretroviral therapy, infection with HIV results in AIDS in 50% of patients over a 12-year period and had a long-term mortality approaching 100%. The situation is now radically different. For HIV seropositive surgeons, further operative practice involving insertion of the fingers into the body cavity is precluded owing to the potential risk of doctor-to-patient transmission: for gynecologic surgeons, this encompasses virtually their entire surgical practice, with the exception of laparoscopic and hysteroscopic procedures.

There is a whole classification related to exposure-prone procedures (EPP) which is categorized into nonexposure-prone (category 0) and exposure (1–3). Category 3 encompasses all open procedures. This classification is available from the UK Department of Health website related to UKAP (United Kingdom Advisory Panel for Health Care Workers infected with blood-borne pathogens). At present there is no vaccine available to prevent infection with HIV. Should needlestick injury occur, the injured area should be squeezed in an attempt to expel any inoculum, and the hands should be thoroughly washed. There is good evidence that after exposure prophylactic zidovudine (azidothymidine [AZT]) reduces transmission by 79%. Most occupational health departments now advise their healthcare workers to commence treatment within 1 hour of injury with multiple therapy which depending on the risk of HIV exposure should either be a two-drug regimen for 4 weeks, or for those at higher risk a three-drug regimen. These used to commonly include zidovudine (AZT), as it is the only drug which has proven to reduce HIV risk following occupational exposure. However, as AZT is often poorly tolerated, newer medications such as tenofovir and emtricitabine are being increasingly utilized instead, mostly in combination with a protease inhibitor.

This type of regimen may well reduce the risks of seroconversion further. In some countries, surgeons with a persistently undetectable viral load (less than 50 copies) may be allowed to return to performing EPPs under occupational health supervision.

Intraoperative transmission of HBV occurs more readily than with HIV, and exposure of skin or mucous membrane to blood from a hepatitis B e antigen (HBeAg) carrier involves a highly significant risk of transmission for those who are not immune (West 1984). The risk of seroconversion following an accidental inoculation with blood from an HBeAg carrier, in the absence of immunity, is up to 30% for susceptible healthcare workers without post-exposure prophylaxis (PEP) or sufficient hepatitis B vaccination (Wicker et al. 2008). Hepatitis B surface antigen (HBsAg) is found in 0.5% to 1% of patients in inner cities and in 0.1% of patients in rural areas and blood donors. Given a needlestick rate of 5% per operation, the risk of acquiring the virus in a surgical lifetime is potentially high. Prior to the introduction of HBV vaccination an estimated 40% of American surgeons became infected at some point in their careers, with 4% becoming carriers. Acute infection with HBV is associated with the development of fulminant hepatitis in approximately 1% of individuals. Carriers may go on to develop chronic liver damage, cirrhosis, or hepatocellular carcinoma, carrying an overall mortality of approximately 40%.

Transmission of HBV from infected healthcare workers to patients is rare but well documented. Welch et al. (1989) reported a case of an infected gynecologist who transmitted HBV to 20 of his patients; the operations carrying greatest risk of infection were hysterectomy (10/42) and caesarean section (10/51). In view of this risk, government guidelines in most countries stipulate that surgeons should be immune to HBV, either through natural immunity or vaccination, the exceptions being staff who fail to respond to the vaccine (5%–10%) and those who are found to be HBsAg positive in the absence of "e" antigenemia (United Kingdom Advisory Group on Hepatitis 2003). In the United Kingdom, the United States, and other countries this is a statutory obligation. Those who fail to respond to vaccination should receive hepatitis B immunoglobulin following needlestick injury where the patient is HBV positive.

HCV, the commonest cause of non-A non-B hepatitis in the developed world, is also known to be spread by blood contamination. Routine screening for antibodies among blood donors in the United Kingdom has shown that 0.05% were seropositive in 2001; many of these were seemingly healthy asymptomatic carriers. However, as many as 85% of injecting drug users may be seropositive. In the United Kingdom, infection with HCV is second only to alcohol as a cause of cirrhosis, chronic liver disease, and hepatocellular carcinoma, although the clinical course in seemingly healthy individuals is unclear.

A recent anonymous seroprevalence study of staff at an inner London teaching hospital reported that infection with HCV was no higher than that previously seen in blood donors. The seroprevalence was no different for workers involved with direct clinical exposure (medical and nursing staff) compared with those at risk of indirect clinical exposure (laboratory and ancillary staff) (Zuckerman et al. 1994). However, these findings should not lead to complacency. From epidemiological data, it would appear that HCV infection is less contagious than HBV, but more so than HIV. The risk of a HCV infection is estimated at between 3 and 10%; it increased tenfold if the source patient has high levels of virus load (Wicker et al. 2008). It would, however, appear that transmission is very rare with solid-bore needles, i.e., almost exclusively follows inoculation with hollow bore needles. Transmission has rarely followed mucous membrane exposure and never via non-intact or intact skin. The possibility of HCV infection should be considered in the event of needlestick injury. Immunization and PEP are not available for those exposed to HCV. Recently, in the United Kingdom the same restrictions have been introduced to healthcare workers infected with HIV and hepatitis C i.e., preclusion from performing exposure-prone procedures. This is not the case in any other country.

PREVENTION OF BLOOD-BORNE INFECTION

Some surgeons have advocated preoperative screening of patients for HIV infection. They argue that patients shown to be infected should be treated as high-risk, while the remaining patients would be labeled as low-risk, with the consequent development of a two-tier infection control policy. However, such an approach is fraught with political, ethical, logistical, and financial implications, and furthermore, wrongly assumes that infected patients can always be identified by serological testing. The universal precautions suggested below are practicable, and effectively minimize the intraoperative infection risk of both surgeon and patient. These precautions are based on the procedure rather than the perceived risk status of the patient. As discussed above, the greatest risk of contracting a blood-borne pathogen is from needlestick injury. Vaginal hysterectomy has been shown to have the highest rate (10%) of needlestick injury of any surgical procedure (Tokars et al. 1991). Glove puncture has been used as a measure of skin contamination and a reflection of needlestick injury; the highest rate of glove puncture reported in any surgical procedure was 55% at caesarean section. Double gloving has shown a sixfold diminution in inner glove puncture rate, and anecdotally appears to result in a reduction in needlestick injury, but it is uncomfortable, particularly during protracted procedures, making it unsuitable for many gynecologic

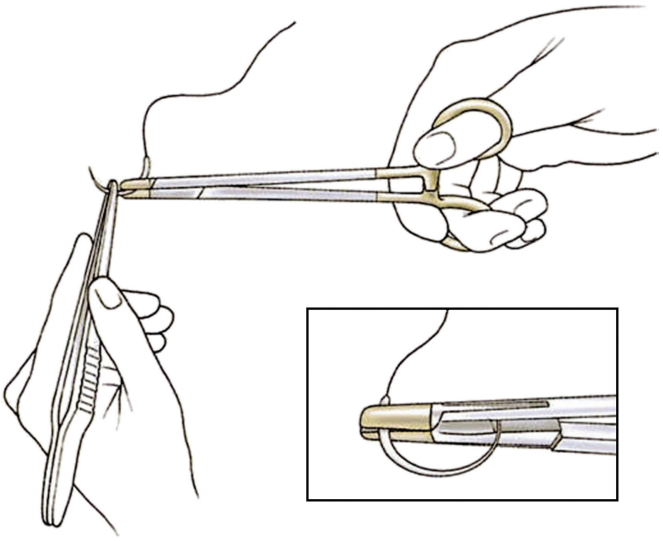

Figure 1.2 Safety needle holder.

Table 1.4 Risk Factors for Transmission of Blood-Borne Pathogens during Surgical Practice

1	Prolonged surgical procedure
2	Heavy blood loss
3	Operating within a confined space, e.g., pelvis or vagina
4	Poor lighting
5	Guiding the needle by feel

Table 1.5 Simple Precautions Available to Reduce Needlestick Injury

1	Blunt-tipped needles: available from Davis & Geck (Protec Point) and Ethicon (Ethiguard needle)
2	Staple guns for skin closure: available from Autosuture and Ethicon Endosurgery
3	Staples for bowel anastomosis: available from Autosuture and Ethicon Endosurgery
4	Spectacles/protective eyewear: blood-borne pathogens have, however, only been shown to be transmitted very rarely and usually only in the presence of gross ocular contamination
5	Magnet for picking up sharps
6	Hands-free disposable sharp boxes for needles and blades
7	Blunt towel clips
8	Self-adhesive drapes

oncological operations. Blunt-tipped needles, such as the Protec Point (Davis & Geck, Gosport, United Kingdom) and Ethiguard (Ethicon, Edinburgh, United Kingdom), appear to reduce the rate of glove puncture, and one of the authors (JRS) has never sustained a needlestick injury in 8 years of continuously using these needles. The newer needles are capable of penetrating the majority of tissues including uterine muscle, vaginal vault, cervix, peritoneum, and rectus sheath. They are unsuitable for bowel and bladder surgery and do not penetrate skin, but they have been used subcutaneously for abdominal wound closure. Abdominal skin closure can also be safely undertaken with the use of staples. This is particularly important since it has been shown that 5% of glove punctures occurred during this stage of the procedure. Just under half of punctures occur in the right hand—a surprising finding considering that most surgeons are right-handed and therefore grasp the needle holder with the dominant hand. Injury appears to occur during knot tying, and a safety needle holder with provision for guarding the needle tip at this stage and when returning the needle to the scrub nurse is now available (Thomas et al. 1995) (Figure 1.2). The use of a kidney dish for passing scalpels between staff should also be encouraged, as should safe needle and blade disposal in hands-free surgical sharps boxes. Blades or needles that have fallen on the floor should be retrieved with a magnet prior to disposal. Blunt towel clips are also available to prevent injury while draping. Reusable self-adhesive drapes are available, as are disposable self-adhesive drapes with a surrounding bag to prevent gross contamination.

Skin and mucous membrane contamination should be avoided by the use of masks and waterproof gowns. Glasses or other protective eyewear should be worn to prevent contamination by facial splashes of blood and other body fluids.

The risks and safety measures discussed above are summarized in Tables 1.4 and 1.5. Table 1.4 demonstrates that oncological surgery carries the greatest risk. However, the simple and relatively cheap procedures and precautions suggested in Table 1.5 can reduce the risk for both surgeon and patient to extremely low levels.

REFERENCES

Advisory Group on Hepatitis. 1993. *Protecting Health Care Workers and Patients from Hepatitis B*. London: HMSO.

Bergqvist D, Agnelli G, Cohen AT, et al. 2002. Duration of prophylaxis against venous thromboembolism with enoxaparin after surgery for cancer. *N Engl J Med* **346**(13):975-80.

Cardo DM, Culver DH, Ciesielski CA, et al. 1997a. A case-control study of HIV seroconversion in health care workers after percutaneous exposure. *N Engl J Med* **337**:1542–3.

Cardo DM, Culver DH, Ciesielski CA, et al. 1997b. A case control study of HIV seroconversion in health care workers after percutaneous exposure. *N Engl J Med* **337**:1485–90.

Centers for Disease Control (CDC). 1987. Update: Human immunodeficiency virus infection in health care workers exposed to blood of infected patients. *MMWR* **36**:285–9.

Evans HE, Mercer CH, Rait G, et al. 2009. Trends in HIV testing and recording of HIV status in the UK primary care setting: A retrospective cohort study 1995–2005. *Sex Transm Infect* **85**:520–6.

Gerberding JL. 2003. Occupational exposure to HIV in health care settings. *N Engl J Med* **348**:826–33.

Gomez-Outes A, Lecumberri R, Pozo C, Rocha E. 2009. New anticoagulants: Focus on venous thromboembolism. *Curr Vasc Pharmacol* **7**:309–29.

Howard RJ. 1990. Human immunodeficiency virus testing and the risk to the surgeon of acquiring HIV. *Surg Gynaecol Obstet* **171**:22–6.

Makary MA, Al-Attar A, Holzmueller CG, et al. 2007. Needlestick injuries among surgeons in training. *N Engl J Med* **356**:2693–9.

NICE. 2015. Guidance on venous thromboembolism in patients undergoing surgery.

Reason J. 1990. *Human Error*. Cambridge: University Press, Cambridge.

Sweet RL, Gibbs RS. 1990. *Infectious Diseases of the Female Genital Tract*. 2nd ed. Baltimore: Williams & Wilkins.

Thomas PB, Falder S, Jolly M, et al. 1995. The role of blunt-tipped needles and a new needle-holder in reducing needlestick injury. *J Obstet Gynaecol* **15**:336–8.

Tokars J, Bell D, Marcus R, et al. 1991. Percutaneous injuries during surgical procedures (Abstract). VII International Conference on AIDS, Florence, Italy.

Wicker S, Cinatl J, Berger A, et al. 2008. Determination of risk of infection with blood-borne pathogens following a needlestick injury in hospital workers. *Ann Occup Hyg* **52**:615–22.

Welch J, Webster M, Tilzey AJ, et al. 1989. Hepatitis B infections after gynaecological surgery. *Lancet* 1989; **1**:205–7.

West DJ. 1984. The risk of hepatitis B infection among health professionals in the United States: A review. *Am J Med Sci* **287**:26–33.

WHO. *Surgical Safety Checklist and Implementation Manual*. Who.int. 2010-12-08.

Zuckerman J, Clewley G, Griffiths P, Cockroft A. 1994. Prevalence of hepatitis C antibodies in clinical health-care workers. *Lancet* **343**:1618–20.

2 Preoperative workup

Jessica Thomes-Pepin and Chris Stephenson

INTRODUCTION

Surgical planning for the patient with a gynecologic malignancy begins with a detailed assessment of perioperative risk determined by pre-existing medical comorbidities. Reducing perioperative-associated complications and improving outcomes remains a prudent goal in procedural preparation.

Additional considerations in surgical planning include discussions with the patient regarding postoperative expectations, the need for blood products, the need for subsequent additional therapy including surgical procedures or chemotherapy, the possibility for ostomy or placement of other tubes and/or catheters, potential changes in sexual function, and the effect of the procedure on quality of life.

The more informed a patient can be regarding expectations surrounding surgical management, the more likely they are to make sound judgment regarding therapy and to be satisfied with their overall care. The following recommendations help assess surgical "fitness" by organ system. Highlights are indicated in a box, as above.

ASSESSMENT OF PERIOPERATIVE CARDIAC RISK

The most treatable cause of morbidity and mortality associated with noncardiac surgery remains perioperative cardiovascular complications. Nearly one-third of all patients undergoing major elective surgery have at least one major cardiac risk factor, with the greatest risk of perioperative death stemming from associated cardiac stress (Mangano 1990).

Acute myocardial infarction (MI) comprises 50% of all perioperative cardiovascular complications, which most commonly occur within the first three days after surgery (Ashton et al. 1993).

A postoperative MI carries a 28-fold increase in risk of cardiovascular complications within the first 6 months following surgery; including a 40% to 70% increased risk of death (Shah et al. 1990). The 2014 ACC/AHA perioperative cardiac risk guidelines determine preoperative risk according to patient and procedural factors applied within an evidence-based algorithm (Fleisher et al. 2008). Preoperative cardiac assessment allows the determination of fitness for surgery, minimizes major adverse cardiac events (MACE) in the postoperative period, and identifies those at risk for long-term adverse outcomes.

2014 ACC/AHA PERIOPERATIVE CARDIAC RISK GUIDELINES

Step 1: Determine the Urgent or Emergent Nature of the Procedure

Emergent (<6 hours) or urgent (6–24 hours) procedures allow for limited to no clinical evaluation. The risk of cardiovascular complications in these procedures is increased two- to fivefold in comparison to elective procedures (Goldman et al. 1977). This prompts the operative team to employ more aggressive perioperative surveillance and management. A procedure performed on an elective basis allows further evaluation and assessment, and possibly treatment of active cardiac conditions, lowering the overall risk of MACE. The majority of oncologic procedures fall into the time-sensitive category (<1–6 weeks), allowing for evaluation and further assessment without significant time for intervention.

Step 2: Determine the Presence of Active Cardiac Disease or Active Clinical Risk Factors of Cardiac Disease

There remains a persistent underestimation of cardiac disease in women evaluated preoperatively. In patients with established cardiovascular disease, preoperative assessment must include eliciting any recent change in symptoms including shortness of breath, palpitations, fatigue, or chest pain. Unstable angina, MI, significant arrhythmias, cardiomyopathy, or severe cardiac valvular disease all increase the risk of MACE. MACE after noncardiac surgery is often associated with prior coronary artery disease (CAD), and the timing of a recent MI impacts perioperative morbidity and mortality (Fleisher et al. 2008).

In a retrospective chart analysis, the incidence of postoperative MI decreased as the length of time from MI to procedure increased (0–30 days, 32.8%; 31–60 days, 18.7%; 61–90 days, 8.4%; 91–180 days, 5.9%) (Livhits et al. 2011).

A recent MI occurring within 6 months of noncardiac surgery has been found to be an independent risk factor for perioperative stroke and associated with an eightfold increase in perioperative mortality (Mashour et al. 2011). Obviously, most cancer patients cannot wait 6 months for surgery, however a delay to beyond 30 days may be acceptable in certain circumstances. Age, smoking, hyperlipidemia, and diabetes mellitus are important historical factors that portend further investigation.

Patients with clinical heart failure (HF) or history of HF are at significant risk for perioperative complications (Detsky et al. 1986). Risk-adjusted 30-day mortality and readmission rates in patients undergoing major noncardiac surgery was 50% to 100% higher in patients with HF than in elderly controls without a history of CAD or HF (Hammill et al. 2008).

Decompensated HF confers the highest perioperative risk, while severely decreased (<30%) left ventricular ejection fraction (LVEF) independently contributes to perioperative morbidity and mortality (Healy et al. 2010).

It is recommended that patients with clinically suspected moderate or greater degrees of valvular stenosis or regurgitation undergo preoperative echocardiography if not performed within the last year or if there has been a change in clinical status or the physical examination since the last evaluation (Douglas et al. 2011).

Preoperative recommendations regarding non-ischemic cardiomyopathies must be made in conjunction with the patient's cardiologist or a gynecological oncologist with a thorough understanding of the pathophysiology of the cardiomyopathy who can integrate assessment and management of the underlying process and associated HF (Fleisher et al. 2015). For those patients requiring intervention, perioperative risk may be lowered if performed prior to elective noncardiac surgery (Nishimura et al. 2014). There are a paucity of data regarding cardiac arrhythmias and conduction disorders regarding true contribution to perioperative risk; however, their presence within the preoperative setting warrants further investigation. Patients with an implantable electronic device (IED) should be managed in conjunction with the clinician following the patient regarding the device and underlying cardiac disease. If feasible, a patient with pulmonary hypertension should undergo evaluation by a specialist prior to proceeding with surgery, and continue all chronic pulmonary vascular targeted therapy unless contraindicated (Fleisher et al. 2015).

Step 3: Calculation of Risk to Determine Perioperative Morbidity

In the 2007 ACC/AHA guidelines, the committee separated clinical risk factors into major, intermediate, and minor categories (Eagle et al. 2002) (Table 2.1). The presence of one or more active cardiac conditions with major clinical risk warrants further investigation prior to proceeding with surgery. In conjunction with estimation of procedural risk, the specific combined incidence of cardiac death and nonfatal MI helps determine whether further preoperative cardiac testing is indicated (Tables 2.2A and 2.2B). The 2014 ACC/AHA clinical practice guidelines (CPG) recommend use of a validated risk-prediction tool to predict the risk of perioperative MACE in patients undergoing noncardiac surgery. Different calculators include the Revised Cardiac Risk Index (RCRI), the American College of Surgeons National Surgical Quality Improvement Program (NSQIP), Myocardial Infarction and Cardiac Arrest (MICA), and the American College of Surgeons NSQIP Surgical Risk Calculator (Cohen et al. 2013, Gupta et al. 2011, Lee et al. 1999) For patients with a low risk of perioperative MACE, further testing is not recommended prior to proceeding with the planned procedure.(Schein et al. 2000)

Step 4: Determine the Patient's Functional Capacity, or their Ability to Perform Common Daily Tasks

Functional capacity is measured in METS (metabolic equivalents), and correlates with oxygen demands in stress testing (Hlatky et al. 1989) (Table 2.3).

Functional status is a reliable predictor of perioperative and long-term cardiac events (Fleisher et al. 2015). A high functional status usually requires no further testing.

Table 2.1 The Presence of One or More Active Cardiac Conditions with Major Clinical Risk Warrants Further Investigation Prior to Proceeding with Surgery

Major cardiac risk factors	Unstable coronary artery syndromes
	Unstable or severe angina
	Recent myocardial ischemia
	Uncertain timing of historic MI-Q waves on EKG
	Acute MI: acute event 7 days or prior
	Recent MI: >7 days or ≤1 month prior
	Decompensated heart failure
	Significant arrhythmias
	Severe valvular disease
Intermediate cardiac risk factors	History of heart failure
	History of compensated heart disease or prior heart failure
	History of cerebrovascular disease
	Diabetes mellitus
	Renal insufficiency
Minor cardiac risk factors	Abnormal EKG: LBBB, LVH, ST abnormality
	Rhythm other than sinus
	Uncontrolled systemic hypertension

Abbreviations: MI, myocardial infarction; EKG, electrocardiogram; LBBB, left bundle branch block; LVH, left ventricular hypertrophy.
Sources: Adapted from Freeman WK, Gibbons RJ, *Mayo Clin Proc* **84**(1):79–90, 2009; Flleisher et al. (2007), Eagle KA, Berger PB, Calkins H, et al., *Anesth Analg* **94**:1052–64, 2002.

In patients without a recent exercise test, functional status can be estimated from the ability to perform activities of daily living (Reilly et al. 1999). Functional capacity is classified as excellent (10), good (7−10), moderate (4–6), poor (4 or less), or unknown. Perioperative cardiac and long-term risks are increased in patients unable to perform 4 METs of work during daily activities (Fleisher et al. 2015). In patients with poor or unknown functional capacity, the number of active clinical risk factors should guide the need for further testing. The 2014 ACC/AHA CPG provides a preoperative algorithm for guidance on perioperative management to minimize associated risk on the basis of available evidence and expert opinion (Figure 2.1).

Step 5: Supplemental Preoperative Evaluation

Supplemental testing allows the clinician to obtain prognostic information, further guiding therapy and perioperative management. A preoperative electrocardiogram (ECG) within 30 days of surgery is useful in patients with established coronary heart disease, providing a useful baseline standard to measure changes postoperatively (Beattie et al. 2006).

An ECG is not useful in asymptomatic patients undergoing low-risk surgical procedures (Liu et al. 2002, Turnbull and Buck, 1987).

Left ventricular (LV) function should be preoperatively evaluated in patients with dyspnea of unknown origin, patients with HF with worsening dyspnea, other changes in clinical status, or stable patients with a history of LV dysfunction and no assessment within a year (Healy et al. 2010).

Table 2.2 A) Procedural-Based Risk

High risk (5%)	Advanced upper abdominal extensive debulking
	Segmental liver resection
	HIPEC
Intermediate risk (1%–5%)	Intraperitoneal and intrathoracic surgery
	Head and neck surgery
	Orthopedic surgery
	Simple and radical hysterectomy
	Robotic hysterectomy
	Extensive MIS debulking
Low risk (<1%)	Simple endoscopic procedures (IP port)
	Superficial procedures
	Wide local excision ambulatory surgery
	Vascular port placements

Source: Adapted from Fleisher LA, Beckman JA, Brown KA, et al., *Anesth Analg* **106**:685–712, 2008.

Table 2.2 B) Preoperative Cardiac Evaluation Algorithm

Without known cardiac issue	Low-risk procedure	Proceed with planned procedure
	Intermediate- or high-risk procedure	Determine functional capacity, proceed with planned procedure if ≥4 METs without symptoms
Low or unknown functional	Intermediate- or high-risk procedure	Consider cardiac testing if it will change capacity management Proceed with heart rate control or consider noninvasive testing if it will change management

Source: Adapted from Fleisher LA et al., *J Am Coll Cardiol* **50**:1707–32, 2007.

Table 2.3 Metabolic Equivalents

I.	Eat, dress, use the toilet without assistance
II.	Walk indoors and around the house without assistance
III.	Walk a block or two on level ground at 2–3 mph without assistance
IV.	Perform light work around the house including dusting or washing dishes
V.	Climb a flight of stairs or walk up a hill
VI.	Walk on level ground at 4 mph
VII–X.	Run a short distance
	Perform heavy housework including scrubbing floor or lifting or moving heavy furniture
	Participate in moderate recreational activity including golf, bowling, dancing, tennis
	Perform strenuous sport activity like running, swimming
	Participate in singles tennis, football, basketball, and skiing

Sources: Adapted from Hlatky MA, Boineau RE, Higginbotham MB, et al., *Am J Cardiol* **64**:651–4, 1989; Fletcher GF, Balady G, Froelicher VF, et al., *Circulation* **91**:580–615, 1995; Fleisher LA, Beckman JA, Brown KA, et al., *Anesth Analg* **106**:685–712, 2008.

For patients with elevated risk who have an excellent functional capacity (>10 METs), and possibly moderate to good (>4 to 10 METs) functional capacity, it is reasonable to forego further testing and proceed with surgery (Carliner et al. 1985). For patients with elevated risk and poor (<4 METs) or unknown functional capacity, it may be reasonable to perform exercise testing with cardiac imaging or noninvasive pharmacologic stress testing to assess for myocardial ischemia if it will change management (Das et al. 2000). Perioperative cardiac risk is directly linked to the extent of jeopardized viable myocardium identified by stress cardiac imaging (Beattie et al. 2006). Cardiopulmonary exercise testing may be considered for patients undergoing elevated risk procedures where functional capacity is unknown (Snowden et al. 2013).

PERIOPERATIVE THERAPY

In patients where preoperative risk stratification recommends revascularization prior to surgery, proceeding with therapy should be dictated according to existing clinical practice guidelines (Hillis et al. 2012, Levine et al. 2011). There are no randomized controlled trials to support routine coronary revascularization prior to noncardiac surgery exclusively to reduce perioperative cardiac events (McFalls et al. 2004).

In patients who have had prior percutaneous coronary intervention (PCI), elective noncardiac surgery should be delayed 14 days after balloon angioplasty, 30 days following bare metal stent (BMS) placement, and 365 days following drug-eluding stent (DES) placement (Berger et al. 2010, Nuttall et al. 2008, van Kuijk et al. 2009).

In situations where noncardiac surgery is necessary, a consensus decision regarding the relative risks of surgery and antiplatelet therapy can be helpful.

Patients with implantable cardioverter defibrillators (ICDs) who have inactivated programming preoperatively should have continuous cardiac monitoring utilized intraoperatively with external defibrillation equipment readily available (Fleisher et al. 2015).

PERIOPERATIVE MEDICAL MANAGEMENT

Several randomized control trials have suggested perioperative beta-blockade reduces cardiac events in high-risk patients during noncardiac procedures. However, other studies, including a

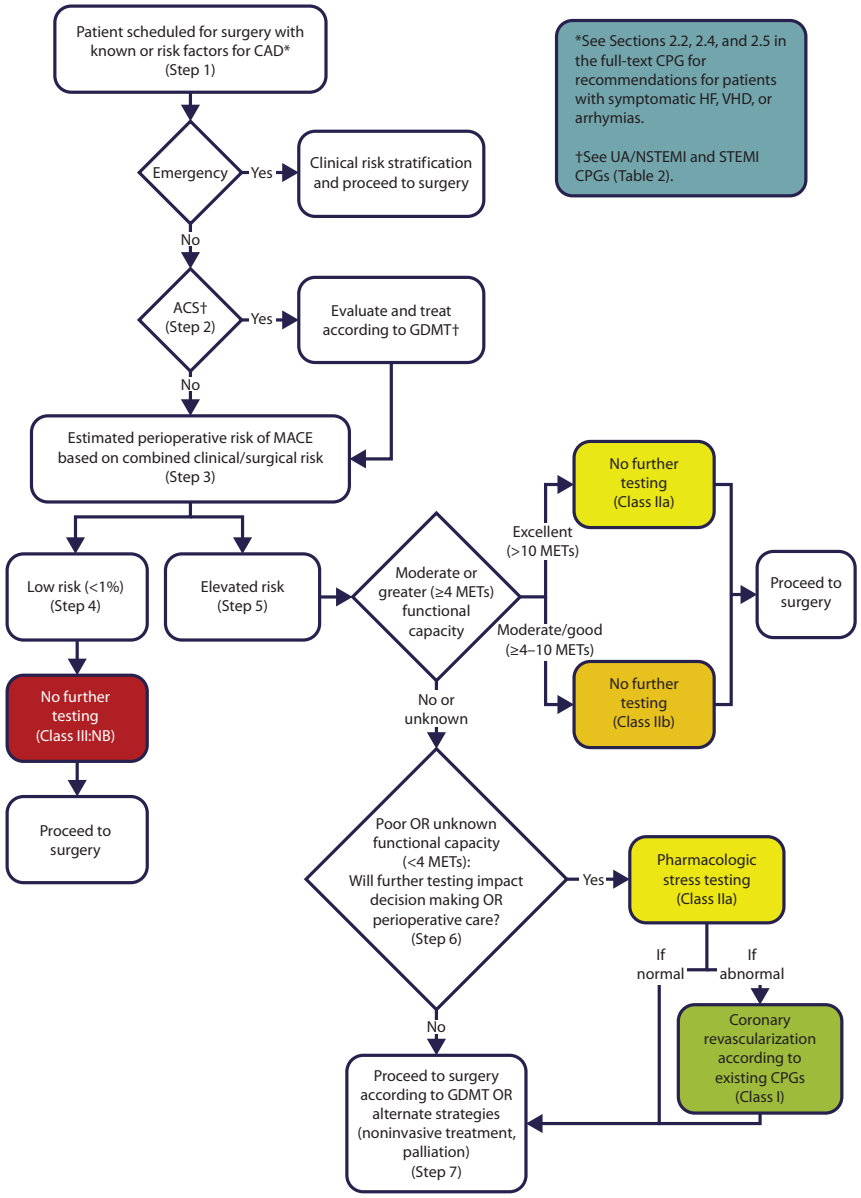

Figure 2.1 Stepwise approach to perioperative cardiac assessment for CAD. Colors correspond to the Classes of Recommendations in Table 2.1. *Step 1:* In patients scheduled for surgery with risk factors for or known CAD, determine the urgency of surgery. If an emergency, then determine the clinical risk factors that may influence perioperative management and proceed to surgery with appropriate monitoring and management strategies based on the clinical assessment (see Section 2.1 in Fleisher et al. 2014 for more information on CAD). (For patients with symptomatic HF, VHD, or arrhythmias, see Sections 2.2, 2.4, and 2.5 in Fleisher et al. 2014 for information on evaluation and management.) *Step 2:* If the surgery is urgent or elective, determine if the patient has an ACS. If yes, then refer patient for cardiology evaluation and management according to GDMT according to the UA/NSTEMI and STEMI CPGs (18,20). *Step 3:* If the patient has risk factors for stable CAD, then estimate the perioperative risk of MACE on the basis of the combined clinical/surgical risk. This estimate can use the American College of Surgeons NSQIP risk calculator (http://www.surgicalriskcalculator.com) or incorporate the RCRI (131) with an estimation of surgical risk. For example, a patient undergoing very low-risk surgery (e.g., ophthalmologic surgery), even with multiple risk factors, would have a low risk of MACE, whereas a patient undergoing major vascular surgery with few risk factors would have an elevated risk of MACE (Section 3, Fleisher et al. 2014). *Step 4:* If the patient has a low risk of MACE (<1%), then no further testing is needed, and the patient may proceed to surgery (Section 3, Fleisher et al. 2014). *Step 5:* If the patient is at elevated risk of MACE, then determine functional capacity with an objective measure or scale such as the DASI (133). If the patient has moderate, good, or excellent functional capacity (≥4 METs), then proceed to surgery without further evaluation (Section 4.1, Fleisher et al. 2014). *Step 6:* If the patient has poor (<4 METs) or unknown functional capacity, then the clinician should consult with the patient and perioperative team to determine whether further testing will impact patient decision making (e.g., decision to perform original surgery or willingness to undergo CABG or PCI, depending on the results of the test) or perioperative care. If yes, then pharmacological stress testing is appropriate. In those patients with unknown functional capacity, exercise stress testing may be reasonable to perform. If the stress test is abnormal, consider coronary angiography and revascularization depending on the extent of the abnormal test. The patient can then proceed to surgery with GDMT or consider alternative strategies, such as noninvasive treatment of the indication for surgery (e.g., radiation therapy for cancer) or palliation. If the test is normal, proceed to surgery according to GDMT (Section 5.3, Fleisher et al. 2014). *Step 7:* If testing will not impact decision making or care, then proceed to surgery according to GDMT or consider alternative strategies, such as noninvasive treatment of the indication for surgery (e.g., radiation therapy for cancer) or palliation. ACS indicates acute coronary syndrome; CABG, coronary artery bypass graft; CAD, coronary artery disease; CPG, clinical practice guideline; DASI, Duke Activity Status Index; GDMT, guideline-directed medical therapy; HF, heart failure; MACE, major adverse cardiac event; MET, metabolic equivalent; NB, No Benefit; NSQIP, National Surgical Quality Improvement Program; PCI, percutaneous coronary intervention; RCRI, Revised Cardiac Risk Index; STEMI, ST-elevation myocardial infarction; UA/NSTEMI, unstable angina/non–ST-elevation myocardial infarction; and VHD, valvular heart disease. * and †: see further Fleischer et al. 2014. (Reproduced with permission from Fleisher LA, Fleischmann KE, Auerbach AD et al. 2015. *J Am Coll Cardiol* 2014;64(22):e77-e137.)

systematic review, have suggested no benefit, with instead an increase in risk of bradycardia and stroke (Juul et al. 2006, Shammash et al. 2001, Yang et al. 2006). According to the 2014 ACC/AHA CPG, beta blockers should be continued in those chronically dependent (Andersson et al. 2014, Lindenauer et al. 2004). Initiating perioperative beta-blockade in patients at intermediate or high risk for myocardial ischemia as determined by preoperative risk stratification may be reasonable (Boersma et al. 2001); however, initiating the day of surgery is not recommended (Devereaux et al. 2006). Similarly, statins should be continued perioperatively (Desai et al. 2010, Kennedy et al. 2005, Lindenauer et al. 2004, Raju et al. 2013). A meta-analysis by Hindler et al. uncovered a 44% reduction in mortality with perioperative statin use, while perioperative statin withdrawal is an independent predictor of myonecrosis (Hindler et al. 2006, Le Manach et al. 2007). The majority of data on perioperative statin use is derived from observational studies demonstrating a protective effect on cardiac complications (Lindenauer et al. 2004, Raju et al. 2013).

Studies have suggested alpha-2 agonists reduce mortality and MI in vascular procedures; however, 2014 ACC/AHA recommendations note these benefits do not transcend to patients undergoing noncardiac surgery (Ellis et al. 1994, Oliver et al. 1999, Stuhmeier et al. 1996, Thomson et al. 1984, Wijeysundera and Beattie 2003). Perioperative calcium channel blockers may also reduce perioperative ischemia and SVT with a trend toward reduced MI and death; however, large-scale trial studies are needed (Wijeysundera and Beattie 2003). Calcium channel blockers with significant negative inotropic effect (i.e., diltiazem and verapamil) have potential to worsen HF (Fleisher et al. 2015). Perioperative angiotensin-converting enzyme (ACE) inhibitors or angiotensin-receptor blocker (ARB) data are limited to observational studies demonstrating an increased risk of hypotension on the day of surgery, without change in cardiovascular outcomes (Rosenman et al. 2008, Turan et al. 2012). The 2014 ACC/AHA CPG states it is reasonable to continue ACE inhibitors and ARBs perioperatively, and if they are held preoperatively, to restart them as soon as clinically feasible postoperatively (Fleisher et al. 2015). In order to lower the risk of renal failure, ACE inhibitors and ARBs should be used judiciously in procedures where large fluid shifts can be anticipated (Bertrand et al. 2001, Comfere et al. 2005, Coriat et al. 1994).

Antiplatelet therapy for the prevention of BMS and DES thrombosis is most protective within the first 4 to 6 weeks after stent implantation (Nuttall et al. 2008, van Kuijk et al. 2009). If urgent surgery is required within this time period, antiplatelet therapy should be continued unless the relative risk of bleeding outweighs the benefit of the prevention of stent thrombosis. If the antiplatelet therapy must be discontinued, it is recommended to continue aspirin and to restart antiplatelet therapy as soon as possible after surgery. Perioperative planning should be determined in concert with the entire medical team to optimize therapy plans and outcomes. The initiation or continuation of aspirin is not beneficial in patients undergoing elective, noncardiac, noncarotid surgery in those without stents unless the risk of ischemic events outweighs the risk of surgical bleeding (Fleisher et al. 2015).

In patients with atrial fibrillation (AF) and prosthetic valves, vitamin K antagonists are prescribed for stroke and thromboembolic prevention. Factor Xa inhibitors are additionally used in patients for stroke prevention with AF but are associated with an increased risk of thrombotic events compared to warfarin (Fleisher et al. 2015). In patients requiring surgery, the risks of bleeding must be weighed against the benefit of remaining on anticoagulants. In procedures with minimal risk of bleeding, it may be reasonable to continue the anticoagulants perioperatively. Patients on vitamin K antagonists with prosthetic valves may require bridging therapy with unfractionated heparin (UFH) or low-molecular weight heparin (LMWH), depending on the associated risks. Reversal agents include vitamin K and fresh frozen plasma. Of note, vitamin K response is delayed, including a delayed return to therapeutic level of anticoagulation, when the antagonists are restarted. Vitamin K antagonists should be discontinued 5 days preoperatively, with bridging therapy at the same time, if utilized. The antagonists may be discontinued earlier, if the international normalized ratio (INR) is higher. The INR should be checked the day prior to surgery. If elevated (1.5 or higher) the day prior, 1–2 mg of oral vitamin K should be administered with a repeat INR the morning of surgery (Douketis et al. 2012). Vitamin K antagonist therapy may then be reinitiated 12–24 hours postoperatively following confirmation of adequate hemostasis. LMWH may be initiated according to risk 48–72 hours postoperatively and continued until the INR reaches the therapeutic range of 2–3. For procedures with an elevated risk of surgical bleeding, it is recommended to discontinue the inhibitors 48 hours or more prior to the procedure (Fleisher et al. 2015). Retrievable inferior vena cava (IVC) filters may be utilized in patients where the risk of bleeding with anticoagulation outweighs the utilization of antithrombotic agents. Temporary IVC filters have been found to effectively capture thrombi and protect against thromboembolic complications (Linsenmaier et al. 1998).

ASSESSMENT OF HEMATOLOGIC RISK

Thromboembolic Disease

Forty percent of postoperative gynecologic deaths and the most preventable cause of hospital deaths are directly related to pulmonary emboli.

Thromboembolic disease is the most frequent cause of postoperative death in patients with uterine or cervical carcinoma (Martino et al. 2006).

Without thromboprophylaxis, the postoperative gynecologic cancer patient has between a 17% and 40% estimated risk of developing a venous thromboembolism (Clarke-Pearson et al. 1984b). Risk stratification, dependent upon patient-specific and procedural-specific risk factors, may be implemented within models to determine the need for therapy, balanced with the risk of bleeding (Geerts et al. 2008). One such model, the Caprini score, estimates risk according to a point system (Caprini 2005). An adaptation provided in the American College of Chest Physicians consensus statement published in 2012 categorizes risk as very low (0–1 point), low (2 points), moderate (3–4 points), or high (≥ 5 points) (Gould et al. 2012). However, gynecologic patients have not been validated individually with the

Caprini score, and are instead stratified according to abdominal or pelvic surgeries. An alternative risk classification system is provided within the ACOG Practice Bulletin 84, modified from the 2004 Chest guidelines (Geerts et al. 2008) (see Figure 2.2). Commonly placed within the highest risk categories, the cancer patient is often subject to additional risks including chemotherapy, radiation therapy, and hormonal treatment, further necessitating the need for long-term thromboprophylactic therapy.

Options for perioperative thromboembolic prophylaxis include pharmacologic and mechanical methods. The risk of venous thromboembolism incidence is decreased to 2% to 6% with standard preventive measures, including intermittent pneumatic compression (IPC), UFH, and LMWH. (Prevention of deep vein thrombosis and pulmonary embolism (2007)) According to the ENOXACAN II study, 4 weeks of postoperative anticoagulation decreases the incidence of VTE from 12% to 4.8% in cancer patients undergoing abdominal, gynecological, or urological surgery (Bergqvist et al. 2002).

IPC devices reduce venous stasis and promote endogenous fibrinolysis. A threefold reduction of venous thromboembolism was found in gynecologic cancer patients undergoing surgery when IPCs are used intraoperatively and continued for 5 days postoperatively (Clarke-Pearson et al. 1984c).

Comparisons of LMWH to UFH have shown overall superiority to LMWH. However, UFH in individualized PTT directed treatment may be therapeutically equivalent. Paradoxically, the overall cost of LMWH is less than UFH when all the nursing and lab costs are included. UFH may be associated with low pharmacy cost.

Concerns with UFH include an increased risk of postoperative bleeding and heparin-induced thrombocytopenia (Clarke-Pearson et al. 1984a). LMWH is associated with decreased risk of bleeding complications, has increased bioavailability and greater ease of use with once-daily dosing. When compared to UFH, LMWH is rarely associated with Heparin-Induced Thrombocytopenia (HIT). Dual prophylaxis with pharmacologic and mechanical methods may benefit the high-risk oncology patient, and is possibly cost-effective (Agnelli et al. 1998; Clarke-Pearson et al. 2003).

Lowest preoperative risk patients do not require prophylaxis, but should begin early ambulation (Figure 2.2). Moderate-risk patients should have at least one type of preventative measure (mechanical or pharmacologic). High-risk patients should receive both mechanical and pharmacologic prevention with IPCs and LMWH (Douketis et al. 2012). IPCs should be initiated preoperatively and continued until ambulation. While all methods are cost-effective, patients in the high-risk group benefit most from the use of IPC with LMWH (Dainty et al. 2004). High-risk patients subjected to a major cancer procedure or with multiple risk factors should receive thromboprophylaxis after hospital discharge for up to 28 days postoperatively. Extended prophylaxis for this is supported by the American College of Chest Physicians and American College of Gynecologists (Geerts et al. 2008).

Inherited risk factors for VTE typically do not result in VTE until an additional precipitating event induces formation (Middeldorp et al. 1998). Factor V Leiden mutation and prothrombin gene mutation G20210A are the most common mutations uncovered with VTE occurrence. Factor V Leiden is carried by 5% of Caucasians and in up to 20% of patients with VTE (Dahlback et al. 1993). Prothrombin G20210A mutations are less common, almost exclusively found in Caucasians, and found in 6% of patients with VTE (Poort et al. 1996). Antithrombin III, protein C, and protein S are additional inherited deficiencies that also result in an increased risk of VTE. Although rare, patients with a strong family history of clots who are negative for Factor V Leiden or prothrombin mutation should consider additional testing (Rosendaal 2005). Antiphospholipid syndrome is an acquired thrombophilia associated with arterial and venous thrombosis. Testing for antiphospholipid syndrome includes serum analysis for lupus anticoagulant and anticardiolipin antibodies (de Groot and Derksen, 2005).

Duplex ultrasonography is ordered with suspicion for the presence of deep venous thromboembolism (DVT).

The sonogram duplex may need to be repeated as the risk of DVT continues throughout the postop period and the sensitivity of the test is only approximately 80% and highly variable.

Treatment is with heparinization to 1.5 times control prothrombin time or with therapeutic doses of LMWH. Increasing sensitivity of dynamic contrast-enhanced computerized tomography has confirmed the replacement of the prior gold standard of pulmonary arteriogram in the diagnosis of pulmonary embolism. Upon diagnosis of a pulmonary embolism, the patient is anticoagulated with UFH or LMWH. LMWH and direct thrombin inhibitors are generally preferred. Long-term anticoagulation should last for 3 months in the case of DVT and 6 months in the case of pulmonary embolism. Some patients on thrombogenic chemotherapy regimens may benefit from lifelong anticoagulation.

ASSESSMENT OF PULMONARY RISK

Pulmonologic-associated procedural-based risk may be specific to the patient, the procedure, or both. Approximately 25% of morbidity in the early postoperative period is pulmonary related, including atelectasis, pneumonia, respiratory failure, and exacerbation of underlying chronic lung disease (Fisher et al. 2002). Major abdominal surgery induces a 20% to 30% overall risk of pulmonary complications (Ferguson 1999). Vital capacity is reduced by 45% and functional residual capacity is reduced by 20% with laparotomy (Qaseem et al. 2006). The supine position results in a reduction of functional residual capacity below alveolar closing volume, significantly increasing the postoperative risk of atelectasis. Several additional intraoperative factors increase the risk of perioperative pulmonary complications (Table 2.4). Procedural-based pulmonary risk factors include duration of surgery, choice of anesthetic, the emergent nature of the procedure, and incision location. Risk factors specific to the patient include increasing age, chronic lung disease, cigarette use, functional status, obesity, congestive heart failure, asthma, obstructive sleep apnea, poor mental status, alcohol use, and neurologic impairment (Doyle 1999, Smetana et al. 2006).

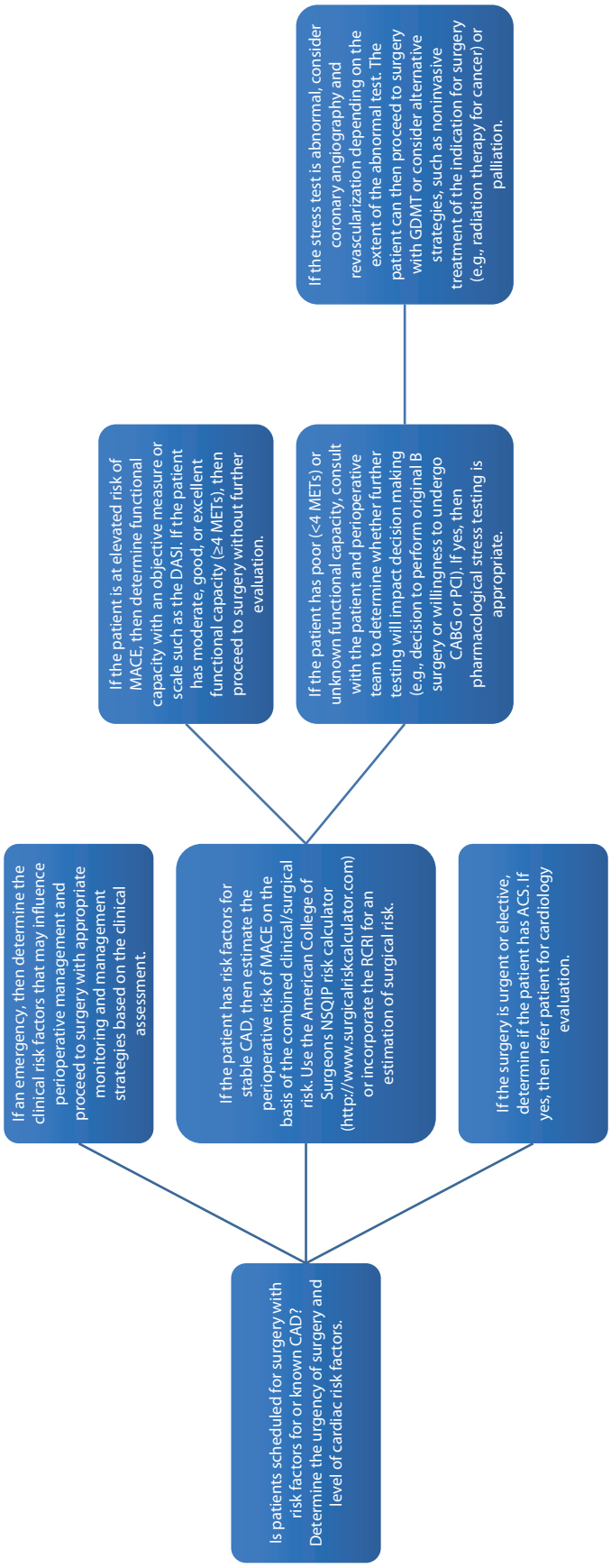

Figure 2.2 Risk classification system. ACS indicates acute coronary syndrome; CABG, coronary artery bypass graft; CAD, coronary artery disease; CPG, clinical practice guideline; DASI, Duke Activity Status Index; GDMT, guideline-directed medical therapy; MACE, major adverse cardiac event; MET, metabolic equivalent; NSQIP, National Surgical Quality Improvement Program; PCI, percutaneous coronary intervention; RCRI, Revised Cardiac Risk Index.

Table 2.4 Intraoperative Factors that Increase the Risk of Perioperative Pulmonary Complications

- Length of surgery
- Amount of IV crystalloids
- Amount of colloid
- Hyperthermia
- Advanced age
- Low preoperative oxygen saturation
- Respiratory infection within the past month
- Preoperative anemia
- Upper abdominal or thoracic surgery
- Emergency surgery

Congestive obstructive pulmonary disease (COPD) remains the most common risk factor for postoperative pulmonary complications. Patients with COPD retain carbon dioxide, have poor gas exchange, and have an increased residual volume. Smoking increases the risk of postoperative complications even in the absence of chronic lung disease. Perioperative pulmonary risk is particularly increased in those who have been smoking more than 20 years, and is highest in patients still smoking within 2 months of surgery (Moller et al. 2002).

Obstructive sleep apnea increases risk for airway management difficulties in the immediate perioperative period; however, with the epidemic of obesity, almost all patients are at risk for some complication.

Patients with a history of asthma or other restrictive lung diseases are at a minimal risk for postoperative complications (Smetana et al. 2006).

There is no predictive value in obtaining a chest x-ray in a well, normal adult and it should not be included in the preoperative evaluation. Alternatively, patients at increased risk for perioperative pulmonary complications, including those older than 50 years of age and those with diagnosed lung disease, may benefit from a baseline chest x-ray. Pulmonary function testing (PFT) may be used to assess the extent of disease and predict the risk of postoperative complications. However, few clinical trials actually support PFT, with the exception of restrictive lung disease (Qaseem et al. 2006). Patients with longstanding restrictive lung disease are at a significantly elevated risk for pulmonary hypertension. Preoperative functional status and coordination with the patient's pulmonologist can be helpful for perioperative pulmonology care. Spirometry may be helpful in diagnosing obstructive lung disease; however, it has not been proven to be predictive of postoperative pulmonary complications. In the setting of unacceptably poor preoperative PFTs, the urgent nature of a procedure should be considered. Management may be determined in concert with the anesthesiologist, and may require cancellation or pulmonary rehabilitation. Preoperative arterial blood gases are not considered an acceptable routine test; however, when indicated, an elevated $PaCO_2$ above 45 mmHg has been proven to increase perioperative complications, while surgery is contraindicated in patients with hypoxemia (PO2 < 50 mmHg). A low serum albumin (<35g/L) is an additional marker for increased risk of postoperative pulmonary complications, particularly in patients with more than one risk factor (Gibbs et al. 1999).

Risk reduction strategies in the postoperative period include pulmonary expansion by means of incentive spirometry, chest wall expansion, deep breathing, and cough, none of which has been proven to be superior to the others. Increased use of bronchodilators and steroids, exacerbations, and smoking are risk factors for perioperative bronchospasm. Prophylaxis in reactive airway disease is with perioperative inhaled beta agonists by inhaler or nebulizer therapy. Steroid therapy should be reserved for those patients already using them as a part of their current regimen, which may decrease inflammation preoperatively and minimize bronchospasm postoperatively. Prophylactic antibiotics have no place in perioperative therapy to prevent pulmonary complications. Patients on oral steroids for prolonged periods of time should receive preoperative stress dose steroids (see below; "Adrenal Suppression"). Preoperative consultation with an anesthesiologist may be helpful in this patient population for planning medication use, optimization of therapy, and communication.

ASSESSMENT OF ENDOCRINOLOGIC RISK

Diabetes Mellitus

Perioperative hyperglycemia has been found to increase the risk of adverse events in patients undergoing elective noncardiac surgery (Frisch et al. 2010).

Postoperative glucose levels greater than 200 mg/dL are associated with prolonged hospital stays and increased risk of postoperative complications including wound infections and cardiac arrhythmias (Ramos et al. 2008).

Postoperative infections make up two-thirds of postoperative complications in diabetics with vascular disease, which additionally increase the risk of postoperative MI and acute renal failure (Dronge et al. 2006).

Diabetes-associated perioperative risk can be determined by evaluating the extent of the disease. Microvascular changes induce long-term complications and end-organ damage, including retinopathy, neuropathy, nephropathy, and cardiovascular disease (Meneghini 2009). The presence of disease for 10 years or more even further increases the risk of microvascular complications (Schiff and Welsh 2003). Preoperative assessment includes a thorough history and physical, an ECG, and serologies evaluating renal function with a glycosylated hemoglobin (HBA1C) level. Understanding the extent of neuropathy prior to the administration of chemotherapy provides a baseline for post-therapy assessments. Preoperative medical management in a diabetic may include holding medications the night prior to surgery (such as metformin and thiazolinediones for risk of lactic acidosis and postoperative fluid retention) or the morning of surgery (most oral antihyperglycemics). Insulin-requiring diabetics should continue regular short-acting insulin the night prior and halve the a.m. dose. Long-acting basal insulin should be continued at full dose unless additionally taking oral antihyperglycemics, when the basal insulin dose should be cut in half (Meneghini 2009). A diabetic controlled by diet alone does not require additional antihyperglycemic therapy preoperatively or intraoperatively.

Operative physiologic stress induces a hyperglycemic state in the diabetic patient. This is caused by an adrenal stress response releasing epinephrine, norepinephrine, cortisol, and growth hormone, all of which suppress insulin function. Gluconeogenesis and lipolysis support the stress response by mobilizing glucose precursors, inducing a net protein catabolism. Intraoperative glucose assessment in procedures lasting longer than 2 hours monitors for signs of ketosis or acidosis resulting from this hyperglycemic stress response (Hoogwerf 2006).

Diabetic patients have an increased risk for postoperative cardiac complications including ischemia and infarction and acute renal failure. Large fluid shifts, peritoneal evaporative loss, anesthetic agents, and gastrointestinal and respiratory losses result in decreased intravascular volume, which may impact postoperative renal function, particularly in the diabetic. Large amounts of crystalloids should be avoided in all perioperative patients but especially in diabetics with reduced renal function. Wound complications and postoperative infections are driven by the hyperglycemic impairment of phagocytes, granulocytes, and collagen synthesis at glucose levels >200 mg/dL. This impairment and microvasculopathy place the uncontrolled diabetic patient at a significantly elevated risk for wound and fascial dehiscence. The microvascular changes of diabetes impair oxygen delivery to tissues, compounding the already poor ability to ward off infection within the wound. Several retrospective studies have found that tighter glycemic control lowers incidence of postoperative wound complications, including reduced infectious morbidity (Marks 2003).

Postoperative glycemic control has undergone recent modification. A large randomized study by Van den Berghe et al. (2001) found that aggressive insulin therapy (glucose levels between 80 and 110 mg/dL) reduced episodes of septicemia and in-hospital mortality over standard insulin therapy (glucose levels between 180 and 200 mg/dL). In contrast, the NICE-SUGAR trial (Normoglycemia in Intensive Care Evaluation and Survival Using Glucose Algorithm Regulation) found an increased risk of mortality (27.5% vs. 24.9%) with intensive control, with the majority due to an increased risk of hypoglycemia (Finfer et al. 2009). Because of these results, management of glycemic control will depend upon the postoperative status, the type and management of the patient's diabetes, and oral intake status to maintain blood glucose levels below 180 mg/dL in the critically ill and 140 mg/dL in the non-critically ill (Moghissi et al. 2009). Converting total insulin requirements to long-acting insulin (50%–80% of total requirements) will more frequently achieve the glycemic goal of <140 mg/dL with lower risk of postoperative infections (Umpierrez et al. 2011).

Thyroid Dysfunction

Thyroid dysfunction increases the risk of perioperative complications associated with cardiac, vascular, metabolic, and central nervous systems. Thyroid-stimulating hormone and thyroxine (T4) levels should be obtained preoperatively in patients with a diagnosis of thyroid dysfunction or those with a history of fatigue and new-onset depression. Avoidance of rare but serious complications (myxedema coma and thyroid storm) can be accomplished by appropriate preoperative assessment.

Retrospective studies have demonstrated that euthyroid to mild or even moderate hypothyroidism may safely undergo surgery (Weinberg et al. 1983).

Perioperative risks associated with hypothyroidism include intraoperative hypotension, gastrointestinal complications including ileus, postoperative neuropsychiatric complications, and inability to mount fever. Patients with severe hypothyroidism (myxedema coma, decreased mentation, pericardial effusions, heart failure, or very low levels of T4) who are in need of an urgent/emergent procedure should receive intravenous T4 and stress dose glucocorticoids (Ladenson et al. 1984). Signs of myxedema coma, a medical emergency, include seizures, coma, unexplained heart failure, hypothermia, prolonged ileus, or postoperative delirium (Stathatos and Wartofsky 2003).

Hyperthyroidism poses perioperative cardiac risk due to the ability of both T4 and triiodothyronine (T3) to impose inotropic and chronotropic effects on cardiac function. The most common cause of hyperthyroidism is Graves' disease, an autoimmune disorder resulting in increased thyroid hormone production. Hyperthyroidism is characterized by tachycardia, atrial fibrillation, fever, tremor, goiter, and ophthalmopathy. The greatest perioperative risk to an untreated hyperthyroid patient is the development of thyroid storm and should be considered in any patient suffering postoperative fever, tachycardia, hyperpyrexia, nausea and vomiting, or delirium. Treatment includes beta-blockade, thionamides, iodine, and corticosteroids in addition to admittance to an intensive care unit for appropriate monitoring. Until control is achieved, moderate to severe hyperthyroidism necessitates surgery cancellation.

Patients with mild disease may proceed with surgery with the support of perioperative beta-blockade.

Moderate to severe (thyrotoxic) patients should have surgery delayed unless the procedure is emergent or urgent. Premedication for these patients includes antithyroid agents, beta-blockade, and corticosteroids.

Adrenal Suppression

Exogenous corticosteroid use over a prolonged period of time poses a potential risk for hypothalamic pituitary axis (HPA) suppression. In preoperative evaluation, the surgeon must determine the type of steroid used, the duration of treatment, and whether a taper was used if the medication was discontinued. Doses seldom resulting in HPA suppression and not requiring stress-dose corticosteroids include steroid equivalents to 5 mg of prednisone as a single daily dose, alternate-day steroids given as a morning dose, and any steroid used for less than 3 weeks. Alternatively, patients taking 20-mg equivalents of prednisone daily for more than 3 weeks require stress-dose steroids in the perioperative period (Salem et al. 1994). Theoretically, the steroid doses typically used every 3 weeks for prevention of hypersensitivity reactions could be associated with adrenal insufficiency (Del Priore et al. 1995). Preoperative stress-dose steroids are used for the prevention of HPA suppression and its life-threatening sequelae. Administering stress-dose glucocorticosteroids must be weighed against the potential side effects of

the medication including poor wound healing, fluid retention, and increased risk for infection.

ASSESSMENT OF RENAL RISK

The prevalence of renal disease in surgical patients continues to rise alongside the incidence of diabetes and hypertension. Advancements in dialysis are allowing many patients to live with end stage renal disease (ESRD). These patients are subject to increased risks of perioperative morbidity and mortality. Patients with ESRD commonly suffer from coronary artery disease and peripheral vascular disease. Half of patients with ESRD die of cardiovascular disease (Go et al. 2004). Contributing factors include microalbuminuria/proteinuria, hypertension, diabetes, dyslipidemia, and smoking (Weir 2011). Preoperative evaluation of ESRD patients includes a cardiac evaluation, electrolyte and fluid management, assessing for anemia or bleeding diatheses, and optimizing glycemic control. Postoperatively, these patients tend to have difficulty with fluid balance, anemia, electrolyte, acid-base abnormalities, and postoperative wound complications secondary to an immunocompromised state. Engaged surgeons can help ensure euvolemia, periprocedural electrolyte replacement, and postoperative fluid shift management. Goal-directed fluids, with as little crystalloid as needed, will help in maintaining euvolemia.

Serum creatinine levels are a poor indicator of renal function.

Day-to-day variations in creatinine more likely reflect acute changes in volume of distribution. All patients have age-related reduction in renal function. All chemotherapy patients have some degree of renal impairment despite normal creatinine.

Erythropoetin is commonly administered to ESRD patients to maintain hemoglobin levels chronically (Eschbach et al. 1989). Within the immediate perioperative period, transfusion may be required to achieve acceptable preoperative hemoglobin levels. ESRD patients frequently suffer increased risk of bleeding secondary to platelet dysfunction due to uremic inhibition, abnormal von Willebrand factor binding, abnormal platelet arachidonic acid metabolism, excess vascular prostacyclin, and nitric acid production. 1-deamino-8-D-arginine vasopressin (dDAVP) intravenously can be used to treat uremic platelet dysfunction or may be administered intranasally with cryoprecipitate to prevent intraoperative bleeding (Rabelink et al. 1994).

ASSESSMENT OF HEPATIC RISK

The most common cause of chronic liver disease in the United States is nonalcoholic fatty liver disease. Routine testing of liver function rarely yields an abnormality or changes perioperative management in the routine surgical patient. However, liver disorders can impact perioperative risk enough to significantly confer unnecessary morbidity and mortality. Decompensated liver disease increases the perioperative risk of acute hepatic failure, sepsis, bleeding, and renal dysfunction. A patient presenting with a history of jaundice, blood transfusions, alcohol or recreational drug use, acute hepatitis, or physical findings of icterus, hepatosplenomegaly, palmar erythema, or spider nevi should be tested to rule out occult or active liver disease (Hoetzel et al. 2012).

The extent of liver dysfunction and type of surgery play key roles in determining perioperative risk. The Child-Turcott-Pugh (CTP) classification and the model of end-stage liver disease (MELD) assist in determining overall surgical risk by assessing the severity of underlying liver disease. The CTP score was found to correlate with overall mortality depending on the procedure (Hoetzel et al. 2012). Liver disease easily affects many other organ systems in the body including the cardiorespiratory and circulatory systems, the brain, kidneys, and the immune system. Patients with chronic hepatitis without cirrhosis have very minimal perioperative morbidity; however, those patients with acute hepatitis have an associated mortality rate of up to 50% and should not undergo non-emergent or urgent procedures until resolution of the acute phase. Cirrhotic disease significantly increases perioperative surgical risk. Cirrhotic patients additionally suffer coagulopathies and frequently require administration of vitamin K, fresh frozen plasma, or cryoprecipitate prior to surgery.

REFERENCES

Agnelli G, Piovella F, Buoncristiani P, et al. 1998. Enoxaparin plus compression stockings compared with compression stockings alone in the prevention of venous thromboembolism after elective neurosurgery. *N Engl J Med* **339**:80–5.

Andersson C, Merie C, Jorgensen M, et al. 2014. Association of beta-blocker therapy with risks of adverse cardiovascular events and deaths in patients with ischemic heart disease undergoing noncardiac surgery: A Danish nationwide cohort study. *JAMA Intern Med* **174**:336–44.

Ashton CM, Petersen NJ, Wray NP, et al. 1993. The incidence of perioperative myocardial infarction in men undergoing noncardiac surgery. *Ann Intern Med* **118**:504–10.

Beattie WS, Abdelnaem E, Wijeysundera DN, et al. 2006. A meta-analytic comparison of preoperative stress echocardiography and nuclear scintigraphy imaging. *Anesth Analg* **102**:8–16.

Berger PB, Kleiman NS, Pencina MJ, et al. 2010. Frequency of major noncardiac surgery and subsequent adverse events in the year after drug-eluting stent placement results from the EVENT (Evaluation of Drug-Eluting Stents and Ischemic Events) Registry. *JACC Cardiovasc Interv* **3**:920–7.

Bergqvist D, Agnelli G, Cohen AT, et al. 2002. Duration of prophylaxis against venous thromboembolism with enoxaparin after surgery for cancer. *N Engl J Med* **346**:975–80.

Bertrand M, Godet G, Meersschaert K, et al. 2001. Should the angiotensin II antagonists be discontinued before surgery? *Anesth Analg* **92**:26–30.

Boersma E, Poldermans D, Bax JJ, et al. 2001. Predictors of cardiac events after major vascular surgery: Role of clinical characteristics, dobutamine echocardiography, and beta-blocker therapy. *JAMA* **285**:1865–73.

Caprini JA. 2005. Thrombosis risk assessment as a guide to quality patient care. *Dis Mon* **51**:70–8.

Carliner NH, Fisher ML, Plotnick GD, et al. 1985. Routine preoperative exercise testing in patients undergoing major noncardiac surgery. *Am J Cardiol* **56**:51–8.

Clarke-Pearson DL, Delong ER, Synan, IS, et al. 1984a. Complications of low-dose heparin prophylaxis in gynecologic oncology surgery. *Obstet Gynecol* **64**:689–94.

Clarke-Pearson DL, Dodge RK, Synan I, et al. 2003. Venous thromboembolism prophylaxis: Patients at high risk to fail intermittent pneumatic compression. *Obstet Gynecol* **101**:157–63.

Clarke-Pearson DL, Synan IS, Colemen, RE, et al. 1984b. The natural history of postoperative venous thromboemboli in gynecologic oncology: Aprospective study of 382 patients. *Am J Obstet Gynecol* **148**:1051–4.

Clarke-Pearson DL, Synan IS, Hinshaw, WM, et al. 1984c. Prevention of postoperative venous thromboembolism by external pneumatic calf compression in patients with gynecologic malignancy. *Obstet Gynecol* **63**:92–8.

Cohen ME, Ko CY, Bilimoria KY, et al. 2013. Optimizing ACS NSQIP modeling for evaluation of surgical quality and risk: Patient risk adjustment, procedure mix adjustment, shrinkage adjustment, and surgical focus. *J Am Coll Surg* **217**:336–46.e1.

Comfere T, Sprung J, Kumar MM, et al. 2005. Angiotensin system inhibitors in a general surgical population. *Anesth Analg* **100**:636–44

Coriat P, Richer C, Douraki T, et al. 1994. Influence of chronic angiotensin-converting enzyme inhibition on anesthetic induction. *Anesthesiology* **81**:299–307.

Dahlback B, Carlsson M, Svensson PJ. 1993. Familial thrombophilia due to a previously unrecognized mechanism characterized by poor anticoagulant response to activated protein C: Prediction of a cofactor to activated protein C. *Proc Natl Acad Sci U S A* **90**:1004–8.

Dainty L, Maxwell GL, Clarke-Pearson DL, et al. 2004. Cost-effectiveness of combination thromboembolism prophylaxis in gynecologic oncology surgery. *Gynecol Oncol* **93**:366–73.

Das MK, Pellikka PA, Mahoney DW, et al. 2000. Assessment of cardiac risk before nonvascular surgery: Dobutamine stress echocardiography in 530 patients. *J Am Coll Cardiol* **35**:1647–53.

De Groot PG, Derksen RH. 2005. The antiphospholipid syndrome: Clinical characteristics, laboratory features and pathogenesis. *Curr Opin Infect Dis* **18**:205–10.

Del Priore G, Gurski KJ, Warshal DP, et al. 1995. Adrenal function following high-dose steroids in ovarian cancer patients. *Gynecol Oncol* **59**(1):102–4.

Desai H, Aronow WS, Ahn C, et al. 2010. Incidence of perioperative myocardial infarction and of 2-year mortality in 577 elderly patients undergoing noncardiac vascular surgery treated with and without statins. *Arch Gerontol Geriatr* **51**:149–51.

Detsky AS, Abrams HB, Mclaughlin JR, et al. 1986. Predicting cardiac complications in patients undergoing noncardiac surgery. *J Gen Intern Med* **1**:211–9.

Devereaux PJ, Yang H, Guyatt GH, et al. 2006. Rationale, design, and organization of the PeriOperative ISchemic Evaluation (POISE) trial: A randomized controlled trial of metoprolol versus placebo in patients undergoing noncardiac surgery. *Am Heart J* **152**:223–30.

Douglas PS, Garcia MJ, Haines DE, et al. 2011. ACCF/ASE/AHA/ASNC/HFSA/HRS/SCAI/SCCM/SCCT/SCMR 2011 Appropriate Use Criteria for Echocardiography. *J Am Coll Cardiol* **57**:1126–66.

Douketis JD, Spyropoulos AC, Spencer FA, et al. 2012. Perioperative management of antithrombotic therapy: Antithrombotic Therapy and Prevention of Thrombosis, 9th ed: American College of Chest Physicians Evidence-Based Clinical Practice Guidelines. *Chest* **141**:e326S–50S.

Doyle RL. 1999. Assessing and modifying the risk of postoperative pulmonary complications. *Chest* **115**:77s–81s.

Dronge AS, Perkal MF, Kancir S, et al. 2006. Long-term glycemic control and postoperative infectious complications. *Arch Surg* **141**:375–80; discussion 380.

Eagle KA, Berger PB, Calkins H, et al. 2002. ACC/AHA Guideline Update for Perioperative Cardiovascular Evaluation for Noncardiac Surgery—Executive Summary. A report of the American College of Cardiology/American Heart Association Task Force on Practice Guidelines (Committee to Update the 1996 Guidelines on Perioperative Cardiovascular Evaluation for Noncardiac Surgery). *Anesth Analg* **94**:1052–64.

Ellis JE, Drijver G, Pedlow S, et al. 1994. Premedication with oral and transdermal clonidine provides safe and efficacious postoperative sympatholysis. *Anesth Analg* **79**:1133–40.

Eschbach JW, Kelly MR, Haley NR, et al. 1989. Treatment of the anemia of progressive renal failure with recombinant human erythropoietin. *N Engl J Med* **321**:158–63.

Ferguson MK. 1999. Preoperative assessment of pulmonary risk. *Chest* **115**:58s–63s.

Finfer S, Chittock DR, Su SY, et al. 2009. Intensive versus conventional glucose control in critically ill patients. *N Engl J Med* **360**:1283–97.

Fisher BW, Majumdar SR, McAlister FA, et al. 2002. Predicting pulmonary complications after nonthoracic surgery: A systematic review of blinded studies. *Am J Med* **112**:219–25.

Fleisher LA, Beckman JA, Brown KA, et al. 2008. ACC/AHA 2007 guidelines on perioperative cardiovascular evaluation and care for noncardiac surgery: Executive summary: A report of the American College of Cardiology/American Heart Association Task Force on Practice Guidelines (Writing Committee to Revise the 2002 Guidelines on Perioperative Cardiovascular Evaluation for Noncardiac Surgery). *Anesth Analg* **106**:685–712.

Fleisher LA, Fleischmann KE, Auerbach AD, et al. 2015. 2014 ACC/AHA guideline on perioperative cardiovascular evaluation and management of patients undergoing noncardiac surgery: Executive summary: A report of the American College of Cardiology/American Heart Association Task Force on practice guidelines. *J Nucl Cardiol* **22**:162–215.

Fletcher GF, Balady G, Froelicher VF, et al. 1995. Exercise standards: A statement for healthcare professionals from the American Heart Association. *Circulation* **91**:580–615.

Freeman WK, Gibbons RJ. 2009. Perioperative cardiovascular assessment of patients undergoing noncardiac surgery. *Mayo Clin Proc* **84**(1):79–90.

Frisch A, Chandra P, Smiley D, et al. 2010. Prevalence and clinical outcome of hyperglycemia in the perioperative period in noncardiac surgery. *Diabetes Care* **33**:1783–8.

Geerts WH, Bergqvist D, Pineo GF, et al. 2008. Prevention of venous thromboembolism: American College of Chest Physicians Evidence-Based Clinical Practice Guidelines (8th Edition). *Chest* **133**:381s–453s.

Gibbs J, Cull W, Henderson W, et al. 1999. Preoperative serum albumin level as a predictor of operative mortality and morbidity: Results from the National VA Surgical Risk Study. *Arch Surg* **134**:36–42.

Go AS, Chertow GM, Fan D, et al. 2004. Chronic kidney disease and the risks of death, cardiovascular events, and hospitalization. *N Engl J Med* **351**:1296–305.

Goldman L, Caldera DL, Nussbaum SR, et al. 1977. Multifactorial index of cardiac risk in noncardiac surgical procedures. *N Engl J Med* **297**:845–50.

Gould MK, Garcia DA, Wren SM, et al. 2012. Prevention of VTE in nonorthopedic surgical patients: Antithrombotic Therapy and Prevention of Thrombosis, 9th ed: American College of Chest Physicians Evidence-Based Clinical Practice Guidelines. *Chest* **141**:e227S–77S.

Gupta PK, Gupta H, Sundaram A, et al. 2011. Development and validation of a risk calculator for prediction of cardiac risk after surgery. *Circulation* **124**:381–7.

Hammill BG, Curtis LH, Bennett-Guerrero E, et al. 2008. Impact of heart failure on patients undergoing major noncardiac surgery. *Anesthesiology* **108**:559–67.

Healy KO, Waksmonski CA, Altman RK, et al. 2010. Perioperative outcome and long-term mortality for heart failure patients undergoing intermediate- and high-risk noncardiac surgery: Impact of left ventricular ejection fraction. *Congest Heart Fail* **16**:45–9.

Hillis LD, Smith PK, Anderson JL, et al. 2012. 2011 ACCF/AHA guideline for coronary artery bypass graft surgery: Executive summary: A report of the American College of Cardiology Foundation/American Heart Association Task Force on Practice Guidelines. *J Thorac Cardiovasc Surg* **143**:4–34.

Hindler K, Shaw AD, Samuels J, et al. 2006. Improved postoperative outcomes associated with preoperative statin therapy. *Anesthesiology* 105:1260–72; quiz 1289–90.

Hlatky MA, Boineau RE, Higginbotham MB, et al. 1989. A brief self-administered questionnaire to determine functional capacity (the Duke Activity Status Index). *Am J Cardiol* **64**:651–4.

Hoetzel A, Ryan H, Schmidt R. 2012. Anesthetic considerations for the patient with liver disease. *Curr Opin Anaesthesiol* **25**:340–7.

Hoogwerf BJ. 2006. Perioperative management of diabetes mellitus: How should we act on the limited evidence? *Cleve Clin J Med* **73**:Suppl 1, S95–9.

Juul AB, Wetterslev J, Gluud C, et al. 2006. Effect of perioperative beta blockade in patients with diabetes undergoing major noncardiac surgery: Randomised placebo controlled, blinded multicentre trial. *BMJ* **332**:1482.

Kennedy J, Quan H, Buchan AM, et al. 2005. Statins are associated with better outcomes after carotid endarterectomy in symptomatic patients. *Stroke* **36**:2072–6.

Ladenson PW, Levin AA, Ridgway EC, et al. 1984. Complications of surgery in hypothyroid patients. *Am J Med* **77**:261–6.

Le Manach Y, Godet G, Coriat P, et al. 2007. The impact of postoperative discontinuation or continuation of chronic statin therapy on cardiac outcome after major vascular surgery. *Anesth Analg* **104**:1326–33.

Lee TH, Marcantonio ER, Mangione CM, et al. 1999. Derivation and prospective validation of a simple index for prediction of cardiac risk of major noncardiac surgery. *Circulation* **100**:1043–9.

Levine GN, Bates ER, Blankenship JC, et al. 2011. 2011 ACCF/AHA/SCAI Guideline for Percutaneous Coronary Intervention. A report of the American College of Cardiology Foundation/American Heart Association Task Force on Practice Guidelines and the Society for Cardiovascular Angiography and Interventions. *J Am Coll Cardiol* **58**:e44–122.

Lindenauer PK, Pekow P, Wang K, et al. 2004. Lipid-lowering therapy and in-hospital mortality following major noncardiac surgery. *JAMA* **291**:2092–9.

Linsenmaier U, Rieger J, Schenk F, et al. 1998. Indications, management, and complications of temporary inferior vena cava filters. *Cardiovasc Intervent Radiol* **21**:464–9.

Liu LL, Dzankic S, Leung JM. 2002. Preoperative electrocardiogram abnormalities do not predict postoperative cardiac complications in geriatric surgical patients. *J Am Geriatr Soc* **50**:1186–91.

Livhits M, Ko CY, Leonardi MJ, et al. 2011. Risk of surgery following recent myocardial infarction. *Ann Surg* **253**:857–64.

Mangano DT. 1990. Perioperative cardiac morbidity. *Anesthesiology* **72**:153–84.

Marks JB. 2003. Perioperative management of diabetes. *Am Fam Physician* **67**:93–100.

Martino MA, Borges E, Williamson E, et al. 2006. Pulmonary embolism after major abdominal surgery in gynecologic oncology. *Obstet Gynecol* **107**:666–71.

Mashour GA, Shanks AM, Kheterpal S. 2011. Perioperative stroke and associated mortality after noncardiac, nonneurologic surgery. *Anesthesiology* **114**:1289–96.

McFalls EO, Ward HB, Moritz TE, et al. 2004. Coronary-artery revascularization before elective major vascular surgery. *N Engl J Med* **351**:2795–804.

Meneghini LF. 2009. Perioperative management of diabetes: Translating evidence into practice. *Cleve Clin J Med* **76** :Suppl 4, S53–9.

Middeldorp S, Henkens CM, Koopman MM, et al. 1998. The incidence of venous thromboembolism in family members of patients with factor V Leiden mutation and venous thrombosis. *Ann Intern Med* **128**:15–20.

Moghissi ES, Korytkowski MT, Dinardo M, et al. 2009. American Association of Clinical Endocrinologists and American Diabetes Association consensus statement on inpatient glycemic control. *Endocr Pract* **15**:353–69.

Moller AM, Villebro N, Pedersen T, et al. 2002. Effect of preoperative smoking intervention on postoperative complications: A randomised clinical trial. *Lancet* **359**:114–7.

Nishimura RA, Otto CM, Bonow RO, et al. 2014. 2014 AHA/ACC guideline for the management of patients with valvular heart disease: Executive summary: A report of the American College of Cardiology/American Heart Association Task Force on Practice Guidelines. *J Am Coll Cardiol* **63**:2438–88.

Nuttall GA, Brown MJ, Stombaugh JW, et al. 2008. Time and cardiac risk of surgery after bare-metal stent percutaneous coronary intervention. *Anesthesiology* **109**:588–95.

[No authors listed]. Practice Bulletin No. 84: Prevention of deep vein thrombosis and pulmonary embolism: Correction. *Obstet Gynecol.* 2016 Jan;127(1):166. Erratum for ACOG Practice Bulletin No. 84: Prevention of deep vein thrombosis and pulmonary embolism. [*Obstet Gynecol.* 2007]

Oliver MF, Goldman L, Julian DG, et al. 1999. Effect of mivazerol on perioperative cardiac complications during noncardiac surgery in patients with coronary heart disease: The European Mivazerol Trial (EMIT). *Anesthesiology* **91**:951–61.

Poort SR, Rosendaal FR, Reitsma PH, et al. 1996. A common genetic variation in the 3'-untranslated region of the prothrombin gene is associated with elevated plasma prothrombin levels and an increase in venous thrombosis. *Blood* **88**:3698–703.

Qaseem A, Snow V, Fitterman N, et al. 2006. Risk assessment for and strategies to reduce perioperative pulmonary complications for patients undergoing noncardiothoracic surgery: A guideline from the American College of Physicians. *Ann Intern Med* **144**:575–80.

Rabelink TJ, Zwaginga JJ, Koomans HA, et al. 1994. Thrombosis and hemostasis in renal disease. *Kidney Int* **46**:287–96.

Raju MG, Pachika A, Punnam SR, et al. 2013. Statin therapy in the reduction of cardiovascular events in patients undergoing intermediate-risk noncardiac, nonvascular surgery. *Clin Cardiol* **36**:456–61.

Ramos M, Khalpey Z, Lipsitz S, et al. 2008. Relationship of perioperative hyperglycemia and postoperative infections in patients who undergo general and vascular surgery. *Ann Surg* **248**:585–91.

Reilly DF, Mcneely MJ, Doerner D, et al. 1999. Self-reported exercise tolerance and the risk of serious perioperative complications. *Arch Intern Med* **159**:2185–92.

Rosendaal FR. 2005. Venous thrombosis: The role of genes, environment, and behavior. *Hematology Am Soc Hematol Educ Program* 1–12.

Rosenman DJ, Mcdonald F S, Ebbert JO, et al. 2008. Clinical consequences of withholding versus administering renin-angiotensin-aldosterone system antagonists in the preoperative period. *J Hosp Med* **3**:319–25.

Salem M, Tainsh RE, Jr, Bromberg J, et al. 1994. Perioperative glucocorticoid coverage. A reassessment 42 years after emergence of a problem. *Ann Surg* **219**:416–25.

Schein OD, Katz J, Bass EB, et al. 2000. The value of routine preoperative medical testing before cataract surgery. Study of Medical Testing for Cataract Surgery. *N Engl J Med* **342**:168–75.

Schiff RL, Welsh GA. 2003. Perioperative evaluation and management of the patient with endocrine dysfunction. *Med Clin North Am* **87**:175–92.

Shah KB, Kleinman BS, Sami H, et al. 1990. Reevaluation of perioperative myocardial infarction in patients with prior myocardial infarction undergoing noncardiac operations. *Anesth Analg* **71**:231–5.

Shammash JB, Trost JC, Gold JM, et al. 2001. Perioperative beta-blocker withdrawal and mortality in vascular surgical patients. *Am Heart J* **141**:148–53.

Smetana GW, Lawrence VA, Cornell JE. 2006. Preoperative pulmonary risk stratification for noncardiothoracic surgery: Systematic review for the American College of Physicians. *Ann Intern Med* **144**:581–95.

Snowden CP, Prentis J, Jacques B, et al. 2013. Cardiorespiratory fitness predicts mortality and hospital length of stay after major elective surgery in older people. *Ann Surg* **257**:999–1004.

Stathatos N, Wartofsky L. 2003. Perioperative management of patients with hypothyroidism. *Endocrinol Metab Clin North Am* **32**:503–18.

Stuhmeier KD, Mainzer B, Cierpka J, et al. 1996. Small, oral dose of clonidine reduces the incidence of intraoperative myocardial ischemia in patients having vascular surgery. *Anesthesiology* **85**:706–12.

Thomson IR, Mutch WA, Culligan JD. 1984. Failure of intravenous nitroglycerin to prevent intraoperative myocardial ischemia during fentanyl-pancuronium anesthesia. *Anesthesiology* **61**:385–93.

Turan A, You J, Shiba A, et al. 2012. Angiotensin converting enzyme inhibitors are not associated with respiratory complications or mortality after noncardiac surgery. *Anesth Analg* **114**:552–60.

Turnbull JM, Buck C. 1987. The value of preoperative screening investigations in otherwise healthy individuals. *Arch Intern Med* 147:1101–5.

Umpierrez GE, Smiley D, Jacobs S, et al. 2011. Randomized study of basal-bolus insulin therapy in the inpatient management of patients with type 2 diabetes undergoing general surgery (RABBIT 2 surgery). *Diabetes Care* **34**:256–61.

Van den Berghe G, Wouters P, Weekers F, et al. 2001. Intensive insulin therapy in critically ill patients. *N Engl J Med* **345**:1359–67.

Van Kuijk JP, Flu WJ, Schouten O, et al. 2009. Timing of noncardiac surgery after coronary artery stenting with bare metal or drug-eluting stents. *Am J Cardiol* **104**:1229–34.

Weinberg AD, Brennan MD, Gorman CA, et al. 1983. Outcome of anesthesia and surgery in hypothyroid patients. *Arch Intern Med* **143**:893–7.

Weir MR. 2011. Recognizing the link between chronic kidney disease and cardiovascular disease. *Am J Manag Care* **17**:Suppl 15, S396–402.

Wijeysundera DN, Beattie WS. 2003. Calcium channel blockers for reducing cardiac morbidity after noncardiac surgery: A meta-analysis. *Anesth Analg* **97**:634–41.

Yang H, Raymer K, Butler R, et al. 2006. The effects of perioperative beta-blockade: Results of the Metoprolol after Vascular Surgery (MaVS) study, a randomized controlled trial. *Am Heart J* **152**:983–90.

3 Complications

David Warshal and James Aikins

INTRODUCTION

Complications are a frequent consequence of surgery. A clear understanding of surgical principles and meticulous technique are essential but are not always sufficient to prevent complications, particularly when normal anatomical relationships have been altered by the presence of a malignancy. Furthermore, some complications are beyond the control of the surgeon. The judicious surgeon must always be cognizant of the potential complications associated with each step of a particular surgical procedure and actively work to minimize these risks. The prompt detection and management of perioperative complications is of paramount importance in order to minimize adverse sequelae.

For this chapter, we have chosen to address what we believe are the most relevant issues in regard to complications associated with gynecologic surgery. Urinary tract complications have not been included in this section since they are discussed in Chapter 30.

BOWEL COMPLICATIONS

Preoperative bowel preparation was considered an essential component in preventing complications associated with colorectal surgery for over a century. However, over the past several years, a series of studies have challenged this belief. A 2011 Cochrane review examining this issue concluded, based on over 5800 subjects participating in 18 trials, that there was no benefit conferred by preoperative bowel preparation. Mechanical bowel preparation versus rectal enema was also examined with no differences detected. In fact, a trend toward increased postoperative infectious complications with bowel preparation was discovered. It has been suggested that this association may be due to leakage of liquid stool from inadequately prepped bowel or from local structural and inflammatory changes of the bowel wall that can result from a mechanical bowel prep. If bulky stool is encountered intraoperatively, it should be gently milked away from the area of resection or washed out from the anus to facilitate reanastomosis. Intravenous antibiotics with both aerobic and anaerobic coverage, such as a second-generation cephalosporin with metronidazole or amoxicillin/clavulanic acid, should be administered preoperatively. Ciprofloxicin or clindamycin may be substituted for the cephalosporin in penicillin-allergic cases. Preoperative use of oral antibiotics has been suggested by multiple studies to reduce the risk of surgical site infection following colectomy.

Historically, injury to the colon, particularly with gross contamination of the peritoneal cavity, was managed by colostomy formation. Recent prospective randomized studies examining the management of traumatic colon injuries have demonstrated either equal or improved outcomes with primary repair rather than colostomy. Though the risk for intra-abdominal sepsis is increased with multiple associated abdominal injuries, massive blood transfusion, and severe peritoneal contamination, the method of management of the colon injury does not affect the incidence of sepsis. In addition, the repair technique, handsewn versus stapled, also does not influence the complication rate. In the face of a colon injury with peritoneal contamination, broad-spectrum antibiotic prophylaxis should be continued for 24 hours.

Intraoperative bowel injuries are most likely to occur during entry into the abdominal cavity and during lysis of adhesions. If entering the abdomen through an old scar, the risk of injury is reduced if entry is gained just beyond the limit of the old scar. Sharp entry is preferred over use of an electrocoagulation device due to the clean, defined nature of a sharp injury. Thermal injuries are more difficult to detect and evaluate due to the potential for delayed tissue necrosis up to a few centimeters beyond the point of visible damage. When a significant thermal injury to the bowel occurs, a wide resection up to 3 to 5 cm from the edges of the injury with primary reanastomosis is recommended. Thin filmy intra-abdominal adhesions can be safely lysed using blunt dissection and the electrocautery devise. Thicker, less yielding adhesions require sharp dissection to avoid injury to the bowel.

Following difficult bowel dissections, direct visual inspection of all bowel surfaces is important. Of note, the risk of compromise of the distal sigmoid colon is increased in cases of ovarian cancer with extensive pelvic disease and with endometriosis where the cul-de-sac may be obliterated. Injury in this area may be particularly difficult to visualize. When concern is raised, a large-gauge foley catheter should be inserted into the rectum and the balloon inflated. With the pelvis filled with saline and the proximal sigmoid occluded with gentle pressure, air is injected into the foley to inflate the bowel. Air will bubble to the surface if a laceration is present.

Small bowel lacerations involving less than half of the circumference of the bowel are repaired without resection. A single layer of full thickness delayed absorbable 3-0 sutures are placed 3 mm apart. The closure is oriented perpendicular to the path of the bowel to limit narrowing of the lumen. A second seromuscular layer imbricating the first layer is sometimes placed, provided that it does not compromise the bowel lumen. The closure should be watertight and is tested by gently milking bowel contents and intraluminal gas past the repair site. Pinching the bowel lumen at the anastomotic site should confirm a luminal diameter of at least 1 cm. If a larger laceration occurs, the edges are devascularized, or multiple small enterotomies involve a short segment of bowel, resection of the injured area with primary reanastomosis is warranted.

Repair of large bowel lacerations is similar to that for the small bowel with a few exceptions. Lacerations of up to 30% of the circumference of the bowel are closed primarily with

larger injuries requiring bowel resection. Two-layer closures as described above are the standard. There is generally no concern regarding narrowing of the large bowel lumen by repair.

Routine use of a nasogastric tube following extensive gynecologic procedures or bowel resection has recently been reexamined. Nasogastric tube suctioning does not reduce the duration of ileus and may actually delay return of normal bowel function. Following bowel resection, the presence of a tube did not affect the incidence of anastomotic leakage or incisional hernia development. In addition to the substantial discomfort associated with nasogastric tubes, they are a major risk factor for postoperative pulmonary complications. Two recent meta-analyses suggested that only up to 10% of patients undergoing bowel resection and managed without nasogastric decompression would warrant insertion later in their postoperative course.

Several studies have recently evaluated the feasibility of early feeding of patients who have undergone bowel resection and other types of intraabdominal surgery. Early feeding was found to be safe and not associated with the development of a prolonged ileus or anastomotic leakage. A reduced length of stay and a reduction in the postoperative infection rate have also been reported. Conversely, many of these studies have also shown that those fed early have an increased risk for nausea, vomiting, and abdominal distention.

Following laparotomy, a *postoperative* ileus occurs routinely. Small bowel motility and absorption generally returns within a few hours of surgery followed by stomach emptying which begins after 24 hours. The colon remains inactive for approximately 48 to 72 hours. This process is controlled by the autonomic nervous system. Occasionally a paralytic ileus may develop that can last from days to weeks. A *paralytic* ileus is associated with bowel mucosal injury secondary to bowel manipulation, hypoxia, endotoxins, and/or hypoperfusion, and all bowel segments are affected. Pain and opioid use can prolong both postoperative and paralytic ileuses. Techniques to reduce the risk of ileus include gentle handling of tissue, appropriate intraoperative fluid management, minimizing opioid use, epidural infusion of local anesthetics for pain management, and use of peripherally acting gastrointestinal opioid receptor antagonist. Alvimopan, approved by the FDA for postoperative use, has been found to shorten the time to return of bowel function without compromising pain control in patients undergoing bowel resection and radical hysterectomy. Concern has been raised regarding a potential association between use of COX 2 inhibitors and impaired intestinal healing following bowel resection. Patients with a paralytic ileus develop abdominal bloating, anorexia, nausea, and vomiting if early feeding is initiated. Abdominal cramping and pain in excess of that anticipated by the patient's postoperative state are usually absent. Physical exam reveals a distended, tympanitic abdomen without bowel sounds. Obstruction series imaging will show a nonspecific bowel gas pattern with dilated loops of small and often large bowel. It can often be difficult radiographically to distinguish an ileus from an early obstruction. It is important to rule out infectious and metabolic causes such as peritonitis, abscess, and electrolyte abnormalities such as hypokalemia and hypomagnesemia. Patients are kept nil per orum (NPO) and observed with supportive measures instituted. For patients with persistent nausea and vomiting, a nasogastric tube should be inserted. However, nasogastric tubes have not been shown to shorten the duration of an ileus. If possible, narcotic use should be minimized. No currently available medications have been demonstrated to relieve a postoperative ileus once it is established. Watchful waiting with periodic obstruction series imaging to exclude an obstruction and blood work to exclude infection and metabolic derangement is recommended. For a prolonged ileus lasting more than 1 week, hyperalimentation should be considered. We have anecdotally found that hunger develops shortly before flatus and that diarrhea is common during the first 24 hours following the onset of bowel movements.

Bowel obstructions, characterized as partial or complete, prevent passage of bowel contents through the intestines. Obstruction most commonly involves the small bowel, with adhesions followed by hernias accounting for the majority of postoperative causes. Symptoms associated with bowel obstructions include colicky abdominal pain that comes in waves, bloating, and rapid onset of nausea, often with forceful emesis that temporarily relieves these symptoms. Auscultation reveals high-pitched, rushing bowel sounds and borborygmi. An obstruction series imaging will show distended loops of bowel with air-fluid levels arranged in a stepladder fashion. Conservative management with placement of a nasogastric tube is appropriate if evidence of bowel strangulation, such as fever, tachycardia, abdominal guarding, rebound tenderness, and leukocytosis are absent. A spontaneous resolution rate of approximately 80% is seen, with partial obstructions responding better than complete blockages. If improvement is not evident within the first 1 to 2 days of conservative management, or if signs and symptoms of bowel compromise develop, surgical exploration should be performed.

Patients who have undergone extensive enterolysis or bowel resection either due to injury or to disease are at risk for perforation or leakage at the anastomotic site with the subsequent development of peritonitis, an abscess, or an enterocutaneous fistula. Leakage from small bowel anastomoses occurs in up to 3% of cases whereas the risk rises to up to 20% for colorectal anastomoses. Patients with perforation or free anastomotic leaks allowing soiling throughout the peritoneum present with fever, tachycardia, increasing abdominal pain, and acute abdominal signs such as guarding and rebound tenderness. In the immediate postoperative period, intra-abdominal free air detected by x-ray will not be diagnostic. Septic shock with hypotension and end-organ dysfunction can rapidly ensue. A high level of suspicion must be maintained when evaluating such patients since the use of postoperative narcotics can minimize these signs and symptoms. If significant concern for peritonitis is present, medical stabilization should be promptly initiated, including the use of broad-spectrum antibiotics, and the patient returned to the operating room for re-exploration. Intraoperative management must be individualized based on the condition of the patient and the complexity of the complication. Often a simple perforation or a small bowel anastomotic leak can be repaired primarily. Distal colonic and rectal anastomotic leaks will usually necessitate colostomy formation. Postoperative abscess formation following contamination of the peritoneal cavity during gynecologic surgery has become much less frequent due to the use of preoperative prophylactic antibiotics. Simple vaginal cuff abscesses can often be opened and allowed to drain

through the vagina. Deeper pelvic or abdominal abscesses can occur spontaneously or in association with a contained leakage from the bowel. Intravenous antibiotics and drainage are usually required. Percutaneous placement of a drainage catheter is favored as a safe approach.

The second group of agents are biologically active. Topical thrombin can be sprayed on an area of light bleeding or can be used in conjunction with a collagen or gelatin matrix. FloSeal® (Baxter, Deerfield, IL) and SURGIFLO combine topical thrombin with a gelatin matrix to provide a framework for clot initiation and limit the spread of thrombin. As noted above, a similar strategy is to saturate Gelfoam® with thrombin. These are applied to areas with light active bleeding and rely on the conversion of the patient's fibrinogen to fibrin to complete hemostasis. Products using bovine thrombin carry a black box warning from the FDA regarding the potential development of antibodies to bovine thrombin and/or factor V that can cross-react against human factor V, causing a factor V deficiency. This can lead to hematologic abnormalities that affect the prothrombin (PT) and the partial thromboplastin (PTT) times and can cause severe bleeding or thrombosis. For more brisk venous or arterial bleeding, fibrin sealants are indicated. These include Tisseal® (Baxter Dearfield, IL), Evicel® (Ethicon Somerville, NJ), and Vitagel® (Orthovita Malvern, PA), and contain thrombin and fibrinogen. Vitagel is unique in that it uses plasma obtained from the patient to supply concentrated autologous fibrinogen, platelets, and other coagulation factors. However, the thrombin in this product is bovine-derived. Fibrin glue can also be made by filling separate syringes with thrombin and cryoprecipitate. The contents of the syringes are applied simultaneously to the area of bleeding. An additional alternative has been developed that impregnates thrombin and fibrinogen onto an oxidized regenerated cellulose patch (EVARREST) to create a seal at the point of bleeding.

There are few studies directly comparing these agents. A rat neurosurgical model was recently used to compare the safety and efficacy of Surgicel®, FloSeal, Arista®, and Avitene® against a negative control. A standardized defect was made in the rats' brain and the agents were then applied to the area. Time to hemostasis was recorded. The rats were sacrificed according to a predetermined schedule and their brains were examined for inflammation and residual hemostatic agent. In this relatively small study, all the hemostatic agents performed better than the negative control, with hemostasis at 1 minute achieved in approximately 65% to 95% of active cases. Avitene and FloSeal showed a propensity to promote granuloma formation and residual material remained for all of the agents but Arista. Clearly these latter two attributes are less critical in abdominal/pelvic surgery.

If the above steps are unsuccessful, suturing of a venous defect in a large vessel such as the vena cava is performed using a 5-0 monofilament suture. Proximal and distal occlusion of the vessel around the site of injury using sponge sticks will facilitate ease of repair. Alternatively, a finger may be placed over the vascular defect and slowly moved down the length of the vessel as successive stitches are placed. For bleeding deep in the pelvis, a bilateral hypogastric artery ligation will reduce the pulse pressure in the more distal vessels and control bleeding in up to 50% of cases.

Recent reports including a meta-analysis have shown that intravenous infusion of recombinant activated factor VIIa has an approximately 75% likelihood of reducing or stopping major abdominal bleeding. Thromboembolic complications occurred in 16% of cases. If all else fails, a base of hemostatic agents are applied to the area of bleeding and packing is placed in an effort to apply pressure to this area when the abdominal wall is closed. A variety of techniques have been described including a "parachute" packing that comes out through the vagina and is placed on traction to apply pressure to the deep pelvis. The patient remains intubated and sedated while medical stabilization is achieved. Prophylactic antibiotics are given and the patient is returned to the operating room for pack removal in 24 to 72 hours.

Where deep pelvic sidewall bleeding is experienced and does not respond to internal iliac ligation but can be controlled by application of clamps deep in the pelvis, it is valuable to be able to leave the clamps in situ and remove them 48 hours postoperatively in the theatre under light anesthesia. Close monitoring thereafter usually reveals no evidence of bleeding.

In situations of excessive hemorrhage, the surgeon must remain aware of the extent of blood loss. If this loss is rapid or extreme, it may be necessary to stop active efforts to identify and repair bleeding sites, which often allows ongoing loss of blood, in favor of controlling the bleeding with pressure and allowing the anesthesiologist to stabilize the patient with crystalloid and blood products. Additional assistants and specialists should be summoned as needed. As blood loss mounts, monitoring of the patient's coagulation profile with replacement using fresh frozen plasma, platelets, and cryoprecipitate as indicated becomes essential. Blood calcium levels can become deranged and be a cause of continuous hemorrhage.

WOUND COMPLICATIONS

The incidence of postoperative wound complications is associated with patient-related factors such as obesity, older age, poor nutritional status, and intercurrent medical conditions such as diabetes and pulmonary disease. Intraoperative factors adversely affecting wound healing include extended duration of surgery, inadequate wound hemostasis, and poor surgical technique. Wound infections occur in up to 12% of cases, while fascial dehiscences are discovered in up to 3% of wounds. Superficial wound separations affect up to 20% of cases. The choice of abdominal incisions is dependent primarily on issues related to access to the pelvis and upper abdomen. Transverse incisions provide excellent exposure to the pelvis while minimizing the cosmetic side effects of pelvic surgery when laparoscopy is not feasible. In addition, many studies, including a recent Cochrane review, have found that when compared to vertical incisions, transverse incisions are associated with less pain, less compromise of pulmonary function, and lower rates of dehiscence and hernia formation. Despite the increased operative time, greater blood loss, and increased risk for nerve damage with transverse incisions, they are the default surgical route when access to the upper abdomen is not needed or large masses do not require intact removal. Entrapment of the ilioinguinal or iliohypogastric nerve within the fascial closure of a transverse incision can occur when the fascial incisions have extended beyond the lateral border of the rectus muscles. Patients present with sharp,

moderate to severe pain localized to the lower quadrant. Relief of the pain following injection of local anesthetic helps to establish the diagnosis. Under extreme circumstances, the fascial stitch may need to be modified.

When pelvic exposure is limited with a Pfannenstiel incision, we recommend conversion to a Cherney incision in which the tendinous insertions of the rectus muscles onto the symphysis pubis are divided. A portion of the tendon is left on both the muscle and the insertion site to facilitate reapproximation with permanent suture at the completion of the procedure. The inferior epigastric vessels are isolated along the lateral edge of each muscle and divided. Partially or fully cutting the rectus muscles under these circumstances is discouraged since the attachment of the muscles to the fascia was taken down as part of the Pfannenstiel incision and closure of the fascia at the completion of the procedure will not reapproximate the cut portion of muscle.

The obese patient presents a special challenge in regard to incision location. The inclination to make a suprapubic incision below the pannus must be resisted due to the high rate of wound breakdown and infection associated with this location. The lone exception to this rule is when a panniculectomy is performed which facilitates the intra-abdominal portion of the procedure and reduced postoperative complications. Gallup has described a technique in which the pannus is retracted caudally and a vertical incision is made either periumbilically or, for those with a very large pannus, entirely supraumbilically. Care must be taken to not extend the incision on to the pannus and inadvertently go through it and on to the mons. The fascial incision is taken down to the symphysis pubis. Issues in regard to closure are discussed below.

Epithelialization begins within hours following wound closure with a watertight seal established within 48 hours. Wounds should be covered with a clean, dry dressing for 24 to 48 hours. The wound's tensile strength increases rapidly during the initial 6 weeks following surgery. Staples may be removed from low-tension, transverse incisions in 7 days. For vertical incisions that are under increased tension, particularly in the obese, staples should remain in place for up to 14 days despite the increased scarring that can develop at the staple sites when they remain in place beyond 7 to 10 days. Tapes such as Steri-Strips are placed across the wound following removal of staples to reduce tension on the skin edges. Alternatives to standard staples for large wounds or those under mild tension are subcuticular stitches or use of copolymer subcutaneous staples that are absorbed over several months and therefore do not need to be removed. For smaller incisions, dermal glues provide fast closure with good cosmesis.

The role of surgical preparation and technique in the development of wound complications has been extensively studied. There is no clear evidence that bathing preoperatively with chlorhexidine reduces the risk for skin infections. Furthermore, scrubbing and painting the abdomen holds no advantage over an iodine-based paint-only skin prep, and using a second scalpel after opening the skin also does not reduce the incidence of wound infections. Clipping rather than shaving pubic hair that might interfere with skin closure has been shown to be beneficial. Incising the subcutaneous fat with either a scalpel or with electrocautery using cutting current also does not appear to affect wound outcome. Coagulation current should not be used for general opening of the subcutaneous tissue or fascia due to the wider path of thermal injury caused by this mode.

Closure of the peritoneum is associated with adhesion formation, infection, and delayed return of bowel function. A running mass closure of the abdominal wall using either delayed-absorbable or permanent monofilament suture with stitches placed 1.5 to 2 cm from the fascial edge and 1 cm apart has a dehiscence rate of less than 0.5%. It is important when closing the fascia to reapproximate the tissue but to not strangulate it by pulling too tightly on the sutures, which can predispose to dehiscence.

Management of the subcutaneous tissue in overweight and obese women remains controversial. A meta-analysis from 2004 examined suture closure of subcutaneous fat greater than 2 cm in thickness during caesarean section. Though only one of the studies independently showed benefit, the analysis concluded that closure decreased the risk of wound disruption by 34%. However, a prospective, randomized study involving 222 evaluable subjects compared a control group to subcutaneous closure or closed suction drainage of the subcutaneous space in gynecologic patients with vertical incisions and 3 cm or more of subcutaneous fat. The overall wound complication rates and wound disruption rates were similar for all groups. Of additional interest is an obstetrical study that showed no difference between suture closure with or without closed suction drainage.

Superficial wound separations occur when excessive tension is placed on the skin edges. Often the subcutaneous tissue has not reapproximated and an infection, seroma, or hematoma may be present. Loculated subcutaneous fluid will usually begin to seep through the wound within 3 to 7 days following surgery, heralding an impending wound separation. If the drainage is copious and persistent, fascial dehiscence must be considered and gentle probing of the fascia with a long Q-tip or a gloved finger should be performed. Purulent drainage due to infection needs to be cultured and drained by opening the incision. Debridement of the wound as described below is usually sufficient. If cellulitis of the skin is present, characterized by erythema, warmth, tenderness, and swelling, antibiotic therapy using a first-generation cephalosporin or a quinolone is prescribed for 10 days.

When a superficial wound separation is apparent, the extent of the defect in the subcutaneous tissue is assessed. If a significant portion of the defect tunnels under an intact area of the wound, particularly if access for debridement and packing is limited, the overlying skin is opened. In the occasional case where the wound surfaces are clean, immediate closure with permanent monofilament suture is performed. Mattress stitches are placed approximately 2 cm apart and tied tight enough to reapproximate but not necrose the tissue. Steri-Strips can be placed between sutures to further approximate the wound edges. It is important to close the deep subcutaneous space to avoid seroma development. We have successfully utilized a modification of the figure-of-eight closure described by Dodson et al. (1992) for patients with particularly deep wounds. Sutures are removed in 10 to 14 days. Antibiotics are used only when infection is present.

If necrotic or infected tissue is present, debridement is performed. Studies evaluating various means of wound debridement including sharp dissection, mechanical debridement using wet-to-dry normal saline dressing changes, and enzymatic

or autolytic agents have failed to identify significant outcome differences between these methods. Once the wound is free of necrotic or infected debris and granulation tissue is present, the wound may be closed using the techniques noted above. Secondary closure significantly reduces recovery time versus healing by secondary intention and is successful in approximately 90% of cases. An additional option to speed healing is a vacuum-assisted closure (VAC) device which cyclically applies negative pressure to the wound bed, facilitating the removal of interstitial fluid and formation of granulation tissue and reducing bacterial colonization. A 2004 study from M.D. Anderson showed that this devise could be used for a variety of complex gynecologic oncology wounds.

Fascial dehiscence (separation of the fascial closure) and evisceration (dehiscence with protrusion of the bowel through the wound) are surgical emergencies that historically have been associated with a mortality rate of up to 35%. Recent series have demonstrated much lower mortality rates, possibly due to earlier recognition and better supportive care. Fascial dehiscence usually occurs 1 to 2 weeks following surgery. When suspected, the incision must be thoroughly inspected, preferably using a gloved finger on the fascia. When a dehiscence is discovered, broad-spectrum antibiotics are started, and the patient is immediately moved to the operating room. Under most circumstances, the point of failure will be the fascia rather than breakage or untying of the suture. The wound should be opened entirely and cleaned of any necrotic or infected tissue. The bowel should be inspected for injury, and copious irrigation of the abdominal cavity performed. A nasogastric tube is placed to help decompress the bowel. A continuous mass closure technique as described above is used to close the abdominal wall. In addition, many surgeons continue to place retention sutures using large permanent sutures placed through the entire thickness of the abdominal wall, spaced approximately 3 cm apart, and secured using skin bridges that allow for adjustment of the tension of the suture. The skin is usually closed secondarily.

BIBLIOGRAPHY

Brown SR, Tiernan J. 2005. Transverse verses midline incisions for abdominal surgery. *Cochrane Database Syst Rev* (4). DOI:10.1002/14651858.CD005199.pub2.

Chelmow D, Rodriguez EJ, Sabatini MM. 2004. Suture closure of subcutaneous fat and wound disruption after cesarean delivery: A meta-analysis. *Obstet Gynecol* **103**:974–80.

Dodson MK, Magann EF, Meeks GR. 1992. A randomized comparison of secondary closure and secondary intention in patients with superficial wound dehiscence. *Obstet Gynecol* **80**(3):321–4.

Guenaga KKFG, Matos D, Wille-Jorgensen P. 2009. Mechanical bowel preparation for elective colorectal surgery. *Cochrane Database Syst Rev* (1).

Güenaga KF, Matos D, Wille-Jørgensen P. 2011. Mechanical bowel preparation for elective colorectal surgery. *Cochrane Database Syst Rev* (9). DOI: 10.1002/14651858.CD001544.pub4.

Pursifull NF, Morey AF. 2007. Tissue glues and nonsuturing techniques. *Curr Opin Urol* **17**:396–401.

Schimp VL, Worley C, Brunello S, Levenback CC, Wolf JK, Sun CC, Bodurka DC, Ramirez PT. 2004. Vacuum-assisted closure in the treatment of gynecologic oncology wound failures. *Gynecol Oncol* **92**(2):586–91.

Stany MP, Farley JH. 2008. Complications of gynecologic surgery. *Surg Clin N Am* **88**:343–59.

Sweeney KJ, Joyce M, Geraghty JG. 2002. Management of intraoperative bowel injuries. *CME J Gynecol Oncol* **7**:178–82.

Tanguy M, Seguin P, Malledant Y. 2007. Bench-to-bedside review: Routine postoperative use of the nasogastric tube—Utility of futility? *Crit Care* **11**:201–7.

Von Heymann C, Jonas S, Spies C, et al. 2008. Recombinant activated factor VIIa for the treatment of bleeding in major vascular and urological surgery: A review and meta-analysis of published data. *Crit Care* **12**:R14.

Wydra D, Emerich J, Ciach K, et al. 2004. Surgical pelvic packing as a means of controlling massive intraoperative bleeding during pelvic posterior exenteration—A case report and review of the literature. *Int J Gynecol Cancer* **14**:1050–4.

4 Anatomy

Ernest F. Talarico, Jr., Jalid Sehouli, Giuseppe Del Priore, and Werner Lichtenegger

INTRODUCTION

Surgical anatomy is the synthesis of topographic, functional, and clinical anatomy and surgical techniques applied to diagnosis and treatment. It presents more than a systematic description of anatomic structures; with particular emphasis on anatomical relationships. Cancer biology and tumor spread are also considered with different surgical techniques. Thus, to achieve the primary goal of cancer treatment, and to completely extirpate tumor masses and preserve important anatomic structures—a detailed knowledge of the anatomy of the pelvis and abdomen is essential. This skill directly influences complication rate (morbidity) and optimal debulking rate (survival) of patients with gynecologic tumors. Further, anatomical knowledge lends insight into pathogenesis, influences treatment decisions, and is critical for effective communication between surgeons and pathologists. Studies have shown that the strongest clinician-driven predictor of survival is the optimal surgical outcome (Barlin et al. 2009, Bristow et al. 2002, Jemal et al. 2008, Lichtenegger et al. 1998). A survey on patients with ovarian carcinoma from 904 American hospitals demonstrated that gynecologic oncologists performed more hysterectomies, oophorectomies, omentectomies, and lymph node, and peritoneal biopsies, and yielded higher debulking rates than other specialists (Nguyen et al. 1993). With the exception of patients with Stage I disease, patients treated by general surgeons had significantly reduced survival compared with those treated by gynecologic oncologists ($p < 0.004$). To optimize clinical management and to eliminate unnecessary steps and improve safety and efficacy, systematic and continual teaching in anatomy is required for all physicians who are involved in the surgical treatment of patients with gynecologic malignancies.

PELVIC FASCIA AND PELVIC SPACES

The pelvic fascia occupies space between the membranous peritoneum and the muscular pelvic walls and floor not occupied by viscera (Figure 4.1). It can be further characterized as membranous pelvic fascia (parietal and visceral) and endopelvic (subperitoneal) fascia. The latter includes numerous synonyms such as intrapelvic fascia, connective tissue body, neurovascular plate, corpus intrapelvicum, paratissue (Stoeckel) parametrium, parangium hypogastricum (Pernkopf), transverse ligament of the collum (Mackenrodt), cardinal ligament (Kocks), web (Meigs), broad ligament, and hypogastric sheets. Some fascia line muscles and viscera, or provide scaffolding, and in doing so form reflections and actual and potential spaces. Their nature and association with pelvic structures explains their inclusion in the critical knowledge base.

Parietal pelvic fascia lines the muscles that form the pelvic walls and floor, and is continuous with transversalis and iliopsoas fascias. Visceral pelvic fascia encloses pelvic organs and forms their adventitial layers. Both parietal and visceral fascias are continuous where viscera penetrate the pelvic floor. Here, parietal fascia thickens, forming the bilateral tendinous arch (arcus) that courses from pubis to sacrum (Figures 4.2 and 4.3), adjacent to the viscera. In females, the arcus is divided into the anterior pubovesicular ligament and the posterior sacrogenital ligaments. This lateral attachment of visceral fascia of the vagina with the arcus is called the paracolpium. The paracolpium supports the vagina and assists in the weight bearing of the urinary fundus. Because of its anatomical course and thickness, the arcus can be used to anchor sutures during reconstructive procedures.

The remaining fascia is endopelvic fascia; it varies in density and content, and forms the matrix surrounding pelvic viscera. Using blunt dissection, surgeons can easily create potential spaces within this loose tissue: the prevesicular (retropubic), the paravesicular (posterolateral), the pararectal and the presacral (retrorectal) spaces (Moore et al. 2014). More fibrous areas of endopelvic fascia form condensations known as pelvic ligaments. One of these, the hypogastric sheath, serves as a conduit for passage of all neurovascular structures passing from the lateral pelvic wall to the viscera, but also separates the retropubic and presacral spaces. Medially, this sheath divides into three pillars (laminae or ligaments) that pass between pelvic organs and convey neurovascular and structural support: the bladder pillar; the lateral rectal pillar; and the uterovaginal pillar (cardinal, or transverse cervical ligament).

The cardinal ligament (see Figure 4.3) is the strongest thickening of pelvic fascia, providing the majority of support for the uterus. It can be used clinically to anchor wide loops of suture during surgical repair. Further, it emits the rectal and bladder pillars. The paracolpium (part of the uterovaginal pillar below the level of the ureter) reaches the vagina and cervix at the level of the vaginal fornix. Additional loose connective tissue lies between the uterus and the ureter (*mesoureter*) containing the blood supply for the ureter.

The bladder pillar courses from the body of the corpus intrapelvicum to the bladder, conveying superior vesicular arteries and veins. Viewed from the vagina, the distal pillar lies in the sagittal plane and rises to the bladder forming a *vesicouterine ligament*, part of which, covering the ureter (ureteral roof), forms the upper limit of the paracystium.

The rectal pillar extends from the cardinal ligament to the sacrum, and conveys the middle rectal arteries and veins, and rectal nerve plexuses. The upper portion deviates laterally to accommodate the pouch of Douglas (rectouterine; cul-de-sac; Moore et al. 2014); bringing it close to the pelvic wall. The rectouterine ligament splits into an anterior leaf that emits rectal fascia, and a posterior leaf, which reaches the sacrum at the level

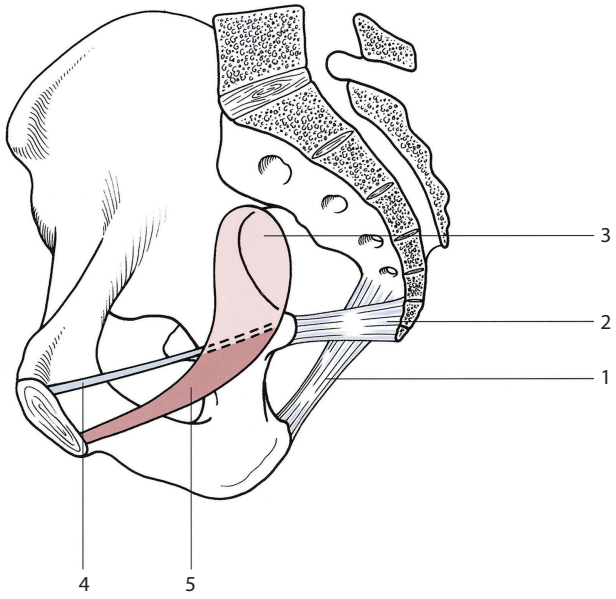

Figure 4.1 1: Ischiosacral ligament; 2: sacrospinous ligament; 3: origin of corpus intrapelvicum at lateral pelvic sidewall; 4: arcus tendineus levatoris ani; 5: arcus tendineus fascia pelvis.

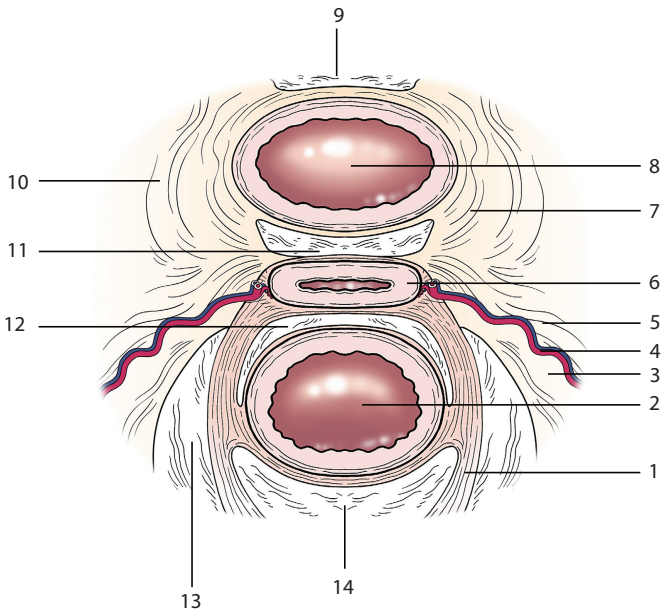

Figure 4.3 1: Uterosacral ligament; 2: rectum; 3: adventitia; 4: vessels; 5: cardinal ligament; 6: vagina; 7: bladder pillar; 8: urinary bladder; 9: prevesical space; 10: paravesical space; 11: vesicovaginal space; 12: rectovaginal space; 13: pararectal space; 14: retrorectal space.

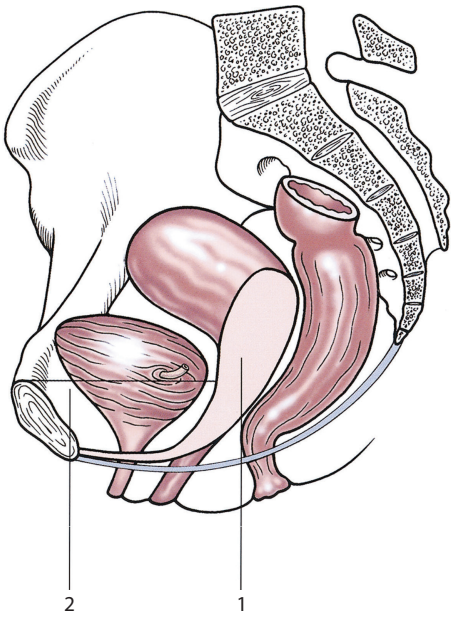

Figure 4.2 1: Corpus intrapelvicum; 2: arcus tendinous levatoris ani.

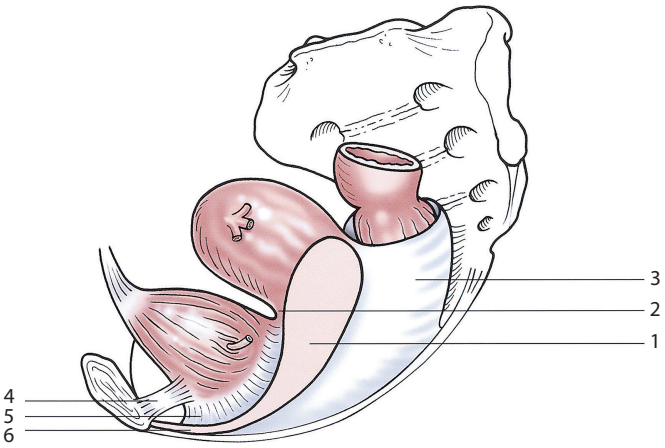

Figure 4.4 1: Origin of connective tissue, detached at lateral pelvic wall; 2: cardinal ligament; 3: uterosacral ligament; 4: pubovesical ligament; 5: laterovesical ligament; 6: arcus tendineus fascia pelvis.

of the anterior sacral foramina II to IV, but can extend upward beyond the sacral promontory (Figures 4.3 and 4.4). As such, this fascia creates a surgically important pelvirectal space superior to the pelvic diaphragm, in contrast to the ischio-anal fossa in the perineum. It is divided into the rectouterine and rectorectal (presacral) spaces by the lateral rectal ligaments. The retrorectal space is limited by rectal fascia and the parietal pelvic fascia, and is separated from the pararectal spaces by the rectal pillar.

The rectouterine pouch opens laterally into the pararectal space (Moore et al. 2014). After being opened from the abdomen, the pararectal space is narrow, because the rectal pillar lies close to the pelvic wall. Surgeons can gain access to this space pulling the uterus anteriorly so that the rectal pillar is lifted off the pelvic wall.

The paravesical space is limited medially by the obliterated umbilical artery (umbilical ligament), vesical fascia, and the ligament of the bladder. At its lateral margin, it merges into the retropubic space. The body of the corpus intrapelvinum and the cardinal ligament form the posterior boundary. The roof of the paravesical and prevesical space is formed by the vesico-umbilical fascia.

The pararectal space is limited medially by the ureter, rectal fascia, and the rectal pillar, and laterally by the parietal pelvic fascia and internal iliac vessels. Its anterior border is the cardinal ligament. After being opened from the abdomen, the pararectal space is narrow, because the rectal pillar lies close to the pelvic wall. The space is best demonstrated by pulling the uterus anteriorly so that the rectal pillar is lifted off the pelvic wall.

The retrorectal/presacral space lies behind the rectum and is limited by rectal fascia and the parietal pelvic fascia. The retrorectal space is separated from the pararectal spaces by the part of the rectal pillar that joins the pelvic sacral foramina II to IV.

Between the vaginal and rectal fascia lies the rectovaginal space extending caudally to the centrum tendinum. Superiorly, it is limited by the peritoneum of the cul-de-sac, and bilaterally by the rectal pillars. The vesicocervical and vaginal spaces are limited by vesical fascia and the cervix, reach the peritoneum, and are separated by the supravaginal septum. The vesicovaginal space reaches caudally to the origin of the urethra and between the bladder pillars.

The rectouterine folds contain a considerable amount of fibrous tissue and muscular fibers which are attached to the front of the sacrum and constitute the uterosacral ligaments (rectouterine ligaments). These ligaments are major ligaments of the uterus (uterosacral, cardinal, and pubocervical ligaments) and course from the uterus near the cervix to the anterior aspect of the sacrum. Pelvic splanchnic nerves run on top of the uterosacral ligaments, and the ligaments are palpable during rectal examination.

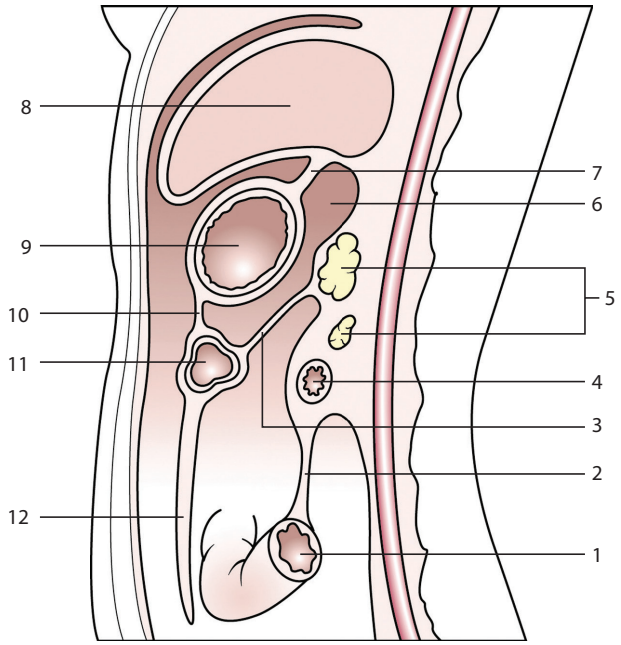

Figure 4.5 1: Small intestine; 2: mesentery; 3: transverse mesocolon; 4: duodenum; 5: pancreas; 6: omental bursa; 7: lesser omentum; 8: liver; 9: stomach; 10: gastrocolic ligament; 11: transverse colon; 12: greater omentum.

UPPER PART OF THE ABDOMEN

In most primary gynecologic cancers, the highest tumor mass is concentrated in the pelvis, whereas the upper abdominal quadrants are predominantly involved by metastases in patients with recurrence. Even so, given the physical proximity of the gastrointestinal (GI) tract to the reproductive tract, as well as the fact that signs and symptoms of GI pathology can mimic those of gynecologic cancers, the abdominal viscera and relationships to peritoneum and peritoneal reflections are important (Le 2013). Gynecologic oncology surgeons are uniquely qualified to balance the surgical effort with the potential therapeutic gain by virtue of their expertise in the relevant cancers, and by virtue of this chapter and similar materials, the relevant surgical anatomy.

The abdominal peritoneal cavity continues inferiorly into the pelvic cavity, and is a potential space devoid of organs but containing a thin film of peritoneal fluid. The intraembryonic coelom (embryonic body cavity) serves as the primordial peritoneum. During development, the primordial abdominal cavity is lined with peritoneum derived from this mesoderm that forms a closed sac; the lumen of this peritoneal sac is the peritoneal cavity. As viscera migrate into this sac, their vessels and nerves remain connected to their extraperitoneal sources or destinations; between fused layers of peritoneum (mesenteries).

Various terms are used to describe parts of the peritoneum/mesentery (Figure 4.5). The small intestine mesentery is referred to as "the mesentery," but other mesenteries of specific parts of the GI tract are named accordingly: mesoesophagus, mesogastrium, transverse and sigmoid mesocolons, and mesoappendix. Omentum describes a double-layered extension of peritoneum passing from the stomach and proximal duodenum to adjacent organs. The greater omentum descends from the greater curvature of the stomach and then ascends to the anterior transverse colon and mesocolon. Similarly, the lesser omentum extends from the lesser curvature of the stomach and duodenum to the liver. Peritoneal ligaments are named based on which organs or parts of the abdominal wall they connect: falciform ligament, hepatogastric, hepatoduodenal ligament (thickened free edge of the lesser omentum conducting the portal triad), gastrophrenic ligament, gastrosplenic ligament, and gastrocolic ligament.

The omental bursa is a sac-like cavity posterior to the stomach, lesser omentum, and gastrocolic ligament that communicates with the greater sac via the epiploic (omental) foramen (of Winslow). Surgeons can explore the omental bursa by preparing the space between the gastrocolic ligament and transverse colon or via the foramen of Winslow by palpation. During primary surgery of ovarian cancer, the greater omentum is often resected incompletely by design. As a consequence, residuals of omentum are frequently detected during surgery in relapse. In the case of an acute pancreatitis, necrosis or effusion can also affect this pouch. In cases of diffuse peritoneal carcinomatosis, peritonectomy is often applied to achieve debulking. This can also be performed in the case of involvement of the right diaphragm. Thus, the falciform ligament of the liver is cut to completely inspect the diaphragm.

Peritoneal recesses/gutters refer mainly to four spaces in the abdomen: left and right paracolic gutters, and left and right paramesenteric gutters. Other smaller recesses include those around the duodenojejunal flexure, cecum, and sigmoid colon. These gutters are clinically important because they allow a passage for infectious fluids from different abdominal compartments. Along the lateral edge of the paracolic gutters (Moore et al. 2014), the White line of Toldt is formed. Surgeons can perform the Cattell maneuver by dividing along the White line of Toldt lateral to the cecum and ascending colon exposing the inferior vena cava (IVC), right renal vessels, fourth part of the duodenum, aorta, and uncinate process of the pancreas.

The duodenum is about 25 cm long, C-shaped, and aside from its ampulla, it is entirely retroperitoneal. The duodenum has four parts: superior, descending, horizontal, and ascending. The ligament of Treitz is a musculofibrous band that extends from the upper aspect of the ascending part of the duodenum to

the right diaphragmatic crus and tissue around the celiac trunk (CT). Always remember that the head of the pancreas lies in the "C" of the duodenum.

VASCULAR SUPPLY

Most vessels encountered during oncologic procedures can be interrupted without ill effect secondary to rich collateral circulation (Figures 4.6 through 4.8). These anastomoses prevent ischemia unless more than one major vessel is occluded. However, patchy ischemia, induced by atherosclerosis, fibrosis, or irradiation, can occur since small vessels entering the gut wall are essentially terminal arteries. Obstruction of these vessels results in segmental ischemia. Whenever possible, vessels should be spared to promote healing and to optimize chemo- and radiotherapy. Certain vessels, such as the superior mesenteric artery (SMA), can never be interrupted without reanastomosis. In advanced cancer, regions of the GI tract are frequently involved; therefore, knowledge of the blood supply of mesenteric and pelvic arteries is required to determine areas of intestinal resection and to obtain maximal debulking.

Blood vessels are not entirely consistent in their course and origin. Guidelines for locating vessels include bony landmarks and cutaneous and muscle relationships. The descending aorta pierces the diaphragm at vertebra level T12 and usually bifurcates at L4. Renal arteries originate near L2. The ovarian arteries arise directly from the aorta at L3. The three major arteries originating from the aorta are the CT (T12–L1); the SMA (L1–L2); and the inferior mesenteric artery (IMA) (L3; 2–3 cm inferior to the SMA) (Figures 4.6 and 4.7). Lastly, external iliac vessels are landmarks of the pelvis that are easily palpated during surgery (Figures 4.7 and 4.8).

The CT supplies mostly structures of the embryonic foregut. From the CT, the common hepatic becomes the proper hepatic; then left and right hepatic (usually giving rise to the cystic artery) arteries. The right gastric and left gastric arteries anastomose, forming the lesser epiploic artery. The common hepatic artery divides into the supraduodenal artery and the gastroduodenal artery, which divides into the right gastro-omental (gastroepiploic) and the superior pancreaticoduodenal. The splenic artery traverses the splenorenal ligament and gives rise to the left gastro-omental artery that anatastomoses with the right gastro-omental artery.

The SMA supplies viscera derived from the embryonic midgut. The SMA runs in the root of the mesentery to the ileocecal junction, gives rise to jejunal and ileal branches, the inferior pancreaticoduodenal artery, the middle and right colic arteries, and terminates as the ileocolic artery. The ileocolic artery divides into ileal and colic branches, and an appendicular artery. The inferior pancreaticoduodenal artery anastomoses with the superior pancreaticoduodenal artery.

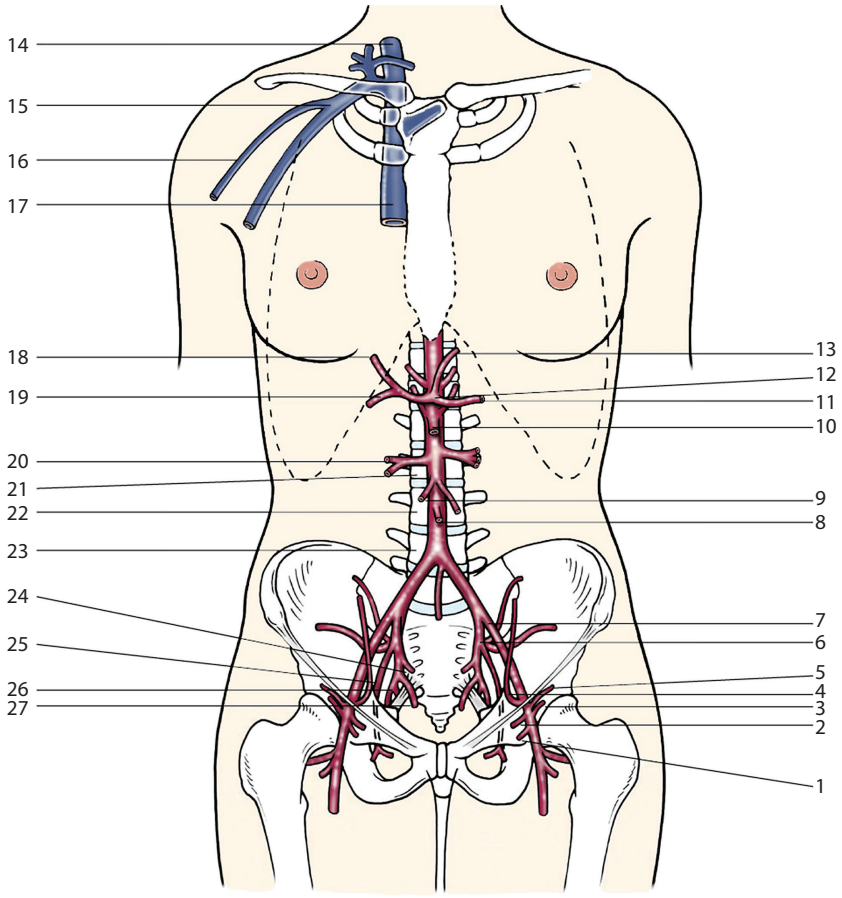

Figure 4.6 1: External pudendal artery; 2: superficial epigastric artery; 3: superficial circumflex iliac artery; 4: inferior epigastric artery; 5: deep circumflex iliac artery; 6: internal iliac artery; 7: external iliac artery; 8: inferior mesenteric artery; 9: gonadal artery; 10: superior mesenteric artery; 11: splenic artery; 12: CT; 13: left gastric artery; 14: internal jugular vein; 15: subclavian vein; 16: cephalic vein; 17: superior vena cava (SVC); 18: hepatic artery; 19: gastroduodenal artery; 20: renal artery; 21: L2; 22: L3; 23: L4; 24: inferior rectal artery; 25: obturator artery; 26: internal pudendal artery; 27: uterine artery.

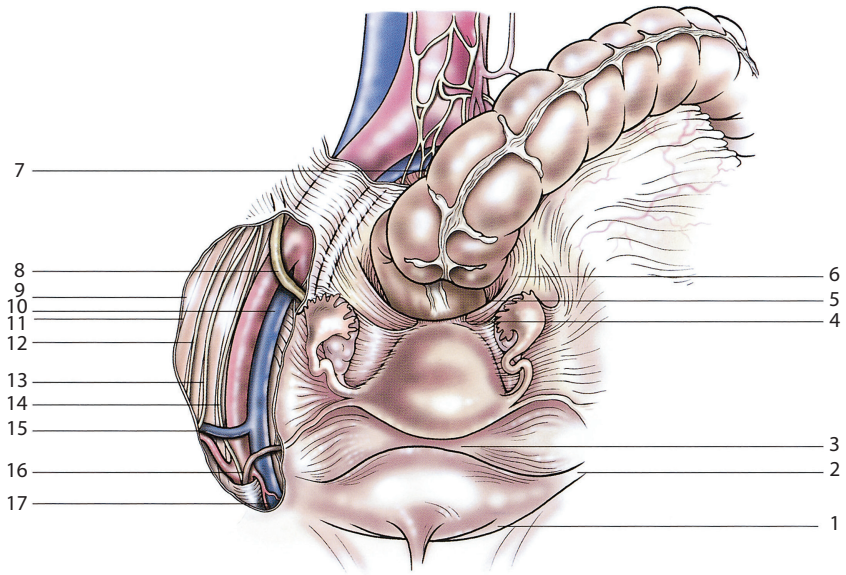

Figure 4.7 1: Paravesical fossa; 2: transverse vesical fold; 3: uterovesical pouch; 4: rectovesical pouch; 5: sacrogenital fold of uterosacral ligament; 6: pararectal fossa; 7: superior hypogastric plexus; 8: ureter; 9: psoas muscle; 10: internal iliac artery; 11: iliohypogastric nerve; 12: ilioinguinal nerve; 13: lateral femoral cutaneous nerve; 14: genitofemoral nerve; 15: circumflex iliac artery; 16: round ligament inserting into internal inguinal ring; 17: inferior epigastric artery.

The IMA descends retroperitoneally supplying the GI tract derived from the embryonic hindgut. It gives rise to the left colic supplying the descending colon, and the sigmoid artery that supplies the distal descending and sigmoid colons. The IMA terminates as the superior rectal artery.

Middle suprarenal arteries arise on the lateral aorta near the SMA. With the superior and inferior suprarenal arteries, they form approximately 60 branches that penetrate the capsule. Usually, four pairs of lumbar arteries arise from the posterior aorta. A fifth pair can originate from the median sacral artery. Ovarian arteries descend in the suspensory ligament of the ovary, and supply the ureter, ovary, and tubular ampulla. The marginal artery of the colon (of Drummond) runs in the mesentery along the border of the bowel as a part of the vascular arcade that connects the SMA and IMA. This is in contrast to Riolan's arch that when present is found near the mesenteric root and parallel to the middle colic artery. Riolan's arch connects the proximal middle colic artery with the left colic artery, and can be identified near the left colic flexure. The marginal artery and Riolan's arch may be enlarged providing significant blood flow to ischemic colonic segments. Critically, when Riolan's arch is not developed, or is narrowed, then ligation of the IMA can induce necrosis of the descending colon because arterial perfusion by the middle colic artery is interrupted.

Venous drainage from the abdominal esophagus, stomach, upper duodenum, jejunum, ileum, cecum, ascending colon, transverse colon, pancreas, and spleen is into the portal vein and the superior mesenteric vein. The inferior mesenteric vein joins the splenic vein before entering the portal vein, and receives blood from the descending and sigmoid colons, and rectal vein plexus. The middle rectal vein drains into the internal iliac vein, and the inferior rectal vein into the internal pudendal vein. The ovarian venous drainage is asymmetric. The right ovarian vein joins the IVC, whereas the left joins the left renal vein. The renal veins are direct tributaries to the IVC.

The internal iliac artery divides into anterior and posterior divisions (Figure 4.8). The branches that arise from the posterior division are the iliolumbar, sacral arteries, and the superior gluteal artery. The first branch to arise from the anterior division may be the iliolumbar artery. This aside, the umbilical artery (obliterated hypogastric vessel) is the first major branch, and it runs along the lateral pelvic wall then ascends toward the umbilicus giving rise to superior vesicular arteries and terminating as the medial umbilical ligament. This ligament raises a fold of peritoneum (medial umbilical fold), and identification

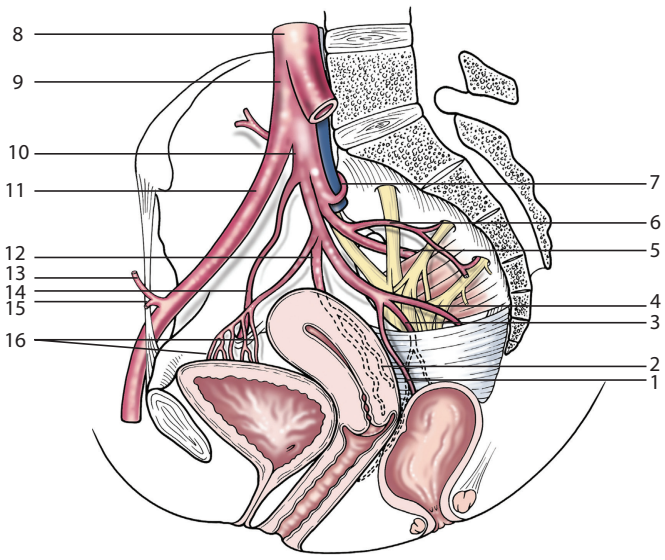

Figure 4.8 1: Middle rectal artery; 2: descending cervical of uterine artery; 3: internal pudendal artery; 4: inferior gluteal artery; 5: superior gluteal artery; 6: lateral sacral artery; 7: iliolumbar artery; 8: aorta; 9: common iliac artery; 10: internal iliac artery; 11: external iliac artery; 12: uterine artery; 13: circumflex iliac artery; 14: obturator artery; 15: inferior epigastric artery; 16: superior vesical arteries.

of the umbilical ligament is very helpful in the preparation of the parametrium during radical hysterectomy.

Near to where the umbilical artery is crossed by the ureter, the obturator artery courses along the obturator fascia. Before exiting the obturator foramen, it will give off a pubic branch that will anastomose with a "superior" pubic branch from the external iliac artery. The obturator artery may arise from the inferior epigastric artery.

The inferior vesicular artery is replaced by the vaginal artery, and arises from the uterine artery. The uterine artery may arise from the internal iliac artery, the anterior division, or from the umbilical artery, and its branches course in the broad and cardinal ligaments. Near to the cervix at the superior vagina, the ureter passes inferior to the uterine artery. The artery divides into an ascending uterine branch and a descending vaginal branch. The ascending branch will anastomose with the ovarian artery, and the vaginal artery with the vaginal branch of the uterine artery and superior vesicular arteries.

The internal pudendal artery will course inferolaterally and exit along the inferior border of the piriformis muscle in the greater sciatic foramen. Then, it will pass around the ischial spine (or sacrospinous ligament), re-entering the pelvis through the lesser sciatic foramen. It exits near the pudendal canal giving rise to the perineal artery and the dorsal artery of the clitoris.

Pelvic venous plexuses and tributaries to the internal iliac vein are important in the presence of metastases and are variable, but generally accompany the arteries that supply the same territory and viscera. One major difference is that there are no veins accompanying the umbilical arteries. Second, iliolumbar veins generally bypass the internal iliac vein, draining directly into the common iliac veins. Third, outside of pregnancy or pelvic congestion syndrome where the uterine veins enlarge, the superior gluteal vein is the largest tributary to the internal iliac vein. Finally, the lateral sacral veins provide a collateral route to the IVC or superior vena cava (SVC) via anastomotic connections with the internal vertebral venous plexus. This collateral pathway may allow ovarian cancer to spread to spinal or cranial sites. The pelvic vessels continue below the inguinal ligament into the femoral triangle (Figures 4.8 and 4.9).

Generally, lymphatic drainage parallels the course of venous blood supply. However, lymph node metastases can obstruct flow and lead to retrograde metastases, which appear to skip regional chains. For example, some endometrial and ovarian cancers can have isolated para-aortic lymph node spread through the lymph vessels of the infundibulopelvic ligament and show a retrograde lymphatic spread (Burghardt et al. 1991).

The groups of regional lymph nodes responsible for drainage of female pelvic viscera are shown in Figure 4.10. Lymph drainage from the rectum is via three pathways: from the *superior rectum* to pararectal and/or sacral nodes to the inferior mesenteric nodes, from the *middle rectum* to the internal iliac nodes, and from the *inferior rectum* directly into the sacral nodes. The inferior mesenteric nodes drain into the lumbar (caval or aortic) lymph nodes, and also collect lymph drainage from the sigmoid and descending colons. Critically, lymphatic drainage from the vagina is from four zones: the *upper vagina* drains into external and internal iliac nodes, to common iliac nodes and then lumbar

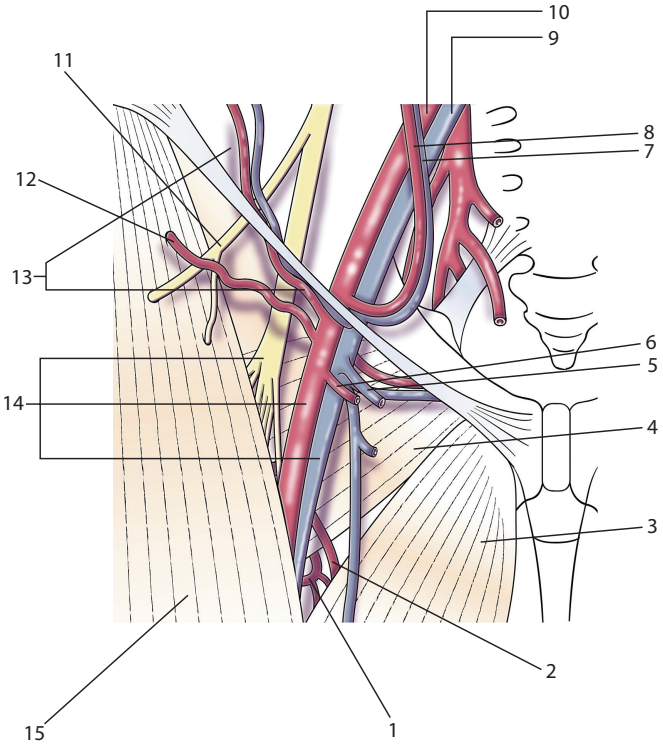

Figure 4.9 1: First perforating artery; 2: femoral pudendis artery; 3: adductor longus muscle; 4: pectineus muscle; 5: external pudendal vein; 6: external pudendal artery; 7: inferior epigastric vein; 8: inferior epigastric artery; 9: external iliac vein; 10: external iliac artery; 11: lateral femoral cutaneous nerve; 12: superficial circumflex iliac artery; 13: deep circumflex iliac artery + vein; 14: femoral nerve, artery + vein; 15: sartorius muscle.

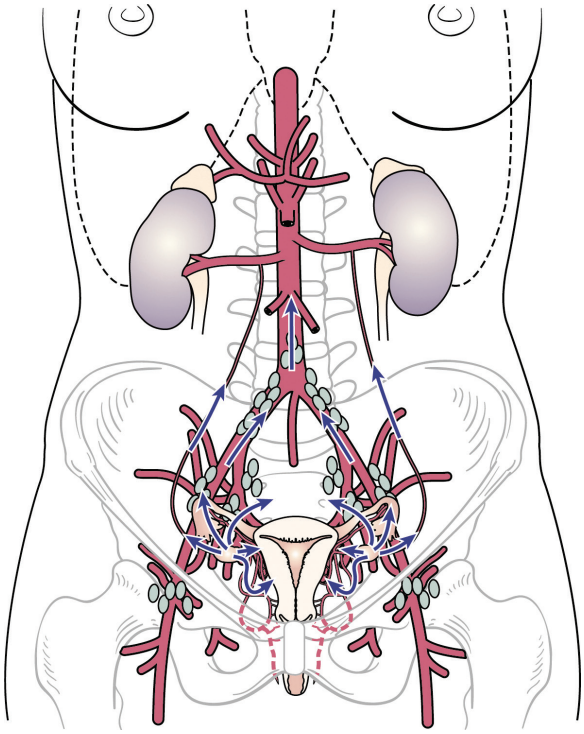

Figure 4.10 Lymphatic spread in ovarian cancer.

nodes; the *middle vagina* drains into internal iliac nodes; the *inferior vagina* drains into sacral and common iliac nodes; and the *vaginal introitus* drains into superficial inguinal nodes, that also receive drainage from the perineal integument, valve, prepuce of the clitoris, perianal integument, and anal canal. The deep inguinal nodes receive lymph flow from the glans of the clitoris.

NERVES

Few procedures require a complete dissection of nerves in gynecologic oncology, although this is advocated by some investigators. Larger nerves are sometimes used as landmarks during surgical dissections; for instance, the obturator nerve may serve as the near-to-inferior border of pelvic lymphadenectomy (obturator fossa) and the phrenic nerve as the posterior border of the scalene node dissection. Smaller nerves, such as the genital femoral nerve, may be transected during the removal of suspicious lymph nodes. To avoid injury, at the very beginning of a surgical procedure, the anatomy of the nervous system should be kept in mind when positioning the patient. For example, because laparoscopy requires the surgeon to be further cephalad than during the same procedure done by laparotomy, both arms should be tucked at the patient's side to avoid excessive superior traction on the brachial plexus. During vaginal procedures, resting an arm on the medial anterior thigh may compress the femoral nerve. This nerve may also be injured by an abdominal retractor placed too deeply over the psoas muscle. Further, the sympathetic trunk and hypogastric nerves are responsible for sympathetic innervation of the pelvis. Injury to the sympathetic trunk can cause ipsilateral vasodilatation postoperatively (hyperthermia in the lower extremity). The splanchnic nerves carry parasympathetic innervation of the pelvis and control micturition and defecation. The nerves of the pelvis and abdomen show a wide spectrum of variation in topographic anatomy. Nevertheless, the general course and function of many nerves must be known in order to avoid their injury and minimize surgical complications (Figures 4.8 and 4.9).

Components of both the somatic and autonomic (visceral) nervous systems are associated with the posterior abdominal wall. These include the subcostal nerves (anterior rami of T_{12}), the lumbar spinal nerves (L_1–L_5), and the lumbar plexus of nerves (anterior rami of L_1–L_4).

The anterior and posterior rami of the lumbar spinal nerves contain sensory and motor fibers. L_1 and L_2 (occasionally L_3) give rise to white rami communicantes conveying presynaptic sympathetic fibers to the lumbar sympathetic trunks. Postsynaptic fibers leave the trunks within gray rami communicantes and enter spinal nerves. The medial aspect of the lumbar sympathetic trunk also gives rise to lumbar splanchnic nerves carrying presynaptic fibers responsible for sympathetic innervation of the pelvic viscera.

The three largest branches of the lumbar plexus are consistent and can be used as surgical landmarks: the femoral nerve (L_2–L_4), the obturator nerve (L_2–L_4), and the lumbosacral trunk (L_4–L_5). The femoral nerve originates at the lateral border of psoas major, and courses deep to the inguinal ligament into the anterior compartment of the thigh. The obturator nerve originates at the medial border of the psoas major and enters the lesser pelvis, then passes through the obturator foramen and into the adductor. Finally, the lumbosacral trunk passes over the ala of the sacrum and into the pelvis, participating in the formation of the lumbosacral plexus with the anterior rami of the S_1–S_4.

Lesser nerves of the lumbar plexus are the ilioinguinal and iliohypogastric nerves (L_1), the genitofemoral nerve (L_1–L_2), the lateral femoral cutaneous nerve (L_2–L_3), and the accessory obturator nerve (L_3–L_4; present about 10% of the time).

The sacral plexus (S_1–S_5) also gives rise to nerves coursing through the pelvis that can be affected by cancers and surgical procedures. The main nerves are the sciatic (L_4–S_3), pudendal (S_3–S_4), and the superior (L_4–S_1) and inferior (L_5–S_2) gluteal nerves. Lesser nerves are the nerves to quadratus femoris (L_4–S_1), pirformis (S_1–S_2) and levator ani and coccygeus (S_3–S_4); a posterior cutaneous nerve to the buttocks and superior posteromedial thigh (S_2–S_3), and the nerve to obturator internus (L_5–S_2). Pelvic splanchnic (S_2–S_4) nerves supply pelvic viscera via the inferior hypogastric and pelvic plexuses. The sciatic nerve is located laterally to the internal iliac artery where anterior rami converge on the surface of the piriformis. Usually, the sciatic nerve leaves the pelvis along the inferior border of piriformis. However, branches may pass above and/or below (or through) the piriformis, and then merge to form the sciatic nerve. The sciatic nerve can be compromised by inadequate positioning during surgery and by lateral pelvic wall metastases.

The pudendal nerve is the main nerve of the perineum and the main sensory nerve of the external genitalia. Throughout its course it is accompanied by the pudendal artery. It exits the pelvis through the greater sciatic foramen between piriformis and coccygeus, then hooks around the ischial spine and the sacrospinous ligament, re-entering the perineum through the lesser sciatic foramen.

The inferior one-quarter of the vagina has somatic innervation from the deep perineal nerve that conveys sympathetic and visceral fibers. In contrast, the superior three-quarters of the vagina are visceral with respect to innervation, and derived from the uterovaginal plexus, which comprises sympathetic, parasympathetic, and visceral afferent fibers. Surgically important, the uterine plexus courses a route paired with the uterine artery along the lateral wall of the uterus within the broad ligament and at the junction of the base of the broad ligament and the superior part of the transverse cervical ligament. Between the layers of the broad ligament, it communicates with the ovarian plexus.

The ovaries and fallopian tubes are innervated in part from the ovarian plexus and the uterine plexus. The ovarian plexus arises from the renal plexus and descends through the suspensory ligament of the ovary. Because the ovaries and tubes are intraperitoneal and superior to the pelvic pain line, afferent pain fibers ascend to cell bodies located in the T_{11}–L_2 spinal ganglia. Afferent reflex fibers course in a retrograde fashion along parasympathetic fibers through the uterine portion of the uterovaginal plexus, and pelvic splanchnic nerves to cell bodies in the $S_{2–4}$ spinal ganglia. Thus, pain secondary to cancer or postoperatively can be controlled in the pelvis by regional anesthetic blockade of the dorsal nerve roots of $T_{10–12}$ to the uterus tubes and ovary, and $S_{2–4}$ to the remaining genital structures.

MUSCLES

The muscles of the abdominal cavity are sometimes involved in either the disease process or surgical procedures in gynecologic oncology. Many of the cutaneous landmarks used in planning gynecologic surgery comprise borders of superficial muscles (Figures 4.11 and 4.12). Muscles are the primary focus of reconstructive procedures (discussed in this book), and can be used as flaps to cover gaping defects created at the time of radical or ultraradical surgery (Possover et al. 1998). One favorite technique involves using the gracilis muscle to close a pelvic defect and create an adequate vagina. These techniques include grafting procedures, realignment of standard incisions, the use of vascular pedicle flaps, and organ substitution. However, most often muscles are structures to be retracted or transected. Nevertheless, they are helpful in identifying related anatomical structures, and therefore surgeons should be familiar with them.

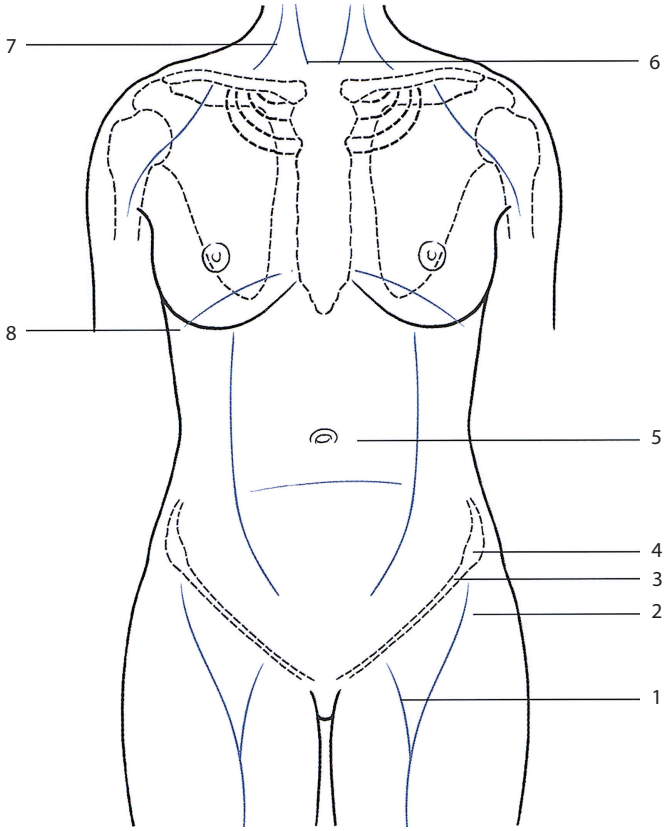

Figure 4.11 1: Adductor longus groove; 2: sartorius muscle groove; 3: inguinal ligament; 4: anterior superior iliac spine; 5: level of L4/L5 vertebral bodies; 6: sternal head; 7: clavicular head and sternocleidomastoid muscle (6 and 7); 8: seventh rib.

One useful relationship is that between the rectus abdominis muscle and the epigastric vessels. When performing laparoscopy (Soper et al. 1989), it is best to place the lateral trocars completely laterally to these muscles to prevent injury of epigastric vessels. This procedure facilitates surgery also by keeping the surgical instruments as far apart as possible. It is this relationship with the epigastrics that makes the rectus abdominis muscle an ideal vascular pedicle flap for reconstructive procedures. The gracilis muscle is also a suitable pedicle flap, but because it is more variable, the rectus is preferred for perineal reconstruction.

Muscles also serve as borders for lymph node dissections. For example, the middle of the psoas muscle marks the lateral extent of the pelvic lymphadenectomy, and the obturator internus muscle does the same for the obturator space lymphadenectomy. The muscles of the proximal lower extremity are similarly used as landmarks in inguinofemoral dissection. During a scalene node biopsy, dissection is carried to the surface of the anterior scalene muscle between the sternocleidomastoid and the trapezius muscles (Figures 4.11 and 4.12).

BONES AND CUTANEOUS LANDMARKS

Experienced surgical oncologists recognize the value of boney and cutaneous landmarks in planning successful gynecologic oncology procedures (Figures 4.11 and 4.12). For example, gaining central venous access always begins with determination of the location of the distal third of the clavicle or the heads of the sternocleidomastoid muscle. Vascular access may also be achieved through a cephalic vein cut-down. This vein is identified by the cutaneous border of the deltoid and pectoralis major muscles (deltoid-pectoral triangle).

These same landmarks are also useful in initiating a scalene node biopsy. An inguinal node dissection may be performed through different incisions provided that the operator recognizes the relationship of the nodes to the inguinal ligament. Tube thoracotomy and thoracocentesis require recognition of the location of the inferior scapula at the seventh and eighth rib. Finally, although the patient's soft tissue dimensions are important, the truly limiting factor for most is the bony confine of the operative field. For instance, a large patient may have a wide and shallow pelvis, making the patient an acceptable candidate for a radical hysterectomy. This may be determined before the incision by noting the distance between the anterior iliac crests in relation to the distance from the crest to the ischial tubercle. Similarly, for vaginal procedures, emphasis should be placed on the distance between the ischial tubercles and the angle of the pubic arch. The best way to assess the patient preoperatively is by recognizing the significance of the bony and cutaneous landmarks of the operative field.

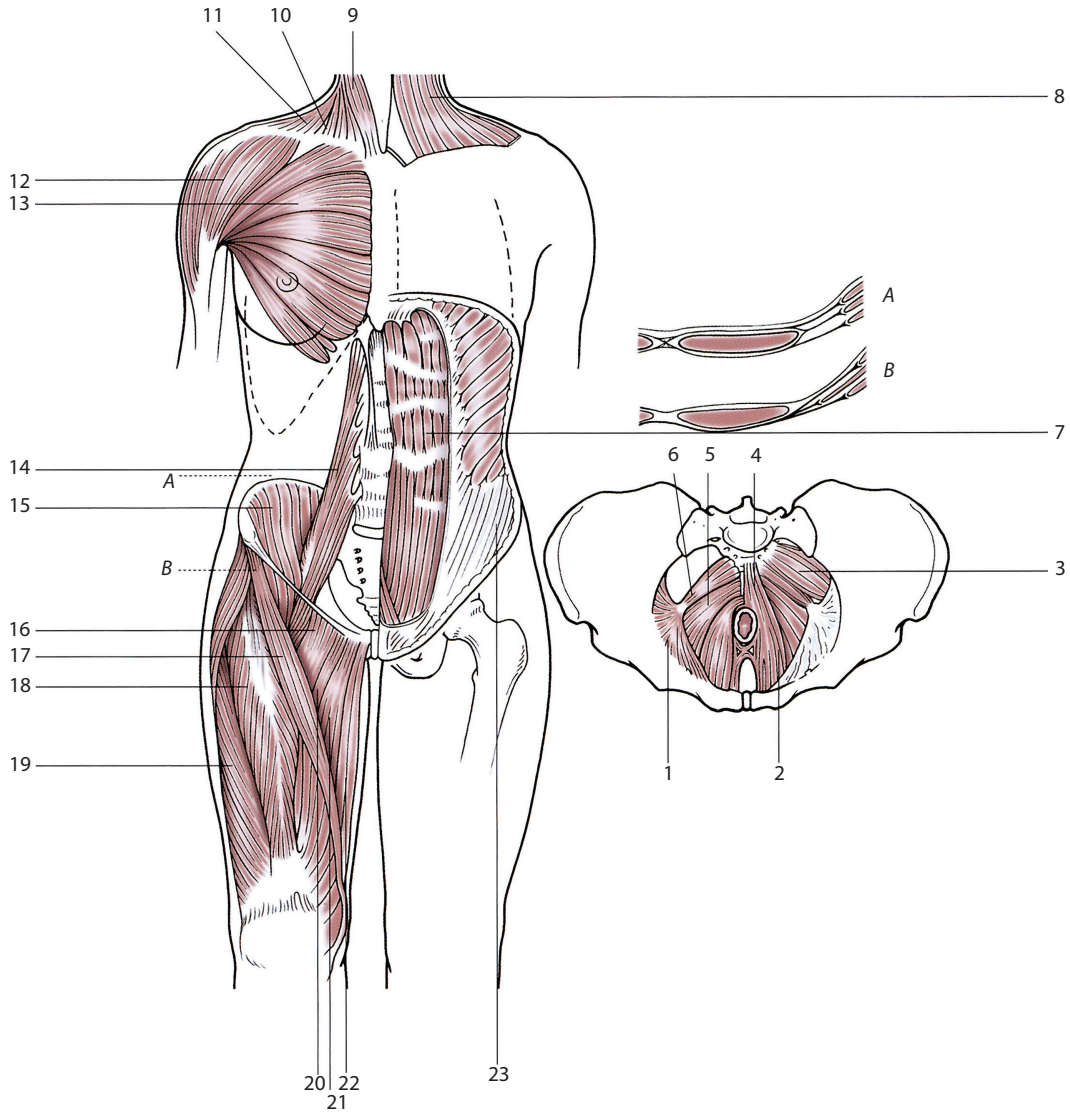

Figure 4.12 A: Transverse level, umbilicus; B: transverse level, arcuate line; 1: obturator internus; 2: puborectalis; 3: piriformis; 4: pubococcygeal muscle; 5: iliococcygeal muscle; 6: coccygeus; 7: rectus abdominis; 8: platysmus; 9: sternocleidomastoid muscle; 10: anterior scalene muscle; 11: trapezius; 12: deltoid; 13: pectoralis major; 14: psoas; 15: iliacus; 16: pectineus; 17: sartorius; 18: rectus femoris; 19: adductor brevis; 20: adductor longus; 21: vastus lateralis; 22: gracilis; 23: anterior superior iliac spine.

REFERENCES

Barlin J, Ueda S, Bristow RE. 2009. Cytoreductive surgery for advanced and recurrent endometrial cancer: A review of the literature. *Women's Health (Lond)* **5**(4):403–11.

Bristow RE, Tomacruz RS, Armstrong DK, et al. 2002. Survival effect of maximal cytoreductive surgery for advanced ovarian carcinoma during the platinum era: A meta-analysis. *J Clin Oncol* **20**(5):1248–59.

Burghardt E, Girardi F, Lahoussen M, et al. 1991. Patterns of pelvic and paraaortic lymph node involvement in ovarian cancer. *Gynecol Oncol* **40**(2):103–6.

Jemal A, Siegel R, Ward E, et al. 2008. Cancer Statistics, 2008. *CA Cancer J Clin* **58**(2):71–86.

Le O. 2013. Patterns of peritoneal spread of tumor in the abdomen and pelvis. *World J Radiol* **28**(3):106–12.

Lichtenegger W, Sehouli J, Buchmann E, et al. 1998. Operative results after primary and secondary debulking operations in advanced ovarian cancer (AOC). *J Obstet Gynaecol Res* **24**(6):447–51.

Moore KL, Dalley AF, Agur AMR. 2014. *Clinically Oriented Anatomy*. 7th ed. Lippincott Williams & Wilkins.

Nguyen HN, Averette HE, Hoskins W, et al. 1993. National Survey of Ovarian Carcinoma: V. The impact of physician's specialty on patient's survival. *Cancer* **73**:3663–70.

Possover M, Krause N, Drahonovsky J. 1998. Left-sided suprarenal retrocrural para-aortic lymphadenectomy in advanced cervical cancer by laparoscopy. *Gynecol Oncol* **71**(2):219–22.

Soper JT, Larson D, Hunter VJ. 1989. Short gracilis myocutaneous flaps for vulvovaginal reconstruction after radical pelvic surgery. *Obstet Gynecol* **74**:823.

5 Cross-sectional and molecular imaging

Syed Babar Ajaz, Ruth Williamson, and Tara Barwick

INTRODUCTION

Pelvic imaging has seen a revolution in the recent times with increasing availability and utilization at almost all levels from initial assessment of tumors to its role in management and disease response evaluation. Various classification systems are in use for staging gynecological malignancies but the International Federation of Gynecology and Obstetrics (FIGO) is currently widely used in this regard. Although FIGO does not take into account the role of cross-sectional imaging for staging of gynecological malignancies, computed tomography (CT) and magnetic resonance imaging (MRI) have become the mainstay for assessment and staging in developed countries; however FIGO manual and surgicopathological staging is vital for full international comparison of incidence and results of treatment. The role of imaging is valuable in the initial assessment of indeterminate adnexal masses and endometrial assessment but not in diagnosing cervical and endometrial cancers. These tumors are diagnosed by clinical examination supplemented by examination under anesthesia (EUA), biopsy, and hysteroscopy. The gold standard for staging of endometrial cancer remains histopathological. CT and MRI also have a vital role in radiotherapy treatment planning. Following treatment, cross-sectional imaging plays an important role in assessing response to treatment and also for evaluating for any recurrence. 2-(F-18) Fluor-2-deoxy-D-glucose positron emission tomography (18 FGD PET) is also now part of the mainstay of imaging when it comes to staging locally advanced cervical cancer, disease recurrence, and prior to pelvic exenteration. It also has an increasing role in radiotherapy planning and response assessment.

CARCINOMA OF THE ENDOMETRIUM

Endometrial cancer is one of the commonest cancers of the female genital tract with estimates of almost 54,870 new cases in 2015 in the United States and 10,170 deaths, as per the figures released by the American Cancer Society (Anon 2015b). This is a disease of elderly females, with 95% of endometrial cancers occurring in women aged 40 and above. The cancer is also related to unopposed estrogen exposure such as in early menarche, late menopause, infertility, exposure to tamoxifen (an anti-breast cancer drug), and hormone replacement therapy. Obesity markedly increases the risk of developing endometrial cancer. The disease predominantly affects postmenopausal women who present with vaginal bleeding. Because of this, most of the women are diagnosed early, with 75% presenting with disease confined to the endometrium. The majority of endometrial tumors arise from the glandular epithelium and hence are adenocarcinomas of the endometrioid type (75%). The other less common type of tumors are serous papillary, adenosquamous, and the clear cell type, all of which have a worse prognosis. Sarcomas, including the mixed malignant Mullerian tumors (MMMT) and leiomyosarcomas, are also relatively rare. The incidence of uterine body sarcomas is 8%.

The diagnosis of the endometrial cancers is by hysteroscopy and curettage with histological confirmation. Carcinoma of the endometrium is staged using either the tumor, node, metastasis (TNM) classification or the FIGO staging system, which is surgicopathological (Table 5.1).

It is important to add here that the FIGO staging system has been revised, and the new staging system has been changed for Stage I disease to Stage IA where the endometrial tumor either does not invade or invades less than half of the depth of the myometrium (Pecorelli 2009). Previously, Stage IA was disease confined to the endometrium with no myometrial invasion. Stage IB now replaces the previous IC disease in which the tumor invades equal to or more than half of the depth of the myometrium. Similarly, cervical glandular epithelium involvement now is staged as Stage I instead of Stage IIA as per the old staging system.

Role of Imaging

Imaging has a role in early detection of abnormality of the endometrium, which may warrant further assessment by hysteroscopy and dilatation and curettage. This may be in the form of abnormal thickening of the endometrial lining on ultrasound, which would then be assessed by a hysteroscopy, and once the diagnosis of endometrial cancer is made on biopsy, imaging evaluation by MRI would be required. Imaging would also be able to assess for advanced disease, which might affect the choice of treatment or the surgical approach. If it is demonstrated on imaging that the disease is advanced, with peritoneal and nodal disease, then adjuvant therapy may be indicated. Some patients may require lymph node sampling or lymphadenectomy, depending on the protocol. These are patients with high-grade tumor, lymphovascular spread, cervical and deep myometrial involvement, and adenosquamous histology. Of these factors, imaging is able to assess the depth of myometrial invasion, nodal enlargement, and also invasion of the cervix.

Ultrasound

Ultrasound is usually the first imaging modality of choice for assessment of the endometrium in patients who present with vaginal bleeding. Transvaginal ultrasound is more accurate and allows precise measurement of the endometrial thickening compared to the transabdominal ultrasound. In addition, in obese patients and in patients with retroverted uterus, it may be difficult to assess the endometrial lining on a transabdominal ultrasound.

Normal endometrial thickness and appearances vary not only with the age of the patient but also with the phase of the

Table 5.1 Endometrial (Corpus Uteri) Cancer (FIGO Staging)

Stage	Description
I	**Confined to corpus uteri**
Ia	Confined to endometrium or invasion < half of the myometrium
Ib	Invasion ≥ half of the myometrium
II	**Tumor invades cervical stroma, but does not extend beyond uterus**
III	**Local or regional spread**
IIIa	Involvement of serosa of uterus or adnexae
IIIb	Vaginal and/or parametrial spread
IIIc	Metastases to pelvic and/or para-aortic lymph nodes
	IIIc1 – Positive pelvic lymph nodes
	IIIc2 – Positive para-aortic lymph nodes
IV	**Bladder, bowel, distant**
IVa	Invasion of bladder or bowel mucosa
IVb	Distant metastases, including intra-abdominal or inguinal lymph nodes

Source: Reproduced from Amant F, Mirza MR, Koskas M, Creutzberg CL. 2015. *Int J Gynecol Obstet* 131 S96–104. With Permission.

menstrual cycle. In the early part of the menstrual cycle, the endometrium is visualized as a thin reflective line (Figure 5.1). During the proliferative phase, the endometrium is thickened and is seen as a triple line (Figure 5.2), and lastly, during the secretory phase, the endometrial lining is at its maximum thickness, with homogenously increased reflectivity and through transmission (Figure 5.3).

In postmenopausal women, the endometrium lining is thin and generally measures less than 4 mm unless the patient is on HRT or tamoxifen for breast cancer. If the patient is on sequential HRT and is asymptomatic, then the endometrial thickness can be up to 8 mm. Endometrial thickness between 5 and 8 mm will require a biopsy if the patient is symptomatic and presents with vaginal bleeding. Thickness greater than 8 mm would require a follow-up ultrasound in asymptomatic patients and a biopsy in symptomatic ones (Levine et al. 1995), although some authors would advise a biopsy in all women with a thickness greater than 5 mm and in all woman with persistent vaginal bleeding regardless of the thickness. Not to biopsy would be indefensible in a postmenopausal woman.

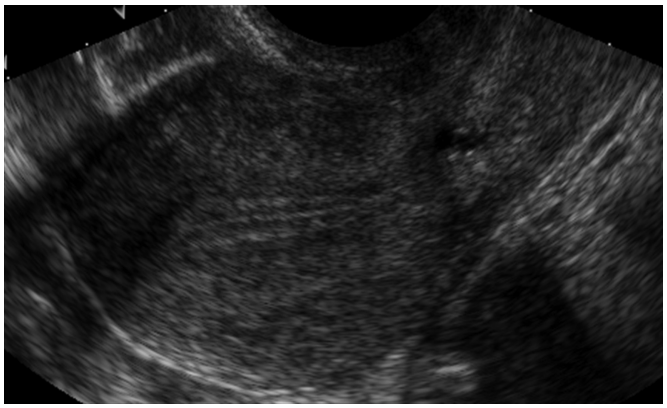

Figure 5.1 Transvaginal ultrasound during the early phase of the menstrual cycle shows a thin reflective endometrial lining.

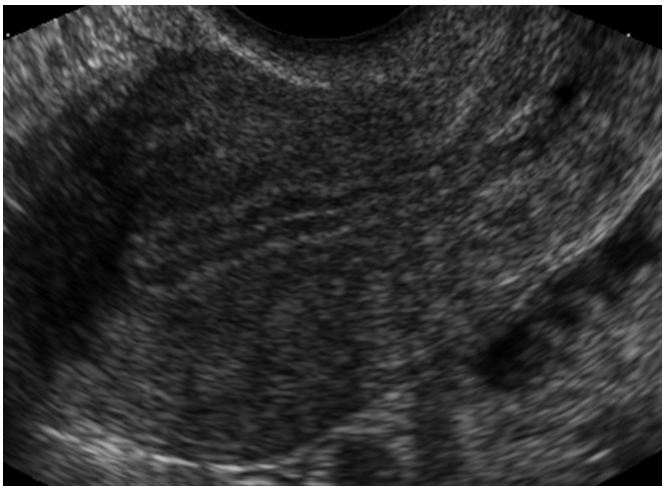

Figure 5.2 Transvaginal ultrasound during the proliferative phase of the menstrual cycle shows a triple line appearance of the endometrial echoes.



Figure 5.3 Transvaginal ultrasound during the secretory phase of the menstrual cycle shows thickened hyperreflective endometrial echoes.

Endometrial cancer is characterized by increased endometrial thickness often associated with heterogeneous reflectivity and irregular and ill-defined margins (Figure 5.4). However, there remains an overlap between endometrial cancer, polyps, and hyperplasia. Transvaginal ultrasound appears to have a sensitivity of about 94.3% for detecting endometrial cancer but has a low specificity of 52.4%. A recent meta-analysis has suggested sensitivity of 68% to 100% and specificity of 71% to 90% for assessing the depth of myometrial invasion (Epstein and Blomqvist 2014).

Computed Tomography

CT has a major role in assessing for distant spread when it comes to staging endometrial carcinoma. MRI, however, best stages the tumor locally. The staging investigation generally includes a contrast-enhanced scan of the chest, abdomen, and pelvis. Although contrast-enhanced CT can detect endometrial thickness and the primary tumor as a hypodense lesion, it is difficult to assess for the depth of myometrial invasion on

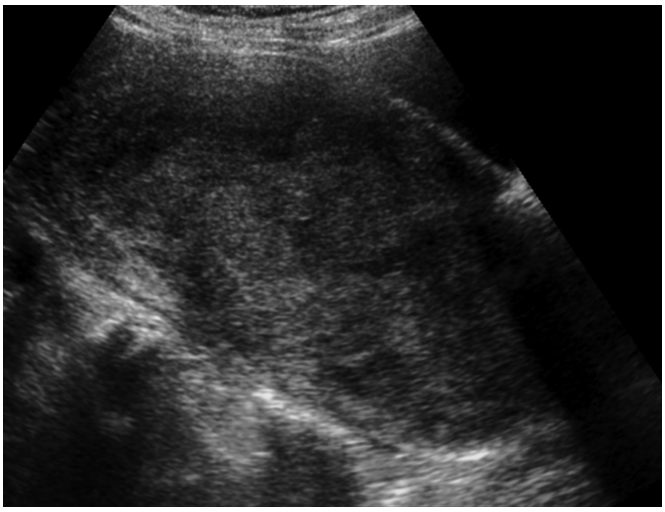

Figure 5.4 Transabdominal ultrasound shows a large uterus with complete replacement of the normal endometrial lining by a heterogeneous mass which shows ill-defined margins. Histology confirmed this to be endometrioid adenocarcinoma of the uterus.

CT (Figure 5.5). The depth of myometrial infiltration can be assessed, as can the cervical involvement, but generally CT is considered inferior to MRI in this regard. In locally advanced disease, CT may show the involvement of parametrial structures and pelvic sidewalls. In addition, CT is useful in detecting enlarged pelvic as well as para-aortic lymph nodes, peritoneal and omental disease in the abdomen, and distant metastases in the liver, lung, bones, and brain. CT can detect enlarged lymph nodes generally based on the size criterion, and this may help plan management preoperatively if the surgeons are contemplating doing lymph node dissection. Alternatively, CT may also provide useful information regarding the nodal map for radiotherapy planning.

Contrast-enhanced CT has an accuracy of about 58% to 76% for staging of endometrial carcinoma (Kim et al. 1995). A more recent study evaluating the depth of myometrial invasion and cervical extension using multidetector CT has shown a greater diagnostic accuracy of 95% and 81%, respectively (Tsili et al. 2008). However, local staging is best performed by MRI rather than CT.



Figure 5.5 Contrast-enhanced axial CT scan shows an enlarged uterus with a large mass filling the endometrial cavity. There is irregular interface between the mass and the left myometrium suggesting inner myometrial invasion.

Magnetic Resonance Imaging

MRI is the modality of choice for local staging of the endometrial cancer once the diagnosis has been confirmed on histology. MRI is not appropriate for diagnosing endometrial cancer, as there is an overlap between the MRI imaging appearances of endometrial cancer, hyperplasia, endometritis, and polyps. Hence the role of MRI is in local staging of the disease after its diagnosis.

MRI exquisitely assesses normal uterine anatomy. The uterus is best assessed on the T2-weighted scans for its zonal anatomy. A normal uterus demonstrated three separate zones on the T2-weighted sequence (Figure 5.6). The endometrial cavity is seen as a bright linear hyperintensity because of the presence of endometrial glands and their secretions. The thickness of the endometrial cavity can vary with the phase of the menstrual cycle. It is thickest in the mid-secretory phase and thinnest after menstruation. This is surrounded by the junctional zone, which is part of the myometrium and appears as a low-signal intensity rim bordering the endometrium. This is low signal because of the low water content and the tight arrangement of the cells with paucity of the extracellular matrix. This is surrounded by the intermediate signal intensity outer myometrium, which can also vary in its signal intensity, and reaching maximum intensity in the mid-secretory phase. The myometrial appearances can also vary with use of oral contraceptives and can be high signal on the T2-weighted sequences. On post-contrast dynamic scans the endometrial cavity and the outer myometrium show intense enhancement while the low signal intensity junctional zone remains as it is. However, there is a sub-endometrial zone, which enhances earlier than the rest of the myometrium and corresponds to the junctional zone.

The standard protocol varies from department to department but generally includes a T1-weighted scan in the axial or coronal planes, sagittal and axial T2-weighted sequences through the pelvis, axial-oblique T2-weighted small field of view perpendicular to the long axis of the endometrial cavity, a coronal or axial short tau inversion sequence (STIR), and finally a T1-weighted fat-saturated dynamic contrast enhanced scan in the sagittal or axial oblique plane. In addition, functional MRI techniques using diffusion-weighted imaging (DWI) sequences is now part of the routine imaging. DWI provides information regarding



Figure 5.6 Sagittal T2-weighted MRI scan demonstrates the normal zonal anatomy of uterus. The endometrial cavity is hyperintense on the T2-weighted sequences. This is surrounded by a hypointense thin layer of junctional zone and the intermediate signal intensity outer myometrium.

the random (Brownian) motion of water molecules in tissues, which is inversely proportional to cellular density and cell membrane integrity (Padhani et al. 2009). Usually several diffusion weightings (*b*-values) are acquired and the quantitative measure apparent diffusion coefficient (ADC) is derived from these and displayed as an ADC map (Sala et al. 2010). Restricted diffusion in hypercellular tumors results in high signal intensity on the high *b*-value diffusion-weighted images with a corresponding low value on the ADC map.

On the T2-weighted sequences, the tumor is seen as a mass or thickening of the endometrial cavity, which is of intermediate signal abnormality in comparison to the high signal of the endometrial cavity (Figure 5.7). This demonstrates a good contrast between the tumor and the endometrial cavity as well as between the intermediate signal intensity tumor and the low signal intensity junctional zone. This spread into the surrounding myometrium is best assessed on the axial oblique small field of view T2-weighted sequences. The tumor also appears heterogeneous and can have ill-defined margins and demonstrate less or no enhancement compared to the rest of the endometrium and the myometrium on the post-contrast-enhanced dynamic scans. The depth of the myometrial infiltration is closely associated with lymph node involvement as well as patient survival. The FIGO staging of the endometrium has recently been revised as described above, with Stage IA being involvement of the inner half of the myometrium and Stage IB with extension into the outer myometrium (Figure 5.8). The tumor can invade the cervical lumen as well as the surrounding stroma and the parametrial tissues (Figure 5.9). This is also best depicted on the sagittal and axial oblique T2-weighted small field of view sequences. The endocervical lumen is bright because of the secretions of the endocervical glands, while the surrounding cervical stroma is of low signal intensity. Hence there is a good contrast between the tumor and the cervix. MRI is also excellent in demonstrating involvement of the adjacent structures like the bladder and the rectum (Figure 5.10). DWI has been shown to differentiate normal from disease endometrium especially using high *b*-values (Fujii et al. 2008). Tumors are generally higher signal intensity than the surrounding myometrium on the DWI sequences and are of low signal intensity on the ADC map (Figure 5.11). Uterine sarcomas including MMMT and leiomyosarcoma can have a similar appearance to endometrial cancer and may be

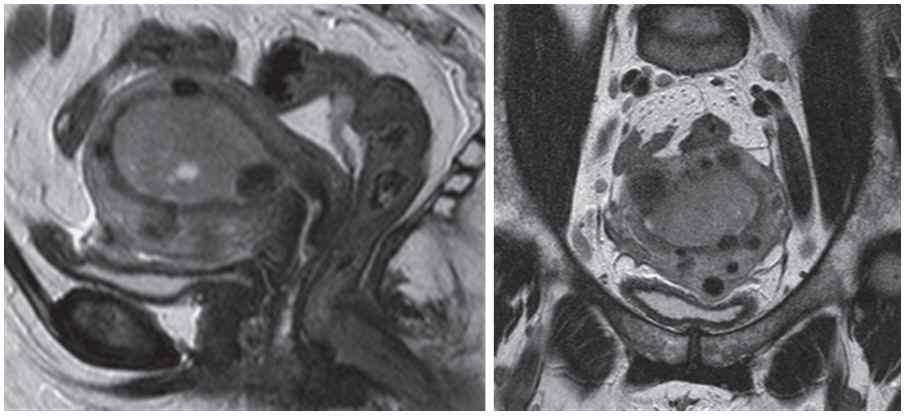

(**A**) (**B**)

Figure 5.7 (**A, B**) Sagittal and axial-oblique T2-weighted MRI scans show complete replacement of the normal endometrial cavity by a large intermediate signal intensity mass in keeping with an endometrial carcinoma. The tumor is confined to the endometrial cavity with no invasion into the adjacent myometrium on both planes, in keeping with FIGO Stage 1A. Incidental small low signal intensity fibroids are noted.

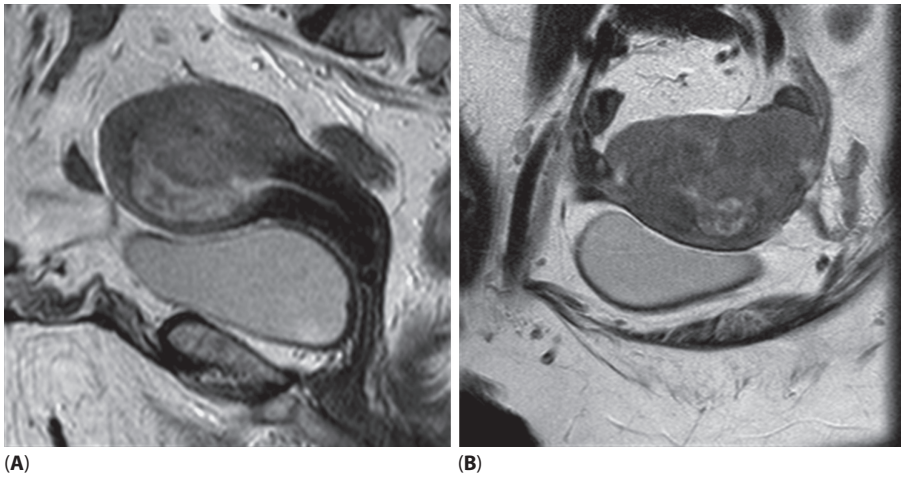

(**A**) (**B**)

Figure 5.8 (**A, B**) Sagittal and axial-oblique T2-weighted scans show invasion of the posterior half of the myometrium by an intermediate signal intensity endometrial carcinoma. The tumor is seen to invade into the outer half of the myometrium in keeping with FIGO Stage 1B.

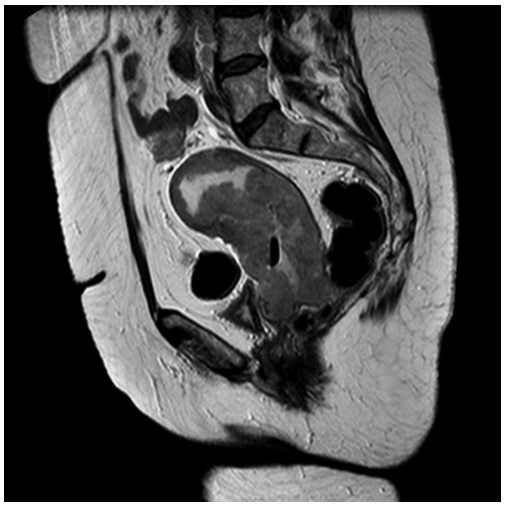

Figure 5.9 Sagittal T2-weighted MRI shows a large endometrial tumor with invasion both of the endocervical canal as well as the surrounding cervical stroma. The low signal intensity centrally with the cervix represents gas secondary to necrotic breakdown of the tumor.

indistinguishable on MRI. However, sometimes these tumors are seen as a large intermediate- to high-signal intensity mass completely replacing the normal uterine architecture (Figure 5.12).

The overall sensitivity and staging accuracy of MRI in assessing for myometrial invasion is 87% and 90% (Ortashi et al. 2008). The pooled sensitivity and specificity of dynamic post-contrast-enhanced MRI scan is 81% and 72% compared to the T2-weighted sequences, which show a pooled sensitivity of 87% and specificity of 58% (Wu et al. 2013). The staging may also be affected by atrophy of the myometrium and other factors like the presence of fibroids and adenomyosis, which may distort the anatomy. MRI accuracy reduces slightly when assessing for the invasion of the outer myometrium and the cervix. In a recent study, MRI differentiation of deep myometrial invasion from superficial disease agreed with pathological findings in 77% of cases, with a sensitivity of 83%, specificity of 72%, and a diagnostic accuracy of 77%. In regard to cervical invasion, MRI had a sensitivity, specificity, and diagnostic accuracy of 42%, 92%, 81%, respectively. In assessing lymph node invasion, MRI presented a sensitivity of just 17%, a specificity of 99%, and a diagnostic accuracy of 89% (Cabrita et al. 2008).

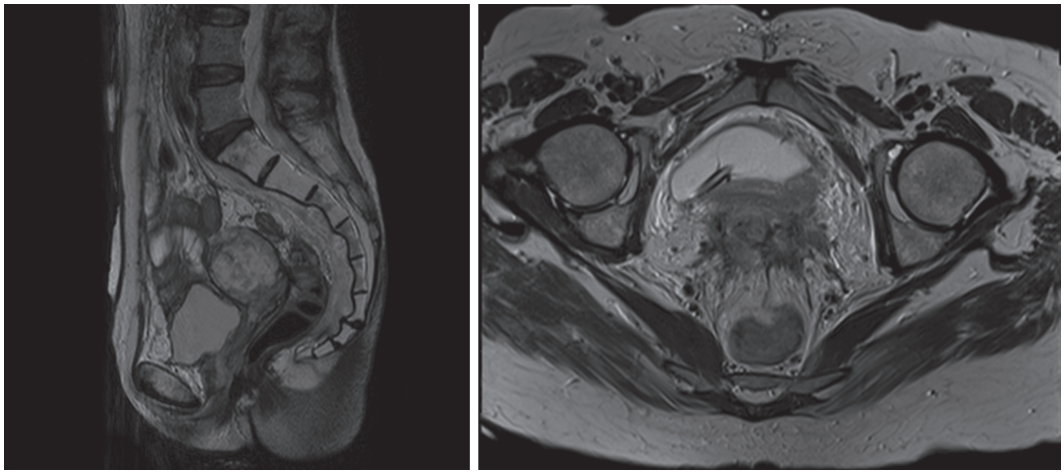

(**A**) (**B**)

Figure 5.10 Sagittal and axial T2-weighted sequences show a large endometrial carcinoma invading the bladder and the rectum on the right side in keeping with stage 4 disease.

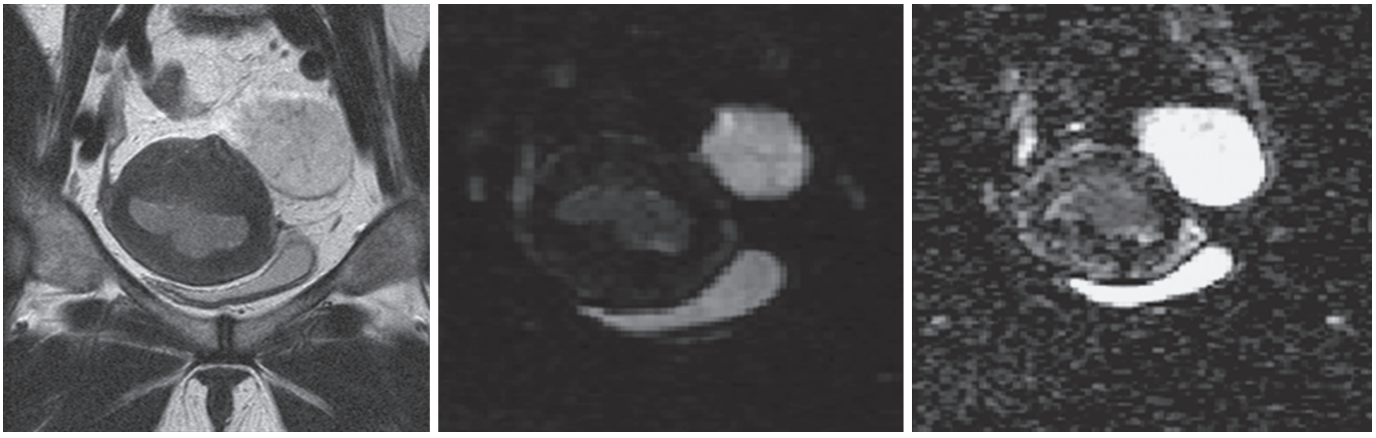

(**A**) (**B**) (**C**)

Figure 5.11 (**A–C**) A large endometrial adenocarcinoma with myometrial invasion on T2-weighted, Diffusion weighted imaging and the corresponding ADC map.

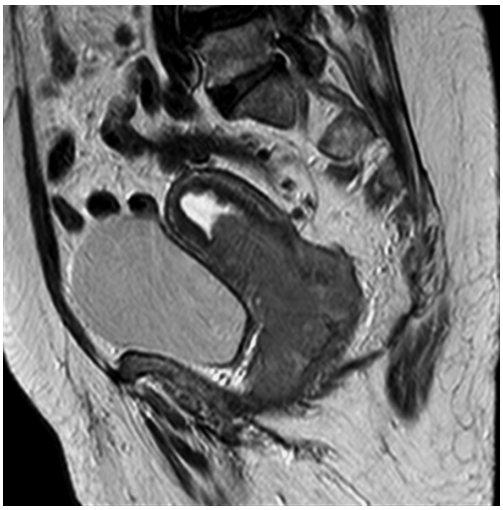

Figure 5.12 Sagittal T2-weighted MRI scan in a 56-year-old patient with mixed malignant Mullerian tumor presenting as a large intermediate signal intensity mass completely involving the lower uterine segment extending into the cervix and vagina.

DWI is increasingly being used to assess the depth of myometrial infiltration. Some recent studies show higher staging accuracy for DWI compared to dynamic post-contrast-enhanced scans. The reported sensitivity, specificity, and positive and negative predictive value for DWI is 84.6%, 70.6%, 52.4%, and 92.3%, compared to 69.2%, 61.8%, 40.9%, and 84% for dynamic post-contrast-enhanced scans, respectively (Rechichi et al. 2010).

Positron Emission Tomography-CT (PET-CT)

PET involves the administration of small amounts of short-lived radioactive tracers which target various biological pathways. PET using the tracer F-18 2-Fluoro-2-deoxy-D-glucose (FDG), a glucose analogue, is established for a variety of oncological applications. The distribution of tracer can be assessed visually or can be analyzed semi-quantitatively using standardized uptake values (SUV) which provide an estimation of activity within a defined region of interest (ROI) normalized to the patient's body weight and administered dose.

MRI is superior to PET-CT in the assessment of the "T" stage of tumors. However, PET is useful in assessing nodal disease and distant metastases.

The presence of lymph nodes in patients with endometrial cancer has important implications in terms of prognosis, patient survival, and surgical management. CT and MRI use size criteria to detect lymph node metastases. However, it is well known that the sensitivity and specificity of both techniques in detecting nodal metastases is low, as enlarged nodes may be reactive and small nodes may harbor metastases (Kakhki et al. 2013).

FDG PET-CT is highly specific for detecting nodal metastases but is less sensitive. A recent meta-analysis of FDG PET-CT in endometrial cancer reported pooled sensitivity and specificity of 72.3% and 92.9%, respectively for nodal staging and 95.7% and 95.4% for distant metastases (Kakhki et al. 2013). FDG PET-CT is not used in routine staging, but high specificity and positive predictive value mean it may be useful in selected cases with equivocal retroperitoneal nodes or distant disease on conventional workup, or in poor surgical candidates.

However, FDG PET-CT is utilized in assessing patients prior to exenterative surgery or salvage radiotherapy to ensure there is no disease without the surgical radiotherapy field (Figure 5.13). A recent meta-analysis assessing the role of FDG PET in recurrent endometrial cancer patients reported the treatment plan changed in 22% to 35% of patients (Kadkhodayan et al. 2013).

CERVICAL CANCER

Cervical cancer is the third most common cancer among women after breast and colorectal cancer. According to the estimated statistics of the American Cancer Society there were 12,900 new cases of cervical cancer diagnosed in 2015, with 4100 cervical cancer-related deaths (Anon 2015a). Cervical cancer is a disease of a younger age group, with peak incidence between 35 and 50 years. More than 15% of cervical cancer is found in women over 65. There is also a greater incidence in developing countries and in patients in the lower socioeconomic class. Risk factors for cervical cancer include early sex and multiple sexual partners. Smoking and long-term use of oral contraceptives has also been implicated. It is now accepted that the human papilloma virus is causative. Approximately 80% of cervical cancers are squamous cell in origin, the remainder being primarily adeno and adenosquamous carcinomas.

Role of Imaging

The FIGO staging system for cervical cancer is clinical (Table 5.2). This involves EUA. Hence there are inherent weaknesses in this staging, as there are with radiology. EUA may misinterpret inflammation in the parametrial tissues as local invasion. Although cross-sectional imaging is not officially included in the staging, CT and MRI are almost universally used for assessment and staging of cervical cancers. In developed countries, cross-sectional imaging is used to provide information about the size and volume of the tumor, involvement of the parametrium and adjacent structures, and also to assess for nodal and metastatic disease. Tumor volume and parametrial involvement are critical factors for decisions regarding operability versus radiotherapy.

Ultrasound

Ultrasound, both transabdominal and transvaginal, have a very limited role in staging and assessing cervical cancer. Transrectal ultrasound has also been used in assessing cervical tumors. The tumor is seen as a hypoechoeic mass in the majority of patients (Figure 5.14). Parametrial extension is inferred when there is soft tissue stranding from the lateral margin of the tumor. In early staging, ultrasound has been reported to have an accuracy of about 75% (Yang et al. 1996). More recently, 3D transvaginal ultrasound has also been used to assess parametrial invasion in cervical cancer, with reported sensitivity and specificity similar to MRI (Byun et al. 2013).

Computed Tomography

CT has a useful role in staging advanced disease, i.e., Stage III and IV, but has a limited role in staging early-stage cervical cancer. The primary tumor may be seen as a hypodense lesion in an otherwise dense-looking cervix on post-contrast-enhanced

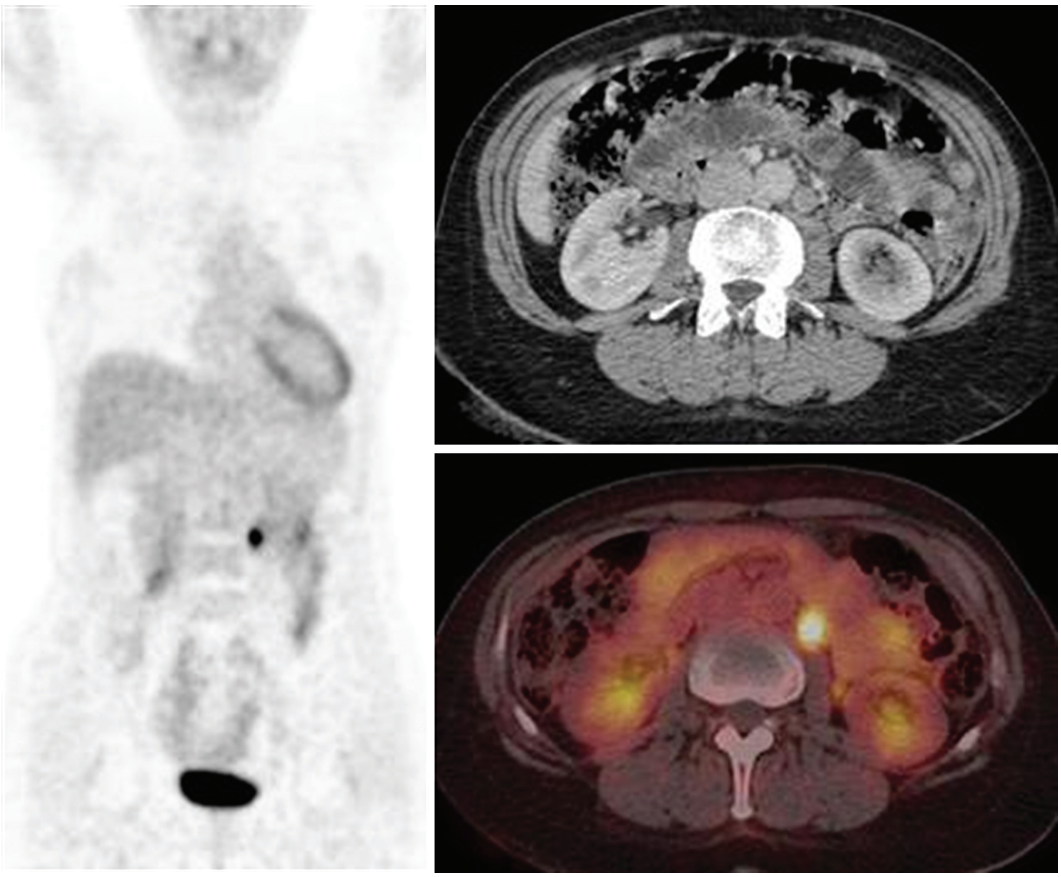

Figure 5.13 Fifty-eight-year-old Stage IIIA grade 2 endometrial carcinoma 2 years prior. Treated with TAH and BSO with adjuvant chemoradiotherapy. On follow-up, small left para-aortic node on contrast enhanced CT (top right) not enlarged by CT criteria. PET-CT confirms metabolically active and solitary site of relapse therefore suitable for radiotherapy.

Table 5.2 Cervical Cancer (FIGO Staging)

Stage	Description
Stage I	Invasive carcinoma confined to the cervix
Stage IA	Diagnosed only by microscopy
Stage IA1	Stromal invasion ≤3 mm in depth and ≤7 mm wide
Stage IA2	Stromal invasion over 3 mm and under 5 mm in depth and ≤7 mm in width
Stage IB	Clinical lesions confined to the cervix or preclinical lesions greater than Stage IA
Stage IB1	Clinical lesions not exceeding 4 cm in diameter
Stage IB2	Clinical lesions larger than 4 cm
Stage II	Extension beyond the cervix but not to the pelvic wall or the lower third of vagina
Stage IIA	Involvement of up to the upper 2/3 of the vagina No obvious parametrial involvement
Stage IIA1	Clinically visible lesion ≤ 4 cm
Stage IIA2	Clinically visible lesion > 4 cm
Stage IIB	Obvious parametrial involvement not reaching the pelvic sidewall
Stage III	The carcinoma has extended onto the pelvic sidewall On rectal examination, there is no cancer-free space between the tumor and pelvic sidewall The tumor involves the lower third of the vagina All cases of hydronephrosis or non-functioning kidney should be included unless they are known to be due to other causes
Stage IIIA	Involves the lower third of the vagina but no extension to pelvic sidewall
Stage IIIB	Extension to the pelvic wall (includes hydronephrosis/nonfunctioning kidney)
Stage IV	Extension beyond the true pelvis or involving the mucosa of bladder and/or rectum
Stage IVA	Spread to adjacent pelvic organs
Stage IVB	Spread to distant organs

Source: Reproduced from Bermudez A, Bhatla N, Leung E. 2015. *Int J Gynecol Obstet* **131**:S88–95. With Permission

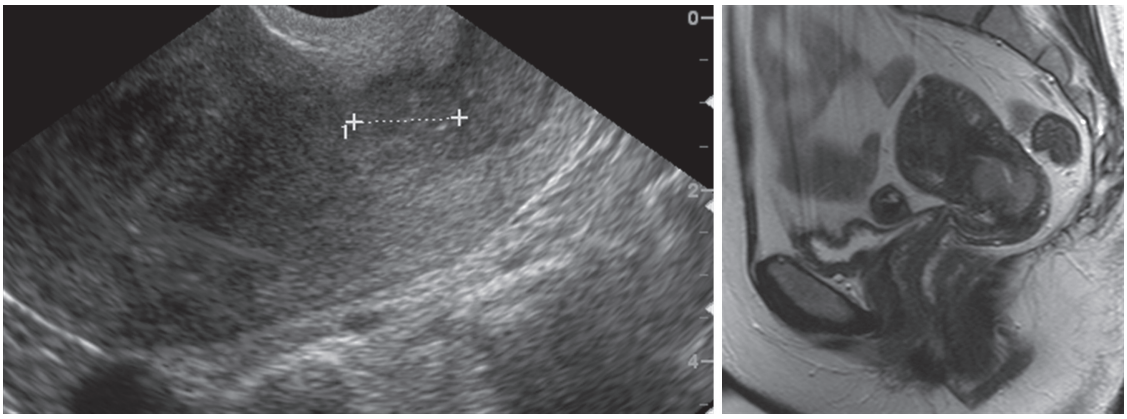

(**A**) (**B**)

Figure 5.14 (**A, B**) Transvaginal ultrasound shows a small hypoechoeic lesion at the level of the cervix in keeping with a cervical carcinoma. Corresponding sagittal T2-weighted MRI images confirms the presence of an intermediate signal intensity tumor.



Figure 5.15 Axial post-contrast-enhanced CT scan shows a large cervical squamous cell carcinoma presenting as a mixed density mass in the cervix with central gas lucency suggestive of necrosis.

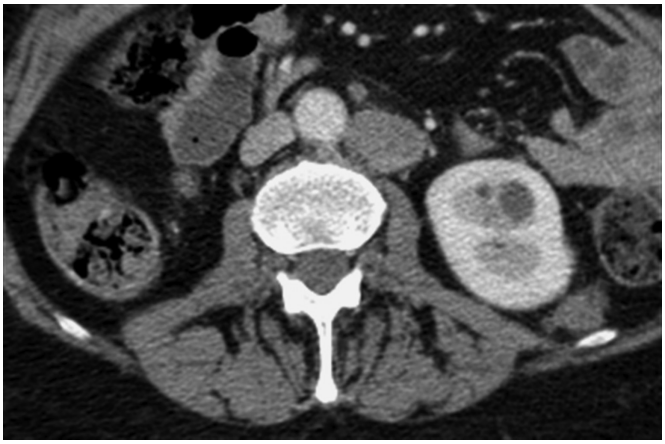

Figure 5.16 Thirty-five-year-old patient with a cervical carcinoma and enlarged left para-aortic lymph node.

scans (Figure 5.15). However, it is not possible to accurately assess the tumor volume because of lack of soft tissue contrast between the tumor and the cervical stroma. In addition, it is very difficult to assess for parametrial extension on CT, as surrounding inflammation may be overestimated as parametrial extension. An eccentric mass extending into the surrounding soft tissues is considered an important sign of parametrial extension. Involvement of the pelvic sidewall may be seen as a tumor extending to involve the obturator internus and piriformis muscle. CT is also useful in detecting nodal enlargement and distant metastases (Figure 5.16). CT has a role in detection of recurrent disease at the vaginal vault and also in the pelvic and para-aortic nodes. There are, however, limitations in differentiating radiation fibrosis from recurrent tumor and in assessing vesicovaginal and rectovaginal fistulas on CT.

Magnetic Resonance Imaging

MRI is the imaging modality of choice for local staging of cervical cancer. MRI provides information about the tumor volume, parametrial spread, and bladder and rectal involvement as well as assessment of local nodes.

The cervix shows a bi-zonal anatomy on the T2-weighted sequence in contrast to the three zones visible in the uterus (Figure 5.17). The endocervical cavity is hyperintense because of the presence of endocervical glands and mucus. The surrounding stroma is low signal on the T2-weighted sequence because of the presence of fibrous tissue and the compact arrangement of the cells with reduced extracellular matrix.

The MRI protocol for the assessment of cervical cancer is the same as that of the endometrium, with the exception that there is no additional benefit in the staging accuracy by the use of intravenous contrast. Hence contrast is not normally given in staging of cervical tumors. The small field of view axial oblique T2-weighted scan is performed perpendicular to the long axis of the cervix.

Invasive cervical carcinoma less than Stage IB is not visualized on MRI. It is important to remember that the patients will have their MRI after they have had a biopsy and diagnosis made on histology. Hence the cervix may demonstrate edema and hemorrhage at the site of the biopsy, which generally appears as an area of diffuse hyperintensity on the T2-weighted sequences. The tumor is of intermediate signal intensity on the T2-weighted scans, which contrasts nicely with the hyperintense cervical lumen and low signal intensity fibrous stroma (Figure 5.18).

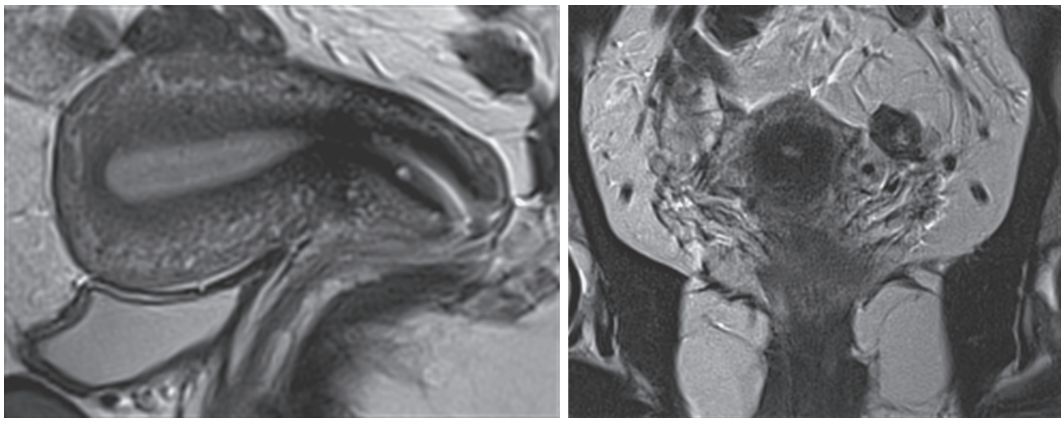

(**A**) (**B**)

Figure 5.17 (**A, B**) Sagittal and axial oblique T2-weighted MRI scan demonstrating the normal zonal anatomy of the cervix. The central endocervical gland shows high signal surrounded by a low signal intensity fibrous stroma.

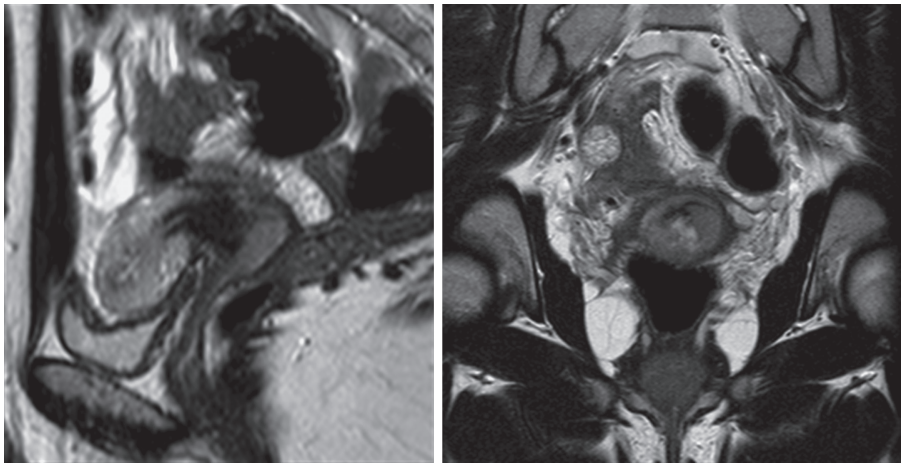

(**A**) (**B**)

Figure 5.18 (**A, B**) Sagittal and axial oblique T2-weighted MRI scan shows an intermediate signal intensity cervical cancer involving the ectocervical lip on the left side with no extension into the surrounding parametrium.

The tumor volume is calculated in three dimensions using the formula of anteroposterior dimension × transverse diameter × craniocaudal height × 0.5. In many centers, tumor volume of more than 12 cc is generally considered a cutoff between surgical treatment versus radiotherapy. Extension of the tumor into the parametrial tissues is another important parameter that defines surgical versus nonsurgical treatment. The presence of a well-defined low signal intensity fibrotic rim around the circumference of the cervical tumor is a good sign that there is no parametrial extension (Figure 5.19). This sign has been shown to have a high negative predictive value of almost 97%.

MRI is also excellent in detection of disease outside the cervix. The involvement of the ureter can be seen on both sagittal and axial T2-weighted scans as a dilated tubular structure (Figure 5.20). Similarly, MRI can assess involvement of the bladder and rectum in Stage IV disease. However, MRI can overstage disease by false positive identification of disease in the bladder or rectum, as mucosal edema may be interpreted as a local invasion. MRI has a high negative predictive value for bladder and rectal invasion (Rockall et al. 2006).

Cervical carcinoma spreads to the parametrium and tends to involve the parametrial lymph nodes and then extends to the obturator and the internal and external iliac chains. MRI, like CT, uses the size criteria for detection of nodal disease. A cutoff of short axis diameter of 10 mm is generally used for para-aortic and pelvic nodes. The cutoff value for the obturator nodes is 8 mm. The accuracy of MRI in nodal detection ranges between 76% and 88%. MRI and CT have low specificity for detection of metastatic lymph nodes. Recently, ultra-small super paramagnetic iron oxide particles have been used to detect nodal metastases in normal-size lymph nodes in patients with cervical and uterine cancers. This has been shown to improve the sensitivity of detecting nodal metastases from 77% to almost 97%; however, it is not available clinically (Rockall et al. 2005). MRI has also been considered to be very useful for assessment of vaginal fistulas, which may be related to the primary tumor or a result of treatment.

DWI has a role at all levels of staging of cervical cancer by assessing the cellularity and ADC value of the tumor as well as for local nodal involvement and detection of recurrence. Poorly differentiated tumors have a higher cellularity and a low ADC value (Figure 5.21). DWI has also been used quantitatively by measuring the ADC value and qualitatively by assessing the signal intensity on high *b*-value images to assess response to

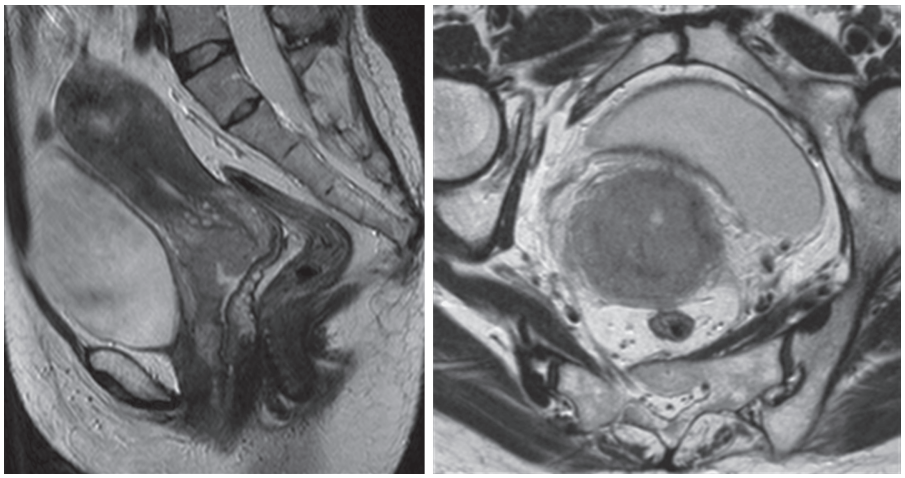

(**A**) (**B**)

Figure 5.19 (**A, B**) Sagittal and axial oblique T2-weighted MRI scans show an intermediate signal intensity tumor involving the anterior cervical lip with involvement of the upper third of the vagina and extending in to the right parametrium.

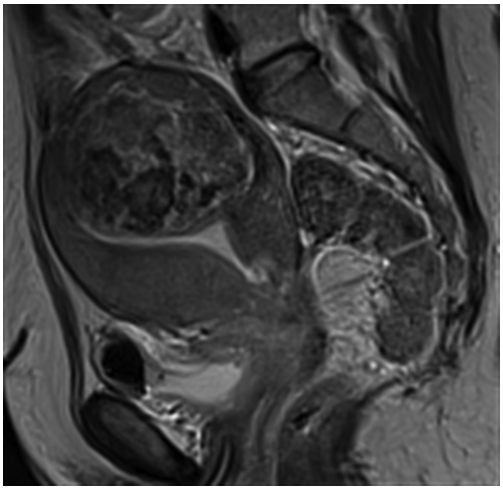

Figure 5.20 Sagittal T2-weighted MRI scan shows a large cervical cancer with Stage IV disease involving the posterior bladder wall as well as the roof. Incidental note is made of a large posterior degenerating fibroid.

treatment (Whittaker et al. 2009). Fusion of T2-weighted images with high *b*-value diffusion-weighted whole-body imaging with background body signal suppression (DWIBS) can improve the diagnostic performance of MRI in assessing parametrial invasion compared to T2-weighted imaging alone (Park et al. 2015).

FDG PET-CT

FDG PET-CT cannot reliably assess the extent of the primary tumor, which is optimally delineated by pelvic MRI. However, baseline tumor SUVmax and metabolic tumor volume are known to be prognostic indicators (Barwick et al. 2013). FDG PET-CT has no routine role in the assessment of nodal disease in early-stage cervical cancer patients, as these groups have a low incidence of nodal involvement, and if present it is often small volume/below the resolution of PET. However, in locally advanced cervical cancer the diagnostic performance of FDG PET-CT is superior to standard contrast-enhanced CT (CECT)-MRI (Choi et al. 2010, Selman et al. 2008). FDG PET-CT is recommended by the National Comprehensive Cancer Network (NCCN), Royal College of Radiologists, and

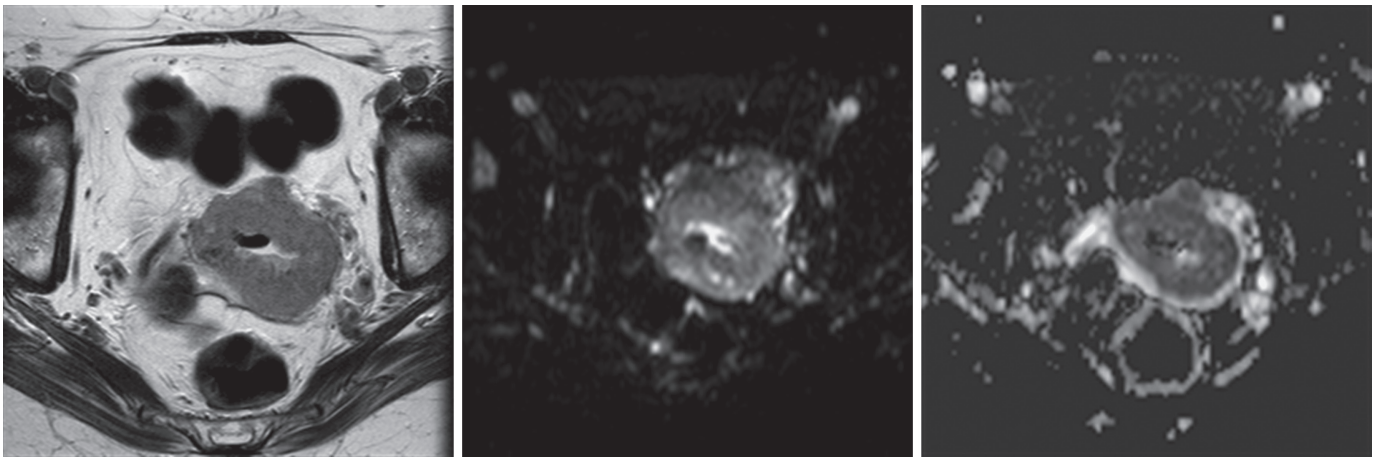

(**A**) (**B**) (**C**)

Figure 5.21 (**A–C**) Axial oblique T2-weighted scan of a cervical cancer showing restricted diffusion seen as high signal on the DWI scan and low signal on the corresponding ADC map.

the Scottish Intercollegiate Guidelines Network (SIGN) guidelines for assessment of locally advanced cervical cancer (>1B1) prior to chemoradiation therapy (Anon 2013) (Figure 5.22). There is no clear role for FDG PET-CT in the routine follow-up of cervical cancer patients. However, FDG PET-CT 3 months following chemoradiation therapy in cases of locally advanced cervical cancer is a prognostic marker for overall outcome (Schwarz et al. 2007). It is widely accepted that FDG PET-CT to exclude distant disease should be performed in cases of recurrence in whom salvage pelvic exenteration or radiotherapy is being considered (Husain et al. 2007).

OVARIAN MALIGNANCY

The estimated number of new cases of ovarian cancer in the United States in 2015 was 21,290, with over 14,180 deaths (Anon 2015c). This generally seems to have remained stable since 2009. A woman's lifetime risk of getting ovarian cancer is 1 in 75. White American females are more likely to get ovarian cancer than African-American women. Presenting symptoms are rather vague, meaning that diagnosis is often at an advanced stage of disease. Imaging is used in the detection of ovarian cancer and surgical planning. In addition, imaging has a pivotal role in the characterization of adnexal masses, many of which are benign.

Ovarian cancer staging is by the FIGO staging system and uses information obtained from surgery, usually comprising of total abdominal hysterectomy, bilateral salpingo-oophorectomy, omentectomy ± pelvic and para-aortic nodal sampling and peritoneal washings for cytology. The American Joint Committee on Cancer (AJCC) staging corresponds with that of FIGO.

Ultrasound

Ultrasound is the main imaging modality used in the detection of ovarian cancer. Transvaginal ultrasound, both gray-scale and color Doppler, is considered the imaging modality of choice for characterization of adnexal masses. However, this needs to be performed by experienced sonographers/radiologists with special interest in gynecological sonography. International Ovarian Tumor Analysis (IOTA) has described various malignant and benign features of adnexal masses. An adnexal mass can be classified into six categories: certainly malignant, probably malignant, of uncertain nature but more likely malignant, uncertain

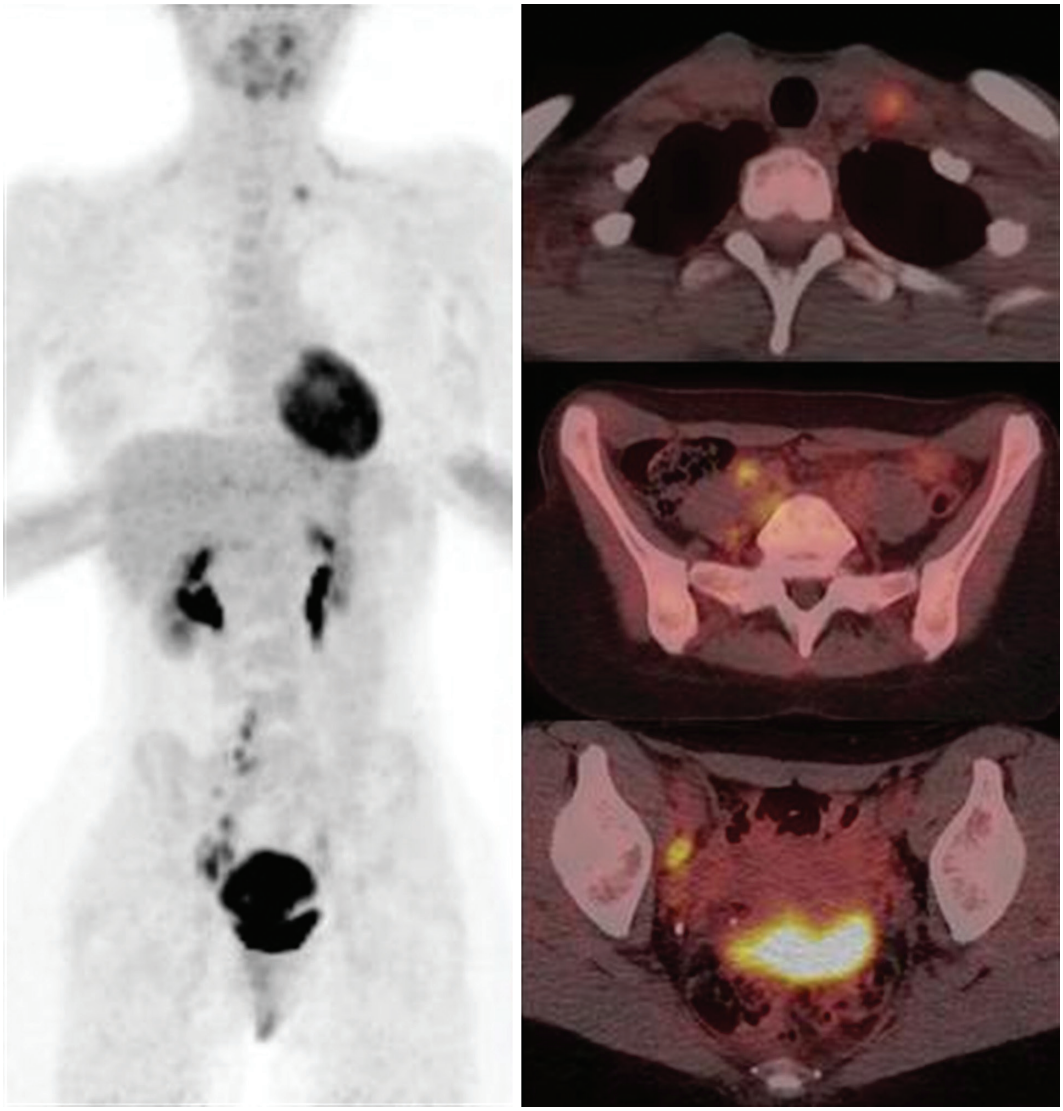

Figure 5.22 Coronal PET and axial fused PET-CT in a 40-year-old with cervical carcinoma shows extensive pelvic nodal disease and a left supraclavicular node.

Table 5.3 International Ovarian Tumor Analysis (IOTA) Simple Rules

	Features for Predicting a Malignant Tumor (M Features)		Features for Predicting a Benign Tumor (B-Features)
M1	Irregular solid tumor	B1	Unilocular tumor
M2	Presence of ascites	B2	Presence of solid components where the largest solid component has the largest diameter <7 mm
M3	At least 4 papillary structures	B3	Presence of acoustic shadows
M4	Irregular multilocular solid tumor with largest diameter >100 mm	B4	Smooth multilocular tumor with largest diameter <100 mm
M5	Very strong blood flow (color score 4)	B5	No blood flow (color score 1)

Source: Reproduced by permission of IOTA.

but most likely benign, probably benign, and certainly benign. In expert hands, the sensitivity and specificity of detecting malignancy in an adnexal mass is 91% and 96%, respectively (Valentin et al. 2011). Imaging features suggesting a malignant diagnosis include solid or mixed cystic and solid lesions, bilateral disease, the presence of ascites, and peritoneal deposits. The simple rules developed by IOTA are based on five ultrasound features of malignancy and five features of benign lesions (Kaijser et al. 2014) (Table 5.3). An alternative approach is to use various prediction and risk models to triage women as being of high or low risk of cancer. The risk of malignancy index (RMI) model is the most validated model. The RMI combines ultrasound with menopause status and the Ca125 level. This RMI ascribes a numerical value, which can be used to assess cancer risk. Premenopausal women are ascribed a value of 1, compared with 3 for postmenopausal women (Jacobs et al. 1990). Ultrasound is scored 0, 1, or 3, depending on the number of malignant indicators, with 0 if no factors are present, 1 for one factor, and 3 for two or more of the following: multilocular cyst, evidence of solid areas, evidence of metastases, presence of ascites, and/or bilateral lesions (Figures 5.23–5.26) (see Chapter 21).

Trials of ultrasound as a screening test for ovarian cancer have to date demonstrated high levels of sensitivity but relatively low specificity, with the result that ultrasound alone is not yet recommended for screening. Trials in high-risk populations are ongoing, as are studies comparing serial Ca-125 estimations with ultrasound (Menon et al. 2009).



Figure 5.23 Ultrasound demonstrating a single unilocular ovarian cyst subsequently diagnosed as a cystadenoma.

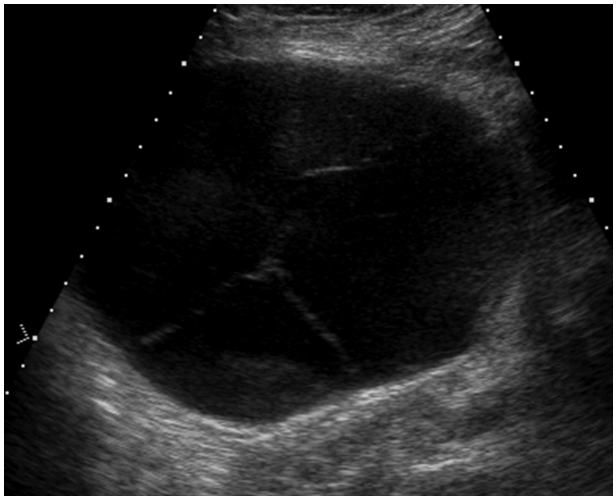

Figure 5.24 Ultrasound showing a simple ovarian cyst with fine internal septations.

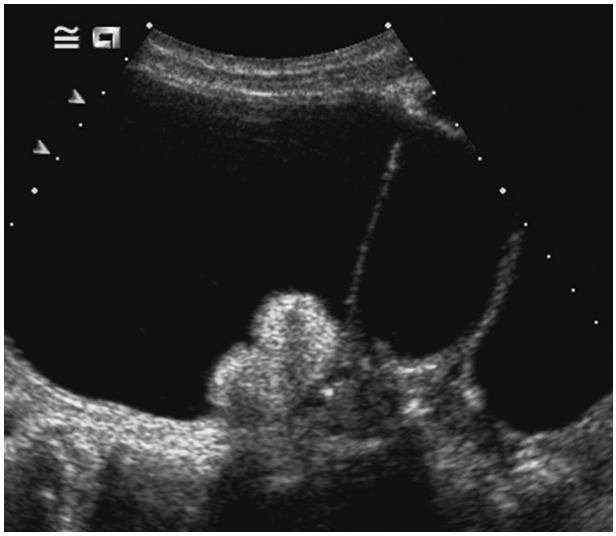

Figure 5.25 Pelvic ultrasound with an adnexal mass comprising both solid and septated cystic elements.

Computed Tomography

CT usually performed with intravenous contrast agents. CT is the mainstay of ovarian cancer staging, providing a rapid evaluation of chest, abdomen, and pelvis. The FIGO staging is outlined in Table 5.4.

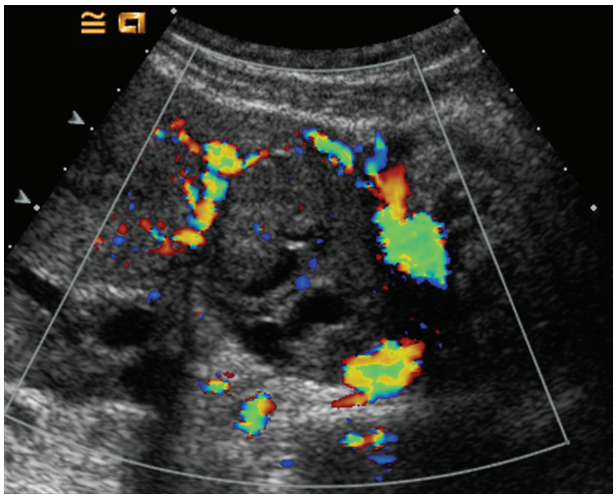

(**A**)

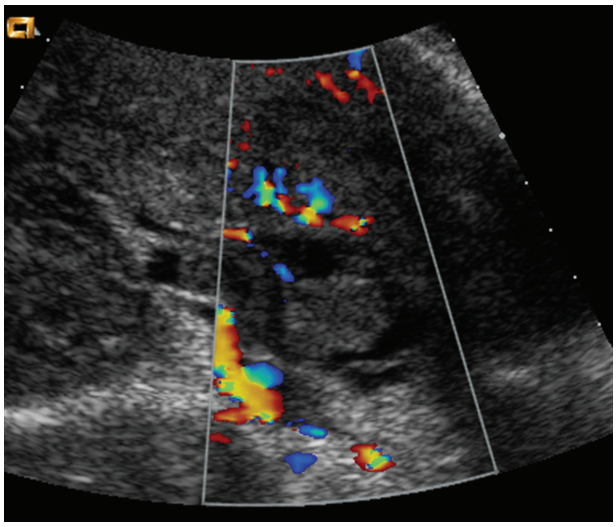

(**B**)

Figure 5.26 (**A, B**) Bilateral complex ovarian masses with cystic and solid elements with abnormal vascularity.

Although FIGO staging of ovarian cancer is based on surgical findings and histopathology, imaging may be used for estimations of disease bulk and staging in more advanced disease. It should be noted that although liver metastases constitute Stage IV disease, this is only the case when they are parenchymal. Subcapsular or surface liver metastases, although dramatic in appearance, only constitute Stage III disease (Figures 5.27–5.31).

The main limitation of CT in staging is that of spatial resolution in the detection of small peritoneal deposits. However, it is useful in predicting those patients less likely to benefit from a primary surgical approach to treatment, i.e., those in whom optical debulking is likely to be unsuccessful. Indicators include significant disease in the upper abdomen, subcapsular liver deposits, and para-aortic lymph nodes above the renal vessels. For patients treated with primary chemotherapy, cytoreductive surgery is often considered if a partial response to treatment is seen after three cycles. In this respect, CT is used to accurately define the extent of post-treatment disease. Although a freehand technique is usually used to define response, many studies require formal RECIST evaluation (response evaluation criteria in solid tumors).

Magnetic Resonance Imaging

MRI serves two main roles in the workup of patients with ovarian cancer. Firstly, there is a diagnostic role, as a good quality MRI can exclude some causes of complex ovarian cyst, e.g., dermoid and endometrioma (Figures 5.32 and 5.33).

MRI can also be invaluable in surgical planning, allowing multiplanar delineation of relationships of adjacent structures, such as bowel, ureters, and blood vessels. It can also give some indication of the type of malignancy. Antispasmolytics are routinely used to control bowel motion. Alternatively, some scanners have motion correction sequences (Figure 5.34).

MRI scans, both conventional and post-contrast-enhanced, are now part of the well-established guidelines provided by the European Society of Urogenital Radiology for characterization of indeterminate adnexal masses (Spencer et al. 2010).

DWI is now routinely used as part of the protocol for characterizing adnexal masses. DWI is based on measuring the cellularity of tumors. In general, malignant tumors tend to be more cellular and show restricted diffusion (high signal) on the DWI sequence with high *b*-value. Tumors of high cellularity are likely to show high signal intensity on high *b*-value images; however, many ovarian tumors have significant cystic components in which there is free diffusion of water and hence low signal on high *b*-value sequences (Whittaker et al. 2009).

Dynamic contrast enhanced MRI scans with semi-quantitative analysis with time intensity curves are also part of the routine protocol for characterization of indeterminate adnexal masses. Changes in signal intensity of the mass on various phases of dynamic post-contrast-enhanced scans before, during, and after contrast administration may help in differentiating benign from malignant tumors (Bernardin et al. 2012) (Figure 5.35). A new Adnex MRI change to MRI scoring system has been developed to improve the characterization of adnexal masses using functional imaging sequences (Thomassin-Naggara et al. 2013).

PET-CT

FDG PET-CT is not used to characterize adnexal masses, as it cannot discriminate reliably between benign, borderline, and malignant lesions (Dauwen et al. 2013). PET-CT may be used to accurately stage disease which is apparently Stage I or II to look for occult peritoneal deposits or lymph node disease. However, the limited spatial resolution means small nodes or peritoneal nodules may be missed. Integrated FDG PET-CT-CECT is more accurate than CECT alone in predicting surgical staging (Kitajima et al. 2008). However, routine PET-CT has not been shown to give additional benefit over CECT alone in terms of cost-effectiveness and patient outcome to support widespread routine use. It may be used in the detection of recurrence particularly in the scenario of rising Ca 125 and negative conventional workup with CECT and MRI (Gu et al. 2009) (Figure 5.35).

There is evidence that FDG PET-CT can detect response early during chemotherapy for ovarian cancer (Avril et al. 2005, Rockall et al. 2012). This is an area for further research.

Table 5.4 Ovarian Cancer (FIGO Staging)

Stage	Description
Stage I	Disease confined to ovaries
Stage IA	Involves one ovary; capsule intact; no tumor on ovarian surface; no malignant cells in peritoneal washings or ascites
Stage IB	Involves both ovaries; capsule intact; no tumor on ovarian surface; negative washings
Stage IC	Tumor limited to ovaries with any of the following: surgical spill, capsule ruptured, tumor on ovarian surface, positive washings
Stage II	Pelvic extensions (below pelvic brim) or implants
Stage IIA	Extension or implants onto uterus or fallopian tube
Stage IIB	Extension or implants onto other pelvic structures
Stage III	Microscopic peritoneal implants outside the pelvis and/or metastasis to the retroperitoneal lymph nodes
Stage IIIA1	Positive retroperitoneal lymph nodes only (cytologically or histologically proven): type i, metastasis up to 10 mm in greatest dimension; type ii, metastasis more than 10 mm in greatest dimension
Stage IIIA2	Microscopic extrapelvic (above the pelvic brim) peritoneal involvement with or without positive retroperitoneal lymph nodes
Stage IIIB	Macroscopic peritoneal metastases beyond pelvis less than 2 cm in size, with or without metastasis to the retroperitoneal lymph nodes
Stage IIIC	Peritoneal metastases beyond pelvis >2 cm with or without lymph node metastases (includes extension of tumor to capsule of liver and spleen without parenchymal involvement of either organ)
Stage IV	Distant metastases excluding peritoneal metastases
Stage IVA	Pleural effusion with positive cytology
Stage IVB	Parenchymal metastases and metastases to extra-abdominal organs (including inguinal lymph nodes and lymph nodes outside of the abdominal cavity)

Source: Reproduced from Berek JS, Crum C, Friedlander M. 2015. *Int J Gynecol Obstet* **131**:S111–22. With Permission.



Figure 5.27 Contrast enhanced CT scan demonstrating Stage I ovarian carcinoma with small bilateral pelvic masses. There is no ascites and the remainder of the scan demonstrated no intra-abdominal disease.

VAGINAL CANCER

Vaginal cancer is a rare disease predominantly seen in elderly females with 70% to 80% occurring in women above the age of 60. According to the American Cancer Society estimates for 2015, 4070 new cases of vaginal cancer will be diagnosed, and about 910 women will die of this cancer (Anon 2015d). Invasive vaginal cancer is usually associated with vaginal intraepithelial neoplasia (VAIN).

The majority of vaginal cancers are squamous cell carcinoma; 5% to 10% of vaginal cancers are adenocarcinomas.

Imaging

Superficial tumors do not require imaging for local staging. However, MRI is the imaging modality, which is useful in staging vaginal tumors and determining the extent of disease for surgical planning. The tumor is difficult to identify on CT. The tumor is intermediate signal on the T1-weighted sequence and slightly high signal on the T2-weighted sequence (Figure 5.36). MRI can demonstrate tumor spread into the paracolpos fat, which implies Stage II disease. Pelvic floor involvement, which implies Stage III disease, is best seen on the coronal sequence. Stage IV disease is seen as involvement of the bladder and rectum. MRI can also demonstrate local pelvic nodal enlargement. MRI is also good for assessment of recurrent disease as well as colovaginal and vesicovaginal fistulas (See Table 5.5).

CT is useful for assessing distant metastases in vaginal cancers.

Vulval Cancer

Vulval carcinoma is a disease predominantly affecting older women. In the United States, vulvar cancer accounts for about 4% of cancers of female reproductive organs and 0.6% of all cancers in women. According to estimates of the American Cancer Society for 2015, about 5150 cases of vulva cancer will be diagnosed, and 1080 women will die of this cancer (Anon 2015e). Early staging is related to the local extent of disease, which is readily evaluated by clinical examination (Table 5.6).

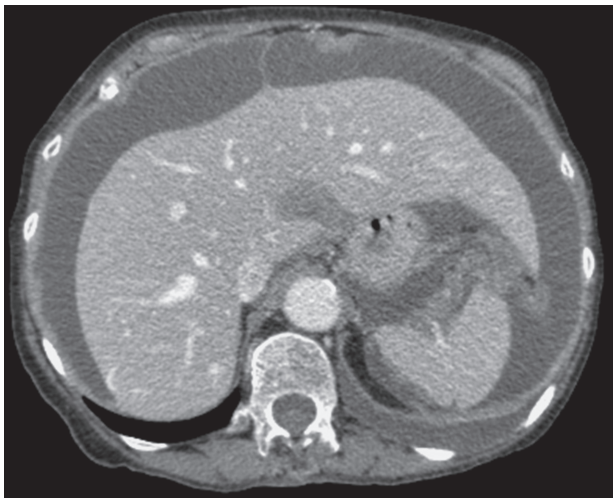

(**A**)

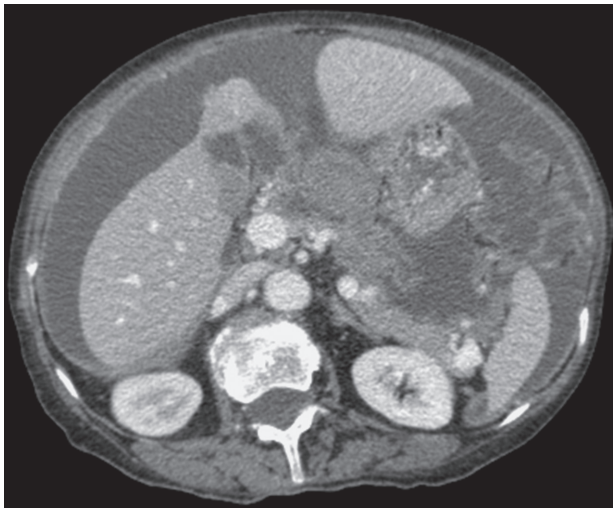

(**B**)

Figure 5.28 (**A, B**) Stage III ovarian carcinoma with ascites and peritoneal deposits affecting the visceral peritoneum and free floating within the peritoneal cavity.

Invasion of local structures is best assessed by MRI, as is inguinal and pelvic lymph node spread.

Ultrasound

There are some reports of the use of high-resolution ultrasound in the estimation of depth of invasion, however this is operator dependent and not always clinically acceptable to patients. Ultrasound may be used for detection of inguinal and some iliac lymph nodes, but views may be obscured by overlying bowel gas. Ultrasound-guided biopsy of lymph nodes that are suspicious for invasion is possible, with the drawback of false negative studies. This is because tumor does not uniformly infiltrate nodes, with a resultant risk of sampling error.

Computed Tomography

The main role of CT is to identify distant metastases and record disease response to therapy. Standard contrast-enhanced axial sequences are used. FDG PET-CT is not routinely used in staging vulval cancer. The high positive predictive value of PET-CT means it can be used for therapy planning in patients with Stage III disease; however, the poor sensitivity for small nodal metastases means it cannot replace surgical lymphadenectomy (Kamran et al. 2014). Alternative functional imaging with technetium 99 (99mTc)-labeled nanocolloids and/or blue dye-enhanced lymphoscintigraphy-guided sentinel lymph node biopsy (SLNB) is also under evaluation at present. A recent meta-analysis of 24 studies suggested SLNB is highly accurate, but patients must make an informed choice between the slightly higher groin recurrence rates of SLNB versus the greater morbidity of nodal dissection (Meads et al. 2014).

MRI is increasingly being used to delineate the exact disease extent, depth of invasion, and involvement of adjacent structures, especially urethra and rectum (Figure 5.37). The spatial resolution makes it impossible to accurately delineate Stage IA disease, but tumor can usually be identified when stromal invasion exceeds 2 to 3 mm. MRI has also been successfully used for the identification of lymph node metastases, although the recognized size criteria are not always reliable in small-volume disease. Assessment of nodal morphology such as contour, presence of necrosis, loss of fatty hilum, and signal intensity relative to primary tumor can improve sensitivity for nodal involvement (Kataoka et al. 2010). Work with Ultrasmall SuperParamagnetic Iron Oxide (USPIO) MRI contrast agents has demonstrated some improvements in sensitivity and specificity, but they are not clinically available.

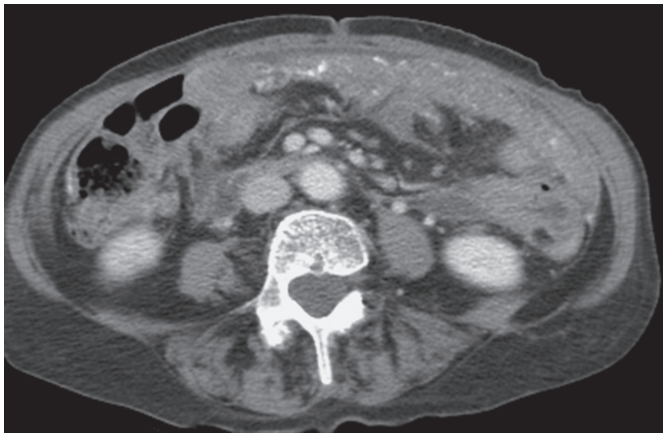

(**A**)

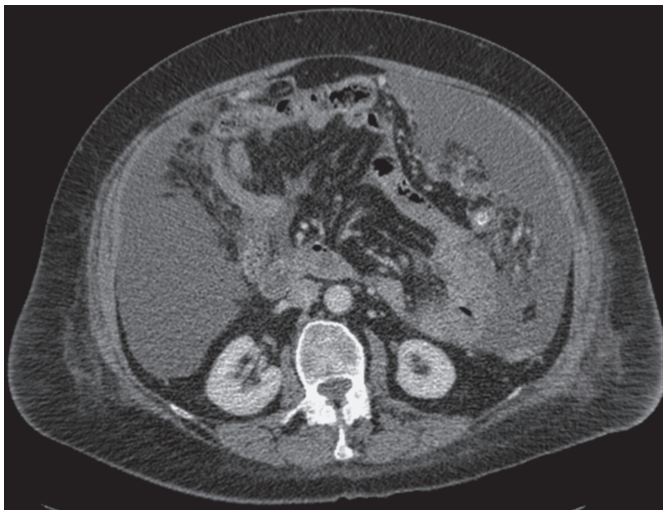

(**B**)

Figure 5.29 Two examples of omental disease in Stage III ovarian cancer. (**A**) Demonstrates a typical omental "cake," while (**B**) demonstrates fine nodular studding of the omentum.



Figure 5.30 CT scan demonstrating subcapsular surface deposits on the liver. They are low attenuation peripheral masses which distort the serosal contour of the liver. This is considered as Stage III disease within the FIGO categorization.



Figure 5.31 Parenchymal liver metastases in this example of Stage IV disease are identified as multiple low attenuation deposits within the liver.

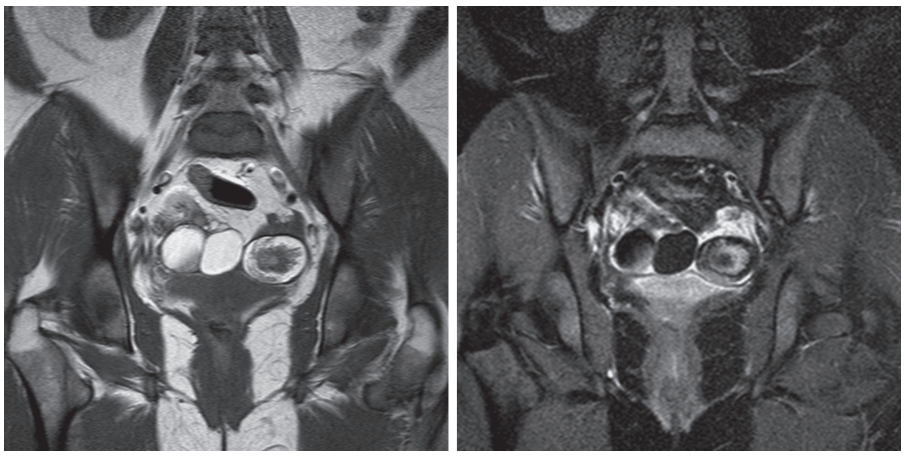

(**A**) (**B**)

Figure 5.32 (**A, B**) MRI imaging of bilateral ovarian dermoids demonstrates high signal return on T1 sequence with loss of signal on T1-weighted fat saturated imaging.

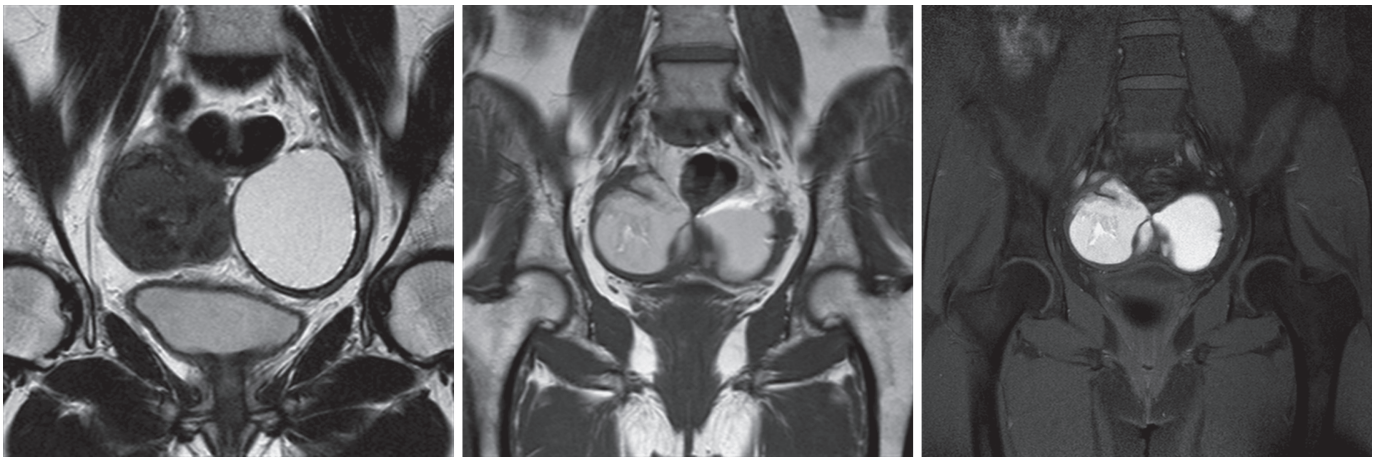

(**A**) (**B**) (**C**)

Figure 5.33 MRI imaging of bilateral complex pelvic masses in endometriosis. Coronal oblique T2-weighted imaging demonstrates two pelvic masses; one of high signal and one of low signal (**A**). They are both high signal on T1-weighted and T1-weighted fat saturated images (**B, C**), indicating the presence of blood products. The T2 appearances indicate that these are of differing ages, a characteristic feature of endometriosis.

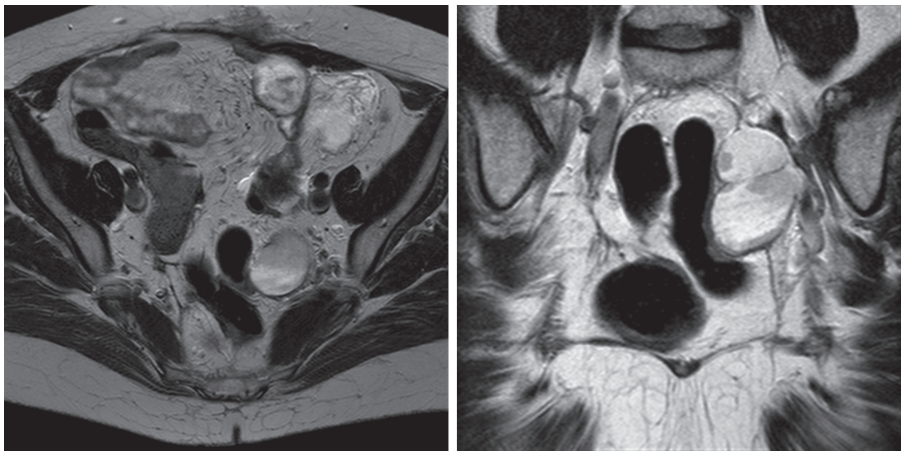

(**A**) (**B**)

Figure 5.34 (**A, B**) Sagittal and coronal T2-weighted sequences elegantly demonstrating the relationship between the ovarian masses and the adjacent bowel.

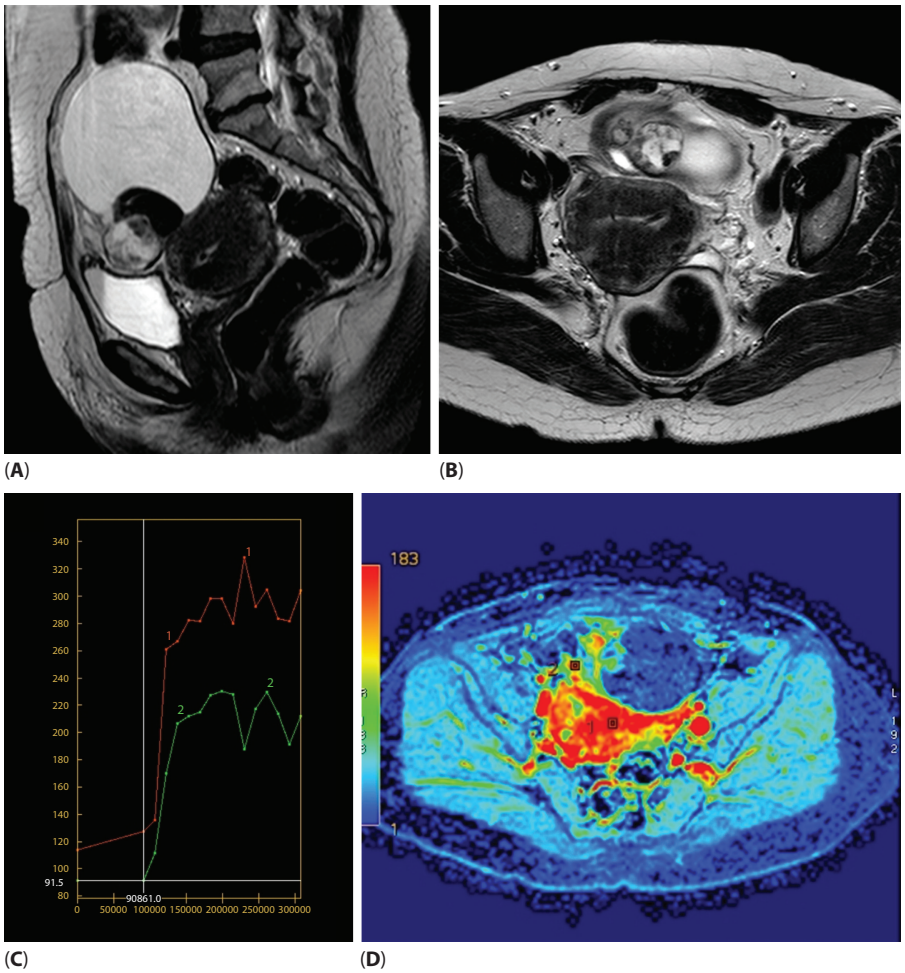

Figure 5.35 (**A–D**) Dynamic contrast enhanced intensity curve on a complex adnexal mass. Axial and sagittal T2-weighted sequences through a complex adnexal mass with solid and cystic components. A time intensity curve is generated (green) with a comparative curve for myometrium (green) showing a Type 3 curve with intense early enhancement greater than myometrium implying an invasive lesion.

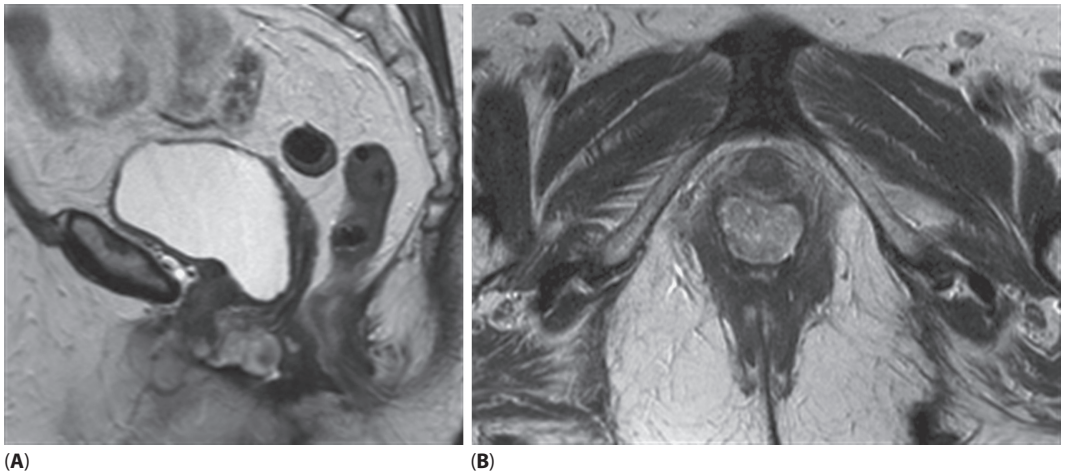

Figure 5.36 (**A, B**) Sagittal and axial T2-weighted MRI scan shows an intermediate signal intensity squamous cell carcinoma in the lower of the vagina almost extending into the introitus.

Table 5.5 Vaginal Cancer (FIGO Staging)

Stage	Description
Stage I	Invasive carcinoma confined to the vaginal wall
Stage II	Tumor has involved subvaginal tissue but has not extended to the pelvic wall
Stage III	Extension to the pelvic wall
Stage IV	The carcinoma has extended beyond the true pelvis or has involved the mucosa of the bladder or rectum (bullous edema as such does not permit a case to be allotted to Stage IV)
Stage IV A	Tumor invades bladder and/or rectal mucosa and/or direct extension beyond the true pelvis
Stage IV B	Spread to distant organs

Source: Reproduced from Hacker NF, Eifel PJ, van der Velden J. 2015. *Int J Gynecol Obstet* **131**:S84–7. With Permission.

Table 5.6 Vulval Cancer (FIGO Staging)

Stage	Description
Stage I	Tumor confined to the vulva
Stage IA	≤2 cm in size, confined to vulva or perineum and with stromal invasion ≤1.0 mm Negative nodes
Stage IB	>2 cm in size or stromal invasion >1.0 mm, confined to vulva or perineum Negative nodes
Stage II	Tumor of any size with extension to adjacent perineal structures (1/3 lower urethra, 1/3 lower vagina, anus) Negative nodes
Stage III	Tumor of any size with or without extension to adjacent perineal structures (1/3 lower urethra, 1/3 lower vagina, anus) Positive inguinofemoral lymph nodes
Stage IIIA	(i) One lymph node metastases (≥5 mm) (ii) One to two lymph node metastasis/es (<5 mm)
Stage IIIB	(i) Two or more lymph node metastases (≥5 mm), or (ii) Three or more lymph node metastases (<5 mm)
Stage IIIC	With positive nodes with extracapsular spread
Stage IV	Tumor invades other regional (2/3 upper urethra, 2/3 upper vagina), or distant structures
Stage IVA	Tumor invades any of the following: (i) Upper urethral and/or vaginal mucosa, bladder mucosa, rectal mucosa, or fixed to pelvic bone (ii) Fixed or ulcerated inguinofemoral lymph nodes
Stage IVB	Any distant metastasis including pelvic lymph nodes

Source: Reproduced from Hacker NF, Eifel PF, van der Velden J. 2015. *Int J Gynecol Obstet* **131**:S76–83. With Permission.

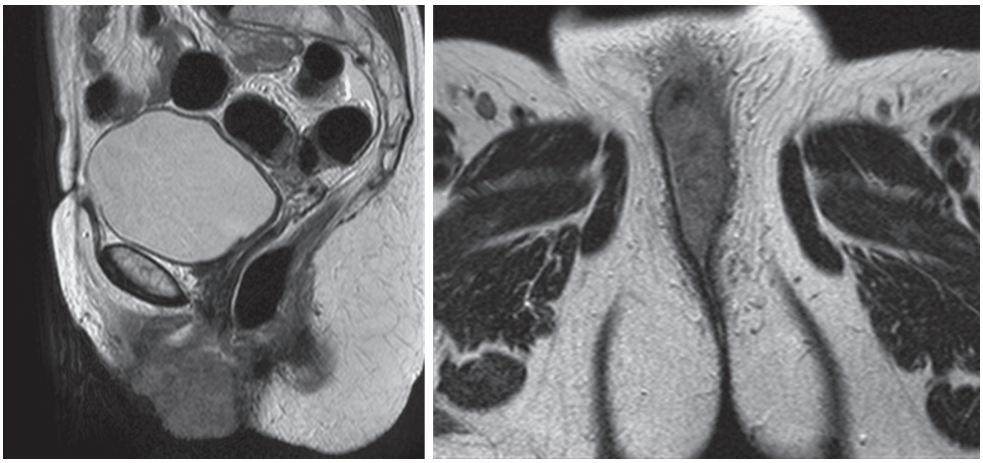

(**A**) (**B**)

Figure 5.37 (**A, B**) Sagittal and axial T2-weighted MRI scan shows a large vulval tumor expanding into the introitus and involving the clitoris. The tumor is seen clear of the lower part of the urethra.

REFERENCES

Anon. The Royal College of Physicians of London. http://www.swscn.org.uk/wp/wp-content/uploads/2014/11/pet-ct_guidelines_2013.pdf.

Anon. 2013. National Comprehensive Cancer Network (NCCN). www.nccn.org/professionals/physician_gls/pdf/cervical.pdf.

Anon. 2015a. American Cancer Society. What are the key statistics about cervical cancer? www.cancer.org/cancer/cervicalcancer/detailedguide/cervical-cancer-key-statistics.

Anon. 2015b. American Cancer Society. Endometrial cancer. www.cancer.org/cancer/endometrialcancer/detailedguide/endometrial-uterine-cancer-key-statistics.

Anon. 2015c. American Cancer Society. Ovarian cancer. www.cancer.org/cancer/ovariancancer/detailedguide/ovarian-cancer-key-statistics.

Anon. 2015d. American Cancer Society. Vaginal cancer. www.cancer.org/cancer/vaginalcancer/detailedguide/vaginal-cancer-key-statistics.

Anon. 2015e. American Cancer Society. Vulvar cancer. www.cancer.org/cancer/vulvarcancer/detailedguide/vulvar-cancer-key-statistics.

Avril N, Sassen S, Schmalfeldt B, et al. 2005. Prediction of response to neoadjuvant chemotherapy by sequential F-18-fluorodeoxyglucose positron emission tomography in patients with advanced-stage ovarian cancer. *J Clin Oncol* **23**(30.):7445–53.

Barwick TD, Taylor A, Rockall A. 2013. Functional imaging to predict tumor response in locally advanced cervical cancer. *Curr Oncol Rep* **15**(6.):549–58.

Bernardin L, Dilks P, Liyanage S, et al. 2012. Effectiveness of semi-quantitative multiphase dynamic contrast-enhanced MRI as a predictor of malignancy in complex adnexal masses: Radiological and pathological correlation. *Eur Radiol* **22**(4):880–90.

Byun JM, Kim YN, Jeong DH, et al. 2013. Three-dimensional transvaginal ultrasonography for locally advanced cervical cancer. *Int J Gynecol Cancer* **23**(8):1459–64.

Cabrita S, Rodrigues H, Abreu R, et al. 2008. Magnetic resonance imaging in the preoperative staging of endometrial carcinoma. *Eur J Gynaecol Oncol* **29**(2):135–7.

Choi HJ, Ju W, Myung S, et al. 2010. Diagnostic performance of computer tomography, magnetic resonance imaging, and positron emission tomography or positron emission tomography/computer tomography for detection of metastatic lymph nodes in patients with cervical cancer: Meta-analysis. *Cancer Sci* **101**(6):1471.

Dauwen H, Van CB, Deroose CM, et al. 2013. PET-CT in the staging of patients with a pelvic mass suspicious for ovarian cancer. *Gynecol Oncol* **131**(3):694–700.

Epstein E, Blomqvist L. 2014. Imaging in endometrial cancer. *Best Pract Res Clin Obstet Gynaecol* **28**(5):721–39.

Fujii S, Matsusue E, Kigawa J, et al. 2008. Diagnostic accuracy of the apparent diffusion coefficient in differentiating benign from malignant uterine endometrial cavity lesions: Initial results. *Eur Radiol* **18**(2):384–9.

Gu P, Pan LL, Wu SQ, et al. 2009. CA 125, PET alone, PET-CT, CT and MRI in diagnosing recurrent ovarian carcinoma: A systematic review and meta-analysis. *Eur J Radiol* **71**(1):164–74.

Husain A, Akhurst T, Larson S, et al. 2007. A prospective study of the accuracy of 18Fluorodeoxyglucose positron emission tomography (18FDG PET) in identifying sites of metastasis prior to pelvic exenteration. *Gynecol Oncol* **106**(1):177–80.

Jacobs I, Oram D, Fairbanks J, et al. 1990. A risk of malignancy index incorporating CA 125, ultrasound and menopausal status for the accurate preoperative diagnosis of ovarian cancer. *Br J Obstet Gynaecol* **97**(10):922–9.

Kadkhodayan S, Shahriari S, Treglia G, et al. 2013. Accuracy of 18-F-FDG PET imaging in the follow up of endometrial cancer patients: Systematic review and meta-analysis of the literature. *Gynecol Oncol* **128**(2):397–404.

Kaijser J, Vandecaveye V, Deroose CM, et al. 2014. Imaging techniques for the pre-surgical diagnosis of adnexal tumours. *Best Pract Res Clin Obstet Gynaecol* **28**(5):683–95.

Kakhki VR, Shahriari S, Treglia G, et al. 2013. Diagnostic performance of fluorine 18 fluorodeoxyglucose positron emission tomography imaging for detection of primary lesion and staging of endometrial cancer patients: Systematic review and meta-analysis of the literature. *Int J Gynecol Cancer* **23**(9):1536–43.

Kamran MW, O'Toole F, Meghen K, et al. 2014. Whole-body [18F]fluoro-2-deoxyglucose positron emission tomography scan as combined PET-CT staging prior to planned radical vulvectomy and inguinofemoral lymphadenectomy for squamous vulvar cancer: A correlation with groin node metastasis. *Eur J Gynaecol Oncol* **35**(3):230–5.

Kataoka MY, Sala E, Baldwin P, et al. 2010. The accuracy of magnetic resonance imaging in staging of vulvar cancer: A retrospective multi-centre study. *Gynecol Oncol* **117**(1):82–7.

Kim SH, Kim HD, Song YS, et al. 1995. Detection of deep myometrial invasion in endometrial carcinoma: Comparison of transvaginal ultrasound, CT, and MRI. *J Comput Assist Tomogr* **19**(5):766–72.

Kitajima K, Murakami K, Yamasaki E, et al. 2008. Diagnostic accuracy of integrated FDG-PET/contrast-enhanced CT in staging ovarian cancer: Comparison with enhanced CT. *Eur J Nucl Med Mol Imaging* **35**(10):1912–20.

Levine D, Gosink BB, Johnson LA.1995. Change in endometrial thickness in postmenopausal women undergoing hormone replacement therapy. *Radiology* **197**(3):603–8.

Meads C, Sutton AJ, Rosenthal AN, et al. 2014. Sentinel lymph node biopsy in vulval cancer: Systematic review and meta-analysis. *Br J Cancer* **110**(12):2837–46.

Menon U, Gentry-Maharaj A, Hallett R, et al. 2009. Sensitivity and specificity of multimodal and ultrasound screening for ovarian cancer, and stage distribution of detected cancers: Results of the prevalence screen of the UK Collaborative Trial of Ovarian Cancer Screening (UKCTOCS). *Lancet Oncol* **10**(4):327–40.

Ortashi O, Jain S, Emannuel O, et al. 2008. Evaluation of the sensitivity, specificity, positive and negative predictive values of preoperative magnetic resonance imaging for staging endometrial cancer. A prospective study of 100 cases at the Dorset Cancer Centre. *Eur J Obstet Gynecol Reprod Biol* **137**(2):232–5.

Padhani AR, Liu G, Koh DM, et al. 2009. Diffusion-weighted magnetic resonance imaging as a cancer biomarker: Consensus and recommendations. *Neoplasia.* **11**(2):102–25.

Park JJ, Kim CK, Park SY, et al. 2015. Parametrial invasion in cervical cancer: Fused T2-weighted imaging and high-b-value diffusion-weighted imaging with background body signal suppression at 3 T. *Radiology* **274**(3):734–41.

Pecorelli S. 2009. Revised FIGO staging for carcinoma of the vulva, cervix, and endometrium. *Int J Gynaecol Obstet* **105**(2):103–4.

Rechichi G, Galimberti S, Signorelli, et al. 2010. Myometrial invasion in endometrial cancer: Diagnostic performance of diffusion-weighted MR imaging at 1.5-T. *Eur Radiol* **20**(3):754–62.

Rockall A, Munari A, Avril N. 2012. New ways of assessing ovarian cancer response: Metabolic imaging and beyond. *Cancer Imaging* **12**:310–4.

Rockall AG, Ghosh S, Alexander-Sefre F, et al. 2006. Can MRI rule out bladder and rectal invasion in cervical cancer to help select patients for limited EUA? *Gynecol Oncol* **101**(2):244–9.

Rockall AG, Sohaib SA, Harisinghani MG, et al. 2005. Diagnostic performance of nanoparticle-enhanced magnetic resonance imaging in the diagnosis of lymph node metastases in patients with endometrial and cervical cancer. *J Clin Oncol* **23**(12):2813–21.

Sala E, Rockall A, Rangarajan D, et al. 2010. The role of dynamic contrast-enhanced and diffusion weighted magnetic resonance imaging in the female pelvis. *Eur J Radiol* **76**(3):367–85.

Schwarz JK, Siegel BA, Dehdashti F, et al. 2007. Association of posttherapy positron emission tomography with tumor response and survival in cervical carcinoma. *JAMA* **298**(19):2289–95.

Selman TJ, Mann C, Zamora J, et al. 2008. Diagnostic accuracy of tests for lymph node status in primary cervical cancer: A systematic review and meta-analysis. *CMAJ* **178**(7.):855–62.

Spencer JA, Forstner R, Cunha TM, et al. 2010. ESUR guidelines for MR imaging of the sonographically indeterminate adnexal mass: An algorithmic approach. *Eur Radiol* **20**(1):25–35.

Thomassin-Naggara I, Aubert E, Rockall A, et al. 2013. Adnexal masses: Development and preliminary validation of an MR imaging scoring system. *Radiology.* **267**(2):432–43.

Tsili AC, Tsampoulas C, Argyropoulou M, et al. 2008. Comparative evaluation of multidetector CT and MR imaging in the differentiation of adnexal masses. *Eur Radiol* **18**(5):1049–57.

Valentin L, Ameye L, Savelli L, et al. 2011. Adnexal masses difficult to classify as benign or malignant using subjective assessment of gray-scale and Doppler ultrasound findings: Logistic regression models do not help. *Ultrasound Obstet Gynecol* **38**(4):456–65.

Whittaker CS, Coady A, Culver L, et al. 2009. Diffusion-weighted MR imaging of female pelvic tumors: A pictorial review. *Radiographics* **29**(3):759–74.

Wu WJ, Yu M., Su HY, et al. 2013. The accuracy of magnetic resonance imaging for preoperative deep myometrium assessment in endometrial cancer. *Taiwan J Obstet Gynecol* **52**(2):210–4.

Yang WT, Walkden SB, Ho S, et al. 1996. Transrectal ultrasound in the evaluation of cervical carcinoma and comparison with spiral computed tomography and magnetic resonance imaging. *Br J Radiol* **69**(823.):610–6.

6 Sigmoidoscopy, cystoscopy, and stenting

Louis J. Vitone, Peter A. Davis, and David J. Corless

PROCTOSCOPY, RIGID AND FLEXIBLE SIGMOIDOSCOPY

Indications

Proctoscopy and sigmoidoscopy form part of the routine examination of patients who present with lower gastrointestinal symptoms and should always be preceded by a digital rectal examination (DRE). DRE is an invaluable part of the clinical examination which may identify rectal tumors in the lower and middle rectum, and may identify pelvic masses in both males and females. It also provides independent clinical assessment relating to the presence of blood, melena, mucus, or pus in the rectum.

Patients presenting with rectal bleeding or a change in bowel habit should undergo either a DRE with rigid sigmoidoscopy followed by (i) barium enema and flexible sigmoidoscopy, or (ii) CT colonography and flexible sigmoidoscopy, or (iii) a colonoscopy. The choice of investigation(s) is not only dependent on a patient's clinical requirement but is also often dictated by available resources and physician/radiologist expertise. In addition, patients presenting with vulvar carcinoma extending to the perineum should have an anorectal assessment. Rigid sigmoidoscopy can be used to assess the distal sigmoid colon and rectum, and is useful in the conservative decompression of a sigmoid volvulus. Similarly, flexible sigmoidoscopy can confirm lesions from the proximal descending colon to the rectum, to obtain tissue biopsy, and in the follow-up of patients who have undergone colonic resections. Sigmoidoscopy remains an important adjunct in the assessment of complex gynecological or pelvic disease and in excluding rectal involvement. Proctoscopy is particularly useful in assessing the anal canal and lower rectum, and has a major diagnostic and therapeutic role in the outpatient assessment of hemorrhoids. In the United Kingdom, physicians performing lower gastrointestinal endoscopy should be familiar with the British Society of Gastroenterology guidelines available for download (https://www.bsg.org.uk/clinical/bsg-guidelines.html) and must undergo the appropriate training in accordance with the Joint Advisory Group on Gastrointestinal Endoscopy (http://www.thejag.org.uk/) available through the National Endoscopy Training Program (http://www.jets.nhs.uk/). In the United States and Britain, gynecologic oncologists often perform these procedures in the operating room as part of an examination under anesthesia to evaluate pelvic disorders.

Preoperative Preparation

Proctoscopy and rigid sigmoidoscopy can be performed in the outpatient department without any special preparation. Bowel preparation in most instances is unnecessary, but in some cases, feces in the rectum may limit views and the advancement of the proctoscope or rigid sigmoidoscope. In these cases, either a glycerin suppository or a phosphate enema can be used prior to the examination. Flexible sigmoidoscopy is usually carried out in the endoscopy suite with or without sedation. Adequate bowel preparation of the left colon and rectum is usually provided by a regimen of clear fluids for 24 hours and either a phosphate enema or, less commonly, one to two sachets of a purgative such as sodium picosulfate taken the previous day.

Instrumentation

Proctoscopy

The proctoscope (Figure 6.1) has an internal obturator aiding insertion with an adjacent light source. There is no requirement to insufflate the rectum with air. After adequate lubrication, it is inserted into the rectum with the obturator in place, until the sphincter resistance is overcome, after which the obturator is removed. The lower rectal mucosa is visualized on slowly withdrawing the proctoscope with attention to the hemorrhoidal cushions, dentate line, and anal epithelium. It is helpful to the physician if the patient is asked to "bear down," as this may help demonstrate prolapsing mucosa and hemorrhoids; the latter can be banded or injected with a sclerosant.

Rigid Sigmoidoscope

The rigid sigmoidoscope (Figure 6.1) is approximately 25 cm long with a 19-mm internal diameter and an internal obturator to aid insertion. It has a detachable eyepiece, which allows instruments to be passed along the shaft, and a circumferential light source. Bellows attached to the distal end are used to insufflate the rectum with air. Newer instruments are disposable, being made of self-lubricating plastic when run under water. Useful appendages are a punch biopsy, grasping forceps, and suction tubing.

Flexible Sigmoidoscope

The flexible sigmoidoscope (Figure 6.2) is 70 to 110 cm long and consists of a control head with eyepiece and controls, a multichannel flexible shaft, and a controllable tip. The flexible shaft contains fiberoptic channels carrying the optics and light source to the visual field, as well as channels for suction, irrigation, and insufflation of the colon and the passage of instruments such as biopsy forceps. Movement of the tip in two planes is produced by pulling wires operated at the control head. The eyepiece can be attached to a video camera and the image viewed on a monitor. The "stack system" is shown in Figure 6.3. Immediately after use, instruments should be washed in fresh disinfectant in accordance with the manufacturers' instructions.

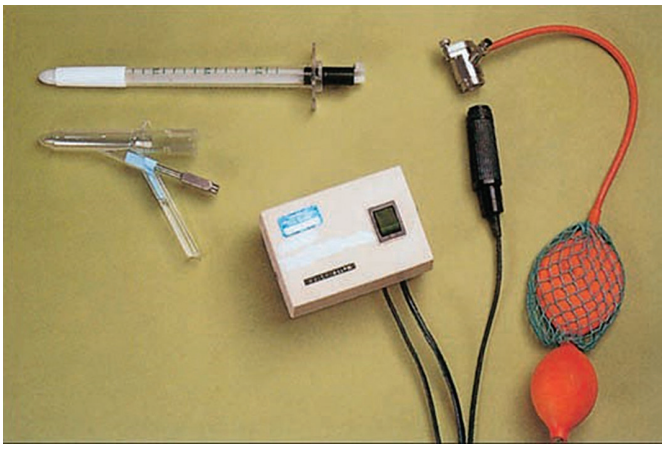

Figure 6.1 Proctoscope and zrigid sigmoidoscope.



Figure 6.2 Flexible sigmoidoscope or colonoscope.

Operative Procedure

Rigid Sigmoidoscope

Rigid sigmoidoscopy can be performed with relative ease in the outpatient clinic. Patients are usually placed in the left lateral (Sims) position with hips and knees flexed and parallel on a couch or bed. The buttocks should ideally overhang the edge of the couch marginally, thus providing better maneuverability of the sigmoidoscope. The more transverse the patient is positioned, the easier the examination will be. The prone knee-elbow or jackknife position, where the patient lays prone in an inverted position, is a less commonly used alternative position. A DRE of the rectum should be performed prior to the sigmoidoscopy.

The light source should always be checked prior to the patient assuming position, by connecting to an appropriate power source. The obturator of the sigmoidoscope should be removed prior to connecting the bellows' tubing with intervening disposable air filter to the sigmoidoscope. The eyepiece window can then be opened and the obturator passed through until the obturator tip protrudes from the sigmoidoscope tip. The sigmoidoscope is held in the right hand, with the left hand holding the buttocks for insertion. An assistant may be required to help with buttock retraction. The instrument is lubricated with a water-based lubricant and inserted into the anal canal, pointing toward the umbilicus with the obturator in place. When the instrument is felt to enter the rectum, it is directed posteriorly and the obturator removed and the eyepiece window closed. Using the bellows, the rectum is gently insufflated with air which allows the sigmoidoscope to be advanced while visualizing the whole circumference of the lumen. As the sigmoidoscope is passed through the rectum at 4 cm from the anus, the rectum angulates posteriorly over the sling formed by puborectalis and into the hollow of the sacrum (Figure 6.4). At this point the sigmoidoscope should be gently directed from the anterior to posterior position. Inspection of the whole mucosa can be achieved by rotating the instrument. Slight angulation of the sigmoidoscope laterally is required to negotiate the rectal valves. At approximately 12 cm from the anal verge, the sacral promontory produces a sharp anterior angulation of the rectum. At this point the sigmoidoscope should be directed anterosuperiorly.



Figure 6.3 A stack system with high-definition video monitor and recorder, light source, video processor, insufflators, and flexible sigmoidoscopy.

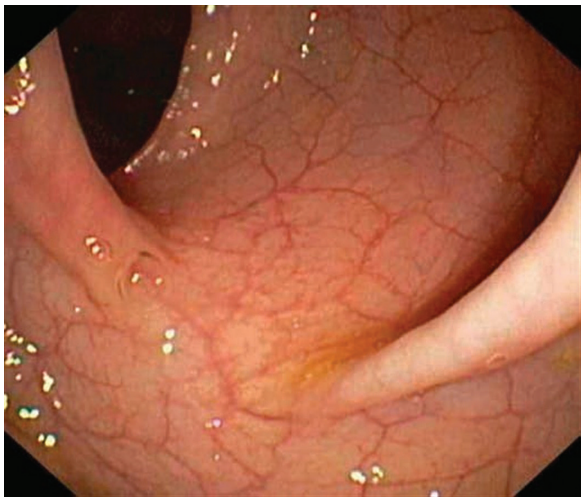

Figure 6.4 View of rectum at sigmoidoscopy.

Negotiation of the instrument at the rectosigmoid junction should be carried out with care; it can be achieved using gentle insufflation and manipulation in order to find the lumen of the sigmoid colon. The best views are often obtained while withdrawing the sigmoidoscope and inspection of the mucosa with particular care around the horizontal rectal folds.

Withdrawal assumes reversal of the above maneuvers. If the patient experiences pain at any point during the procedure, the scope should be withdrawn and consideration given to termination of the examination. Documentation of the position reached should be made in centimeters from the anal verge. The patient's perianal region should be cleansed and the patient returned to a more comfortable position.

Rectal Biopsy

The sigmoidoscope is manipulated so that the lesion is at the tip of the instrument. The glass eyepiece is removed; although this causes deflation of the rectum, the lesion should still be in view. Punch biopsy forceps are passed along the sigmoidoscope and the biopsy is taken under direct vision. The jaws of the biopsy forceps are closed around the lesion and removal is aided by rotation of the closed forceps. Excessive bleeding at the site of the biopsy can easily be controlled with pressure from a cotton-wool swab or occasionally injection of 1 in 1000 adrenaline (epinephrine). Great caution should be taken if considering biopsy 8 cm or more proximal to the anal verge (level of peritoneal reflection), as the risk of perforation of flat lesions is significant with long, cumbersome biopsy forceps.

Polypectomy

Polyps with a long stalk can be removed using a diathermy snare technique through the rigid sigmoidoscope. The polyp is grasped with polyp-holding forceps which have been passed through the loop of a diathermy snare. The snare is then passed over the polyp and closure of the snare during application of diathermy coagulates the stalk. The polyp is then removed by the forceps and the excision site inspected for bleeding. It is important to avoid excessive traction on the forceps because this may result in removal of excess normal mucosa and hence perforation.

Flexible Sigmoidoscope

Patients are placed in the left lateral position on a couch or bed and a DRE is performed. Intravenous sedation and oxygen may be administered via a face mask or nasal prongs and a pulse oximeter attached to the patient. The tip of the sigmoidoscope is lubricated and inserted into the anal canal for a distance of 4 to 5 cm. Initial inspection usually reveals a red blur as the tip of the sigmoidoscope rests against the rectal mucosa. The rectum is gently inflated and the tip position adjusted and withdrawn until the lumen comes into view. It may be necessary to adjust the focus, wash the lens, and suck out any residual fluid or feces to optimize the image. With gentle insufflation and guidance of the tip, the sigmoidoscope is advanced through the lumen and the rectosigmoid junction negotiated under direct vision. If the lumen or movement across the mucosa is not seen, then the sigmoidoscope should be withdrawn until the lumen once again comes into view. Looping of the sigmoidoscope prevents advancement, and in such cases the instrument should also be withdrawn. In most patients, a combination of manipulation of the tip and twisting of the shaft (torque steering) should make it possible to examine the whole left colon. The best views are once again seen on slow withdrawal of the sigmoidoscope, keeping the lumen in view all the way and aspirating as much air as possible. Biopsy can also be performed on withdrawal. The lesion is cleaned by injecting water down the irrigation channel, and biopsy forceps are passed through the instrument port. The biopsy is taken under direct vision, the closure usually performed by an assistant who then removes the forceps while the operator directs the sigmoidoscope and the position of the biopsy. Lesions that macroscopically represent a cancer can be biopsied and marked adjacently with indigo blue dye. This is a helpful adjunct in identifying the tumor and determining resection margins during surgery. However, the latter can be left to a later date, as colonoscopic examination is recommended preoperatively to exclude synchronous colonic lesions. The incidence of perforation with a flexible sigmoidoscope is extremely low, but if the patient complains of excessive pain or discomfort then the examination should cease.

Postoperative Care

No special postoperative care is necessary after routine sigmoidoscopy. After a polypectomy or biopsy, the patient should be observed for signs of excessive bleeding or perforation. Barium enema or CT colonography should not be performed for 10 days after biopsy because of the risk of extravasation of contrast. Patients who have been sedated require postoperative monitoring in a designated recovery area.

CYSTOSCOPY AND STENTING

Indications

Cystoscopy is the single most common urological procedure and is used in the investigation of urinary symptoms. Patients who present with urological symptoms such as frequency, dysuria, and hematuria undergo cystoscopy for the diagnosis of lesions of the urethra and bladder. In addition, cystoscopy may be performed by gynecologic oncologists as part of the International Federation of Gynecology and Obstetrics preoperative staging for cervical carcinoma or where it is suspected that tumors may

involve the bladder and urethra. It can also be used to perform retrograde ureterography to provide x-ray visualization of the ureter and collecting system and the placement of retrograde ureteric stents. Stents provide ureteric drainage and can also be used to identify the position of the ureter. Where retrograde stenting proves impossible, the interventional radiologist may well be able to pass antegrade stents or, failing this, to insert bilateral nephrostomy tubes.

Preoperative Preparation

Rigid cystoscopy is carried out under general anesthesia or IV sedation in the operating theater or properly equipped outpatient facility, with the patient in the lithotomy position. It is important to rule out severe osteoarthritis of the hips which may make examination impossible. Antibiotic prophylaxis is given if there is any evidence or suspicion of a urinary tract infection. Flexible cystoscopy is usually carried out in the endoscopy suite under local anesthesia. Lignocaine (lidocaine) gel inserted into the urethra acts as both lubricant and local anesthetic agent. If possible, the patient should void prior to examination to ensure the bladder is empty.

Instrumentation

Rigid Cystoscope

The rigid cystoscope (Figure 6.5) is composed of a sheath, a bridge, and a telescope. It is 30 cm long. The sheath has both an inlet and an outlet port for irrigation and is attached to the bridge with a watertight lock. The endoscope is introduced into the sheath through the bridge, and is also fitted with a watertight lock. The telescope comprises a hollow metal cylinder containing a series of solid rod lenses and a magnifying eyepiece. In front of the eyepiece is a pillar connected to a fiberoptic light source which transmits light to the visual field. The bridge has one or two other ports for the introduction of biopsy forceps and electrodes, and a director which allows the passage of a ureteric catheter and its advancement into the ureteric orifice. Endoscopes with viewing angles of 0°, 30°, 70°, and 90° are available.

Flexible Cystoscope

The flexible cystoscope (Figure 6.6) is 35 to 40 cm long and consists of a control head with eyepiece and controls, a multichannel flexible shaft, and a controllable tip. The flexible shaft contains fiberoptic channels carrying the optics and light source to the visual field, an irrigation channel, and a biopsy channel. Movement of the tip occurs in one plane and ranges from 145° to 180°, controlled by a deflecting level adjacent to the eyepiece.



Figure 6.5 Rigid cystoscope.



Figure 6.6 Flexible cystoscope.

Operative Procedure

Rigid Cystoscope

The patient is placed on the operating table in the lithotomy position. The cystoscope sheath is lubricated and introduced into the urethra. The female urethra is about 4 cm long and has a relatively uniform caliber from the meatus to the bladder outlet. Upon entering the bladder, the telescope is removed to allow the residual urine and irrigant to drain from the bladder. This may be sent for cytological and bacteriological analysis. Approximately 50 mL of saline is inserted, and the fundus of the bladder is identified by finding the air bubble. With incomplete distension, the bladder mucosa appears rugated, but as the irrigant fluid distends the bladder the mucosa becomes smooth. The ureteric orifices are visualized on the interureteric ridge at the superolateral corners of the trigone (Figure 6.7). By regular sweeping of the cystoscope backward and forward and rotation of the endoscope, the entire bladder mucosa can be visualized. Views of the anteroinferior bladder are obtained by suprapubic compression with the hand. At the completion of the examination, the irrigating fluid is evacuated from the bladder by removing the telescope, and the instrument is slowly withdrawn. A bimanual examination of the pelvis is performed after the procedure.

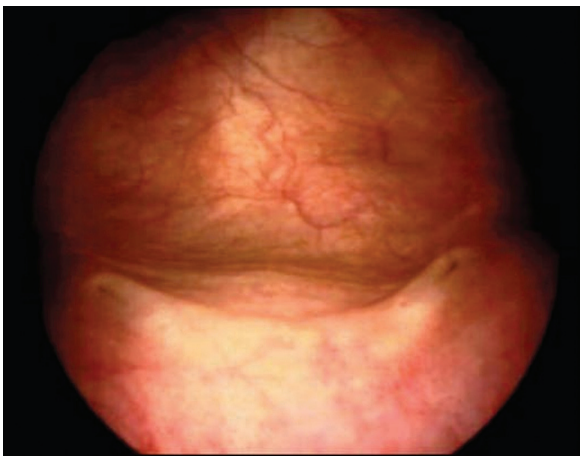

Figure 6.7 Ureteric orifices.

Bladder Biopsy

Bladder biopsy (Figure 6.8) is the procedure most commonly performed during cystoscopy. Biopsy forceps are introduced down the cystoscope sheath via a port in the bridge, sometimes together with a diathermy wire. This allows cup biopsies of the mucosa to be taken. If required, the biopsy sites are then cauterized with diathermy to prevent excessive bleeding.

Ureteric Catheterization and Stenting

The instrumentation and stenting of ureters should only be performed by clinicians such as urologists or gynecologic oncologists, since it is easy to damage the ureteric orifices and ureters. Ureteric catheterization and the placement of double J stents are achieved with the 30° telescope. There is a special port for the introduction of the stents, which can be directed toward the ureteric orifices. A floppy-tipped, Teflon-coated guide wire is first placed into the ureteric orifice and advanced under fluoroscopic control into the renal pelvis. The double J stent is slid over the guidewire through the channel of the cystoscope and into the ureter (Figure 6.9). The stent is radio-opaque and its position is monitored by fluoroscopic control. Excessive force used in insertion of the guidewire or stent should be avoided. The proximal and distal ends curl to form a J shape when they are correctly placed in the renal pelvis and bladder, respectively.

Flexible Cystoscope

The patient is placed on the operating table or bed in the "frog-leg" position. The cystoscope is lubricated and introduced into the urethra. The end of the cystoscope is passed into the bladder and deflected upward. The midline of the anterior bladder is examined by withdrawing the instrument until the bladder outlet is encountered. The cystoscope is then pushed back into the bladder, rotated 30°, and withdrawn again. This process is continued until the entire bladder has been inspected. Biopsy of the bladder mucosa can also be achieved by the passage of biopsy forceps down the instrumental channel of the cystoscope.



Figure 6.8 Bladder biopsy.

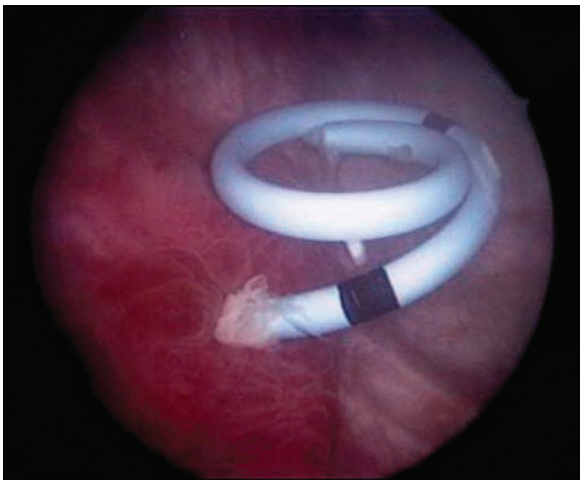

Figure 6.9 Distal end of a double J stent.

Postoperative Care

No special postoperative measures are needed. Patients should be given general precautions including the recognition of early signs and symptoms of an infection.

ACKNOWLEDGMENTS

The authors thank Daniel Wallaker and Hayley Kellett of Olympus Medical, UK, for their assistance in providing some of the images included in this chapter and Dr Laura Wilson, F2 General Surgery, Leighton Hospital, UK, for proofreading the manuscript.

BIBLIOGRAPHY

Calne RY, Pollard SG. 1992. *Operative Surgery*. London: Gower.

Carter DC, Russell RCG, Pitt HA. 1996. *Atlas of General Surgery*. 3rd ed. London: Chapman & Hall.

Corman ML. 2012. *Colon and Rectal Surgery*, 6th ed. Philadelphia, PA: Lippincott, Williams & Wilkins.

Cotton PB, Williams CB. 2013. *Practical Gastrointestinal Endoscopy*, 7th ed. Oxford: Blackwell. Jackson E, Fowler JR. 1992. *Urologic Surgery*. Mastery of Surgery Series. New York: Little, Brown.

Reuter HJ. 1987. *Atlas of Urological Endoscopy: Diagnosis and Treatment*. New York: Thieme.

7 Tumor markers

James Dilley and Usha Menon

INTRODUCTION

A tumor marker is defined as a molecule or substance produced by or in response to neoplastic proliferation, which enters the circulation in detectable amounts. It indicates the likely presence of cancer or provides information about its behavior. Since the description of Bence-Jones proteins well over a century ago, a variety of substances have been investigated as potential tumor markers, and advances in molecular biology and technology continually add to this list.

Tumor markers can be broadly classified into tumor-specific antigens and tumor-associated antigens. Two examples of strictly tumor-specific antigens are the idiotypes of immunoglobulins of B cell tumors and certain neo-antigens of virus-induced tumors. The vast majority of tumor markers are in reality tumor-associated antigens. In many cases, they are initially described as highly tumor specific with subsequent studies uncovering their presence in multiple cancers and in normal adult or fetal tissues. On the basis of size, tumor-associated antigens can be divided into low-molecular weight tumor markers (approximately <1000 Daltons) and macromolecular tumor antigens. It is the macromolecular tumor markers that form the largest subgroup and have been most useful in the clinical management of cancer.

A marker's performance depends on its sensitivity (proportion of cancers detected by a positive test) and specificity (proportion of those without cancer identified by a negative test), as well as the prevalence of the disease being tested in a particular population. An ideal tumor marker should have a 100% sensitivity, specificity, and positive predictive value. However, in practice such a marker does not exist. As the majority of markers are tumor-associated rather than tumor-specific, and are elevated in multiple cancers, benign and physiological conditions, they lack specificity. In addition, varying sensitivity means that a normal result may not exclude malignancy. Hence, in most diseases, tumor markers contribute to differential diagnosis but are not themselves diagnostic. They may also have an important role to play in screening, surveillance, predicting prognosis, and determining therapeutic efficacy.

A wide variety of macromolecular tumor antigens, including enzymes, hormones, receptors, growth factors, biological response modifiers, and glycoconjugates have been investigated as potential tumor markers. Despite significant research, the number of clinically useful markers is limited. This is related to a variety of design issues both pre-analytical, such as selection bias and control matching, analytical, such as poor reproducibility, and post-analytical, such as statistical overfitting (Diamandis 2010, Jacobs and Menon 2011). As a result, they perform very differently when analyzed in an unbiased population based on prospectively collected samples (Cramer et al. 2011, Timms et al. 2014, Zhu et al. 2011). To remedy this, there is a push to adopt a standardized approach to biomarker studies, which includes separate roadmaps for biomarker development, depending on the application, and clinical validation where possible using a prospective specimen collection and retrospective blinded evaluation (PRoBE) design (Pepe et al. 2008). In addition, reporting recommendations, such as REMARK for tumor marker prognostic studies (Altman 2012, Mcshane et al. 2005) and STARD for tests of diagnostic accuracy (Bossuyt et al. 2003, Korevaar et al. 2014) have been proposed to overcome significant past reporting deficiencies in the published literature.

The focus of this chapter is largely limited to tumor markers that are detectable in the blood and are clinically relevant to female genital tract malignancies.

OVARIAN AND FALLOPIAN TUBE CANCER

Ovarian cancer (OC) represents 1.7% of total incident cancers in women worldwide (Ferlay et al. 2012). The lifetime risk for developing OC is approximately 1% to 2%. Epithelial ovarian cancer (EOC) accounts for around 80% to 90% of all OC (CRUK 2011). EOC is a diverse group of tumors that can be classified based upon morphological and molecular features (Kurman and Shih 2010). Type I are thought to originate from borderline tumors and include low-grade serous, low-grade endometrioid, clear cell, mucinous, and transitional (Brenner) carcinomas. Type II include high-grade serous carcinoma (HGSC), undifferentiated carcinoma, and malignant mixed mesodermal tumors (carcinosarcoma). These are highly aggressive, evolve rapidly, and almost always present in advanced stage (Kurman and Shih 2010). HGSC is thought to originate from fallopian tube or cortical inclusion cysts related to fallopian tube epithelium (Nik et al. 2014). HGSC accounts for approximately 75% of OCs and over 90% of all deaths (Cho and Shih 2009, Nik et al. 2014). HGSC is more common in older women, with mucinous and endometrioid EOC, germ cell, and granulosa cell/sex-cord tumors more common in the reproductive age group.

Tumor Markers in Ovarian Cancer

Only a few tumor markers have been validated for clinical use, with the best known among them being cancer antigen 125 (CA125). More recently, serum HE4 has been approved for use in EOC. The indications for use are detailed below.

CA125

CA125 was first described by Bast in 1981. It is a 200-kd glycoprotein recognized by the OC125 murine monoclonal antibody (Bast et al. 1981). The CA125 structure includes two major antigenic domains: domain A (binds monoclonal antibody OC-125) and domain B (binds monoclonal antibody M11) (Nustad et al. 1996). The present second-generation heterologous CA125-II

assay incorporates M11 and OC125 antibodies, while the original homologous assay was with OC125 alone. A number of CA125 assays which correlate well with each other are currently in clinical use (Davelaar et al. 1998).

CA125 is widely distributed in adult tissues and lacks specificity for OC. Although the exact cutoff might vary depending on the commercial assay, the cutoff is equivalent to the original cutoff of 35 U/mL, which is the 99th centile in a distribution of CA125 values in 888 healthy men and women (Bast et al. 1983). However, CA125 values can show wide variation, with lower levels (20 U/mL) found in postmenopausal women (Alagoz et al. 1994, Bon et al. 1996, Bonfrer et al. 1997, Zurawski et al. 1988). Levels are raised in pregnancy, with peak values occurring in the first trimester (112 U/mL, 65 U/mL correspond to 99th and the 96th centile, respectively) (El-Shawarby et al. 2005, Sarandakou et al. 2007) and postpartum (Spitzer and Kaushal 1998), and return to normal by 10 weeks after delivery (Spitzer and Kaushal 1998). Menstruation (Grover et al. 1992) as well as benign gynecological conditions (pelvic inflammatory disease, fibroids, and endometriosis) increase CA125. Higher values are reported for Caucasian compared to African or Asian women (Pauler et al. 2001). Caffeine intake, hysterectomy, and smoking in some (Pauler et al. 2001) but not all reports (Green et al. 1986) were associated with lower CA125 levels (Pauler et al. 2001). Non-gynecological conditions (tuberculosis, cirrhosis, ascites, hepatitis, pancreatitis, peritonitis, pleuritis) and other cancers (breast, pancreas, lung, and colon cancer) can also cause an elevated CA125.

Raised levels were found in 25% of 59 stored serum samples collected 5 years before OC diagnosis (Zurawski et al. 1988), suggesting that CA125 is elevated in preclinical disease. An elevated CA125 (>35 U/mL) has been found in 85% of EOC (Canney et al. 1984, Zurawski et al. 1988), 50% Stage I, and >90% Stage II–IV cancer (Jacobs and Bast 1989). CA125 levels are more frequently elevated in serous cancers as compared to mucinous/borderline tumors (Jacobs and Bast 1989, Tamakoshi et al. 1996, Vergote and Bormer 1987).

Human Epididymis Protein 4

Human epididymis protein 4 (HE4), is a glycoprotein found in epididymis epithelium. Increased gene expression of HE4 (WFCD2) and elevated serum levels have been reported in ovarian (Drapkin et al. 2005, Grisaru et al. 2007), as well as lung, breast, bladder, ureter transitional cell, pancreatic, and endometrial cancers (Galgano et al. 2006, Huhtinen et al. 2009). Serum HE4 levels are not increased in endometriosis (Huhtinen et al. 2009, Montagnana et al. 2009), and this results in fewer false positives compared to CA125 in differential diagnosis of adnexal masses (Heliström et al. 2003). HE4 levels appear to be lower in the Asian population (Park et al. 2012), and are decreased in pregnancy. The normal cutoff (95th centile) is 89 pmol/L and 128 pmol/L for premenopausal and postmenopausal women, respectively (Moore et al. 2012). Above the age of 40, serum HE4 concentrations rise, with dramatic changes seen in women above 55, leading to the recommendation that age-specific reference ranges be used (Urban et al. 2012). It has been reported to be elevated in over 50% of OC patients whose tumors do not express CA125 (Moore et al. 2008).

Indications for Use of Tumor Markers

Screening

Serum CA125 continues to be investigated as a screening tool in clinical trials. In the ovarian screening arm of the Prostate Lung Colorectal and Ovarian Cancer Screening Trial (PLCO), 78,000 women were randomised to annual screening with TVS and CA125 (interpreted using a cut-off of ≥35 U/mL) or control groups. OC was diagnosed in 212 women (5.7 per 10000 person-years) of whom 118 died (3.1 per 10,000 person-years) in the intervention group. In the control group, 176 (4.7 per 10,000 person-years) women were diagnosed, of whom 100 died (2.6 per 10,000 person-years). There was no difference in mortality (RR, 1.18; 95% CI, 0.82−1.71) with screening. However, screening did result in an increase in invasive medical procedures with its associated risks. Of the 3285 women with false positive results, 1080 underwent surgical follow-up, of which 163 women experienced at least one serious complication (15%) (Buys 2011). This has resulted in reconfirmation that low-risk women should not be screened outside the context of clinical trials (US Preventative Services Task Force 2014).

More recently there has been a move in the context of screening to interpret serum CA125 levels using a more sophisticated approach, incorporating serial pattern of CA125 over time and age (Menon et al. 2005, Menon et al. 2009, Lu et al. 2013). This computerized algorithm, called the risk of ovarian cancer algorithm (ROCA), increases CA125 sensitivity by correctly identifying women with normal but rising levels while improving specificity by classifying women with static but elevated levels as low risk. In the general population UK Collaborative Trial of Ovarian Cancer Screening (UKCTOCS) of 202,638 postmenopausal women, 50,639 women in the multimodal (MMS) arm underwent annual screening with CA125 interpreted using ROCA with second-line tests involving repeat CA125 and transvaginal ultrasound (TVS). The performance characteristics of MMS were encouraging, with sensitivity, specificity, and positive predictive value for detection of primary ovarian/tubal cancers diagnosed within 1 year of screen being 89.4%, 99.8%, and 43.3% on the intial prevalence screen (Menon et al. 2009) and 82.8%, 99.8%, and 24.1%, respectively on incidence screening (Menon et al. 2015). The use of ROCA doubled the number of screen-detected invasive EOC detected during incidence screening compared to a fixed cutoff. Of the 155 women with invasive EOC, the ROCA detected 86.4%, whereas using annual serum CA-125 fixed cutoffs of >35, >30, and >22 U/mL would have identified only 41.3%, 48.4%, and 66.5%, respectively (Menon et al. 2015). This is in keeping with a retrospective analysis of the ovarian screening arm of the Prostate Lung Colorectal and Ovarian Cancer Screening Trial (PLCO) study. At 99% specificity, 20% of cases were identified on average 10 months earlier and at a lower CA125 concentration using a parametric empirical Bayes (PEB) longitudinal algorithm compared to a CA125 cutoff of ≥35 U/mL (Drescher et al. 2013). Recently the mortality results of UKCTOCS were published (Menon et al. 2015). There was a significant stage shift in primary invasive epithelial ovarian/tubal/peritoneal cancers on an intention-to-treat analysis in the multimodal arm compared to no screening (control) arm, with the proportion diagnosed in Stage I, II, IIIA 40% compared ($p < 0{\cdot}0001$) to 26% in the control group.

The 15% average mortality reduction noted on primary analysis was not significant. It consisted of a reduction in mortality of 8% in years 0 to 7 from randomization and 23% for years 7 to 14. The delayed effect on mortality reduction was in keeping with other screening trials. OC-specific mortality was increasing at censorship in the control arm but seemed to have plateaued in the control arm. Additional follow-up is now underway to confirm if there is a definitive mortality reduction (Jacobs et al. 2015).

In women at high risk for familial OC, annual screening with both CA125 and TVS has not been found to be effective (Hermsen et al. 2007). More frequent 3- to 4-monthly screening using the multimodal strategy was undertaken in UK Familial Ovarian Cancer Screening Study (UKFOCSS) Phase 2 as well as the Cancer Genetics Network (CGN) and Gynecological Oncology Group 0199 (Sherman et al. 2014) trials in the United States. Not all of these trial results have been published, but preliminary reports are available from conference proceedings. In the CGN trial, five OCs (following 38 surgeries) were detected in 2343 high-risk women undergoing 3-monthly screening. Four of these were early-stage cancers (Skates et al. 2007). In the larger UKFOCSS study of 4,348 women who underwent 13,728 women-years of screening, 19 cases were diagnosed, of which six were occult cancers found at risk reducing salpingooophorectomy (RRSO) and 13 were screen detected. There were no interval cancers. Fifty-two percent of the iEOC were Stage I/II (Rosenthal et al., 2017). In BRCA mutation carriers, the low incidence of primary peritoneal cancer following RRSO is similar to the general population and does not justify CA125 screening (Chen et al. 2014).

HE4 may have better sensitivity than TVS as a second-line screen (Urban et al. 2011). Results from a small randomized controlled study of semiannual screening involving 208 high-risk women suggested that HE4 could be used as a confirmatory screening test following primary screening using CA125 (Karlan et al. 2014).

Differential Diagnosis and Prognosis

Accurate discrimination between benign and malignant adnexal masses permits women with benign lesions to be managed conservatively or operated by general gynecologists while ensuring women with cancer are triaged to cancer centers for management by multidisciplinary teams and surgery by gynecological oncologists. CA125 using a cutoff of 35 U/mL had a pooled sensitivity and specificity of 78% for differentiating benign from malignant adnexal masses, with higher values achieved in postmenopausal women (Myers et al. 2006).

A variety of modalities have been used to improve CA125 performance. The risk of malignancy index (RMI) is the oldest and most widely used. It is calculated by multiplying the serum CA125 level, an ultrasound based ovarian morphology score (U) and menopausal status (M) (Jacobs et al. 1990) and has a sensitivity of 85% and specificity of 97% (Jacobs et al. 1990). It has been validated in numerous prospective and retrospective studies (Andersen et al. 2003, Aslam et al. 2000, Bailey et al. 2006, Davies et al. 1993, Manjunath et al. 2001, Morgante et al. 1999, Tingulstad et al. 1996, Ulusoy et al. 2007). RMI ≥200 has been shown to be reliable in identifying patients who should undergo further preoperative imaging in a tertiary care setting (Håkansson et al. 2012). RMI sensitivity has been improved by increasing the RMI cutoff (Bailey et al. 2006, Davies et al. 1993) or modifying the RMI calculation (Manjunath et al. 2001). Recent modifications have included RMI IV which includes CA19-9 levels so as to better discriminate between borderline tumors and benign adnexal masses (Alanbay et al. 2012).

In a systemic review of women with suspected gynecologic disease, HE4 demonstrated a higher specificity (93% vs. 78%) and similar sensitivity (79%) to CA125 when distinguishing benign disease from OC (Ferraro et al. 2013). While HE4 and CA125 had similar diagnostic performance for EOC diagnosis, the former may be better at detection of borderline and early-stage cancers (Jacob et al. 2011) and in differentiation of EOC from ovarian metastases of gastrointestinal origin (Stiekema et al. 2015). Combining CA125 with HE4 was found to increase sensitivity while maintaining high specificity, and this has resulted in the development of the risk of ovarian malignancy algorithm (ROMA) (Moore et al. 2008). ROMA was shown to be superior to CA125 alone in the differential diagnosis of a pelvic mass, with an overall sensitivity of 93.8% at a specificity of 74.9% and a negative predictive value of 98% (Moore et al. 2009). In the subgroup of premenopausal women, it achieved a sensitivity of 100% (Moore 2011). A recent 2014 meta-analysis which included 32 studies evaluating the role of CA125, HE4, and ROMA concluded that HE4 performs better than CA125 and ROMA in the premenopausal population, with the reverse being true in the postmenopausal women (Wang et al. 2014). ROMA has been reported to have a higher receiver operating characteristics (ROC) area under the curve (AUC) for Type II EOC than Type I when compared to benign (Kristjansdottir et al. 2013).

OVA1 is a recently FDA-approved diagnostic test of the following five proteomic biomarkers: CA125, transthyretin (prealbumin), apolipoprotein A1, β2 microglobulin, and transferrin. Recent studies from two groups have shown that OVA1 combined with physician assessment had higher sensitivity and net present valus (NPV) than physician assessment alone and CA125 (Ueland et al. 2011, Bristow et al. 2013). These findings seemed to persist when only early-stage cancers were studied (Longoria et al. 2014). OVA1 has not been directly compared to ROMA. However, assimilated studies suggest that sensitivity and negative predictive value are likely to be similar but ROMA has greater specificity (73% vs. 43%) (Nolen and Lokshin 2013). A second-generation OVA1 (CA125, transferrin, apolipoprotein A-1, follicle-stimulating hormone, and HE4) has recently obtained FDA approval. This test provides significantly improved specificity (69% vs. 54%) and PPV (40% vs. 31%) compared to the first generation, while sensitivity (91% vs. 94%) and NPV (97% vs. 97%) remained unchanged. This improvement is of particular value as it decreases the number of benign masses requiring gynecological oncology referral (Coleman et al. 2015).

ADNEX is a recently proposed model that uses CA125, age, and type of gynecology center as well as six ultrasound predictors. It has the ability to discriminate between five types of adnexal tumors (benign, borderline, Stage I cancer, Stage II–IV cancer, and secondary metastatic cancer) and also between benign and all malignant tumors. The model's ability to discriminate between advanced primary and secondary metastatic cancer is attributed to the CA125 level. ADNEX's performance seems to

be similar to or better than logistic regression model 2 (LR2) and simpler (Van Calster et al. 2014), but needs external validation.

Controversy persists on the most appropriate test for differential diagnosis of adnexal masses. Results comparing ROMA versus RMI are conflicting (Moore 2010, Van Gorp et al. 2012). In a recent meta-analysis which evaluated 19 prediction models in 96 validation studies, ultrasound models, simple rules and the LR2, outperformed RMI in diagnostic accuracy, particularly in premenopausal women (Kaijser et al. 2014). A key limitation is that almost all studies were based on women who underwent surgery for adnexal masses, and therefore performance characteristics cannot be accurately extrapolated to include women with adnexal lesions that were managed conservatively.

Prognosis

A detailed literature review of epidemiological studies undertaken up to 2009 concluded that serum CA125 is a strong prognostic factor for OC. Levels are inversely related to progression-free and overall survival. Levels following surgery and during the first three cycles of chemotherapy together with CA125 half-life and nadir have been found to be independent prognostic indicators (Gupta and Lis 2009). This extends to levels in the normal range with pre-maintenance chemotherapy patients with baseline CA125 values ≤10 U/mL or ≤5 U/mL having greater progression-free survival compared to those with higher "normal" levels (Markman et al. 2006, van Altena et al. 2010). A gradual, as opposed to abrupt, rise seems to be associated with longer progression-free and overall survival (Levy et al. 2013).

There is great interest in trying to predict complete cytoreduction. A preoperative CA125 level >500 has been associated with a high risk of suboptimal cytoreduction (Suidan et al. 2014). Other studies have suggested that HE4 (Angioli et al. 2013) or a combination of HE4 and CA125 might be better predictors of surgical outcome (Braicu et al. 2013). A CA125 level of <75 U/mL after the third cycle of neo-adjuvant chemotherapy has recently been reported to independently predict complete cytoreduction at interval debulking surgery (Pelissier et al. 2014).

Monitoring Response to Treatment and Recurrence

Serial serum CA125 forms part of most standard protocols for evaluating response to treatment (Söletormos et al. 2012), although not an integral part of the RECIST (v1.1) criteria (Eisenhauer et al. 2009). Levels correlate with clinical course of EOC and may also be of benefit in women with α-fetoprotein (AFP) and human chorionic gonadotropin (hCG)-negative germ cell tumors (Patterson and Rustin 2006). There is emerging data that HE4 may detect recurrence earlier than CA125 and additionally have a role to play in women whose tumors do not express CA125 (Schummer et al. 2012).

Various CA125-based definitions for recurrence have been suggested, such as 2- to 2.5-fold increase from baseline (Rustin et al. 2001, Tuxen et al. 2001) with an interval of 3 to 4 months (range 1–15 months) between increase and clinical detection of progressive disease (Cruickshank et al. 1991, Tuxen et al. 2001). It is important to highlight that the randomized controlled trial OV05 showed no survival benefit on commencing treatment on the basis of rising CA125 levels in the absence of other indicators of disease recurrence (Rustin et al. 2010).

Carcinoembryonic Antigen

Carcinoembryonic antigen (CEA) is a 180-kDa glycoprotein, initially described as a tumor marker for gastrointestinal, prostate, and lung cancers (Icard et al. 1994). Raised levels have been reported in endometrioid, mucinous, and Brenner tumors (Sölétormos et al. 1996). It is often used to differentiate between EOC and ovarian metastases of gastrointestinal origin (Stiekema et al. 2015). An added benefit is that it is not elevated in benign and inflammatory adnexal masses, and pregnancy and does not differ with menopausal status (Kondalsamy-Chennakesavan et al. 2013).

CA-19-9

CA-19-9 is an monosialoganglioside secreted by mucinous tumors of the gastrointestinal tract, including the pancreas and biliary tree (Pavai and Yap 2003). It is more frequently elevated in mucinous (76%) than serous (27%) EOC (Gocze et al. 1988, Terracciano et al. 2005). Markedly elevated serum levels (>1000 U/mL) may be found in benign mucinous neoplasms as well as in borderline and malignant tumors. Elevated levels cannot be used to predict whether an ovarian mucinous tumor is benign, borderline, or malignant (Kelly et al. 2010).

Alpha-Fetoprotein and Human Chorionic Gonadotropin

AFP (70-kDa glycoprotein) is synthesized initially in the yolk sac and subsequently in the fetal liver and intestine (Gitlin et al. 1972). AFP is increased in pregnancy, benign liver disease, and liver, gastric, pancreatic, colon, and bronchogenic malignancies. Elevated levels are seen in most endodermal sinus/yolk sac ovarian tumors and correlate with the extent of the disease. It is useful in monitoring treatment response and in assessing early recurrences (Parkinson et al. 2011). With regard to other germ cell tumors, increased AFP levels have been reported in 33% to 62% of immature teratomas and 12% of dysgerminoma and embryonal tumors (Kawai et al. 1992, Lu 2005). Beta human chorionic gonadotropin (βhCG) levels are universally raised in the rare ovarian choriocarcinoma and in 5% of patients with dysgerminoma. Mixed germ cell tumor can secrete either, both, or none, depending on the components. In patients with dysgerminoma, an AFP or βhCG level of >100 IU/L indicates the presence of nondysgerminomatous elements (Berek and Hacker 2005). Tumor markers are negative in pure immature teratomas.

Inhibin and Anti-Mullerian Hormone

Inhibin is a heterodimeric glycoprotein with two isoforms: inhibin-A and inhibin-B. Serum inhibin is elevated in ovarian granulosa cell/sex cord/stromal tumors and has a useful role in differential diagnosis and surveillance of these malignancies (Boggess et al. 1997, Geerts et al. 2009, Lappohn et al. 1989). Granulosa cell tumors secrete both inhibin-A and inhibin-B, though the latter is more common (Petraglia et al. 1998). Inhibin is considered more reliable and superior to estradiol E2 in monitoring and predicting recurrence in granulosa cell tumors (Pectasides et al. 2008). AMH is a dimeric glycoprotein, a member of the transforming growth factor-β family, and is produced by the granulosa cell (La Marca et al. 2010). It is more specific for granulosa cell tumors than inhibin, as inhibin may

also increase in some (mucinous) epithelial ovarian tumors (Burger et al. 1996). In patients with elevated inhibin-B and/or AMH levels at initial diagnosis, it can be used during follow-up. Currently, there is no evidence-based preference for inhibin-B or AMH as a tumor marker (Geerts et al. 2009).

Future Tumor Markers

Many published biomarkers are not validated in independent studies, leading to a paucity of clinical useful tests. However, there are some promising potential tumor markers on the horizon. The most exciting are tumor-derived cell-free nucleic acids (DNA and RNA) (Kamat et al. 2010) and circulating tumor cells Ma et al. 2014, Romero-Laorden et al. 2014).

Circulating tumor DNA (ctDNA) is usually detected by sequencing for tumor specific mutations. In HGSC, TP53 mutation are ubiquitous (Ahmed et al. 2010). Forshew et al. (2012) have recently reported detection of high levels of ctDNA using tagged-amplicon deep sequencing (TAm-Seq) for TP53 mutations in 2% to 65% in plasma from patients with advanced OC. Further optimization is required, together with an increase in sensitivity, but this technique does offer the potential of a noninvasive, low-cost, and high-throughput "liquid biopsy." Autoantibodies to tumor-derived proteins, p53, PTPRA, and PTGFR as potential biomarkers for early detection of OC are being investigated (Anderson et al. 2015).

There is also a move to explore OC biomarkers in novel samples. Studies have detected tumor DNA from OC in liquid-base cervical cytology specimens (Kinde et al. 2013). Recent reports suggest sensitivity for detection of OC can be improved by lavage of the the endometrial cavity using a three-way catheter to obtain samples that can then be tested for somatic mutations using massively parallel sequencing (next-generation sequencing) (Maritschnegg et al. 2015).

CERVICAL CANCER

In the UK, approximately 3100 cases and 1000 deaths from cervical cancer occur annually (CRUK 2014). Around two-thirds of cases are squamous cell carcinoma and 15% are adenocarcinoma. Seventy-eight percent of cases are diagnosed in 25- to 64-year-olds, with peak incidence occurring in the 30- to 34-year age group (CRUK 2014). Cervical cancer screening using cytology or HPV DNA testing of cervical specimens is one of the most successful public health interventions in the developed world, and serological tumor markers do not currently play a role. However, a variety of serum markers have been investigated in assessing prognosis, monitoring response to treatment, and detecting recurrence.

Squamous-Cell Carcinoma Antigen

Squamous-cell carcinoma (SCC) antigen (Kato 1977) has two isoforms: SCC1 (neutral isoform) and SCC2 (acidic isoform). Elevated serum levels are more common in women with well (78%) and moderately (67%) differentiated carcinoma than in poorly differentiated tumors (38%) (Crombach et al. 1989), confirming that it is a marker for squamous cell differentiation. Squamous and adenosquamous tumors are more likely to have elevated levels than pure adenocarcinomas (Kawaguchi et al. 2013). SCC levels correlate positively with lymph node metastasis, although a normal level cannot exclude it (Takeda et al. 2002, Yoon et al. 2007).

Serum SCC levels reflect response to treatment, and rising levels often precede recurrence (Gadducci et al. 2007). In a recent study, response to chemotherapy was more accurately predicted by SCC than by MRI, with a combination of the two further improving predictive power (Yin et al. 2013). Persistently elevated or rising post-treatment SCC levels are indicative of disease persistence or progression.

Other Tumor Markers

CEA has low sensitivity (38%) but high specificity (98%) for cervical adenocarcinoma (Borras et al. 1995, Ngan et al. 1996), and levels are reported to correspond with extent of disease (Molina et al. 2005, Yoon et al. 2007). Serum CA125 levels are raised in 20% to 75% of women with cervical adenocarcinoma, and may be useful for monitoring patients (Gadducci et al. 2007). CYFRA 21-1 has been found to be elevated in 34% to 63% of cervical cancer, with higher values reported in adenocarcinoma and late-stage disease (Piao et al. 2015, Pras et al. 2002).

GESTATIONAL TROPHOBLASTIC TUMORS/NEOPLASIA

Gestational trophoblastic disease (GTD) comprises a wide spectrum of disorders, with gestational trophoblastic tumors (GTT) or gestational trophoblastic neoplasia (GTN) representing the malignant end of the spectrum (Ngan and Seckl 2007). The UK incidence is 1 in 387 live births in Asian women and 1 in 752 live births in non-Asian women (Tham et al. 2003). Although GTN may occur after any pregnancy, it is 2000 times more common following a molar pregnancy. Malignant transformation occurs in 16% complete and 0.5% partial molar pregnancies (Ngan and Seckl 2007). Accurate diagnosis is paramount, as it is almost always possible to cure GTN and preserve fertility. Survival rates of 100% and 95% have been obtained for low-risk and high-risk disease, respectively (Froeling and Seckl 2014).

Human Chorionic Gonadotropin

Human chorionic gonadotropin (hCG) is an oncofetal antigen (glycoprotein), which consists of two subunits (α and β) and is normally secreted by the syncytiotrophoblast. While the β-subunit is distinct and responsible for biologic and immunologic specificity, the α-subunit is common to other anterior pituitary hormones. It has a half-life of 24 to 48 hours, though this is much shorter for the individual subunits. In normal pregnancy, βhCG is largely intact and is only hyperglycosylated in the first trimester. However, in trophoblastic disease or cancer, the βhCG can exist in a number of fragments, including nicked hCG, β-core, C-terminal segment, and free β-subunit. Hence in cancer it is important to use hCG assays that detect all forms of βhCG. An inability to detect some hCG variants may lead to false negative test results, and miss detection of active disease or recurrence. Some assays may lead to an increase in false positive results due to cross-reacting heterophile antibodies (Froeling & Seckl 2014). No commercial assay is licensed for use in cancer diagnosis at present. In the UK, a non-commercial rabbit polyclonal antibody is used for assay. Seckl et al. (2010) have recommended use of the Siemens IMMULITE (Deerfield, IL, USA) as the only commercial assay that seems comparably safe to use.

βhCG is an "ideal tumor marker" for GTN, as its levels are universally raised and correlate with tumor burden and therapeutic response. It is very sensitive for small-volume disease, and plays a primary role in the management of GTN. The diagnosis of GTN is dependent on failure of βhCG serum levels to regress following either a normal or abnormal pregnancy. In addition to diagnosis, hCG is an integral part of FIGO staging and risk scoring systems, and is used for monitoring treatment and detecting recurrence (Agarwal et al. 2012, Seckl et al. 2010, Seckl et al. 2013).

Placental site trophoblastic tumors (PSTT) produce low levels of βhCG, and undetectable serum levels do not equate to lack of tumor. Presence of β-core fragment in the urine may aid in the diagnosis of PSTT. In PSTT, serum βhCG is not thought to be helpful in predicting survival (Schmid et al. 2009).

ENDOMETRIAL CANCER

Around 93% of endometrial cancers occur in postmenopausal women. In the reproductive age group it is mainly linked to genetic predisposition (e.g., Lynch syndrome), obesity, or polycystic ovary syndrome. With prolonged life expectancy and rising obesity, the incidence is expected to rise. None of the serum markers have a well-established role in the clinical management of endometrial cancer.

Serum CA125 is elevated in 10% to 34% of patients. Elevated preoperative levels have been found to correlate with advanced stage (Powell et al. 2005), higher grade, increased depth of myometrial invasion, positive peritoneal cytology, and nodal involvement (Chen et al. 2011, Jiang et al. 2015). CA125 levels of >35 U/mL and >105 U/mL in women aged >49 and ≤49 years, respectively, have been reported to be associated with poor survival (Chao et al. 2013). It may be useful in follow-up but evidence is limited (Kurihara et al. 1998, Lo et al. 1997, Otsuka et al. 2010).

Recent studies suggest that preoperative HE4 is better correlated to myometrial invasion and primary tumor diameter than CA125 (Brennan et al. 2014, Kalogera et al. 2012). This may be useful for preoperative risk stratification, allowing identification of patients who may benefit from lymphadenectomy at surgical staging.

VULVAR AND VAGINAL CANCER

Tumors of the vulva and the vagina are uncommon, and only a few studies have described circulating markers in these cancers, which include tissue polypeptide-specific antigen, SCC, and urinary gonadotropin fragment (Carter et al. 1995, Nam et al. 1990, Salman et al.1995). There is currently no role for serological markers in the clinical management of these cancers.

SUMMARY

CA125 remains the most widely investigated and clinically used tumor marker for epithelial OC. As part of the RMI and more recently ADNEX, it plays a crucial role in differential diagnosis of adnexal masses. Newer tests include ROMA, which combines HE4 with CA125, and OVA1, where a further panel of markers has been added to the duo. Serial CA125 measurements are used to monitor treatment and detect recurrence. However, no survival benefit has been reported on commencing treatment on the basis of rising CA125 levels in the absence of clinical recurrence. Multimodal screening using serial CA125 and second-line TVS has been shown in trial to have encouraging performance characteristics for detecting invasive OC. However, it is not currently recommended outside the trial setting, as the mortality impact of screening is not yet available. The most promising tumor markers for future clinical use include tumor-derived DNA and circulating tumor cells. AFP and βhCG are routinely used in germ cell tumors and inhibin and AMH in ovarian granulosa cell/sex cord/stromal tumors.

βhCG is the "ideal tumor marker" for GTN and is integral to diagnosis, staging, and monitoring therapeutic response. Using hCG assays that detect all forms of βhCG is essential in cancer patients to minimize false negative results.

SCC is the commonest tumor marker used for cervical carcinoma. Serum SCC levels in squamous cell carcinoma reflect response to treatment, and rising levels often precede recurrence. Serological markers are currently not used in the routine clinical management of the other gynecological malignancies.

REFERENCES

Agarwal R, Teoh S, Short D, et al. 2012. Chemotherapy and human chorionic gonadotropin concentrations 6 months after uterine evacuation of molar pregnancy: A retrospective cohort study. *Lancet* **379**(9811):130–5.

Ahmed AA, Etemadmoghadam D, Temple J, et al. 2010. Driver mutations in TP53 are ubiquitous in high grade serous carcinoma of the ovary. *J Pathol* **221**(1):49–56.

Alagoz T, Buller RE, Berman M, et al. 1994. What is a normal CA125 level? *Gynecol Oncol* **53**(1):93–7.

Alanbay I, Akturk E, Coksuer H, et al. 2012. Comparison of risk of malignancy index (RMI), CA125, CA 19-9, ultrasound score, and menopausal status in borderline ovarian tumor. *Gynecol Endocrinol* **28**(6):478–82.

Altman DG, McShane LM, Sauerbrei W, et al. 2012. Reporting Recommendations for Tumor Marker Prognostic Studies (REMARK): Explanation and elaboration. *PLoS Med* 9(5): e1001216.

Andersen ES, Knudsen A, Rix P, et al. 2003. Risk of Malignancy Index in the preoperative evaluation of patients with adnexal masses. *Gynecol Oncol* **90**(1):109–12.

Anderson KS, Cramer DW, Sibani S, et al. 2015. Autoantibody signature for the serologic detection of ovarian cancer. *J Proteome Res* **14**(1):578−86.

Angioli R, Plotti F, Capriglione S, et al. 2013. Can the preoperative HE4 level predict optimal cytoreduction in patients with advanced ovarian carcinoma? *Gynecol Oncol* **128**(3):579–83.

Aslam N, Tailor A, Lawton F, et al. 2000. Prospective evaluation of three different models for the pre-operative diagnosis of ovarian cancer. *BJOG* **107**(11):1347–53.

Bailey J, Tailor A, Naik R, et al. 2006. Risk of malignancy index for referral of ovarian cancer cases to a tertiary center: Does it identify the correct cases? *Int J Gynecol Cancer* **16**:Suppl 1, 30–4.

Bast RC, Jr, Feeney M, Lazarus H, et al. 1981. Reactivity of a monoclonal antibody with human ovarian carcinoma. *J Clin Invest* **68**(5):1331–7.

Bast RC, Jr, Klug TL, St John E, et al. 1983. A radioimmunoassay using a monoclonal antibody to monitor the course of epithelial ovarian cancer. *N Engl J Med* **309**(15):883–7.

Berek JS, Hacker NF. 2005. *Nonepithelial Ovarian and Fallopian Tube Cancers. Practical Gynecologic Oncology.* Philadelphia: Lippincott Williams & Wilkins.

Boggess JF, Soules MR, Goff BA, et al. 1997. Serum inhibin and disease status in women with ovarian granulosa cell tumors. *Gynecol Oncol* **64**(1):64–9.

Bon GG, Kenemans P, Verstraeten R, et al. 1996. Serum tumor marker immunoassays in gynecologic oncology: Establishment of reference values. *Am J Obstet Gynecol* **174**(1):107–14.

Bonfrer JM, Gaarenstroom KN, Korse CM, et al. 1997. Cyfra 21-1 in monitoring cervical cancer: A comparison with tissue polypeptide antigen and squamous cell carcinoma antigen. *Anticancer Res* **17**(3C):2329–34.

Borras G, Molina R, Xercavins J, et al. 1995. Tumor antigens CA 19.9, CA 125, and CEA in carcinoma of the uterine cervix. *Gynecol Oncol* **57**(2):205–11.

Bossuyt PM, Reitsma JB, Bruns DE, et al. 2003. Towards complete and accurate reporting of studies of diagnostic accuracy: The STARD initiative. *Br Med J* **326**(7379):41–4.

Braicu EI, Fotopoulou C, Van Gorp T, et al. 2013. Preoperative HE4 expression in plasma predicts surgical outcome in primary ovarian cancer patients: Results from the OVCAD study. *Gynecol Oncol* **128**(2):245–51.

Brennan DJ, Hackethal A, Metcalf AM, et al. 2014. Serum HE4 as a prognostic marker in endometrial cancer—A population based study. *Gynecol Oncol* **132**(1):159–65.

Bristow RE, Smith A, Zhang Z, et al. 2013. Ovarian malignancy risk stratification of the adnexal mass using a multivariate index assay. *Gynecol Oncol* **128**(2):252–9.

Burger HG, Robertson DM, Cahir N, et al. 1996. Characterization of inhibin immunoreactivity in post-menopausal women with ovarian tumours. *Clin Endocrinol* **44**(4):413–8.

Buys SS. 2011. Effect of screening on ovarian cancer mortality: The prostate, lung, colorectal and ovarian (PLCO) cancer screening randomized controlled trial. *JAMA* **305**(22):2295.

Canney PA, Moore M, Wilkinson PM, et al. 1984. Ovarian cancer antigen CA125: A prospective clinical assessment of its role as a tumour marker. *Br J Cancer* **50**(6):765–9.

Carter PG, Iles RK, Neven P, et al. 1995. Measurement of urinary beta core fragment of human chorionic gonadotrophin in women with vulvovaginal malignancy and its prognostic significance. *Br J Cancer* **71**(2):350–3.

Chao A, Tang YH, Lai CH, et al. 2013. Potential of an age-stratified CA125 cutoff value to improve the prognostic classification of patients with endometrial cancer. *Gynecol Oncol* **129**(3):500–4.

Chen Y, Bancroft E, Ashley S, et al. 2014. Baseline and post prophylactic tubal-ovarian surgery CA125 levels in BRCA1 and BRCA2 mutation carriers. *Familial Cancer* **13**(2):197–203.

Chen YL, Huang CY, Chien TY, et al. 2011. Value of pre-operative serum CA125 level for prediction of prognosis in patients with endometrial cancer. *Austral NZ J Obstet Gynaecol* **51**(5):397–402.

Cho KR, Shih I-M. 2009. Ovarian cancer. *Annu Rev Pathol* **4**:287–313.

Coleman RL, Herzog TJ, Chan DW, et al. 2015. Validation of a second-generation multivariate index assay for malignancy risk of adnexal masses. *Am J Obstet Gynecol* **215**(1):82.e1–11.

Cramer DW, Bast RC Jr, Berg CD, et al. 2011. Ovarian cancer biomarker performance in prostate, lung, colorectal, and ovarian cancer screening trial specimens. *Cancer Prevent Res* **4**(3):365–74.

Crombach G, Scharl A, Vierbuchen M, et al. 1989. Detection of squamous cell carcinoma antigen in normal squamous epithelia and in squamous cell carcinomas of the uterine cervix. *Cancer* **1**;63(7):1337–42.

Cruickshank DJ, Terry PB, FW. 1991. The potential value of CA125 as a tumour marker in small volume, non-evaluable epithelial ovarian cancer. *Int J Biol Markers* **6**(4):247–52.

CRUK, 2011. CancerStats Ovarian Cancer—UK CancerStats—Ovarian Cancer—UK., (March). http://info.cancerresearchuk.org/cancerstats.

CRUK. 2014. Cervical Cancer statistics. http://www.cancerresearchuk.org/health-professional/cancer-statistics/statistics-by-cancer-type/cervical-cancer.

Davelaar EM, van Kamp GJ, Verstraeten RA, et al. 1998. Comparison of seven immunoassays for the quantification of CA 125 antigen in serum. *Clin Chem* **44**(7):1417–22.

Davies AP, Jacobs I, Woolas R, et al. 1993. The adnexal mass: benign or malignant? Evaluation of a risk of malignancy index. *Br J Obstet Gynaecol* **100**(10):927–31.

Diamandis EP. 2010. Cancer biomarkers: Can we turn recent failures into success? *J Natl Cancer Inst* **102**(19):1462–7.

Drapkin R, von Horsten HH, Lin Y, et al. 2005. Human epididymis protein 4 (HE4) is a secreted glycoprotein that is overexpressed by serous and endometrioid ovarian carcinomas. *Cancer Res* **65**(6):2162–9.

Drescher CW, Shah C, Thorpe J, et al. 2013. Longitudinal screening algorithm that incorporates change over time in CA125 levels identifies ovarian cancer earlier than a single-threshold rule. *J Clin Oncol* **31**(3):387–92.

Eisenhauer EA, Therasse P, Bogaerts J, et al. 2009. New response evaluation criteria in solid tumours: Revised RECIST guideline (version 1.1). *Eur J Cancer* **45**(2):228–47.

El-Shawarby SA, Henderson AF, Mossa MA. 2005. Ovarian cysts during pregnancy: Dilemmas in diagnosis and management. *J Obstet Gynaecol* **25**(7):669–75.

Ferlay J, Soerjomataram I, Ervik M, et al. 2012. Cancer Incidence and Mortality Worldwide: IARC CancerBase No. 11. Lyon, France: International Agency for Research on Cancer; 2013. GLOBOCAN 2012.

Ferraro S, Braga F, Lanzoni M, et al. 2013. Serum human epididymis protein 4 vs. carbohydrate antigen 125 for ovarian cancer diagnosis: A systematic review. *Biochim Clin* **37**(3):179–189.

Forshew T, Murtaza M, Parkinson C, et al. 2012. Noninvasive identification and monitoring of cancer mutations by targeted deep sequencing of plasma DNA. *Science Translat Med* **4**(136):136ra68–136ra68.

Froeling FEM, Seckl MJ. 2014. Gestational trophoblastic tumours: An update for 2014. *Curr Oncol Rep* **16**(11);408.

Gadducci A, Tana R, Fanucchi A, et al. 2007. Biochemical prognostic factors and risk of relapses in patients with cervical cancer. *Gynecol Oncol* **107**:1 Suppl, 23–6.

Galgano MT, Hampton GM, Frierson HF. 2006. Comprehensive analysis of HE4 expression in normal and malignant human tissues. *Modern Pathol* **19**(6):847–53.

Geerts I, Vergote I, Neven P, et al. 2009. The role of inhibins B and antimullerian hormone for diagnosis and follow-up of granulosa cell tumors. *Int J Gynecol Cancer* **19**(5):847–55.

Gitlin D, Perricelli A, Gitlin GM. 1972. Synthesis of alpha-fetoprotein by liver, yolk sac, and gastrointestinal tract of the human conceptus. *Cancer Res* **32**(5):979–82.

Gocze PM, Szabo DG, Than GN, et al. 1988. Occurrence of CA 125 and CA 19-9 tumor-associated antigens in sera of patients with gynecologic, trophoblastic, and colorectal tumors. *Gynecol Obstet Invest* **25**(4):268–72.

Green PJ, Ballas SK, Westkaemper P, et al. 1986. CA 19-9 and CA 125 levels in the sera of normal blood donors in relation to smoking history. *J Natl Cancer Inst* **77**(2):337–41.

Grisaru D, Hauspy J, Prasad M, et al. 2007. Microarray expression identification of differentially expressed genes in serous epithelial ovarian cancer compared with bulk normal ovarian tissue and ovarian surface scrapings. *Oncology Reports* **18**(6):1347–56.

Grover S, Koh H, Weideman P, et al. 1992. The effect of the menstrual cycle on serum CA 125 levels: A population study. *Am J Obstet Gynecol* **167**(5):1379–81.

Gupta D, Lis CG. 2009. Role of CA125 in predicting ovarian cancer survival—A review of the epidemiological literature. *J Ovarian Res* **2**:13.

Håkansson F, Høgdall EV, Nedergaard L, et al. 2012. Risk of malignancy index used as a diagnostic tool in a tertiary centre for patients with a pelvic mass. *Acta Obstet Gynecol Scand* **91**(4):496–502.

Hellström I, Raycraft J, Hayden-Ledbetter M, et al. 2003. The HE4 (WFDC2) protein is a biomarker for ovarian carcinoma. *Cancer Res* **63**(13):3695–700.

Hermsen BB, Olivier RI, Verheijen RH, et al. 2007. No efficacy of annual gynaecological screening in BRCA1/2 mutation carriers; an observational follow-up study. *Br J Cancer* **96**(9):1335–42.

Huhtinen K, Suvitie P, Hiissa J, et al. 2009. Serum HE4 concentration differentiates malignant ovarian tumours from ovarian endometriotic cysts. *Br J Cancer* **100**(8):1315–9.

Icard P, Regnard JF, Essomba A, et al. 1994. Preoperative carcinoembryonic antigen level as a prognostic indicator in resected primary lung cancer. *Ann Thorac Surg* **58**(3):811–4.

Jacob F, Meier M, Caduff R, et al. 2011. No benefit from combining HE4 and CA125 as ovarian tumor markers in a clinical setting. *Gynecol Oncol* **121**(3):487–91.

Jacobs I, Bast RC, J. 1989. The CA 125 tumour-associated antigen: A review of the literature. *Hum Reprod* **4**(1):1–12.

Jacobs I, Oram D, Fairbanks J, et al. 1990. A risk of malignancy index incorporating CA 125, ultrasound and menopausal status for the accurate preoperative diagnosis of ovarian cancer. *Br J Obstet Gynaecol* **97**(10):922–9.

Jacobs I, Menon U. 2011. The sine qua non of discovering novel biomarkers for early detection of ovarian cancer: Carefully selected preclinical samples. *Cancer Prevent Res* **4**(3):299–302.

Jacobs IJ, et al. 2015. Ovarian cancer screening and mortality in the UK Collaborative Trial of Ovarian Cancer Screening (UKCTOCS): A randomised controlled trial. *Lancet* **6736**(15):1–12.

Jiang T, Huang L, Zhang S. 2015. Preoperative serum CA125: A useful marker for surgical management of endometrial cancer. *BMC Cancer* **15**(1):1–8.

Kaijser J, Sayasneh A, Van Hoorde K, et al. 2014. Presurgical diagnosis of adnexal tumours using mathematical models and scoring systems: A systematic review and meta-analysis. *Hum Reprod Update* **20**(3):449–62.

Kalogera E, Scholler N, Powless C, et al. 2012. Correlation of serum HE4 with tumor size and myometrial invasion in endometrial cancer. *Gynecol Oncol* 124(2):270–75.

Kamat AA, Baldwin M, Urbauer D, et al. 2010. Plasma cell-free DNA in ovarian cancer: An independent prognostic biomarker. *Cancer* **116**(8):1918–25.

Karlan BY, Thorpe J, Watabayashi K, et al. 2014. Use of CA125 and HE4 serum markers to predict ovarian cancer in elevated-risk women. *Cancer Epidemiol Biomarkers Prevent* **23**(7):1383–93.

Kato H, Torigoe T. 1977. Radioimmunoassay for tumor antigen of human cervical squamous cell carcinoma. *Cancer* **40**(4):1621–8.

Kawaguchi R, Furukawa N, Kobayashi H, et al. 2013. Posttreatment cut-off levels of squamous cell carcinoma antigen as a prognostic factor in patients with locally advanced cervical cancer treated with radiotherapy. *J Gynecol Oncol* **24**(4):313–20.

Kawai M, Kano T, Kikkawa F, et al. 1992. Seven tumor markers in benign and malignant germ cell tumors of the ovary. *Gynecol Oncol* **45**(3):248–53.

Kelly PJ, Archbold P, Price JH, et al. 2010. Serum CA19.9 levels are commonly elevated in primary ovarian mucinous tumours but cannot be used to predict the histological subtype. *J Clin Pathol* **63**(2):169–73.

Kinde I, Bettegowda C, Wang Y, et al. 2013. Evaluation of DNA from the Papanicolaou test to detect ovarian and endometrial cancers. *Science Transl Med* **5**(167):167ra4.

Kondalsamy-Chennakesavan S, Hackethal A, Bowtell D, et al. 2013. Differentiating stage 1 epithelial ovarian cancer from benign ovarian tumours using a combination of tumour markers HE4, CA125, and CEA and patient's age. *Gynecol Oncol* **129**(3):467–71.

Korevaar D, Van Enst WA, Spijker R, et al. 2014. Reporting quality of diagnostic accuracy studies: A systematic review and meta-analysis of investigations on adherence to STARD. *Evidence-Based Med* **19**(2):47–54.

Kristjansdottir B, Levan K, Partheen K, et al. 2013. Diagnostic performance of the biomarkers HE4 and CA125 in type I and type II epithelial ovarian cancer. *Gynecol Oncol* **131**(1):52–8.

Kurihara T, Mizunuma H, Obara M, et al. 1998. Determination of a normal level of serum CA125 in postmenopausal women as a tool for preoperative evaluation and postoperative surveillance of endometrial carcinoma. *Gynecol Oncol* **69**(3):192–6.

Kurman R, Shih I. 2010. The origin and pathogenesis of epithelial ovarian cancer—A proposed unifying theory. *Am J Surg Pathol* **34**(3):433–43.

La Marca A, Sighinolfi G, Radi D, et al. 2010. Anti-Mullerian hormone (AMH) as a predictive marker in assisted reproductive technology (ART). *Hum Reprod Update* **16**(2):113–30.

Lappohn RE, Burger HG, Bouma J, et al. 1989. Inhibin as a marker for granulosa-cell tumors. *N Engl J Med* **321**(12):790–3.

Levy T, Weiser R, Boaz M, et al. 2013. The significance of the pattern of serum CA125 level ascent to above the normal range in epithelial ovarian, primary peritoneal and tubal carcinoma patients. *Gynecol Oncol* **129**(1):165–8.

Lo SS, Cheng DK, Ng TY, et al. 1997. Prognostic significance of tumour markers in endometrial cancer. *Tumour Biol* **18**(4):241–9.

Longoria TC, Ueland FR, Zhang Z, et al. 2014. Clinical performance of a multivariate index assay for detecting early-stage ovarian cancer. *Am J Obstet Gynecol* **210**(1):78.e1–9.

Lu KH, GD. 2005. Update on the management of ovarian germ cell tumors. *J Reprod Med* **50**(6):417–25.

Lu KH, Skates S, Hernandez MA, et al. 2013. A 2-stage ovarian cancer screening strategy using the Risk of Ovarian Cancer Algorithm (ROCA) identifies early-stage incident cancers and demonstrates high positive predictive value. *Cancer* **119**(19):3454–61.

Ma X, Xiao Z, Li X, et al. 2014. Prognostic role of circulating tumor cells and disseminated tumor cells in patients with prostate cancer: A systematic review and meta-analysis. *Tumour Biol* **35**(6):5551-60.

Manjunath AP, Pratapkumar, Sujatha K, et al. 2001. Comparison of three risk of malignancy indices in evaluation of pelvic masses. *Gynecol Oncol* **81**(2):225–9.

Maritschnegg E, Wang Y, Pecha N, et al. 2015. Lavage of the uterine cavity for molecular detection of Müllerian duct carcinomas: A proof-of-concept study. *J Clin Oncol* **33**(36):4293–300.

Markman M, Liu PY, Rothenberg ML, et al. 2006. Pretreatment CA-125 and risk of relapse in advanced ovarian cancer. *J Clin Oncol* **24**(9):1454–8.

McShane LM, Altman DG, Suerbrei W, et al. 2005. Reporting recommendations for tumor marker. *J Natl Cancer Inst* **97**(16):1180–4.

Menon U, Skates SJ, Lewis S, et al. 2005. Prospective study using the risk of ovarian cancer algorithm to screen for ovarian cancer. *J Clin Oncol* **23**(31):7919–26.

Menon U, Gentry-Maharaj A, Hallett R, et al. 2009. Sensitivity and specificity of multimodal and ultrasound screening for ovarian cancer, and stage distribution of detected cancers: Results of the prevalence screen of the UK Collaborative Trial of Ovarian Cancer Screening (UKCTOCS). *Lancet Oncol* **10**(4):327–40.

Menon U, Ryan A, Kalso J, et al. 2015. Risk algorithm using serial biomarker measurements doubles the number of screen-detected cancers compared with a single-threshold rule in the United Kingdom collaborative trial of ovarian cancer screening. *J Clin Oncol* **33**(18):2062–71.

Molina R, Filella X, Augé JM, et al. 2005. CYFRA 21.1 in patients with cervical cancer: comparison with SCC and CEA. *Anticancer Res* **25**(3A):1765–71.

Montagnana M, Lippi G, Danese E, et al. 2009. Usefulness of serum HE4 in endometriotic cysts. *Br J Cancer* **101**(3):548.

Moore R. 2011. Evaluation of the diagnostic accuracy of the risk of ovarian malignancy algorithm in women with a pelvic mass. *Obstet Gynecol* **118**(401):280–8.

Moore RG, Brown AK, Miller MC, et al. 2008. The use of multiple novel tumor biomarkers for the detection of ovarian carcinoma in patients with a pelvic mass. *Gynecol Oncol* **108**(2):402–8.

Moore RG, McMeekin DS, Brown AK, et al. 2009. A novel multiple marker bioassay utilizing HE4 and CA125 for the prediction of ovarian cancer in patients with a pelvic mass. *Gynecol Oncol* **112**(1):40–6.

Moore RG, Jabre-Raughley M, Brown AK, et al. 2010. Comparison of a novel multiple marker assay vs the Risk of Malignancy Index for the prediction of epithelial ovarian cancer in patients with a pelvic mass. *Am J Obstet Gynecol* 203:228.e1–6.

Moore RG, Miller MC, Eklund EE, et al. 2012. Serum levels of the ovarian cancer biomarker HE4 are decreased in pregnancy and increase with age. *Am J Obstet Gynecol* **206**(4):1–7.

Morgante G, la Marca A, Ditto A, et al. 1999. Comparison of two malignancy risk indices based on serum CA125, ultrasound score and menopausal status in the diagnosis of ovarian masses. *Br J Obstet Gynaecol* **106**(6):524–7.

Myers ER, Bastian LA, Havrilesky LJ, et al. 2006. Management of adnexal mass. *Evid Rep Technol Assess* **130**(130):1–145.

Nam JH, Chang KC, Chambers JT, et al. 1990. Urinary gonadotropin fragment, a new tumor marker. III. Use in cervical and vulvar cancers. *Gynecol Oncol* **38**(1):66–70.

Ngan HY, Cheung AN, Lauder IJ, et al. 1996. Prognostic significance of serum tumour markers in carcinoma of the cervix. *Eur J Gynaecol Oncol* **17**(6):512–7.

Ngan S, Seckl MJ. 2007. Gestational trophoblastic neoplasia management: an update. *Curr Opin Oncol* **19**(5):486–91.

Nik NN, Vang R, Shih IeM, et al. 2014. Origin and pathogenesis of pelvic (ovarian, tubal, and primary peritoneal) serous carcinoma. *Annu Rev Pathol* **9**:27–45.

Nolen BM, Lokshin AE. 2013. NIH Public Access. *National Institutes of Health*, **17**(3):139–46.

Nustad K, Bast RC, Jr, Brien TJ, et al. 1996. Specificity and affinity of 26 monoclonal antibodies against the CA 125 antigen: First report from the ISOBM TD-1 workshop. International Society for Oncodevelopmental Biology and Medicine. *Tumour Biol* **17**(4):196–219.

Otsuka I, Uno M, Wakabayashi A, et al. 2010. Predictive factors for prolonged survival in recurrent endometrial carcinoma: Implications for follow-up protocol. *Gynecol Oncol* **119**(3):506–10.

Park Y, Kim Y, Lee EY, et al. 2012. Reference ranges for HE4 and CA125 in a large Asian population by automated assays and diagnostic performances for ovarian cancer. *Int J Cancer* **130**(5):1136–44.

Parkinson CA, Hatcher HM, Ajithkumar TV. 2011. Management of malignant ovarian germ cell tumors. *Obstet Gynecol Surv* **66**(8):507–14.

Patterson DM, Rustin GJS. 2006. Controversies in the management of germ cell tumours of the ovary. *Curr Opin Oncol* **18**(5):500–6.

Pauler DK, Menon U, McIntosh M, et al. 2001. Factors influencing serum CA125II levels in healthy postmenopausal women. *Cancer Epidemiol Biomarkers Prev* **10**(5):489–93.

Pavai S, Yap SF. 2003. The clinical significance of elevated levels of serum CA 19-9. *Med J Malaysia* **58**(5):667–72.

Pectasides D, Pectasides E, Psyrri A. 2008. Granulosa cell tumor of the ovary. *Cancer Treat Rev* **34**(1):1–12.

Pelissier A, Bonneau C, Chéreau E, et al. 2014. CA125 kinetic parameters predict optimal cytoreduction in patients with advanced epithelial ovarian cancer treated with neoadjuvant chemotherapy. *Gynecol Oncol* **135**(3): 542–6.

Pepe MS, Feng Z, Janes H, et al. 2008. Pivotal evaluation of the accuracy of a biomarker used for classification or prediction: Standards for study design. *J Natl Cancer Inst* **100**(20):1432–8.

Petraglia F, Luisi S, Pautier P, et al, 1998. Inhibin B is the major form of inhibin/activin family secreted by granulosa cell tumors. *J Clin Endocrinol Metab* **83**(3):1029–32.

Piao X, Kong TW, Chang SJ, et al. 2015. Pretreatment serum CYFRA 21-1 level correlates significantly with survival of cervical cancer patients: A multivariate analysis of 506 cases. *Gynecol Oncol* **138**(1):89–93.

Powell JL, Hill KA, Shiro BC, et al. 2005. Preoperative serum CA-125 levels in treating endometrial cancer. *J Reprod Med* **50**(8):585–90.

Pras E, Willemse PH, Canrinus AA, et al. 2002. Serum squamous cell carcinoma antigen and CYFRA 21-1 in cervical cancer treatment. *Intl J Radiat Oncol Biol Physics* **52**(1):23–32.

Romero-Laorden N, Olmos D, Fehm T, et al. 2014. Circulating and disseminated tumor cells in ovarian cancer: A systematic review. *Gynecol Oncol* **133**(3):632–9.

Rosenthal AN, Fraser L, Philpott S, et al. 2013. Final results of 4-monthly screening in the UK Familial Ovarian Cancer Screening Study (UKFOCSS Phase 2). *J Clin Oncol* **31**:Suppl, Abstact 5507.

Rosenthal, AN, Fraser, LSM, Philpott, S, et al. 2017. Evidence of stage shift in women diagnosed with ovarian cancer during phase II of the United Kingdom familial ovarian cancer screening study. *J Clin Oncol* **35**(13):1411–20.

Rustin GJ, Marples M, Nelstrop AE, et al. 2001. Use of CA-125 to define progression of ovarian cancer in patients with persistently elevated levels. *JCO* **19**(20):4054–57.

Rustin GJ, van der Burg ME, Griffin CL, et al. 2010. Early versus delayed treatment of relapsed ovarian cancer (MRC OV05/EORTC 55955): A randomised trial. *Lancet* **376**(9747):1155–63.

Salman T, el-Ahmady O, Sawsan MR, et al. 1995. The clinical value of serum TPS in gynecological malignancies. *Int J Biol Markers* **10**(2):81–6.

Sarandakou A, Protonotariou E, Rizos D. 2007. Tumor markers in biological fluids associated with pregnancy. *Crit Rev Clin Lab Sci* **44**(2):151–78.

Schmid P, Nagai Y, Agarwal R, et al. 2009. Prognostic markers and long-term outcome of placental-site trophoblastic tumours: A retrospective observational study. *Lancet* **374**(9683):48–55.

Schummer M, Drescher C, Forrest R, et al. 2012. Evaluation of ovarian cancer remission markers HE4, MMP7 and Mesothelin by comparison to the established marker CA125. *Gynecol Oncol* **125**(1):65–9.

Seckl MJ, Sebire NJ, Fisher RA, et al. 2013. Gestational trophoblastic disease: ESMO Clinical Practice Guidelines for diagnosis, treatment and follow-up. *Ann Oncol* **24**: Suppl 6:vi39–50.

Seckl MJ, Sebire NJ, Berkowitz RS. 2010. Gestational trophoblastic disease. *Lancet* **376**(9742):717–29.

Sherman ME, Piedmonte M, Phuong L, et al. 2014. Pathologic findings at risk-reducing salpingo-oophorectomy: Primary results from Gynecologic Oncology Group Trial GOG-0199. *J Clin Oncol* **32**(29):3275–83.

Skates SJ DCW, Isaacs C, Schildcraut JM, et al. 2007. A prospective multicenter ovarian cancer screening study in women at increased risk. Chicago, IL: American Society of Clinical Oncology. *J Clin Oncol* 276.

Söletormos G, Duffy MJ, Bonfrer H, et al. 2012. European Group of Tumor Markers (EGTM) guidelines for use of biomarkers in gynecological cancer. http://www.egtm.eu/information_for_patients/gynecological_cancer (accessed 5 August 2016).

Sölétormos G, Nielsen D, Schiøler V, et al. 1996. Tumor markers cancer antigen 15.3, carcinoembryonic antigen, and tissue polypeptide antigen for monitoring metastatic breast cancer during first-line chemotherapy and follow-up. *Clin Chem* **42**(4):564–75.

Spitzer M, Kaushal N, Benjamin F. 1998. Maternal CA-125 levels in pregnancy and the puerperium. *J Reprod Med* **43**(4):387–92.

Stiekema A, Boldingh QJ, Korse CM, et al. 2015. Gynecologic oncology serum human epididymal protein 4 (HE4) as biomarker for the differentiation between epithelial ovarian cancer and ovarian metastases of gastrointestinal origin. *Gynecol Oncol* **4**(3):562–6.

Suidan RS, Ramirez PT, Sarasohn DM, et al. 2014. A multicenter prospective trial evaluating the ability of preoperative computed tomography scan and serum CA-125 to predict suboptimal cytoreduction at primary debulking surgery for advanced ovarian, fallopian tube, and peritoneal cancer. *Gynecol Oncol* **134**(3):455–61.

Tamakoshi K, Kikkawa F, Shibata K, et al. 1996. Clinical value of CA125, CA19-9, CEA, CA72-4, and TPA in borderline ovarian tumor. *Gynecol Oncol* **62**(1):67–72.

Takeda M, Sakuragi N, Okamoto K, et al. 2002. Preoperative serum SCC, CA125, and CA19-9 levels and lymph node status in squamous cell carcinoma of the uterine cervix. *Acta Obstet Gynecol Scand* **81**(5):451–7.

Terracciano D, Mariano A, Macchia V, et al. 2005. Analysis of glycoproteins in human colon cancers, normal tissues and in human colon carcinoma cells reactive with monoclonal antibody NCL-19-9. *Oncol Rep* **14**(3):719–22.

Tham BW, Everard JE, Tidy JA, et al. 2003. Gestational trophoblastic disease in the Asian population of Northern England and North Wales. *BJOG* **110**(6):555–9.

Timms JF, Arslan-Low E, Kabir M, et al. 2014. Discovery of serum biomarkers of ovarian cancer using complementary proteomic profiling strategies. *PROTEOMICS - Clinical Applications* **8**(11-12):982–93.

Tingulstad S, Hagen B, Skjeldestad FE, et al. 1996. Evaluation of a risk of malignancy index based on serum CA125, ultrasound findings and menopausal status in the pre-operative diagnosis of pelvic masses. *Br J Obstet Gynaecol* **103**(8):826–31.

Tuxen MK, Sölétormos G, Dombernowsky P. 2001. Serum tumour marker CA 125 in monitoring of ovarian cancer during first-line chemotherapy. *Br J Cancer* **84**:1301–7.

US Preventative Services Task Force, 2014. Final Recommendation Statement: Ovarian Cancer: Screening. http://www.uspreventiveservicestaskforce.org/Page/Document/RecommendationStatementFinal/ovarian-cancer-screening.

Ueland FR, Desimone CP, Seamon LG, et al. 2011. Effectiveness of a multivariate index assay in the preoperative assessment of ovarian tumors. *Obstet Gynecol* **117**(6):1289–97.

Ulusoy S, Akbayir O, Numanoglu C, et al. 2007. The risk of malignancy index in discrimination of adnexal masses. *Int J Gynecol Obstet* **96**(3):186–91.

Urban N, Thorpe J, Karlan BY, et al. 2012. Interpretation of single and serial measures of HE4 and CA125 in asymptomatic women at high risk for ovarian cancer. *Cancer Epidemiol Biomarkers Prevent* **21**(11):2087–94.

Urban N, Thorpe JD, Bergan LA, et al. 2011. Potential role of HE4 in multimodal screening for epithelial ovarian cancer. *J Nat Cancer Inst* **103**(21):1630–4.

van Altena AM, Kolwijck E, Spanjer MJ, et al. 2010. CA125 nadir concentration is an independent predictor of tumor recurrence in patients with ovarian cancer: A population-based study. *Gynecol Oncol* **119**(2):265–9.

Van Calster B, Van Hoorde K, Valentin L, et al. 2014. Evaluating the risk of ovarian cancer before surgery using the ADNEX model to differentiate between benign, borderline, early and advanced stage invasive, and secondary metastatic tumours: Prospective multicentre diagnostic study. *BMJ* **349**:g5920.

Van Gorp T, Veldman J, Van Calster B, et al. 2012. Subjective assessment by ultrasound is superior to the risk of malignancy index (RMI) or the risk of ovarian malignancy algorithm (ROMA) in discriminating benign from malignant adnexal masses. *Eur J Cancer* **48**(11):1649–56.

Vergote IB, Børmer OP, Abeler VM. 1987. Evaluation of serum CA 125 levels in the monitoring of ovarian cancer. *Am J Obstet Gynecol* **157**(1):88–92.

Wang J, Gao J, Yao H, et al. 2014. Diagnostic accuracy of serum HE4, CA125 and ROMA in patients wth ovarian cancer: A meta-analysis. *Tumor Biol* **35**(6):6127–38.

Yin M, Hou Y, Zhang T, et al. 2013. Evaluation of chemotherapy response with serum squamous cell carcinoma antigen level in cervical cancer patients: A prospective cohort study. *PLoS ONE* **8**(1).

Yoon SM, Shin KH, Kim JY, et al. 2007. The clinical values of squamous cell carcinoma antigen and carcinoembryonic antigen in patients with cervical cancer treated with concurrent chemoradiotherapy. *Int J Gynecol Cancer* **17**(4):872–8.

Zhu CS, Pinsky PF, Cramer DW, et al. 2011. A framework for evaluating biomarkers for early detection: Validation of biomarker panels for ovarian cancer. *Cancer Prevent Res* **4**(3):375–83.

Zurawski VR, Jr, Orjaseter H, Andersen A, et al. 1988. Elevated serum CA 125 levels prior to diagnosis of ovarian neoplasia: Relevance for early detection of ovarian cancer. *Intl J Cancer* **42**(5):677–80.

8 Cone biopsy

Giuseppe Del Priore

INTRODUCTION

The cone biopsy—removal of a cone-shaped portion of the cervix—has been performed by gynecologists for decades. Several methods exist for obtaining this specimen. These include electrosurgical techniques, laser, or scalpel method of excision. The electrosurgical techniques referred to as the *loop electrosurgical excision procedure* (LEEP) or *loop excision of the transformation zone* (LETZ) are the most popular. They have several advantages over the other methods, including less immediate bleeding and discomfort. It is therefore possible to perform LEEP in the office without general anesthesia. There is also a technique referred to as a *needle excision of the transformation zone* (NETZ) which can be used in place of cold knife cone biopsy. Although the surgical margins are cauterized for all electrosurgical methods, they still provide reasonable specimens for pathologic interpretation, with no clinically significant limitations. The scalpel and LEEP techniques are also generally equivalent in their clinically significant outcomes (i.e., cure rates). However, the scalpel cone tends to be larger, which is of no particular advantage except perhaps when used in patients with adenocarcinoma of the endocervix. Since this histology may be multifocal, a larger specimen may be more likely to remove all of the lesions. As there may still be, on occasion, the need to perform a scalpel cone biopsy, all gynecologists should be familiar with both techniques.

INDICATIONS

Cone biopsy is indicated for the diagnosis or exclusion of microinvasive cervical cancer as suggested on a presurgical Papanicolaou (Pap) smear or colposcopic punch biopsy. It could also be used to exclude and possibly treat endocervical adenocarcinoma. As mentioned above, a large scalpel cone biopsy or NETZ may be a better option for these women since it is less likely to have a positive margin and thus less likely to need a repeat procedure. Cone biopsy, preferably by LEEP, is also indicated for patients with high-grade squamous epithelial lesions on Pap smear but no identifiable colposcopic lesion, but only after excluding lesions elsewhere such as on the vagina or vulva. Some advocate cone biopsy for larger cancers (e.g., IA2) with separate lymphadenectomy. In these cases, the cone seeks to avoid the morbidity of the parametrectomy of radical surgery.

ANATOMIC CONSIDERATIONS

Vascular Supply

A small descending branch of the uterine artery supplies the cervix. It can usually be found laterally in the vaginal portion of the cervix at the 3 and 9 o'clock positions. Despite its apparent accessible location, lateral stay sutures to occlude these vessels do so in less than half of all cases.

Innervation

The nerves of the cervix arise from the hypogastric plexus. Specific branches from this plexus to the cervix are sometimes known as the uterovaginal plexus and are found in the broad ligament. Even more distal, the uterine cervical ganglion may be identified in the paracervical tissue closest to the cervix. The autonomic sympathetic nerves arise from the sympathetic trunk originating in the nerve roots from T10 to L1. The parasympathetics arise from the roots of S2 to S4.

Muscles Involved

The cervix sits above the urogenital diaphragm and as such does not have any direct muscle connection. Retaining the cervix during a supracervical hysterectomy or removing part of it during a cone biopsy does not have a significant effect on pelvic physiology or prolapse.

Bony Landmarks

The cervix lies roughly in the plane of the ischial spine, being slightly anterior and inferior to it. It is important to consider the bony pelvic outlet when contemplating operating transvaginally on the cervix. For cone biopsies, only the most contracted pelvis would present a significant limitation. Often, cases that seem impossible in the office are found to be feasible during general anesthesia with proper assistance and retraction.

SURGICAL PROCEDURE

Loop Electrosurgical Excision

The LEEP procedure begins with the proper positioning of the patient's legs. The standard office examination table with stirrups is usually sufficient. A speculum that is large enough to hold the vaginal wall away from the cervix should be inserted. In obese patients, the finger of a latex glove with the tip cut off may be used to assist in retraction of the vaginal walls. It is pulled over the speculum in a "condom-like" application. An insulated speculum is not necessary. In fact, if the insulated speculum has an undetected break in its insulation, it may allow for a pinpoint high-energy discharge and patient injury. An uninsulated uncoated speculum would disperse the charge over the entire surface contact area safely. A suction apparatus for evacuating the copious amount of smoke produced is absolutely essential. This may either be built into the speculum or clipped on to a standard one. Hand-held wall suction (e.g., Yankauer) is generally not adequate as it is usually too large to fit into the vagina simultaneously with the LEEP device. A smaller diameter hand-held suction tip may be adequate. Immediately before the actual procedure, colposcopy is used to identify the lesion.

Local anesthesia should be administered circumferentially with a narrow gauge (e.g., ≤27-gauge) reinforced shaft (e.g., Potocky) needle. Larger needles will lead to significantly more bleeding. Any local anesthetic with epinephrine 1:100,000 will help control bleeding during the procedure. Preoperative oral analgesics, including NSAIDs, should be considered. Since water dissipates the electrosurgical current, excess stromal injections may make the procedure difficult. Discomfort from the local injection can be minimized by having the patient cough simultaneously with placing the needle on the surface of the cervix. The movement inferiorly of the cervix during this Valsalva maneuver is usually all that is needed to painlessly enter the cervix. The anesthetic should be administered early to allow sufficient time for it to take effect (Figure 8.1).

Different electrosurgical units have various settings and power sources. The only important parameter is current density at the electrosurgical wire surface. This is the actual energy that the cervix receives and is dependent on the length of the wire loop in contact with the tissue, the diameter or gauge of the wire itself, and the current setting. The highest current density possible should be used to minimize drag through the tissue and consequently, cautery artifact. However, too high a current density will result in the loop wire breaking, much like an incandescent light bulb filament. If this should happen, completing the procedure will be more difficult as the operator will have to begin with a new wire loop in the middle of the specimen or from the opposite side from the first incision starting point. Trial and error using inanimate specimens may be needed to find the maximal power settings depending on the combination of generator and loop wires used. There are several wire configurations available that should be chosen based on anatomic configuration of the lesion and the patient.

After infiltration of the cervix, the operator should choose a loop size and shape that can remove the colposcopically-identified acetowhite lesion with clear margins, but no larger than necessary to avoid excessive cervical damage. However, if the cone is a diagnostic procedure, then the entire transformation zone should be removed.

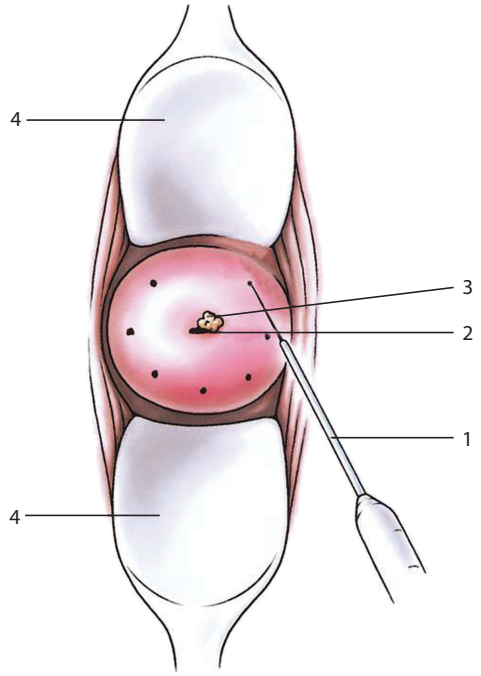

Figure 8.1 1: Reinforced shaft with thin needle; 2: squamocolumnar junction; 3: acetowhite epithelium; 4: speculum blades.

The depth of excision should be dependent upon the position of the transformation zone (TZ). TZ that are completely ectocervical in nature require an excision depth of approximately 10 mm. TZs that have an endocervical component require more depth; i.e., 10- to 15-mm depth, while TZs that are not fully visible, may require 10- to 20-mm depth excision. The future obstetric impact of such excisions should be considered, with increasing depth of excisions being associated with a higher risk of preterm labor (PTL). The relative risk (RR) of PTL with a 10-mm excision is 2, whereas this increases to between 2 and 3 with excisions of between 11 and 15 mm. Excisions between 16 and 20 mm increase RR further to 3.6, while excisions over 20 mm result in a dramatically increased RR at 6.4.

The operator should practice the hand motion to be used before actually turning on the current. Once a comfortable hand motion has been determined, the colposcope, used to identify the lesion and transformation zone, may be removed from the operating field unless it has a very low magnification setting, since using the loop wire under colposcopic vision may be difficult. Once everything has been rechecked, the operator applies the pure cutting current and smoothly passes the loop wire through the cervix, being careful not to touch the vaginal wall. Activating the energy source can be facilitated by using a foot switch instead of a fingertip button on the hand piece. The specimen may be grasped with a forceps and sent to pathology. A sample of the endocervical canal may be obtained at this point using an endocervical curette followed by a cytobrush and sent together to pathology. Alternatively, another smaller cone "top hat" may be obtained with a smaller wire loop LEEP device (Figure 8.2). Although there is usually no immediate bleeding, late rebleeding can be reduced by prophylactically cauterizing the cone base. This should be done using a ball, needle tip, or spatula tip cautery attachment. The current should be set on coagulation at a sufficiently high current setting or "spray" to exceed the capacitance of air. The ball or other suitable tip should then be held a few millimeters from the surface of the cone base to allow the current to arc across to the tissue for hemostasis. A small rim of endocervical canal should be left uncoagulated to allow the transformation zone to evert during healing. After the entire base is cauterized in this manner, ferric subsulfate (Monsel's) solution may also be applied. The patient should be instructed not to place anything in the vagina for at least 2 weeks and call if there are any signs or symptoms of infection. A routine postoperative visit is not necessary, as it rarely uncovers an asymptomatic issue.

Scalpel "Cold Knife" Cone

Colposcopy should be used to identify the lesion. The scalpel cone biopsy does not require a special speculum with smoke evacuator. However, wall suction must be available since considerably more bleeding will be encountered during the procedure. Because the procedure lasts longer than the LEEP and patient cooperation is necessary to deal with the intraoperative bleeding, either general or regional anesthesia is usually required. No thromboembolic prophylaxis is needed. After positioning of the speculum, two lateral stay sutures are placed at approximately the

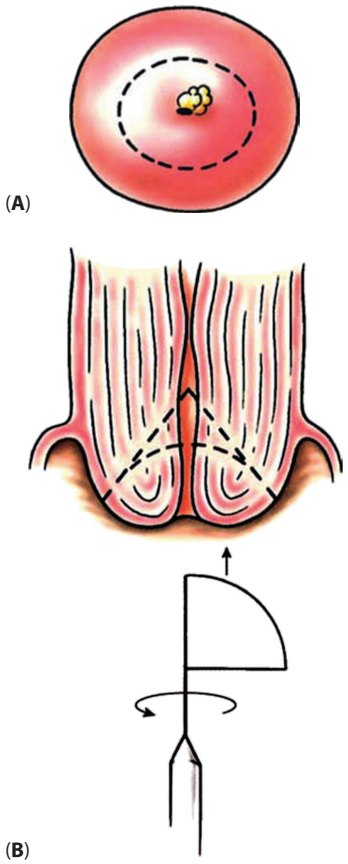

Figure 8.2 (**A**) Clear lateral margins. (**B**) Profile of cone biopsy margins.

3 and 9 o'clock positions. The sutures are placed in a figure-of-eight manner to help hold the cervix and reduce the blood supply by ligation of the cervical branch of the uterine artery. An absorbable suture of 0 or 00 is sufficient. These are held with hemostats attached to the drapes to help draw the cervix down into the lower vagina (Figure 8.3A and B). As with the LEEP circumferential injection of local anaesthetic with Adrenalin should be instilled or epinephrine can be injected for added hemostasis. Starting posteriorly, using a large curved knife handle, the colposcopically identified acetowhite lesion is excised. Again, for diagnostic cones, the entire transformation zone should be removed. The base of the cone may be difficult to separate completely with the scalpel. Instead, curved scissors may be used for the last cut separating the specimen entirely. A sample of the endocervical canal may be obtained at this point using an endocervical curette and cytobrush. Active bleeding may be controlled with cautery or fine 000 absorbable sutures on a small highly curved vascular needle. Prophylactic cautery of the base reduces delayed bleeding better than the occluding "Sturmdorf" sutures which turn the edge of the cervix over the excision base. Care must be taken not to occlude the os during any of these maneuvers. A cotton-tipped swab, placed in the os before any sutures, will help in avoiding this complication. Monsel's solution should be applied after hemostasis for prophylaxis against delayed bleeding. If hemostasis is still a problem, a commercial hemostatic agent, such as sheets of oxidized cellulose, may be used to tamponade the bleeding base and held in place by the lateral stay sutures. These sutures can be brought together over the midline and tied together (Figure 8.4). Systemic antibiotics are not routinely used.

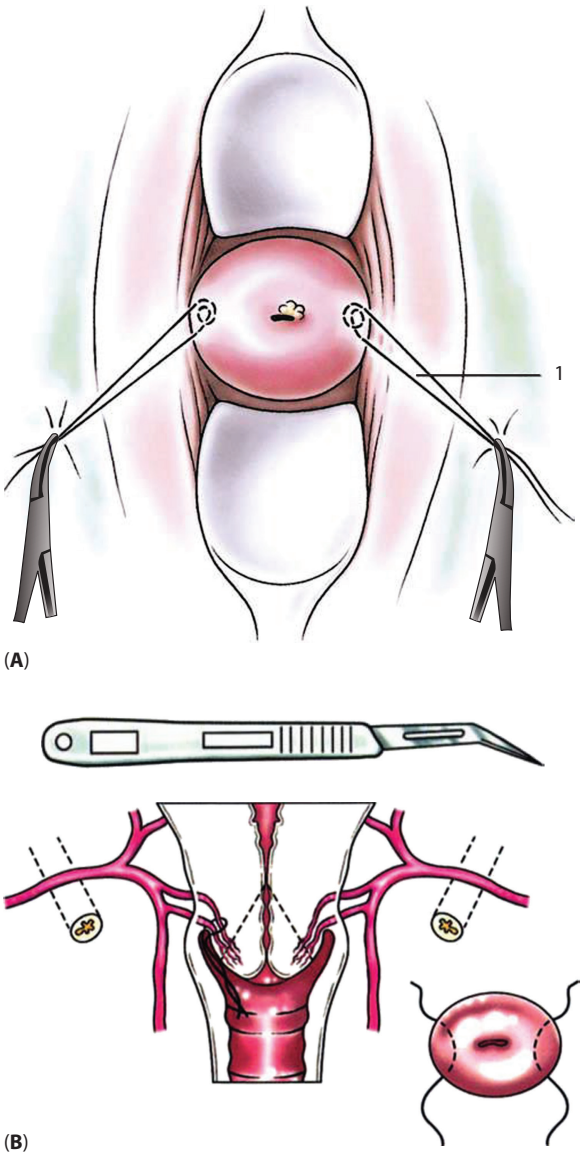

Figure 8.3 (**A**) 1: Hemostat on drape. (**B**) Cone to be excised.

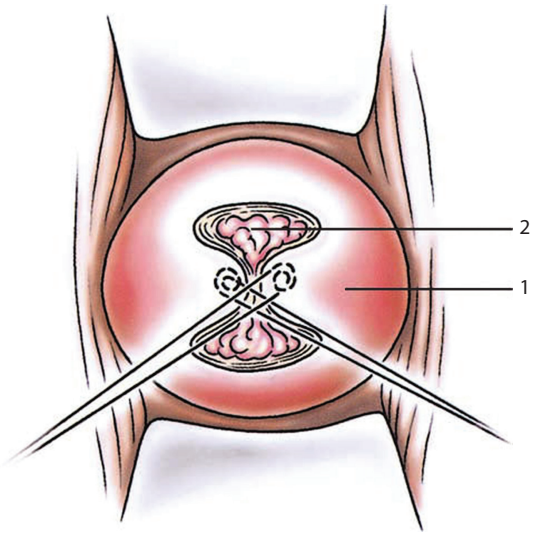

Figure 8.4 1: Ectocervix; 2: hemostatic absorbable packing filling cone base.

9 Radical abdominal hysterectomy

J. Richard Smith, Deborah C.M. Boyle, and Giuseppe Del Priore

INTRODUCTION

Radical abdominal hysterectomy is designed to remove the uterus, cervix, upper third of the vagina, either part or the whole of the parametrium, and the uterosacral and vesicouterine ligaments. In addition, the common iliac, internal iliac, external iliac, obturator, hypogastric, and presacral lymph nodes are removed, as may be the paraaortic nodes.

This surgery is used for the management of stage IA2 and IB1 and IB2 tumors of the uterine cervix. It may be used by some surgeons for the management of stage IIA cervical tumors and occasionally in the management of vaginal cancer. It has been classified by Rutledge as radical abdominal hysterectomy types II and III (Piver et al. 1974). Staging of cervical cancer, carried out preoperatively, is not further discussed in this chapter. The choice of whether to perform this procedure or one of those described in Chapters 8, 9, 10, 26, and 27 depends on the surgeon's preference, with each operation tailored to the needs of the specific patient. The radicality of the planned procedure depends on the characteristics of the tumor.

Prior to surgery, the patient's bowel should be prepared using standard protocol. Consent for the specific procedure, including oophorectomy if planned, should have been obtained.

The procedure described here is an open approach. Many centers will adopt a laparoscopic or robotic approach but the dissection and order of the surgery are the same. Readers are referred to Chapter 28 (Robotic surgery) and Chapter 26 (Laparoscopy).

SURGICAL PROCEDURE

A general anesthetic is administered with or without an epidural anesthetic. The addition of a regional anesthetic allows better pain control postoperatively and facilitates surgery by reducing intraoperative blood loss.

The patient is then placed supine on the operating table. The bladder is catheterized with an indwelling Foley catheter and the vagina packed with a roll of gauze. Some surgeons insert the Foley catheter postoperatively, while others prefer to insert a suprapubic catheter at the end of the procedure. The authors' practice depends on the radicality of the procedure. In cases of stage IIA cervical cancer the vagina may be marked with cutting diathermy 2 to 3 cm away from the vaginal lesion to assist in later ensuring good resection margins.

The abdomen is opened using either a subumbilical, vertical midline incision or a large lower transverse, rectus muscle-cutting incision, dependent on the patient's desire for cosmesis (Figure 9.1). It may be helpful to insert stay sutures to hold the peritoneum to the edges of the transverse skin incision.

After adequate exposure of the pelvis, the lymph nodes of the pelvis, the common iliac nodes, and those above the bifurcation of the aorta are palpated, as is the liver.

The round ligament is then grasped, divided, and ligated close to the pelvic sidewall and the broad ligament opened to expose the retroperitoneal structures including the ureter attached to the medial aspect (Figure 9.2).

The paravesical space is the first of the potential spaces to be developed during surgery (Figure 9.3). This is achieved using blunt dissection with a combination of dissecting scissors and fingers or mounted pledgets. The dissection is commenced medial and slightly inferior to the external iliac vein. The paravesical space is bounded medially by the bladder and obliterated hypogastric artery and caudally by the ventral aspect of the cardinal ligament. The obturator muscle and fossa form the lateral border; this is dissected out later.

The pararectal space is then opened using a similar technique (Figure 9.4). This space is bounded by the rectum medially, the sacrum ventrally, the pelvic sidewall, and internal iliac vessels laterally, and the cardinal ligament anteriorly. This allows the cardinal ligament and parametrium to be directly assessed by placing one's fingers in the newly opened paravesical and pararectal spaces (Figure 9.5).

Some clinicians perform the removal of the uterus first, and others the lymphadenectomy. The choice is purely personal.

The lymphadenectomy is commenced at the bifurcation of the common iliac vessels, excising the loose lymphatic tissue overlying the internal and external iliac arteries and veins (Figures 9.6 and 9.7). This is performed in a caudal direction, having first identified psoas muscle and the genitofemoral and lateral cutaneous nerve of the thigh. The dissection of the external iliac vessels continues caudally until the circumflex iliac vessels are encountered. Dissection in a cephalad direction allows clearance of common iliac and paraaortic nodes. Presacral nodes are also removed (Figure 9.8).

Once the external iliac artery and vein are exposed they can be separated from the underlying tissue laterally. With gentle lateral (Figure 9.9) and/or medial (Figure 9.10) traction on the external iliac vessels the obturator fossa is now exposed. It is often helpful to sweep the external iliac vessels off the pelvic sidewall and approach the obturator fossa from the lateral side (Figure 9.11). Great care must be taken to preserve the obturator nerve, and the dissection always becomes much easier once this structure has been identified (Figures 9.12 and 9.13). Occasionally, the obturator artery and vein may require to be sacrificed to allow adequate dissection of the tissues posterior and lateral to the nerve. The ureter is further dissected from the peritoneum. Sharp dissection is employed to create the vesicouterine and vesicocervical spaces (Figure 9.14). It is important to find the correct tissue plane since this facilitates easier and bloodless dissection. The uterine arteries are clamped, divided, and ligated close to their origins at the internal iliac arteries using either ligatures or hemoclips (Figure 9.15). The ureteric

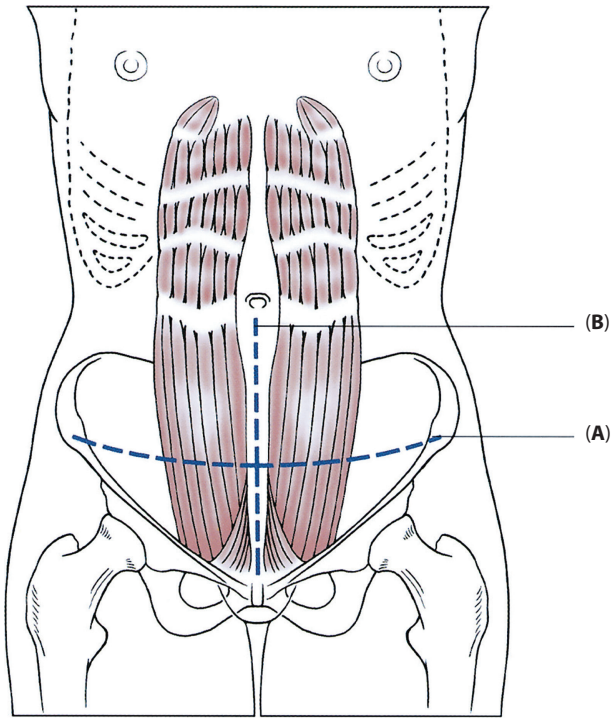

Figure 9.1 Opening the abdomen. (**A**) Low transverse rectus muscle cutting incision. (**B**) Vertical subumbilical incision.

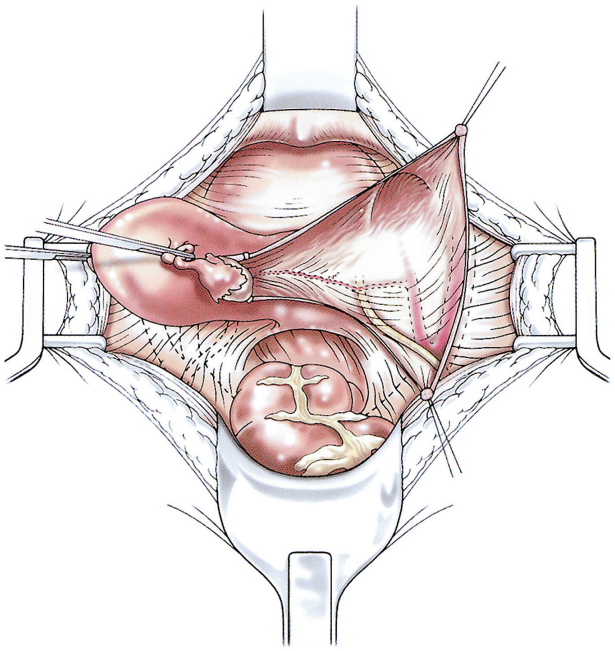

Figure 9.2 The round ligament is divided and the broad ligament opened.

tunnels are then deroofed, allowing exposure of the ureters and their separation from parametrial tissue (Figure 9.16). This can be performed cephalad-to-caudal or vice-versa. Roberts clamps or large hemoclips are helpful in minimizing hemorrhage. Whatever technique is used, bleeding tends to be brisk at this stage.

Harmonic scissors can be very useful at reducing hemorrhage at this stage.

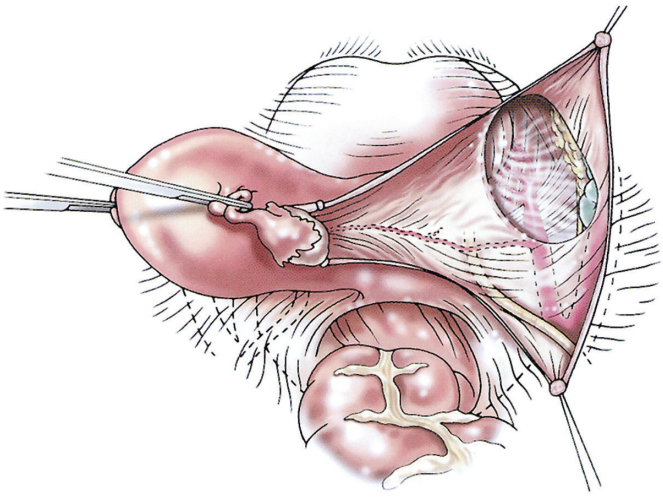

Figure 9.3 Developing the paravesical space.

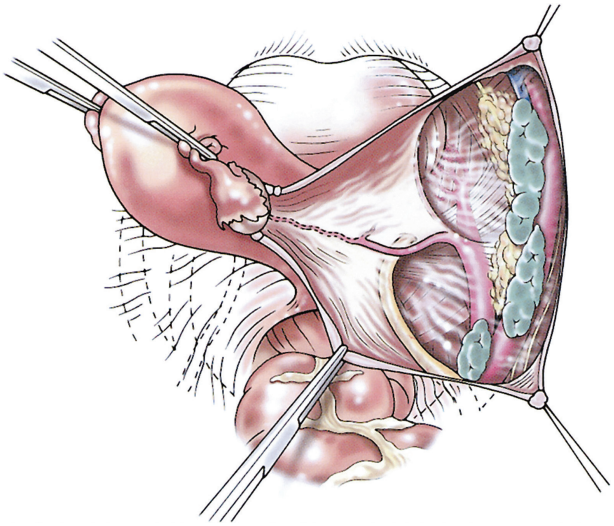

Figure 9.4 Developing the paravesical and pararectal spaces.

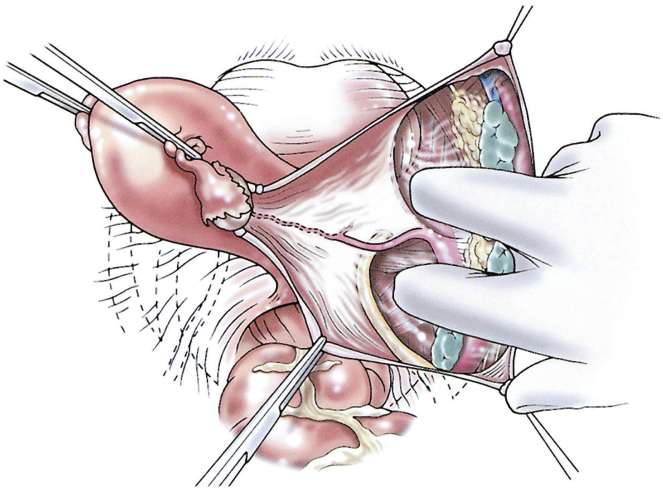

Figure 9.5 Palpating the parametrium directly.

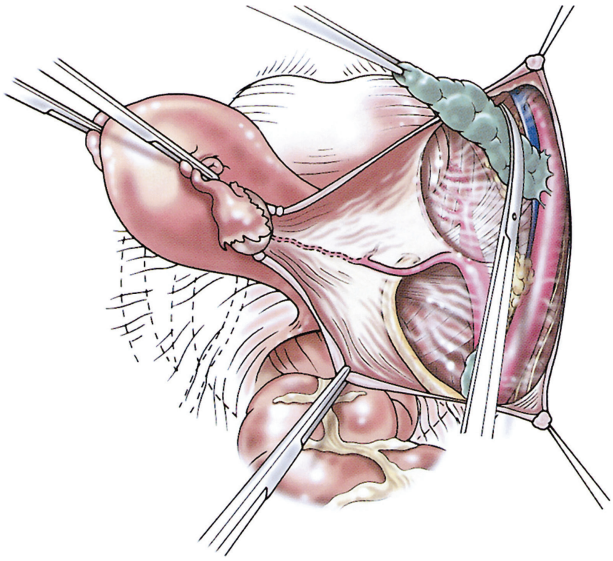

Figure 9.6 Pelvic lymphadenectomy.

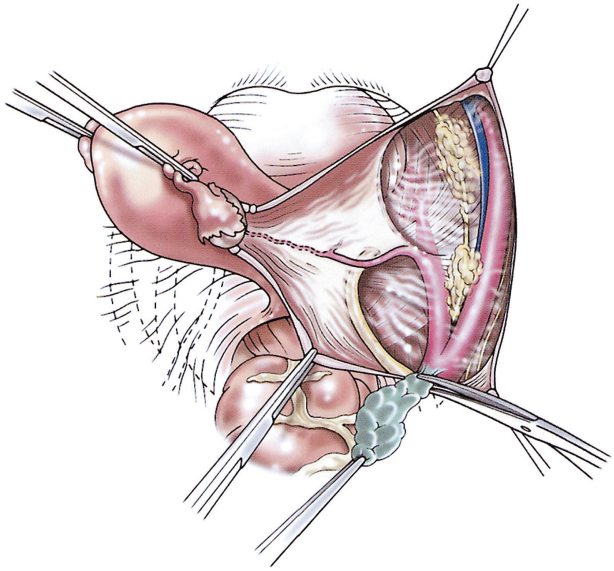

Figure 9.7 Pelvic lymphadenectomy: sidewall dissection.

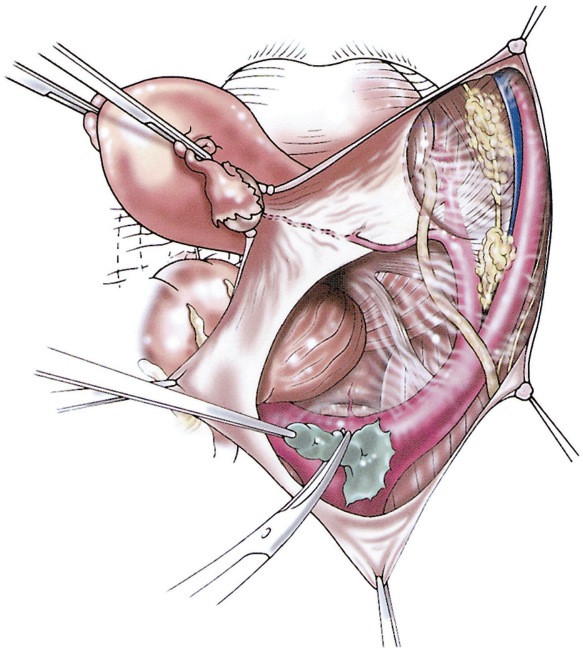

Figure 9.8 Presacral node removal.

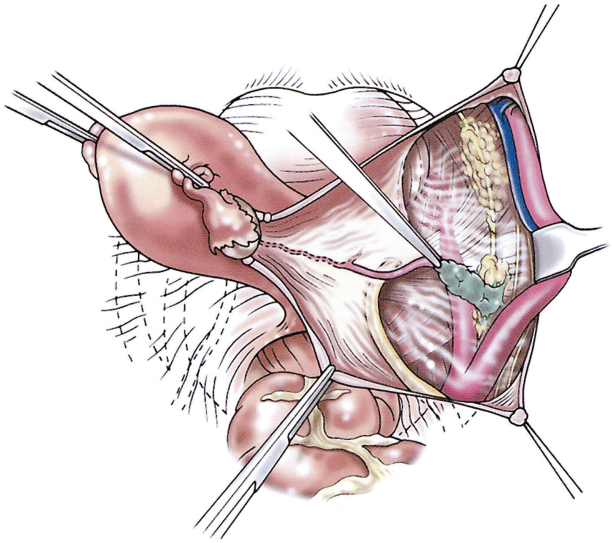

Figure 9.9 Exposure of the obturator fossa. Removal of lymph nodes from the common iliac bifurcation.

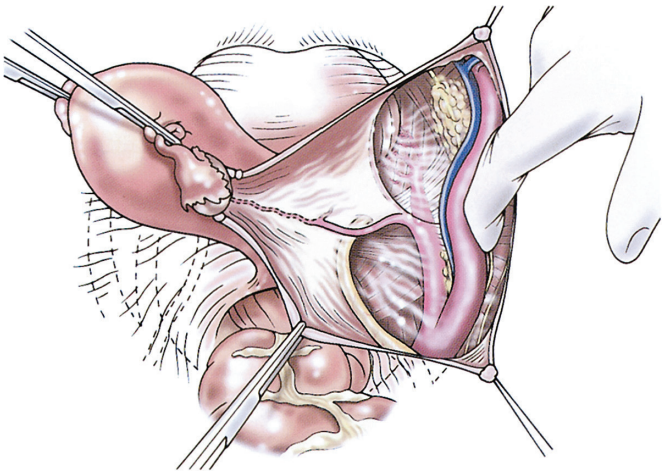

Figure 9.10 Exposure of the obturator fossa: lateral approach.

The pararectal space is further developed from above from between the ureter medially and the internal iliac vessels laterally (Figure 9.17). The boundaries have been described above but the dissection now takes place to the level of the pelvic floor. The rectum is dissected away from the uterus, thus freeing it of its posterior visceral attachments (Figure 9.18). This is best achieved by grasping the rectum between the fingers and lifting it in a cephalad direction and then entering the rectovaginal space by sharp dissection. The rectum is often much higher on the uterus than is at first suspected and this technique minimizes the possibility of inadvertent rectal injury.

Clamping, division, and ligation of the uterosacral ligaments then takes place (Figures 9.19 and 9.20). Alternatively, Harmonic scissors can be used. These can either be performed midway along the ligaments or at the sacrum, depending on the size and nature of the tumor. The cardinal ligaments are then clamped, divided, and ligated, again either halfway between the cervix

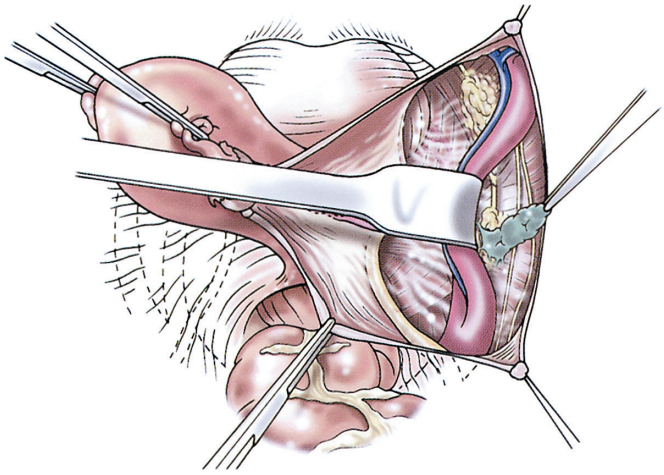

Figure 9.11 Exposure of the obturator fossa. Removal of external iliac lymph nodes from lateral approach.

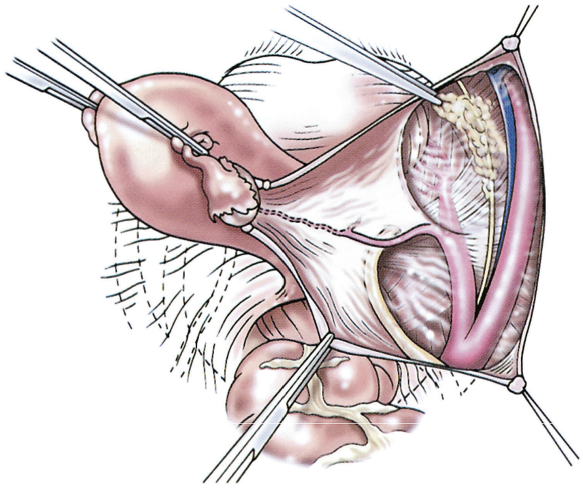

Figure 9.12 Removal of lymph nodes from the obturator fossa around the obturator nerve.

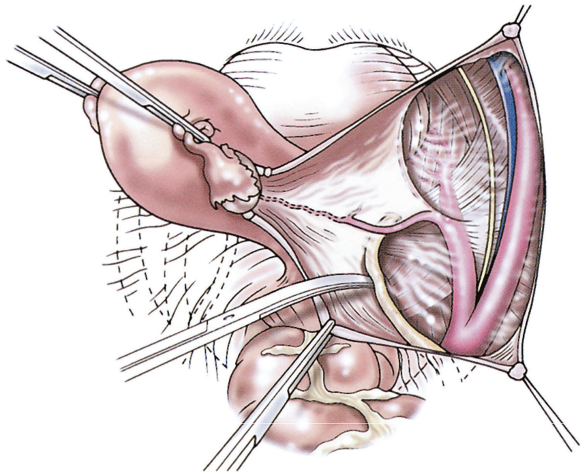

Figure 9.13 Obturator fossa post-lymphadenectomy.

and the pelvic sidewall or at the pelvic sidewall, using the same criteria as with the uterosacral ligaments (Figure 9.21). Again, Harmonic scissors can be used to effect this maneuver. These differing levels of radicality have been classified by Rutledge and the procedures just described are Rutledge II and III procedures (Piver et al. 1974) (Figure 9.22).

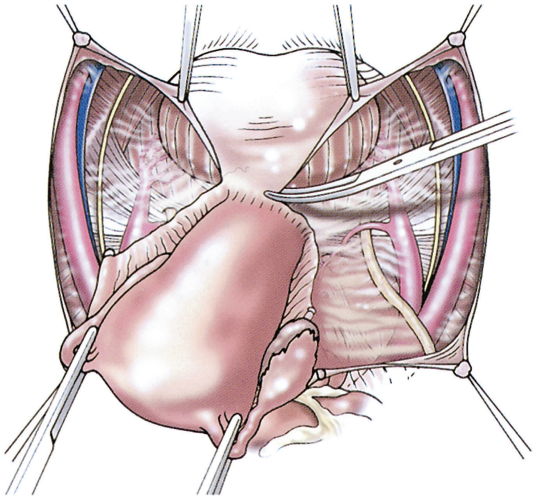

Figure 9.14 Developing the vesicouterine and vesicocervical spaces.

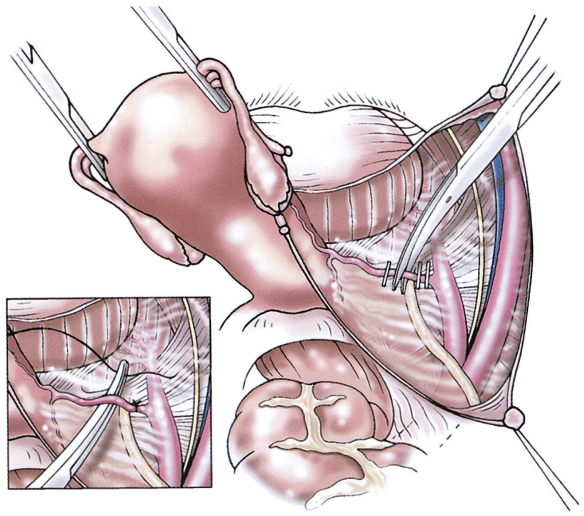

Figure 9.15 The uterine arteries are clamped and divided close to their origins.

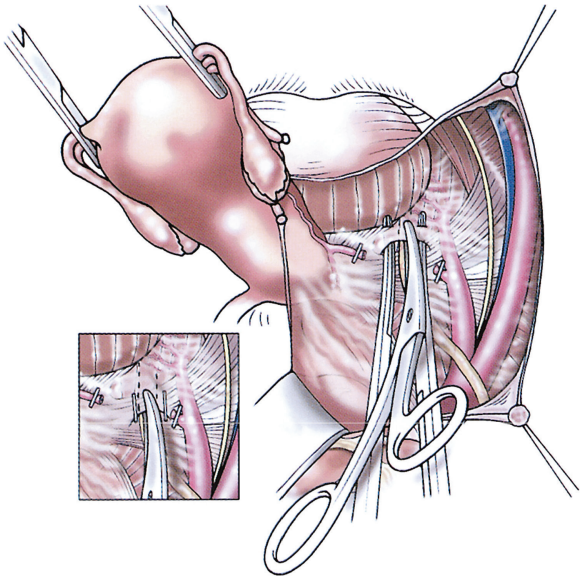

Figure 9.16 Deroofing of the ureteric tunnels.

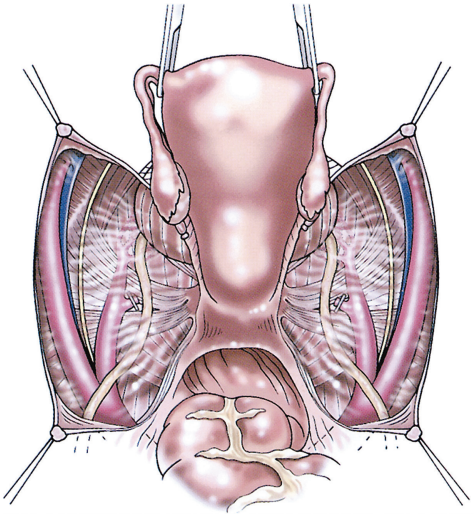

Figure 9.17 Further dissection of the pararectal space.

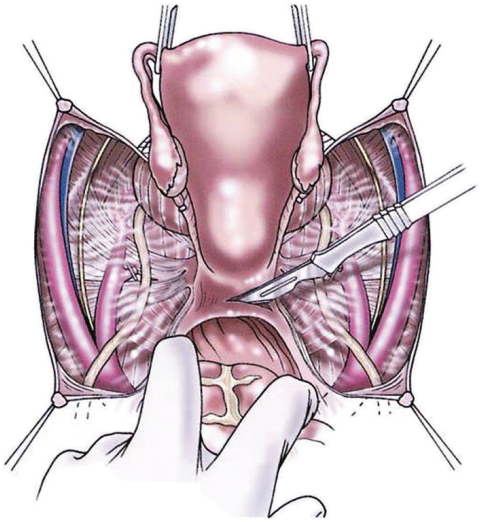

Figure 9.18 Dissection of the rectum from the uterus, opening the recto-vaginal space.

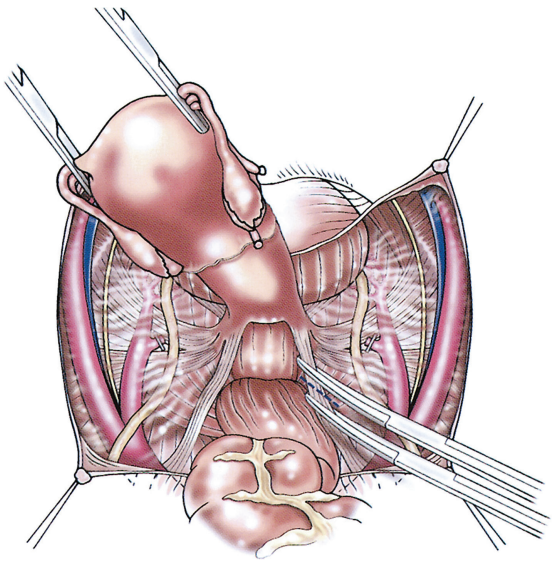

Figure 9.19 Division of the uterosacral ligaments.

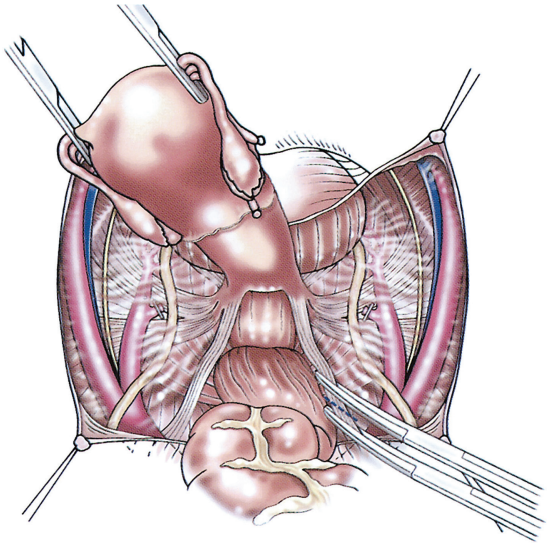

Figure 9.20 Division of the uterosacral ligaments, close to their origin.

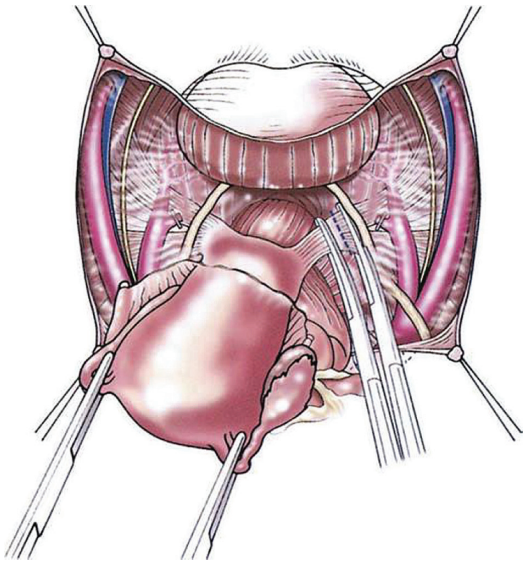

Figure 9.21 Division of the cardinal ligaments.

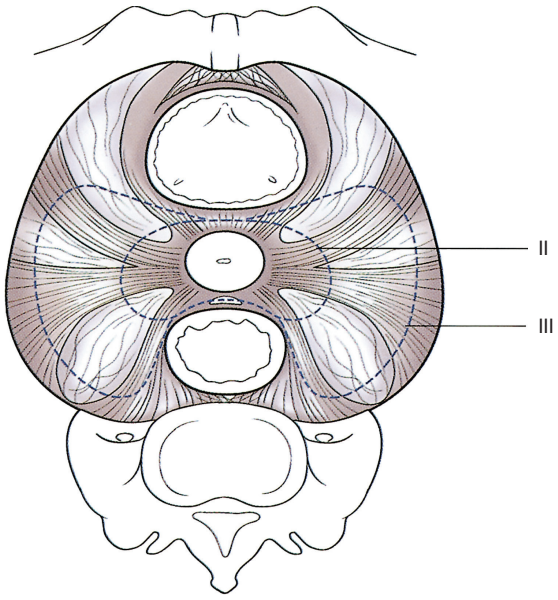

Figure 9.22 Rutledge II and III procedures, operative procedure.

The division of these ligaments causes the paravesical and pararectal spaces to be united (Figures 9.23 and 9.24).

Right-angle clamps or cutting diathermy are applied to the vagina far enough caudally to allow removal of the upper third of the vagina (Figure 9.25). As described above, in cases of stage IIA tumor, the vagina may have been marked with diathermy at the start of the procedure to ensure adequate resection margins are obtained. The vagina is then incised and the uterus with parametrium and upper vagina is then removed. The upper edges of the vagina may be oversewn circumferentially with a locked-on suture to achieve hemostasis, while leaving the vagina open to act as a natural drain. It is also thought that this suturing allows the edges of the vagina to come together by direct apposition, thus minimizing the chances of vaginal mucosa being obscured from view during long-term follow-up. Direct closure of the vagina will inevitably leave some vagina above the suture line and thus out of sight when inspected at follow-up.

At the end of the procedure, the skeletonized vessels, nerves, and ureters can be clearly seen. The paravesical and pararectal spaces are joined and the rectum is exposed to the level of the pelvic floor. Many surgeons leave a silastic drain with gravity drainage in situ at the end of the procedure, although the need for

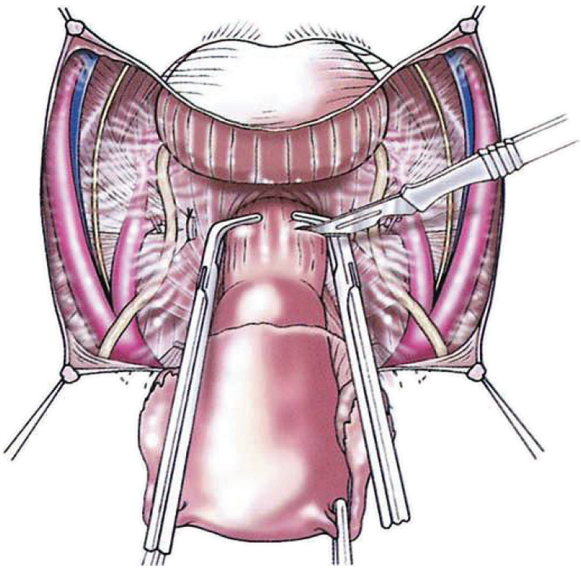

Figure 9.24 Paravesical spaces united.

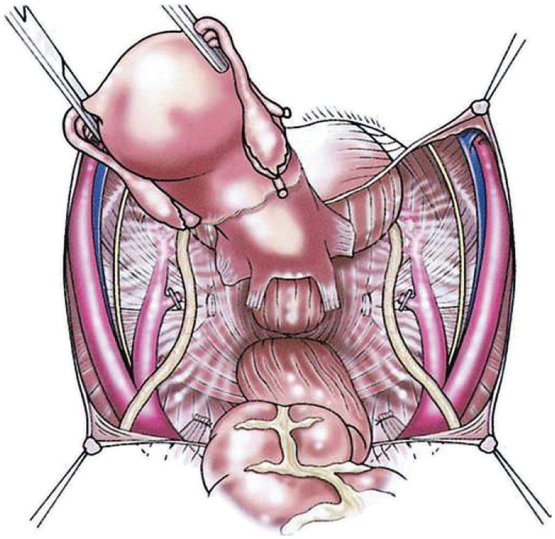

Figure 9.23 Pararectal spaces united.

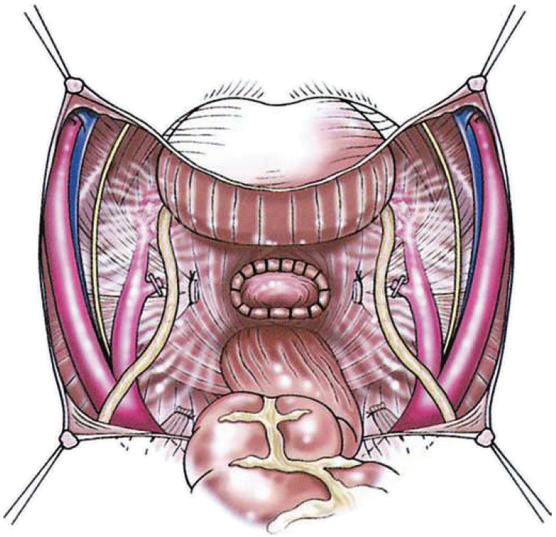

Figure 9.25 Division of the vagina.

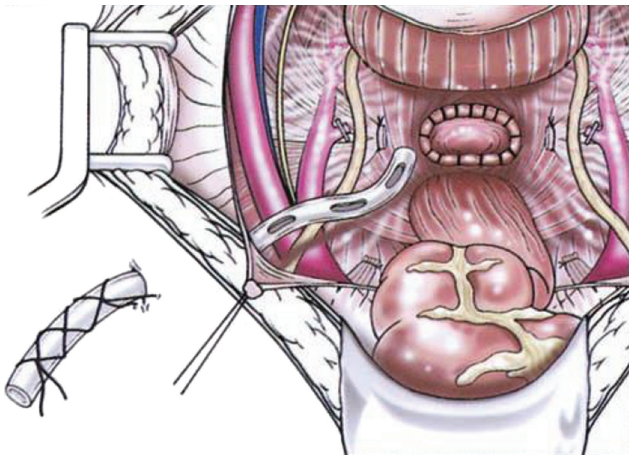

Figure 9.26 The completed procedure. A drain may occasionally be warranted.

this is questionable. This will probably not be required for more than 24 hours (Figure 9.26). Suction drainage has been shown not to reduce lympho cyst formation. A suprapubic catheter may be inserted at this point. It is the authors' practice to use one when a Rutledge III procedure has been performed, since these patients are more likely to encounter urinary difficulties in the postoperative period. The abdomen is then closed with mass closure for vertical incision using a looped PDS suture; a fat suture can be used and the authors use clips to skin. Transverse muscle cutting incisions are closed in a mass closure involving anterior, posterior rectus sheath and parietal peritoneum, usually without attempting to repair the transected rectus muscles; again, clips to skin are used.

REFERENCE

Piver MS, Rutledge FN, Smith JP. 1974. Five classes of extended hysterectomy for women with cervical cancer. *Obstet Gynecol* **44**:265–72.

10 Laparoscopically assisted vaginal radical hysterectomy

Daniel Dargent and Michel Roy

INTRODUCTION

When surgeons considered treating cancers of the cervix in ways other than by cauterization or similar palliative tools, the vaginal hysterectomy was the first technique used (Recamier 1829). However, at the turn of the nineteenth century the abdominal approach became common, as a consequence of two simultaneous changes. First, even if it was more risky than vaginal surgery, abdominal surgery was no longer a death sentence. Second, the concept of radical surgery, introduced by Halsted in the field of breast cancer, was also spreading to the management of all other malignancies. The first "radical hysterectomy" performed by Clark in 1895 included, as a true Halstedian operation, an extirpation of the parauterine tissues and pelvic lymph nodes. Just before Clark devised the radical abdominal hysterectomy, Pavlik in Czechoslovakia (1889) and Schuchardt in Germany (1893) had described a method enabling the removal of the parauterine tissues at the same time as the uterus, while maintaining a vaginal approach. However, removal of the pelvic lymph nodes could obviously not be included in this operation.

The abdominal and vaginal techniques were used concurrently in middle Europe at the end of the nineteenth century. Wertheim became the champion of the first technique, and Schauta the defender of the second. The long and hard fight between the two surgeons ceased when Wertheim's book (1911) was published. Despite higher rates of pre- and postoperative complications, the survival rates obtained by Wertheim were far higher than those noted by Schauta in his book of 1908. With Marie Curie's subsequent discovery of radium in 1910, surgery was no longer a treatment option until the 1930s and 1940s.

Surgery found a new place in the management of cervical cancer as a tool to solve the problem of positive lymph nodes that were not managed by radiotherapy. Leveuf in France (1931) and Taussig in the United States (1935) proposed a combination of radiation therapy and pelvic lymphadenectomy in order to improve outcomes. This idea was the first step toward the reintroduction of radical surgery, whose official beginning was 1945, the year in which JV Meigs delivered his first paper about the new Wertheim operation. Since the highlight of the new radical surgery was systematic pelvic lymphadenectomy, the vaginal approach clearly could not benefit from the revival of such surgery.

The Revival of Radical Vaginal Hysterectomy—Role of Laparoscopy

Following an idea first expressed by Navratil, the Indian surgeon Suboth Mitra (1959) proposed a new combined approach and can be considered as the spiritual father of the new-era vaginal surgery in the management of cervical cancer. In the Suboth Mitra operation, a systematic pelvic lymphadenectomy was first carried out through a bilateral abdominal extraperitoneal incision, then a vaginal radical hysterectomy (VRH) after Schauta. In spite of the two successive surgical interventions, the operation remained less dangerous than the abdominal radical hysterectomy (ARH) because it did not include a large and lengthy opening of the peritoneal cavity. During the 1970s, postoperative morbidity was three times less after the Suboth Mitra operation than after the Meigs operation. Therefore we used it (Dargent 1991) for the high surgical risk patients as today does Massi (Savino et al. 2001), but we did not extend the indications to the standard surgical risk patients.

In order to increase the area of application of the VRH it was proposed (Dargent 1987) to replace the bilateral abdominal incision by the laparoscopic tool for performing the systematic pelvic dissection, which is part of the radical hysterectomy since the Meigs publication. So was born the concept of "Celio-Schauta," or laparoscopically assisted vaginal radical hysterectomy (LAVRH), a concept derived from laparoscopically assisted vaginal hysterectomy (LAVH). LAVH includes four variants. In variant 0, the laparoscope is only used for assessing the peritoneal cavity before performing the vaginal hysterectomy. In variant 1, the round ligaments and the infundibulopelvic ligaments (and the peritoneal adhesions, if needed) are divided with the laparoscope. In variant 2, one pushes up to the level of the uterine arteries. In variant 3, the paracervical ligaments as well are divided with the laparoscope. In variant 4, the entire operation is carried out with the laparoscope, including incision and closure of the vagina. A similar classification can be used for the LAVRH.

From 1986 to 1992 the LAVRH type 0 Celio-Schauta was our daily practice. The laparoscope was used for assessing the pelvic cavity, the organs it contains, and the lymph nodes along the pelvic sidewalls in the retroperitoneal spaces. After having performed the systematic pelvic lymphadenectomy, the vaginal approach was used and the VRH was performed following the technique of Schauta using either the German variant (Stoeckel 1928), whose radicality is like the Piver 2 ARH, or the Austrian variant (Amreich 1924), whose radicality is like the Piver 3 ARH. The first operation was selected for the smallest tumors (<2 cm in size), and the second one was reserved for the biggest ones (2 cm in size or more).

From 1992 a handful of papers (Dargent and Mathevet 1992, Kadar and Reich 1993, Roy et al. 1996, Schneider et al. 1996, Pomel et al. 2003) were published concerning variants of LAVRH one could designate as the variant 3, in that meaning that the laparoscope was not only used for performing the indispensable systematic pelvic lymphadenectomy but for dividing the uterine arteries and the paracervical ligaments as well. The common feature of these techniques was the quest for radicality which could be greatly increased thanks to the laparoscope. Indeed, one of the technical difficulties in the vaginal approach is clamping the

parametrium close to the pelvic sidewall because of the oblique angle. Conversely, the laparoscope, with its magnification, helps the surgeon removing parametrial tissue potentially containing nodes and leaving only vessels, nerves, and connective tissue. This makes possible clamping of the parametrium away from the pelvic sidewall and therefore limiting the damage to bladder and rectal innervation. The operation we describe here is a variant of the LAVRH type 3.

SURGICAL PROCEDURE

The aim of the radical hysterectomy operation, whichever approach is chosen, is to retrieve part of the vagina and the parauterine tissues, together with the uterus itself. The ventral and dorsal surfaces of the vagina and the tissues close to the uterus are also in close proximity with the bladder floor and the ureters from the ventral surface of the specimen when opening the vesicovaginal space on the midline and the paravesical spaces on either side in order to locate the bladder pillars and divide them after identification of the ureters. The dorsal aspect of the specimen is freed when the rectal pillars are divided (a much simpler step of the operation).

Laparoscopic Operation

The laparoscopic part of the LARVH is usually done using the classical transumbilical transperitoneal route.

Four trocars are used: two 10 mm for the umbilical and suprapubic opening and two 5 mm placed laterally in the pelvis. In the transperitoneal approach, inspection of the peritoneal surfaces, liver, and pelvic organs is carried out. When obvious peritoneal invasion is seen around the cervix, or gross pelvic node metastases are encountered, the radical hysterectomy is aborted and para-aortic dissection is carried out to rule out metastasis in the para-aortic area.

The search and removal of the sentinel lymph nodes (SLN) is performed and sent for frozen section (see Chapter 18) and the pelvic lymphadenectomy is done. If one of the SLN is positive, the radical hysterectomy is aborted.

The medial aspect of the iliac vessels is easily cleaned (Figure 10.1). The lateral aspect is a little more difficult; however, it can be achieved laparoscopically as effectively as it is at laparotomy, if not better. The iliac vessels are detached from the psoas muscle and pushed medially. The opened space is cleaned out until the obturator nerve is identified (Figure 10.2).

The last step of the laparoscopic procedure is dividing the uterine arteries and preparing the cardinal ligament (Figure 10.3). Rather than cutting the ligament laparoscopically, its lateral part is emptied of the lymph node-bearing tissues which are in the vascular network of the ligament. This emptying is done by gentle teasing of the adipose tissue between the vessels. Among the vessels handled are the uterine arteries, which are accompanied

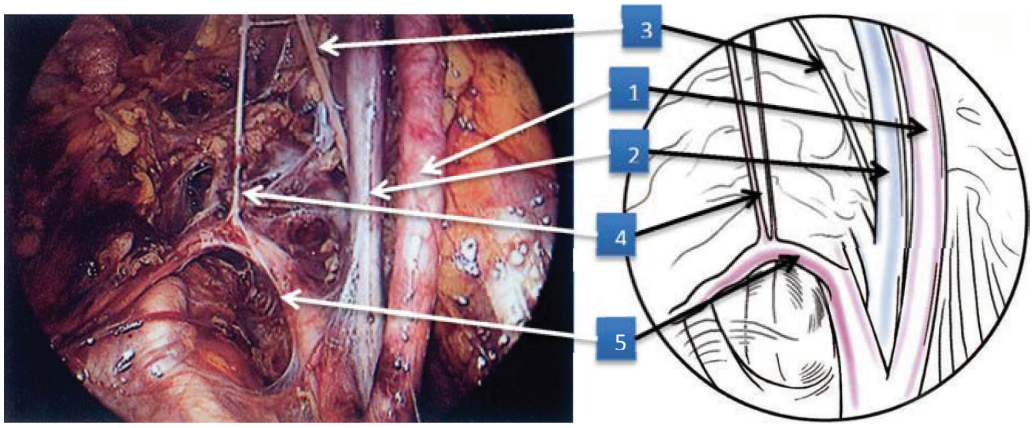

Figure 10.1 Laparoscopic view of the medial aspect of the right common iliac bifurcation. 1: External iliac artery; 2: external iliac vein; 3: obturator nerve; 4: superior vesical artery; 5: internal iliac artery.

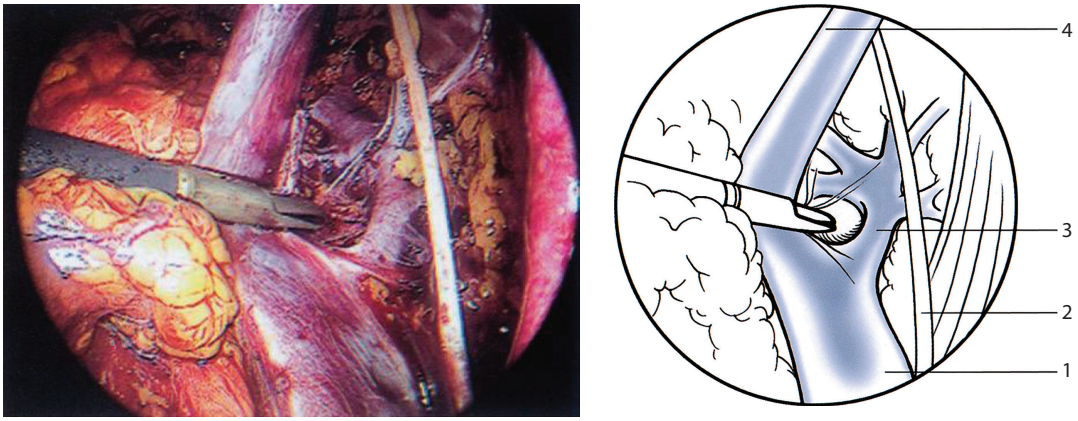

Figure 10.2 Laparoscopic view of the lateral aspect of the right common iliac venous convergence: the obturator nerve crosses the gluteal vessels. 1: Common iliac vein; 2: obturator nerve; 3: internal iliac vein; 4: external iliac vein.

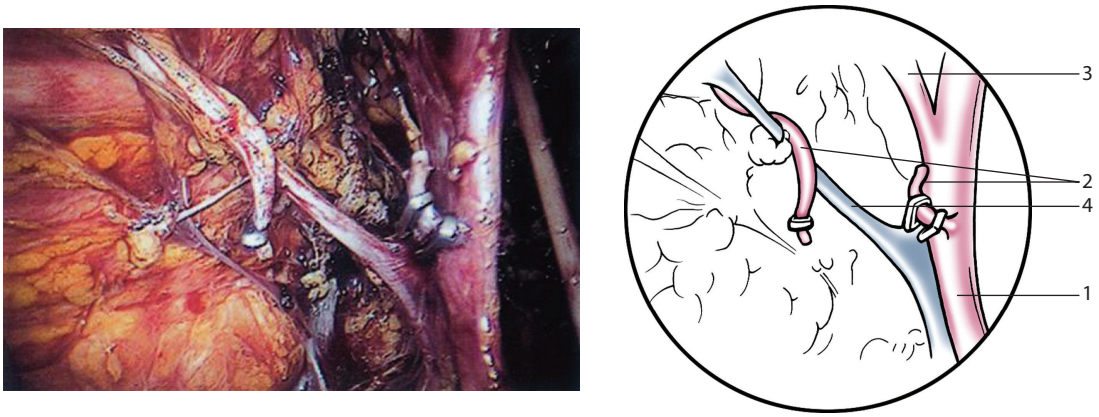

Figure 10.3 Laparoscopic view after transection of the right uterine artery. A superficial uterine vein will be cut next. 1: Internal iliac artery; 2: uterine artery; 3: superior vesical artery; 4: uterine vein.

by lymphatic channels. A superficial uterine vein can accompany the artery as well (Figure 10.3).

Vaginal Surgery

The original Schauta operation started with a Schuchardt incision (deep left lateral episiotomy) in order to enlarge the field of dissection and to more easily open the left pararectal space. Nowadays, the Schuchardt is rarely used for three main reasons. First, the vaginal radical approach should not be chosen when the volume of the cervical tumor exceeds 2.5 to 3 cm, and in those cases, there is no need for removal of the entire parametrial tissue. Furthermore, distal parametrectomy is performed laparoscopically, so only proximal parametrium needs to be removed vaginally. The second reason is the risk of metastasis in the incision (Bader et al. 2006, Beranger et al. 2004). The third reason is the discomfort of the patient and the risk of vaginal hematoma. In the postoperative period, the most important site of pain used to be the vaginal incision.

After the cervix is grasped with clamps, determination of the vaginal margin (Figure 10.4) is made roughly 1 to 2 cm from the cervix, depending on the size and location of the tumor. The inferior brim of the head of the prolapse is infiltrated using diluted synthetic vasopressin, primarily for prophylactic hemostasis but also to separate the two parts of the fold.

Dividing the vagina is done in four stages. The anterior aspect is treated first (Figure 10.5). It is the most difficult step,

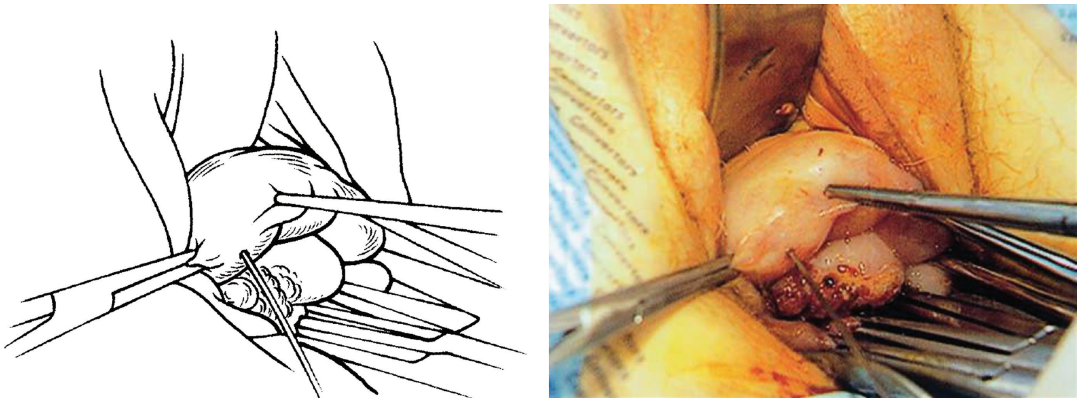

Figure 10.4 Infiltration of the vaginal margin.

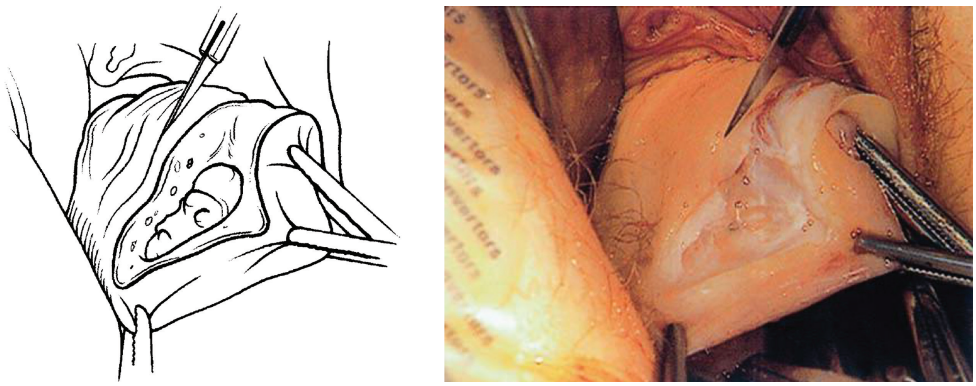

Figure 10.5 The Schauta operation: separation of the vaginal cuff on the ventral (anterior) aspect; the incision is full thickness.

because the bladder floor is drawn inside the vaginal fold one pulls on. All the layers of the vaginal wall must be cut without injury to the bladder wall. Treating the posterior aspect is easier because of the tissue present between the rectum and vagina. On the lateral aspects, only the mucosa is cut (Figure 10.6) in order to maintain the relationship between the vaginal cuff and the underlying structures; that is, the paracervical ligaments. Compare this with the anterior and posterior surfaces, where the goal was separating the cuff from the underlying organs; that is, the bladder and rectum.

Once the vaginal cuff is separated, it is grasped using Chrobak forceps (Figure 10.7) and pulled downward. Traction reveals the supravaginal septum, a pseudomembrane made by condensation of the connective fibers joining the bladder floor to the vagina. This pseudo-aponeurosis has to be opened on the midline close to the base of the trigone (Figure 10.8). Once the aponeurosis has been opened (use the scissors perpendicularly to the vagina), the areolar tissue of the vesicovaginal space is visible and a tunnel can be made and enlarged to the level of the vesicovaginal peritoneal fold (this is possible using the scissors parallel to the vagina).

Next the vesicovaginal space is opened, together with the paravesical space.

To open the paravesical spaces, two forceps are applied to the brim of the vagina (at positions 1 o'clock and 3 o'clock for the left side, 11 o'clock and 9 o'clock for the right side). Pulling on

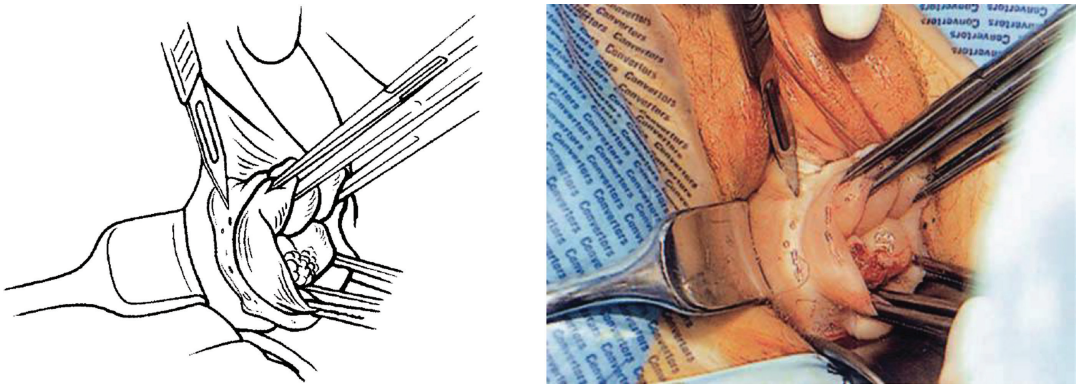

Figure 10.6 Separation of the vaginal cuff on the lateral aspect; the incision is more superficial.

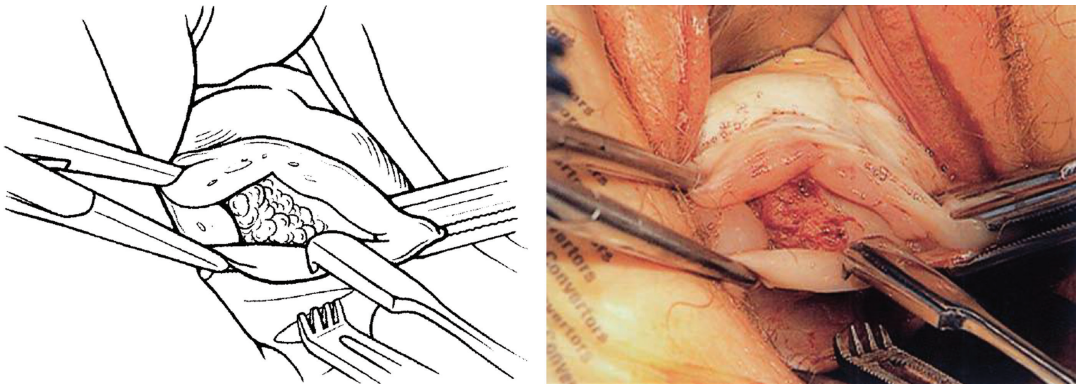

Figure 10.7 Grasping the vaginal cuff with the forceps.

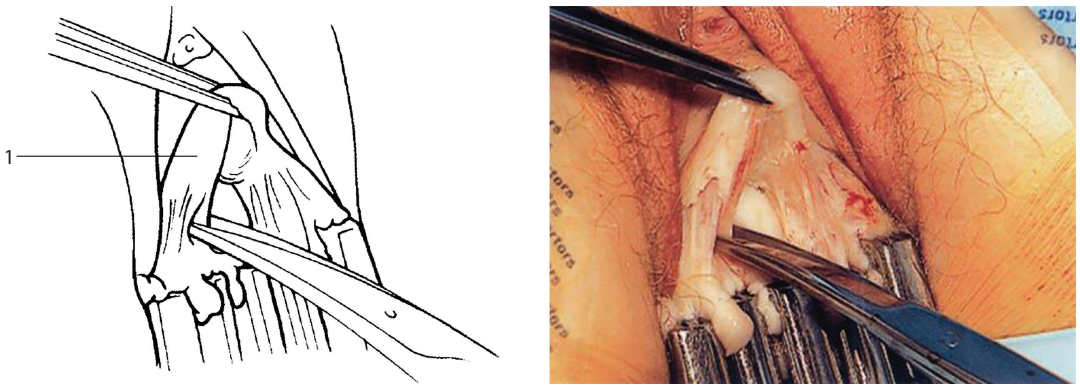

Figure 10.8 Opening the vesicovaginal space on the midline. 1: Bladder.

the forceps reveals a depression located close to the most lateral instrument (Figure 10.9). Deepening this depression by blunt use of Metzenbaum scissors oriented laterally and ventrally (Figure 10.10) opens the paravesical space, into which is introduced a micro-Breiski retractor. The structure interposed between this retractor and the previously opened vesicovaginal space is the bladder pillar, inside which the contour of the ureter can be identified while palpating the pillar against the retractor. The characteristic "snap" of the ureter is evinced (Figure 10.11).

While appropriate exposure is maintained with the retractors, the inferior brim of the pillar, which appears vertical, is opened with the tip of the scissors, and its lateral fibers are separated using the same scissors (Figure 10.12). After a new palpatory assessment (make sure the ureter is located, laterally to the isolated part of the pillar) the fibers of the pillar are cut (Figure 10.13). The paravesical space becomes wider, and a broader retractor is introduced. The lateral aspect of the "knee" of the ureter becomes visible (Figure 10.14). The medial fibers of the pillar can then be cut to release the ventral aspect of the paracervical ligament (Figure 10.15): this enables location of the arch of the uterine artery in the para-isthmic window (a space whose inferior brim is the superior edge of the paracervical ligament). The descending branch of the arch is tugged and the already divided artery arrives in the operative field with a staple at the cut end (Figure 10.16).

After freeing the ventral aspect of the specimen, the surgeon moves to the dorsal aspect. The first step is opening the pouch of Douglas (Figure 10.17). The recto-uterine ligaments are then

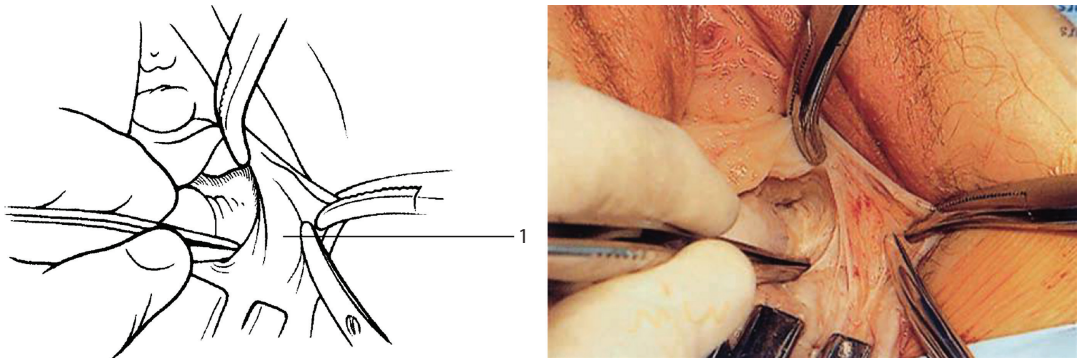

Figure 10.9 Opening the paravesical space. 1: Bladder pillar.

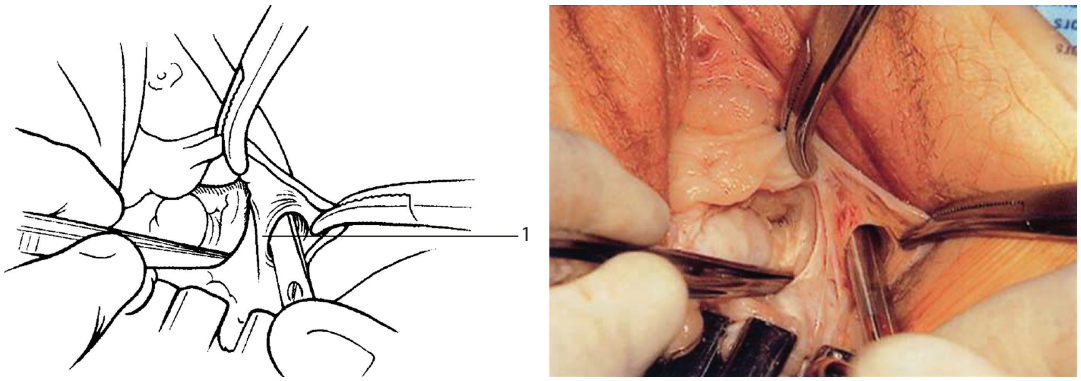

Figure 10.10 Evincing the entry into the paravesical space on the left side. 1: Bladder pillar.

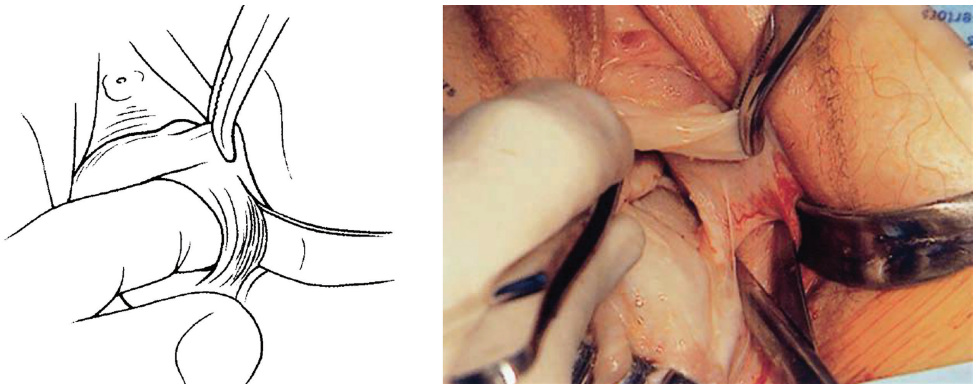

Figure 10.11 Palpation of the bladder pillar on the left side to elicit the "snap" of the ureter.

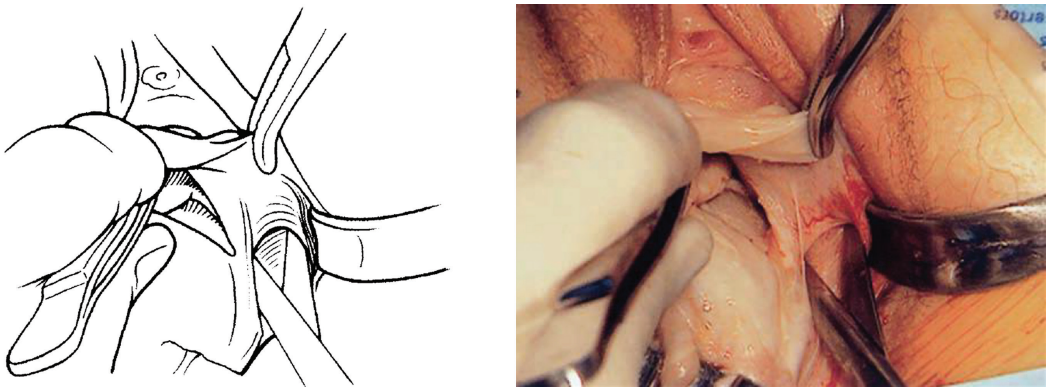

Figure 10.12 Separation of the lateral part of the bladder pillar on the left side.

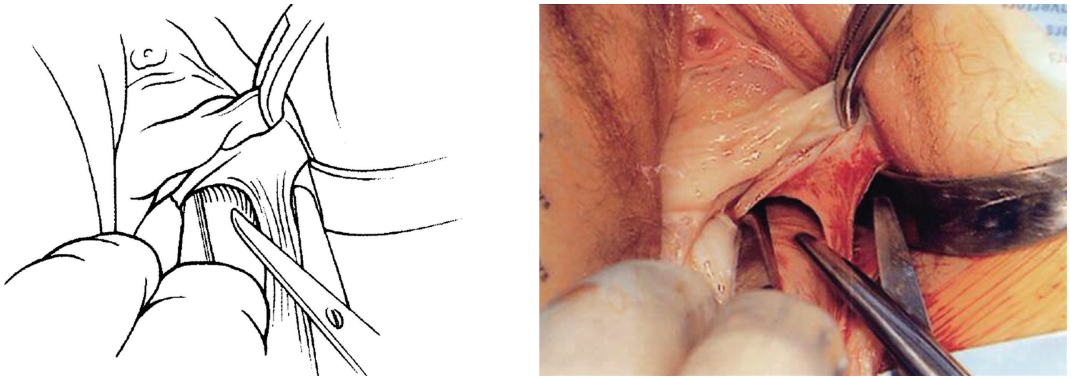

Figure 10.13 Cutting the lateral part of the bladder pillar.

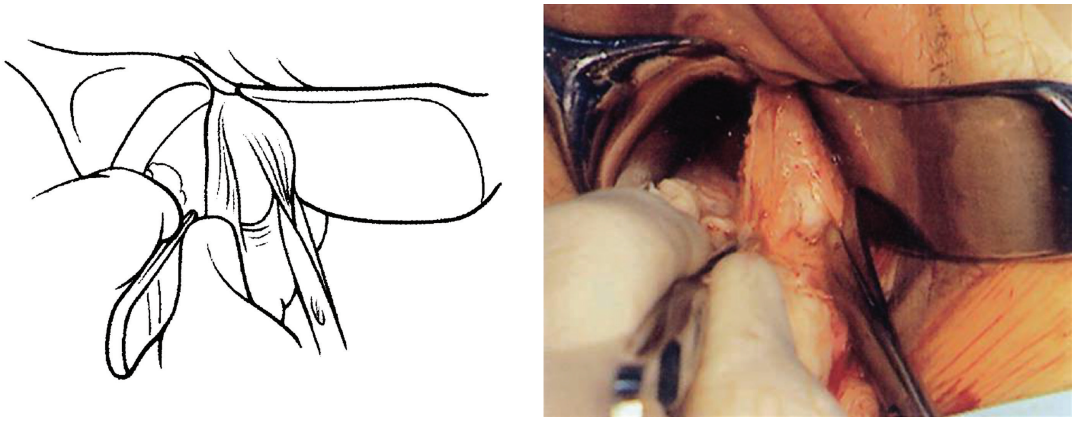

Figure 10.14 Further division of the lateral fibers of bladder pillar on left side: the knee of the ureter is visible.

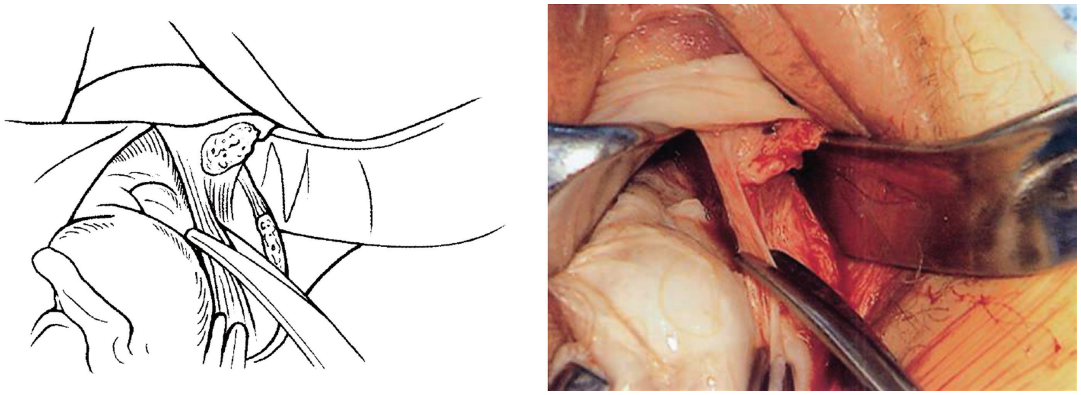

Figure 10.15 Division of medial part of bladder pillar on left side.

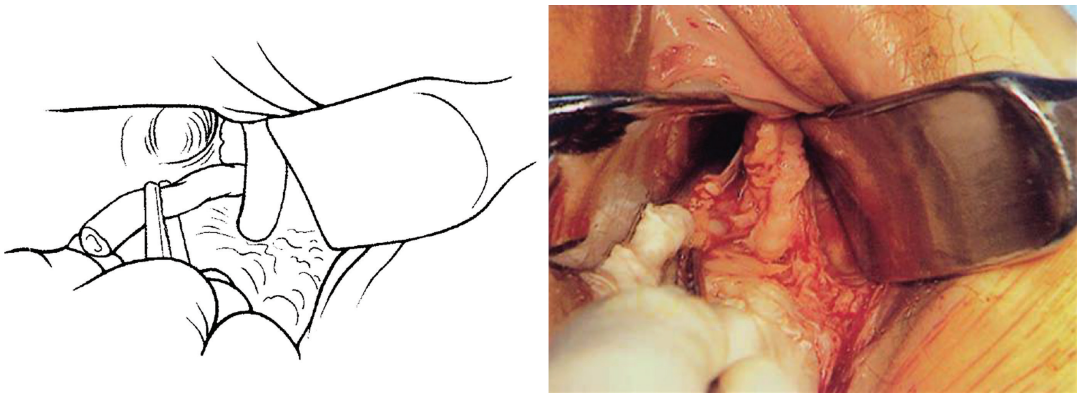

Figure 10.16 Pulling on the descending branch of arch of uterine artery on left side.

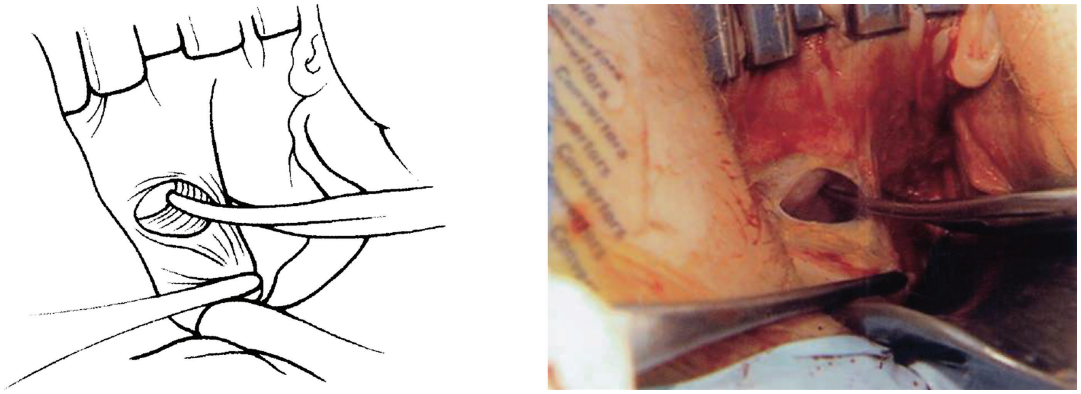

Figure 10.17 Opening the pouch of Douglas and the rectal pillar.

divided at a point equidistant between the uterus and the rectosigmoid. Cutting at this level is easy (no preventive clamping is needed) and leads directly to the dorsal aspect of the paraisthmic window, the ventral aspect of which has been identified previously. The tip of a right-angle forceps is pushed into the window from back to front.

Two clamps can be put onto the cardinal ligament. The first one is placed medially, and traction is exerted. The second clamp (which has a slightly greater curvature) is placed laterally; the convexity of its curvature lies in contact with the "knee" of the ureter (Figure 10.18).

Following transection of the ligaments, the uterine body can be turned in a dorsal direction, and the adnexa can be left in place or removed, depending on the age of the patient (Figure 10.19). The vagina is closed with interrupted sutures after careful evaluation of intraperitoneal hemostasis. A Foley catheter is left in place for 3 to 5 days. Since hemostasis can be difficult to assess vaginally, we go back laparoscopically for inspection of

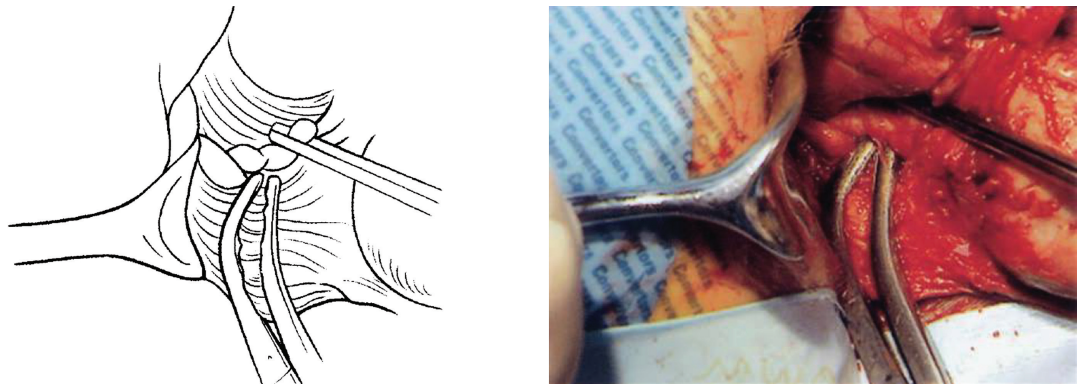

Figure 10.18 Paracervical ligament is clamped, the lateral clamp being put underneath the tip of the "knee" of the ureter. The vagina is closed without a drain or gauze. A Foley catheter is left in place for 3 to 5 days. Since hemostasis can be difficult to assess vaginally, we go back laparoscopically for inspection of the dissected areas, to complete hemostasis, and to make sure of the integrity of the bladder and the ureters.

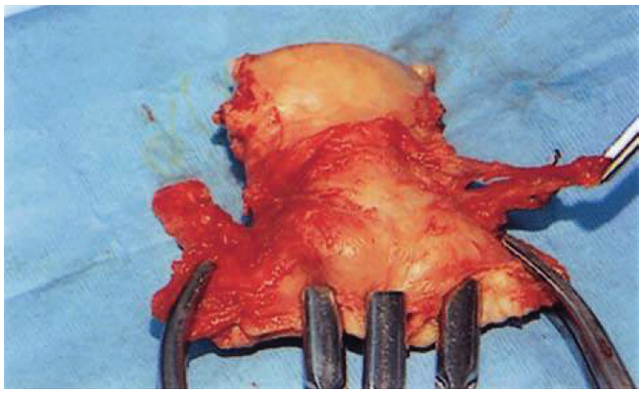

Figure 10.19 The removed specimen with proximal parametrium and uterine arteries is lacking here, having been removed during the laparoscopic procedure.

the dissected areas, to complete hemostasis and to make sure of the integrity of the bladder and the ureters.

Postoperative Course—Complications

The LAVRH is performed in 3 hours, including 2 hours for the laparoscopic part and localization and retrieval of the sentinel nodes, and roughly 1 hour for the vaginal part. Preservation of the bladder floor and ureters is the main concern. Injuries can occur which are easily detected because of urine leakage. They can usually be fixed without having to resort to laparotomy. If the injury concerns the ureter(s) or the bladder floor close to the ureteric orifices, stents should be used. Other perioperative problems are not specific. The postoperative course is usually simple. The patient can get up the night of surgery or on postop day one. The return to normal diet is rapid. Resuming normal urinary bladder function can take time. We recommend leaving the bladder catheter in place for 3 to 5 days. Post-micturition residuals must be done and self-catheterization is taught to the patient when indicated, and she can be discharged home when there is no significant residual ($2 \times <100$ cm^3) or self-catheterization is understood. Postoperative complications are similar to those that can occur after all extended pelvic surgery. Bleeding is the first complication, but usually less than with the abdominal approach (Roy and Plante 2011). It occurs most of the time in the first 48 hours postop. The incidence of bleeding is lowered by laparoscopic re-evaluation of the abdomen after the vagina is closed. Postoperative pelvic collections of various natures can be observed as a consequence of occult bleeding during the first postoperative days or as a consequence of accumulation of lymphatic fluid in the successive weeks. Fistulas are generally the consequence of undiagnosed injuries, and symptoms appear in the first hours following the surgery. Fistulas linked to tissue necrosis and occurring later in the postoperative course are practically unknown after VRH, unlike ARH. Nevertheless, it is mandatory to investigate by an intravenous pyelogram if injury is suspected.

Urinary, bowel, and sexual sequelae can occur. The first ones are the most concerning. The urinary bladder voiding difficulties observed in the immediate postoperative period can persist at least in the form of loss of the feeling of the need to urinate and a prolonged time to void. In the extreme forms, self-catheterization is the treatment. A micturition calendar and biofeedback usually are enough. The same is for constipation, which can be the consequence of neurogenic rectal atony and pre-existing anal problems. Nonirritant laxatives and biofeedback are the two pillars of the management.

The complication rates of LAVRH depend essentially on the "learning curve effect." In the literature of the early 1990s, the rate of urinary injuries and/or fistulas was around 10%. In the literature of the early 2000s, the rates are much lower. In the Quebec City experience (Renaud et al. 2000), 7 complications were observed among 91 patients, of which 3 were among the first 25 cases and 4 among the following 77 cases. In the Jena experience (Hertel et al. 2003), 65% of the complications occurred for the first 100 cases versus 35% for the 100 following cases. Other publications (Querleu et al. 2002) do not mention any severe complications, with the exception of one post-radiotherapy ureteral stenosis in a series of 95 patients who had LAVRH. In a Cochrane Database review, Kucukmetin et al. (2013) confirmed less blood loss for LARVH but longer operation time. In a systematic review of the literature by Pergialiotis et al. (2013), the learning curve might be too slow for the surgeon to gain expertise. Total laparoscopic or robotic-assisted radical hysterectomy might become a better surgical choice.

Endpoints—Indications

The data of the recent literature enable us to define the indications for the LAVRH. In our own series (unpublished data), the actuarial disease-free 5-year survival was 94.2% in a series of 216 patients affected by cervical cancer stage N0, pIA2, and pIB1 submitted to Celio-Schauta or LAVRH between December 1986 and May 2002. For stages IB2 and higher, the results are not as good. In the Jena series (Hertel et al. 2003), the actuarial disease-free 5-year survival was under 70% for stage IB2 and under 60% for stages IIA and IIB. In stage IB1, a clear cutoff exists between the tumors less than 2 cm in size and the others. In our own experience (unpublished data), the disease-free 5-year survival was 100% for the 144 patients with tumors less than 2 cm in size versus 87.5% for the 72 patients with tumors 2 cm or more in size. Among the patients with the biggest tumors followed 3 years or more, the number of recurrences was 4 out of 23 after the VRH type Schauta-Amreich versus 3 out of 11 after VRH type Schauta-Stoeckel and 3 out of 19 after VRH type Schauta-Stoeckel preceded by a paracervical lymphadenectomy carried out as a complement of the laparoscopic pelvic lymphadenectomy which was performed in all cases.

The radical vaginal hysterectomy should not be performed for stage IB2 and more. Clinical examination and magnetic resonance imaging (MRI) are the keys of this first selection. The team from Jena (Hertel et al. 2003) proposes going further and rejecting the cases with lymphovascular space involvement and also pN1. The first risk factor is assessed on the initial large biopsy specimen. The second one can be evidenced at the initial imaging. If not, the frozen sections done on the sentinel nodes retrieved laparoscopically give the answer. Such a selection could provide a 98% rate of 5-year disease-free survival. Furthermore, this result can be obtained at the price of the least aggressive of the VRH techniques, that of Stoeckel. Our data seem to demonstrate that the parametrial lymphadenectomy performed during the laparoscopic part of the surgery significantly lowers the risk of recurrences.

CONCLUSIONS

LAVRH in light of the published data is equivalent to ARH in the management of early cervical cancer for the chances of cure. The evidence is level B (consistent retrospective and prospective surveys). Perioperatively, blood loss is significantly less (Roy and Plante 2011). Concerning postoperative comfort, LAVRH offers better than ARH (level A). The minimally invasive surgery, at first sight, seems to be more "patient friendly," but classical surgery has changed a lot since the new tool appeared and has been developed further: new incisions, new instruments (Ligasure®, Biclamp®, Ultracision®), new wound closure techniques, and new analgesic strategies make the postoperative course much less painful than it was in the past. With more recent use of laparoscopy or robotics in cervical cancer surgery, the future might be "vaginal assisted laparoscopic radical hysterectomy" (Koehler et al. 2012).

REFERENCES

Amreich AI. 1924. Zur Anatomie und Technik der erweiterten vaginalem Carzinom Operation. *Arch Gynäkol* **122**:497.

Bader AA, Bjelic-Radisic V, Tamussimo KF, et al. 2006. Recurrence in a Schuchardt incision after Schauta-Amreich operation for cervical cancer. *Int J Gynecol Cancer* **16**:1479.

Barranger E, Hugol D, Darai E. 2004. Metastasis on a Schuchardt incision after Schauta-Amreich operation for cervical carcinoma. *Gynecol Oncol* **92**:1006.

Clark JG. 1895. A more radical method for performing hysterectomy for cancer of the uterus. *Bull Johns Hopkins Hosp* **6**:120.

Dargent D. 1987. A new future for Schauta's operation trough presurgical retroperitoneal pelviscopy. *Eur J Gynaecol Oncol* **8**:292.

Dargent D. 1991. Treatment of the cancers of the ecto-cervix and vagina with preservation of the uterus and adnexae. *Cah Oncol* **1**:21.

Dargent D, Mathevet P. 1992. Radical laparoscopic vaginal hysterectomy. *J Gynecol Obstet Biol Reprod (Paris)* **21**:709.

Hertel H, Kohler C, Michels W, et al. 2003. Laparoscopic-assisted radical vaginal hysterectomy (LARVH): Prospective evaluation of 200 patients with cervical cancer. *Gynecol Oncol* **90**:505.

Kadar N, Reich H. 1993. Laparoscopically assisted radical Schauta hysterectomy and bilateral laparoscopic pelvic lymphadenectomy for the treatment of bulky stage IB carcinoma of the cervix. *Gynaecol Endosc* **2**:135.

Koehler C, Gottscalk E, Chiantera V, et al. 2012. From laparoscopic assisted radical vaginal hysterectomy to vaginal assisted laparoscopic radical hysterectomy. *BJOG* **119**:254–62.

Kucukmetin A, Biliatis I, Naik R, et al. 2013. Laparoscopically assisted radical vaginal hysterectomy versus radical abdominal hysterectomy for the treatment of early cervical cancer. *Cochrane Database Syst Rev* **10**:CD006651.

Leveuf J. 1931. L'envahissement des ganglions lymphatiques dans le cancer du col de l'uterus. *Bull Mem Soc Nat De Chir* **57**:662.

Meigs JV. 1945. Wertheim operation for carcinoma of the cervix. *Am J Obstet Gynecol* **49**:542.

Mitra S. 1959. Extraperitoneal lymphadenectomy and radical vaginal hysterectomy for cancer of the cervix (Mitra technique). *Am J Obstet Gynecol* **78**:191.

Pavlik K. 1889. O extirpaci cele dälohy a casti vaziva panvicniho. *Casopis Lekaru Ceskych* **XVIII**:28.

Pergialiotis V, Rodolakis A, Christakis D, et al. 2013. Laparoscopically assisted vaginal radical hysterectomy: Systematic review of the littérature. *J Minin Invasive Gynecol* **20**:745–53.

Pomel C, Atallah D, Le Bouedec G, et al. 2003. Laparoscopic radical hysterectomy for invasive cervical cancer: 8-year experience of a pilot study. *Gynecol Oncol* **91**:534.

Querleu D, Narducci F, Poulard V, et al. 2002. Modified radical vaginal hysterectomy with or without laparoscopic nerve-sparing dissection: A comparative study. *Gynecol Oncol* **85**:154.

Recamier JCA. 1829. Ablation de l'uterus cancereux. In: *Recherche sur le traitement du cancer*. Paris: Gabon, pp. 519–29.

Renaud MC, Plante M, Roy M. 2000. Combined laparoscopic and vaginal radical surgery in cervical cancer. *Gynecol Oncol* **79**:59.

Roy M, Plante M, Renaud MC, et al. 1996. Vaginal radical hysterectomy versus abdominal radical hysterectomy in the treatment of early-stage cervical cancer. *Gynecol Oncol* **62**:336.

Roy M, Plante M. 2011. Place of Schauta's radical vaginal hysterectomy. *Best Pract Res Clin Obstet Gynaecol* **25**:227–37.

Savino L, Borruto F, Comparetto C, et al. 2001. Radical vaginal hysterectomy with extraperitoneal pelvic lymphadenectomy in cervical cancer. *Eur J Gynaecol Oncol* **22**:31–5.

Schauta F. 1908. *Die erweiterte vaginale Totalextirpation des Uterus beim Kollumkarzinome*. Vienna: J. Safar.

Schneider A, Possover M, Kamprath S, et al. 1996. Laparoscopy-assisted radical vaginal hysterectomy modified according to Schauta-Stoeckel. *Obstet Gynecol* **88**:1057.

Schuchardt K. 1893. Eine neue methode der gebärmutterexstirpation. *Zbl Chir* 1131.

Stoeckel W. 1928. Die vaginale Radikaloperation des Collumkarzinomes. *Zbl Gynäkol* **52**:39.

Taussig FJ. 1935. The removal of lymph nodes in cancer of the cervix. *Am J Roentgenol* **34**:354.

Wertheim. 1911. *Die erweiterte abdominale Operation bei Carcinoma Colli Uteri*. Berlin: Urban & Schwarzenberg.

11 Radical vaginal trachelectomy

Marie Plante and Michel Roy

INTRODUCTION

Cervical cancer frequently affects young women in their reproductive years, often before they have had the chance to begin or complete their family plans. So, in terms of quality of life, fertility preservation has become a major issue in the management of young women with early-stage cervical cancer (Plante 2000).

Vaginal radical trachelectomy (VRT) has been performed for over 30 years. It is now recognized as a valuable conservative fertility-preserving surgical procedure for the treatment of selected cases of early-stage cervical cancer. This procedure has the advantage of preserving the uterine body, which in turn allows preservation of childbearing potential. This surgery has been described and first published by Professor Daniel Dargent from Lyon, France (Dargent et al. 1994). Data have been reported from nearly 1000 women who have undergone this procedure worldwide (Plante 2013). More than 450 pregnancies have been reported and more than 300 healthy babies have been born so far. The majority of patients have delivered by elective caesarean section and approximately two-thirds were at term. The main obstetrical problem is the risk of premature second trimester birth or miscarriage. Oncologic results are also reassuring, as the risk of recurrences remains less than 5% (Plante 2013).

This procedure is now accepted as a valid alternative to the radical hysterectomy procedure and is now part of the National Comprehensive Cancer Network (NCCN) guidelines as an option in young women with early-stage disease who wish to preserve their fertility. However, the procedure has been mostly validated for small lesions measuring <2 cm in size (NCCN guidelines version 2.2015).

INDICATIONS

The eligibility criteria have not changed significantly since first proposed (Roy and Plante 1998). As data accumulate, these criteria are subject to change in the future.

1. Desire to preserve fertility
2. No clinical evidence of impaired fertility
3. Lesion size less than 2.0 to 2.5 cm
4. FIGO stage IA1 with vascular space invasion (VSI), IA2–IB1
5. Squamous cell or adenocarcinoma
6. No involvement of the upper endocervical canal as determined by colposcopy and/or magnetic resonance imaging (MRI)
7. No metastasis to regional lymph nodes

ANATOMICAL CONSIDERATION

Vascular Supply

The blood supply to the cervix is assured by the cervical (or descending) branch of the uterine artery, and by the vaginal artery which originates from either the hypogastric, the uterine, or the superior vesical artery. At the level of the upper endocervix, these two arteries form a network of anastomosis and a rich vascular plexus. At the isthmus, the uterine artery also forms a loop, often referred to as the cross of the uterine artery. This is an important landmark because all efforts should be made to preserve the uterine artery in order to assure a good vascular supply to the uterine body, particularly in the event of a pregnancy. However, bilateral uterine artery ligation is not a contraindication to continuing the trachelectomy, and pregnancies should be allowed to proceed normally; the uterine body usually maintains good vascularization through the utero-ovarian vascular supply. The venous supply follows the arterial one (Figure 11.1).

Uterovaginal Endopelvic Fascia

The endopelvic fascia refers to the reflections of the superior fascia of the pelvic diaphragm upon the pelvic viscera. This thin layer thus encases respectively the urethra and bladder (urethrovesical fascia), the vagina and lower uterus (uterovaginal fascia), and the rectum (rectal fascia). The uterovaginal endopelvic fascia is of particular importance as it lies in close proximity to the pelvic peritoneum. The former is an avascular space that should be defined when mobilizing the bladder base at the time of VRT, but the anterior pelvic peritoneum itself should not be entered (Figure 11.2).

Cardinal (Mackenrodt) Ligament

The cardinal ligament is composed of condensed fibrous tissue and some smooth muscle fibers. It extends from the lateral aspect of the uterine isthmus toward the pelvic wall. This fibrous sheath contains the ureter, the uterine vessels and associated nerves, the lymphatic channels and lymph nodes draining the cervix, and some fatty tissue. It is commonly referred to as the parametrium. The cardinal ligament is in continuity anteriorly to the uterovaginal endopelvic fascia, and posteriorly, fibers are integrated with the uterosacral ligament. Since VRT is performed in patients with small lesions, only the medial part (i.e., approximately 2 cm) of the cardinal ligaments is usually taken at the time of a VRT (Figure 11.3).

Uterosacral Ligaments

These ligaments are true ligaments of musculofascial consistency that run from the upper part of the cervix to the sides of the sacrum. They contribute to the uterine support together with the cardinal ligaments. Only the proximal part of the uterosacral ligaments is taken at the time of VRT so as to leave adequate uterine support (Figure 11.3).

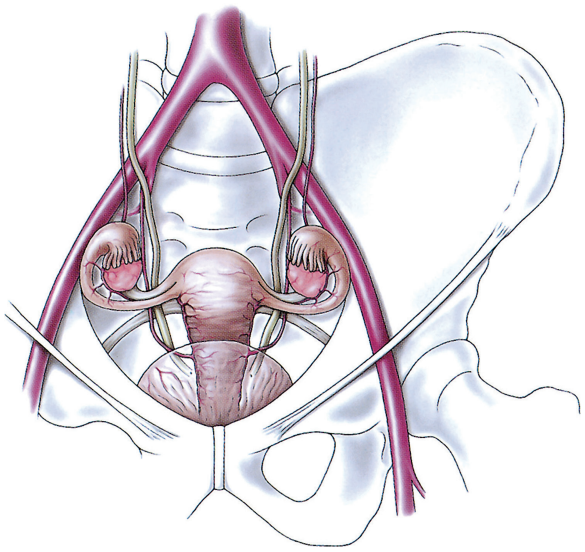

Figure 11.1 Cervical vascular supply.

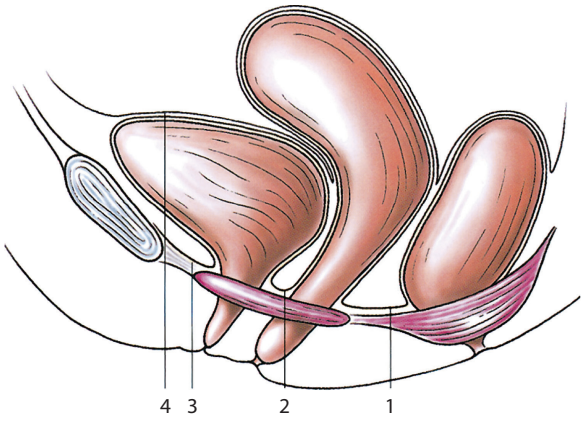

Figure 11.2 1: Rectal fascia; 2: uterovaginal fascia; 3: pelvic peritoneum; 4: urethrovesical fascia.

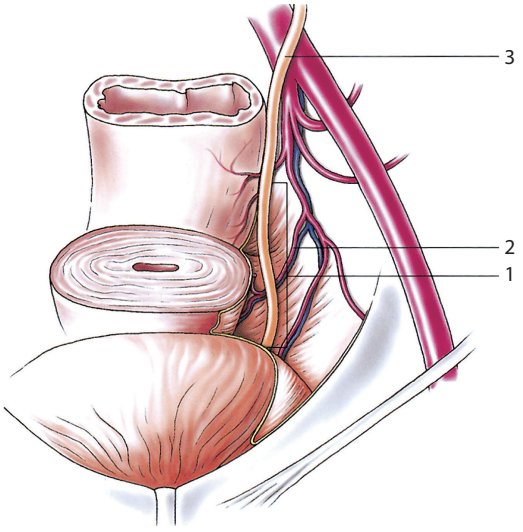

Figure 11.3 1: Cardinal ligament; 2: uterine artery; 3: ureter.

PROCEDURE

Anatomical Relationship

It is of paramount importance to understand the relationship between the ureter, the uterine artery, and the cardinal ligament (parametrium), and picture the relationship between the bladder base and the lower uterine segment when performing radical vaginal surgery. When a radical hysterectomy is performed abdominally, the uterus is pulled upward, bringing with it the parametrium and the uterine vessels, while the bladder base is mobilized downward. Therefore the uterine vessels lie above the concavity of the ureters as the ureters run into the parametrial tunnel to enter the bladder base. Thus, after mobilization, the ureters end up lateral and below the parametrium (Figure 11.4A). When the radical hysterectomy is performed vaginally, the relationship between the structures is completely the opposite. The uterus is pulled downward and the bladder base along with the ureter is mobilized upward. As such, the uterine vessels end up below the concavity, or the "knee," of the ureter, and after mobilization the ureter courses above the parametrium (Figure 11.4B).

Vaginal Cuff Preparation

A rim of vaginal mucosa is delineated circumferentially clockwise using 8 to 10 straight Kocher clamps placed at regular interval. For small lesions, 1 to 2 cm of vaginal mucosa is sufficient. To reduce bleeding from the edges of the vaginal mucosa, 20 to 30 cc of a xylocaine 1% solution mixed with epinephrine

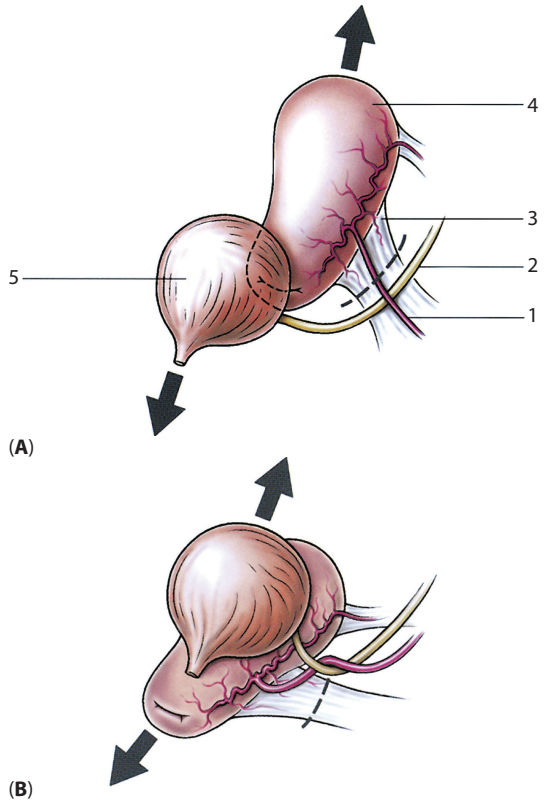

Figure 11.4 Comparison of (**A**) abdominal and (**B**) vaginal approaches to radical hysterectomy. The arrows indicate the direction of traction; the dotted line indicates the level of excision of the parametrium. 1: Uterine artery; 2: ureter; 3: parametrium; 4: uterus; 5: bladder. (Courtesy Dr Hélène Roy.)

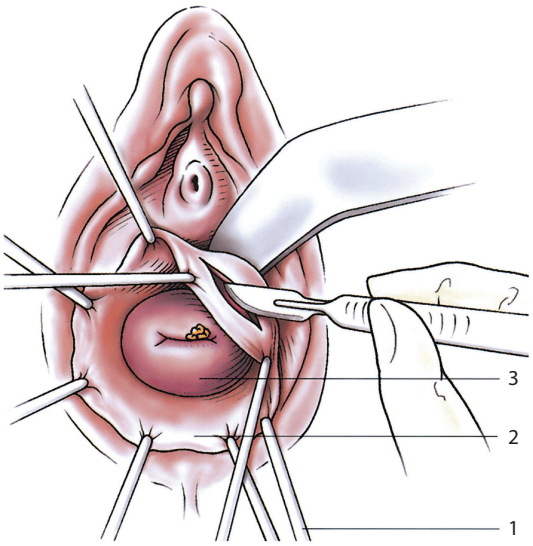

Figure 11.5 Vaginal cuff preparation: incision. 1: Straight Kocher clamps; 2: vaginal mucosa; 3: cervix. (Courtesy of Dr Hélène Roy.)

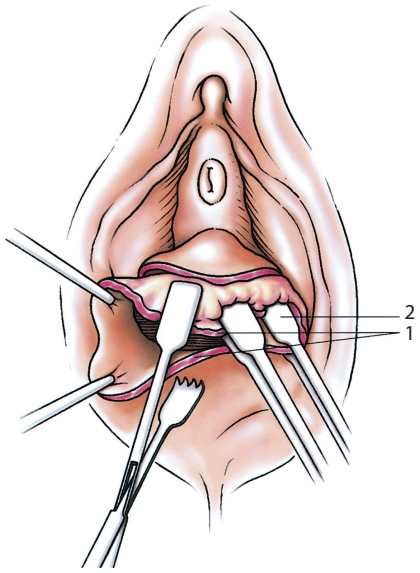

Figure 11.6 Vaginal cuff preparation: placing the clamps. 1: Anterior and posterior vaginal mucosa covering cervix; 2: chrobak clamps. (Courtesy of Dr Hélène Roy.)

1:100,000 is used to inject the vaginal mucosa between each Kocher clamp. A circumferential incision is then made with a scalpel just above the Kocher clamps (Figure 11.5). Finally, the edges of the vaginal mucosa are grasped with 5 or 6 Chrobak clamps in order to completely cover the exocervix and allow a good traction onto the specimen (Figure 11.6).

Identification of the Vesicouterine Space

This space is opened by directing Metzenbaum scissors perpendicular to the cervix. Care is taken to not enter the peritoneum as in a simple vaginal hysterectomy. The space should be avascular and allows one to easily palpate the anterior surface of the endocervix and isthmus and see the whitish body of the uterus and the bladder base. When the space is stretched with a narrow Deaver retractor, the anterior bladder pillars lie on each side of the space as vertical strands of tissue (Figure 11.7).

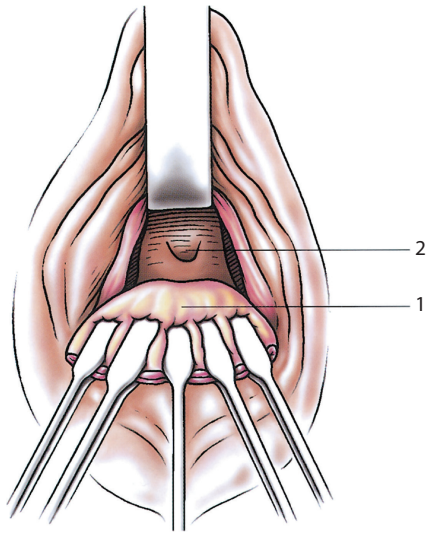

Figure 11.7 Opening the vesico-uterine space. 1: Endocervix; 2: uterine isthmus. (Courtesy of Dr Hélène Roy.)

Opening of the Paravesical Space (Description for the Patient's Left Side)

The Chrobak clamps are pulled toward the patient's right side. Straight Kocher clamps are placed onto the vaginal mucosa at 1 and 3 o'clock and stretched out. An areolar opening is seen just medial and slightly anterior to the 3 o'clock clamp. The space is blindly entered using Metzenbaum scissors, with the tips pointing upward and outward. The space is widened by rotating the scissors under the pubic bone in a semicircular rotating motion to the patient's right side (Figure 11.8).

Identification and Mobilization of the Ureter

A small retractor is placed in the left paravesical space and rotated under the symphysis pubis pulling the bladder pillars and the bladder medially. The knee of the ureter is located on

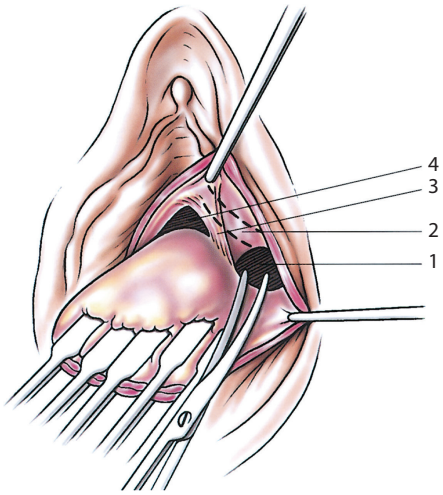

Figure 11.8 Opening the paravesical space. 1: Paravesical space; 2: ureter; 3: bladder pillars; 4: vesico-uterine space. (Courtesy of Dr Hélène Roy.)

the lateral aspect of the bladder pillars, which act as pseudo-ligaments (Figure 11.9). Holding the Chrobak clamps between the palms of both hands, the surgeon's right index finger (or the back of a surgical instrument) is placed in the left paravesical space and the left index finger in the vesicouterine space. The surgeon's fingers are then pulled down gently until the "click" is heard and the ureter is felt rolling under the fingers (Figure 11.10).

Section of the Bladder Pillars

To avoid damage, the ureter has to be seen and palpated unequivocally. With Metzenbaum scissors, the bladder pillars are stretched open and dissected carefully until the ureter is seen. Once the ureter has been safely mobilized upward, the bladder pillars can be excised midway between the bladder base and the anterior aspect of the specimen. The ureter is then freed laterally from its posterior attachment to allow its mobilization upward (Figure 11.11). Medial dissection of the ureter should be avoided because of the risk of injury to the bladder base. This maneuver allows the ureter and the bladder base to be mobilized upward as well.

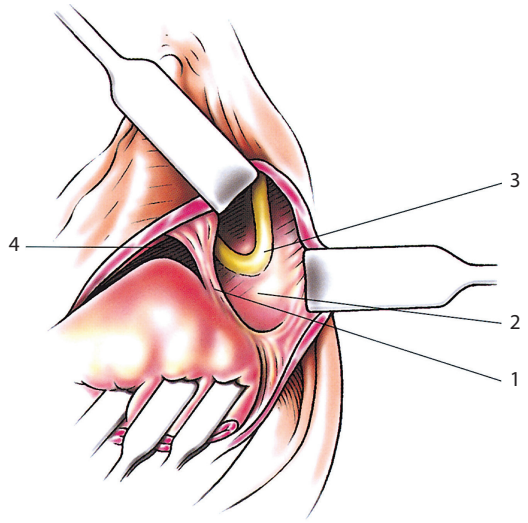

Figure 11.9 The 'knee' of the ureter is exposed on the lateral aspect of the bladder pillars. 1: Bladder pillars; 2: paravesical space; 3: knee of ureter; 4: vesico-uterine space. (Courtesy of Dr Hélène Roy.)

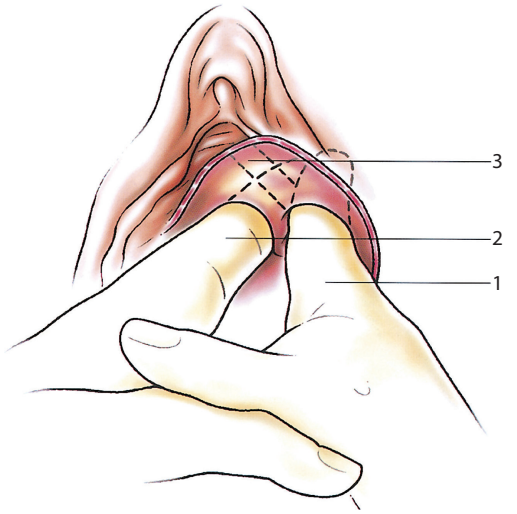

Figure 11.10 The ureter must be clearly seen and palpated, to avoid damage. 1: Right index finger in paravesical space; 2: ureter; 3: left index finger in vesico-uterine space. (Courtesy of Dr Hélène Roy.)

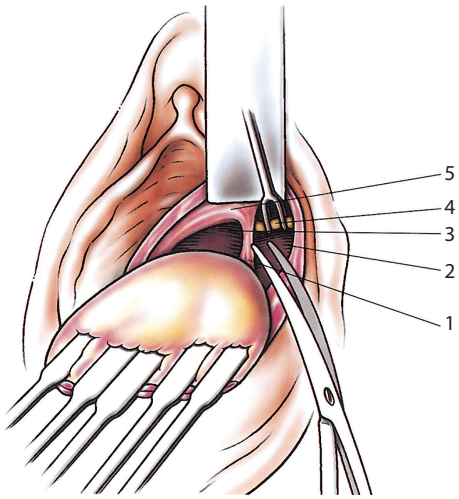

Figure 11.11 Excision of the bladder pillars. 1: Bladder pillars; 2: paravesical space; 3: vesico-uterine space; 4: ureter; 5: bladder base. (Courtesy of Dr Hélène Roy.)

Section of the Cardinal Ligament (Proximal Parametrium)

After opening the posterior cul-de-sac, the proximal aspect of the uterosacral ligament is excised. After careful re-identification of the ureter and the cross of the uterine artery, two curved Heaney clamps are used to secure the cardinal ligament or proximal parametrium. The first Heaney clamp is placed medially, and with gentle traction the second Heaney is placed more distally to get wider parametrium, having the ureter safely mobilized upward (Figure 11.12). The cervicovaginal branch of the uterine artery is then identified at the level of the isthmus, clamped,

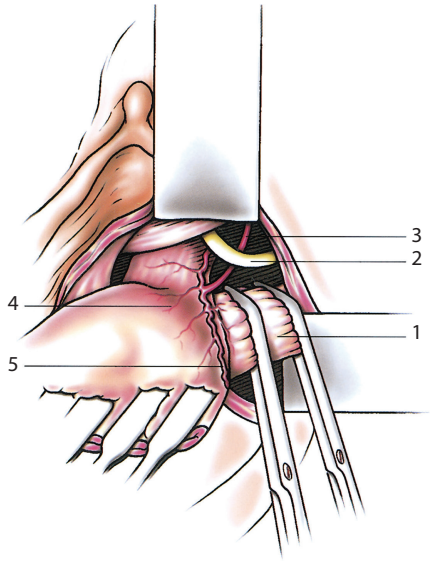

Figure 11.12 Excision of the parametrium. 1: Parametrium; 2: ureter; 3: uterine artery; 4: isthmus with cross of uterine artery; 5: descending branch of uterine artery. (Courtesy of Dr Hélène Roy.)

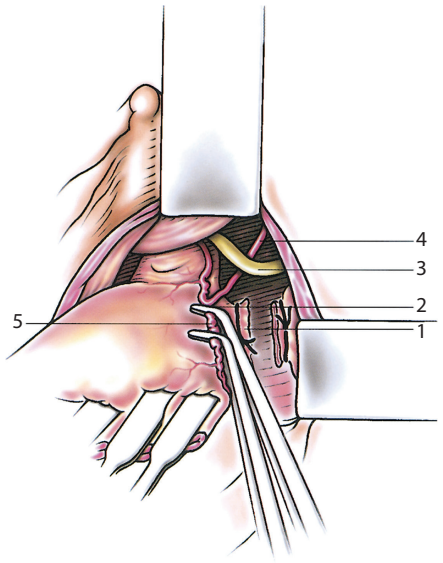

Figure 11.13 Care is needed to preserve the cross of the uterine artery. 1: Excised parametrium; 2: cross of the uterine artery; 3: ureter; 4: uterine artery; 5: descending branch of uterine artery. (Courtesy of Dr Hélène Roy.)

excised, and ligated. Care should be taken to identify and preserve the cross of the uterine artery (Figure 11.13).

Excision of the Specimen

The above steps are performed on the patient's right side. The cervix is then amputated with a scalpel held perpendicular to the specimen at about 1 cm from the isthmus. The new exocervix appears gradually (Figure 11.14). An endocervical curettage (ECC) of the residual endocervical canal is done afterward. The trachelectomy specimen is sent for immediate frozen section to assess the level of the tumor in relation to the endocervical resection margin. At least 8 to 10 mm of free endocervical canal should be obtained, otherwise additional endocervix should be removed, or the trachelectomy should be aborted and a radical vaginal hysterectomy (Schauta) completed instead. Indications and methods of frozen section of vaginal trachelectomy specimen have been proposed (Chênevert et al. 2009).

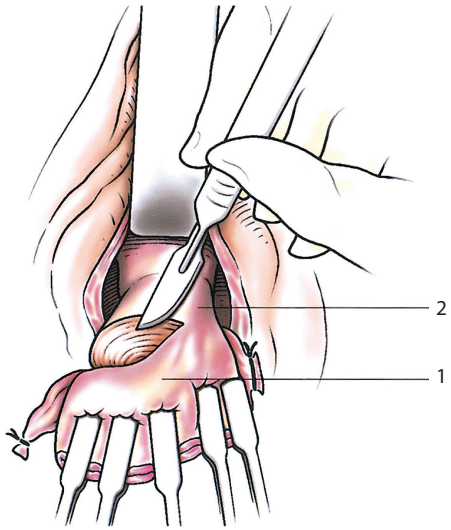

Figure 11.14 Excision of the cervix. 1: Trachelectomy specimen; 2: residual endocervix. (Courtesy of Dr Hélène Roy.)

Prophylactic Cervical Cerclage and Closure of the Vaginal Mucosa

The posterior cul-de-sac is first closed with a purse-string suture of Chromic 2-0 suture. A permanent cerclage is then placed using a nonresorbable Prolene-0 suture starting at 6 o'clock to have the knot lying posteriorly. Sutures are placed at the level of the internal os and not too deeply within the cervical stroma. When tying the knot, a uterine probe can be left in the cervical os to avoid tightening the knot too much, as this may cause cervical stenosis (Figure 11.15). The edges of the vaginal mucosa are sutured to the residual exocervical stroma (and not to the endocervical tissue) with interrupted figure-of-eight. Sometimes excess vaginal mucosa has to be excised to facilitate the closure. Sutures should not be placed too close to the new cervical os to avoid burying the cervix, making follow-up examinations more difficult (Figure 11.16).

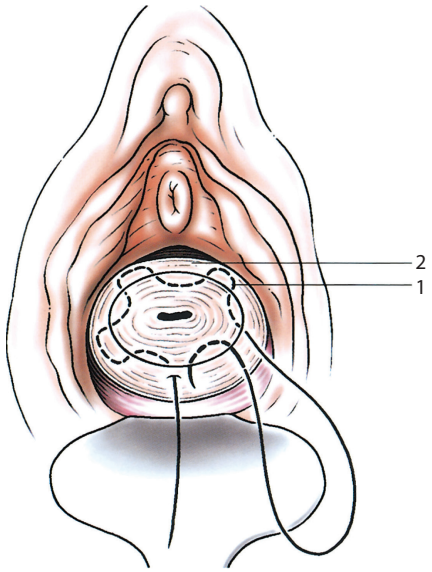

Figure 11.15 Placing the cervical cerclage. 1: Suture; 2: new ectocervix. (Courtesy of Dr Hélène Roy.)

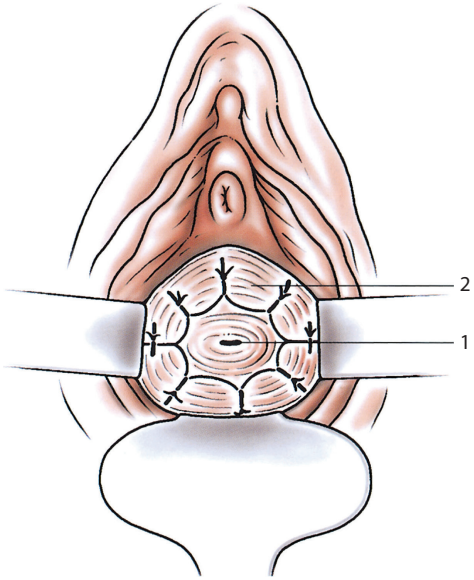

Figure 11.16 Closure of vaginal mucosa. 1: New external os; 2: new ectocervix. (Courtesy of Dr Hélène Roy.)

Trachelectomy Specimen

Ideally, the cervical specimen should be at least 1 cm long, with 1 cm of vaginal mucosa and 1 to 2 cm of parametrium. Figure 11.17 shows a cervix with a small exophytic lesion (A); (B) shows a lateral view of the trachelectomy specimen demonstrating the endocervical cut margin, proximal parametria (stretched by the Debakey instruments), and vaginal cuff (suture) covering the cervical lesion; (C) shows the appearance of the cervix after suturing of the vaginal mucosa to the residual exocervix.

Cervical Appearance after a Trachelectomy Procedure

With time, the new cervix gradually resumes an almost normal appearance except for its shorter length. It therefore remains accessible for monitoring with colposcopic examination, cytology, and ECC. Figure 11.18 shows pictures of the cervix 6 months after a trachelectomy (A) and in the first trimester in a patient who became pregnant after the procedure (B).



(**A**)

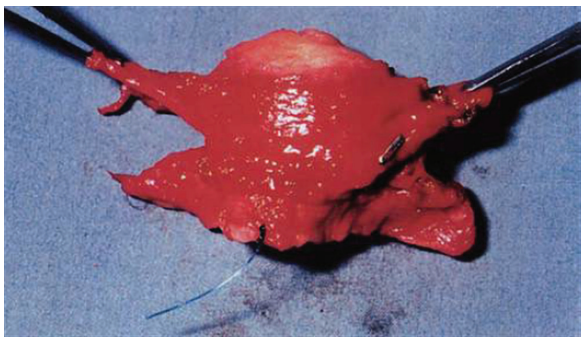

(**B**)

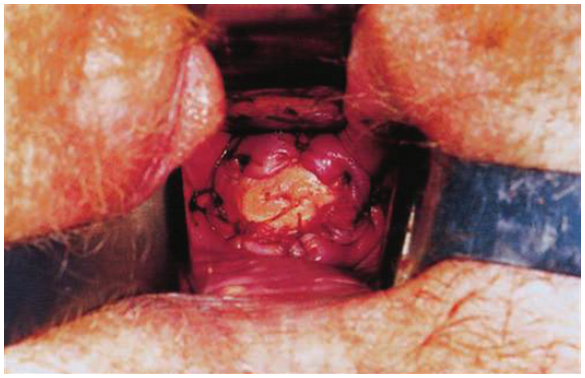

(**C**)

Figure 11.17 Example of trachelectomy specimen. (**A**) Exophytic lesion; (**B**) lateral view; (**C**) after closure.

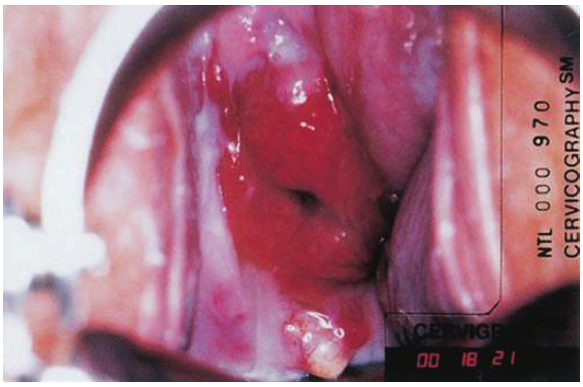

(**A**)

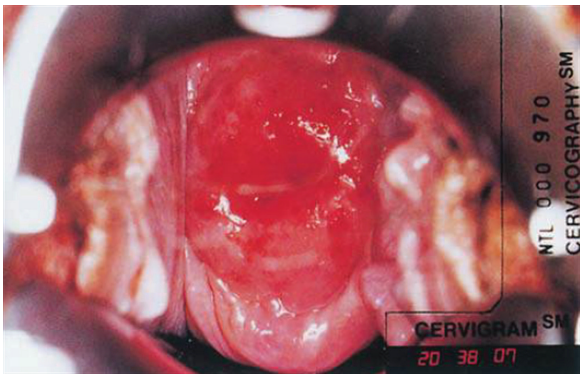

(**B**)

Figure 11.18 Postoperative appearance. (**A**) Six months after RVT; (**B**) first trimester of a subsequent pregnancy.

RESULTS

The radical trachelectomy procedure has gained wider acceptance and recognition over the years. Data totalizing over 1000 cases from the six largest series has recently been summarized elsewhere and are briefly reviewed here (Plante 2013).

Oncologic Results

Over 1000 cases of vaginal radical trachelectomies have been reported so far in the literature (Plante et al. 2013). The recurrence rate has remained below 5% and the death rate is under 2%. This is comparable to the overall outcome following the standard radical hysterectomy for similar size lesions. In his analysis of 96 cases, Dargent has noted that the most important risk factors in terms of recurrence were the size of the lesion (>2 cm) and depth of stromal invasion (>1 cm). The presence of vascular space invasion and age <30 were almost statistically significantly associated with the risk of recurrence (Dargent et al. 2002). In their series of 125 VRT, Plante et al. (2011) also noted that the only factor that was statistically associated with a higher risk of recurrence was the size of the lesions >2 cm.

Some of the recurrences reported have occurred in the lymph nodes, which probably represents a failure of the lymphadenectomy itself. Other recurrences have been reported in the parametrial area, which probably represents a failure of the trachelectomy and potentially an inadequate removal of parametrial tissue. Very few recurrences have been reported on the residual cervix itself.

Obstetrical Results

Over 450 pregnancies have been reported in cases of early-stage cervical malignancy (Plante 2013). The rate of first trimester loss is in the range of 17%, which is comparable to the rate in the general population. However, the rate of second trimester loss is slightly less than 10%, which is higher than in the general population. It is believed to be secondary to the short cervix and the less effective mucus plug, which normally acts as a natural barrier against ascending infection. Subacute chorioamnionitis probably eventually leads to premature contractions and premature labor and delivery. It is unknown at this point whether prophylactic cultures and antibiotic coverage is beneficial. Some authors suggest the routine injection of prophylactic steroids to hasten fetal lung maturation in case of premature delivery (Bernardini et al. 2003). Others have suggested the use of progesterone supplements, reduction of physical activities, monitoring of the cervical length with serial endovaginal ultrasounds, prophylactic antibiotics, etc. (Jolley et al. 2007). Ideally, a multidisciplinary team including an oncologist, maternal-fetal medicine, and neonatologist should be involved in the care and evaluation of pregnant women post trachelectomy. However, overall, two-thirds of the pregnancies will reach the third trimester, and of those, two-thirds will deliver at term (Plante 2013).

Fertility Results

Following a radical trachelectomy procedure, up to 80% of women attempting to conceive have been successful (Plante 2008). The estimated cumulative fertility rate is in the range of 55% (Bernardini 2003). The majority of women experiencing fertility problems are due to causes unrelated to the trachelectomy issues (ovulatory dysfunction, endometriosis, male factor, etc.). However, cervical stenosis, which occurs in up to 10% to 15% of women post trachelectomy, may be a cause of infertility. Managing the tight pinpoint stenosis causes special challenges for the infertility specialist and often limits the possibility of intrauterine insemination and embryo transfer following in vitro fertilization. New options and tools have been developed to assist the infertility specialist in dealing with those obstacles (Noyes et al. 2009). Women undergoing fertility-preserving surgery in the hope of conceiving often experience a high level of anxiety postoperatively, and may require emotional support (Carter et al. 2008).

SUMMARY

The radical trachelectomy has now been performed for approximately 30 years. Data are accumulating indicating that the procedure is oncologically safe in well-selected cases: young women, small lesions (<2.5 cm), limited endocervical extension, and limited VSI. Obstetrically, data are also accumulating indicating that two-thirds of patients can anticipate a normal pregnancy and delivery near term. However, the risk of premature second trimester loss or delivery is higher than in the general population and these pregnancies should probably be managed jointly with a fetal-maternal medicine consultant. Thus the radical trachelectomy procedure truly offers a valuable alternative to young women with small lesions who wish to preserve their fertility potential.

For women with larger size lesions, the option of neoadjuvant chemotherapy to reduce the size of the lesion, followed by a fertility-sparing radical trachelectomy procedure is an interesting alternative. Data from five series have recently been summarized (Plante 2015). Upfront abdominal radical trachelectomy as described in Chapter 12 also appears to be oncologically acceptable for larger size lesions, although the risk of requiring adjuvant radiation therapy is significant (Plante 2015).

There has been a recent trend toward even more conservative procedures in patients with lesions <2 cm, as the risk of parametrial invasion has been estimated to less than 1% (Schmeler et al. 2011). In the future, even more conservative procedures such as conization alone or simple trachelectomy with lymph node assessment may be sufficient in women with very early lesions and in the absence of high risk features (Plante 2017).

REFERENCES

Bernardini M, Barrett J, Seaward G, et al. 2003. Pregnancy outcome in patients post radical trachelectomy. *Am J Obstet Gynecol* **189**:1378–82.

Carter J, Sonoda Y, Chi DS, et al. 2008. Radical trachelectomy for cervical cancer: Postoperative physical and emotional adjustment concerns. *Gynecol Oncol* **111**:151–7.

Chênevert J, Têtu B, Plante M, et al. 2009. Indication and method of frozen section in vaginal radical trachelectomy. *Internat J Gynecol Pathol* **28**:480–8.

Dargent D, Brun J-L, Roy M, et al. 1994. La trachélectomie élargie (T.E.). Une alternative à l'hystérectomie radicale dans le traitement des cancers infiltrants développés sur la face externe du col utérin. *J Obstet Gynecol* **2**:285–92.

Dargent D, Franzosi F, Ansquer Y, et al. 2002. Extended trachelectomy relapse: Plea for patient involvement in the medical decision. *Bull Cancer* **89**:1027–30.

Jolley JA, Battista L, Wing DA. 2007. Management of pregnancy after radical trachelectomy: Case reports and systematic review of the literature. *Am J Perinatol* **24**:531–9.

Noyes N, Abu-Rustum N, Ramirez P, et al. 2009. Options in the management of fertility-related issues after radical trachelectomy in patients with early-stage cervical cancer. *Gynecol Oncol* **114**:117–20.

Plante M. 2000. Fertility preservation in the management of gynecologic cancers. *Curr Opin Oncol* **12**(5):497–507.

Plante M. 2008. Vaginal radical trachelectomy: An update. *Gynecol Oncol* **111**:S105–10.

Plante M. 2013. Evolution in fertility-preserving options for early-stage cervical cancer: Radical trachelectomy, simple trachelectomy, neoadjuvant chemotherapy. *Int J Gynecol Cancer* **23**(6):982–9.

Plante M. 2015. Bulky early-stage cervical cancer (2–4 cm lesions): Upfront radical trachelectomy or neoadjuvant chemotherapy followed by fertility-preserving surgery: Which is the best option? *Int J Gynecol Cancer* **25**(4): 722–8.

Plante M, Gregoire J, Renaud MC, et al. 2011. The vaginal radical trachelectomy: An update of a series of 125 cases and 106 pregnancies. *Gynecol Oncol* **121**(2):290–7.

Plante M, Gregoire J, Renaud MC, et al. 2013. Simple vaginal trachelectomy in early-stage low-risk cervical cancer: A pilot study of 16 cases and review of the literature. *Int J Gynecol Cancer* **23**(5):916–22.

Plante M, Renaud MC, Sebastianelli A, Gregoire J. 2017. Simple vaginal trachelectomy: A valuable fertility-preserving option in early-stage cervical cancer. *Int J Gynecol Cancer* **27**(5):1021–1027.

Ramirez PT, Pareja R, Rendón GJ, Millan C, Frumovitz M, Schmeler KM. 2014. Management of low-risk early-stage cervical cancer: Should conization, simple trachelectomy, or simple hysterectomy replace radical surgery as the new standard of care? *Gynecol Oncol* **13**(1):254–9.

Roy M, Plante M. 1998. Radical trachelectomy in the treatment of early stage cervical cancer. *Am J Obstet Gynecol* **179**:1491–6.

Schmeler KM, Frumovitz M, Ramirez PT. 2011. Conservative management of early stage cervical cancer: Is there a role for less radical surgery? *Gynecol Oncol* **120**(3):321–5.

12 Radical abdominal trachelectomy

Laszlo Ungar, Laszlo Palfalvi, Srdjan Saso, Benjamin P. Jones, Giuseppe Del Priore, and J. Richard Smith

INTRODUCTION

Carcinoma of the cervix is the second most common cancer in women in developing countries and remains a leading cause of death worldwide. Despite the introduction of a successful screening program in many developed countries, 45% of surgically treated stage IB cancers still occur in women under the age of 40 years. Given the increasing age of nulliparity in developed countries and the adverse impact of unwelcome infertility following hysterectomy, fertility-sparing procedures now demand serious consideration when contemplating treatment options for women keen to preserve their fertility.

FIGO STAGING

The traditional management of invasive cervical carcinoma has naturally depended upon the stage of the tumor (see Table 5.2). As outlined in Chapter 8, conization is suitable management for cervical intraepithelial neoplasia (CIN) and stage IA1 tumors. It is also probably satisfactory management for the majority of stage IA2 tumors. Table 12.1 shows the papers published relating to extracervical spread of microinvasive tumors, suggesting that the majority will be adequately managed by conization. Most gynecologic oncologists would ratify this, depending on whether lymphovascular permeation was present. If it was, they might proceed to a radical hysterectomy and pelvic lymphadenectomy. As can be seen from the table, this practice is not strictly evidence based. It should be noted that according to current FIGO definitions, some of the tumors referred to in the table would now be staged beyond IA2 by virtue of their lateral dimensions; however, this serves to further confirm that radical hysterectomy is potentially overtreatment in many cases. Traditionally, stage IB1, IB2, and IIA tumors have been managed by radical hysterectomy and pelvic lymphadenectomy, although many centers now utilize primary chemoradiotherapy for stage IB2 and IIA tumors, owing to seemingly equivalent outcomes and reduced morbidity associated with dual modalities of therapy in the presence of high-risk features. Stage IIB, III, and IV tumors are managed by radiotherapy, chemotherapy, and surgery, either singly or in combination, dependent upon the individual center and the individual patient. Units vary on their policy for commencing radiotherapy depending on the number of lymph nodes involved.

An increasing number of young women are being diagnosed with invasive cervical cancer, probably due to earlier detection, at both earlier age and stage, through the cervical screening program. This called for a drive toward a less radical treatment than radical hysterectomy and pelvic lymphadenectomy, while maintaining high cure rates but, importantly, allowing preservation of fertility.

The late Daniel Dargent and Michel Roy describe in Chapter 10 the radical vaginal hysterectomy (Dargent et al. 2000). Expertise in this procedure is the prerequisite to having the skill required for a new technique described for removal of exophytic tumors, stages IA2 to IIA, which were unsuitable for treatment by conization. Dargent called this procedure "radical vaginal trachelectomy." It involves laparoscopic pelvic lymphadenectomy followed by removal of the cervix, parametrium, and upper vagina via the vaginal route. This requires considerable skill in both vaginal and laparoscopic techniques. Gynecological oncologists have acquired laparoscopic skills to complement their open surgical skills, but fewer have undertaken the training necessary to perform radical vaginal hysterectomy. For this reason, we have been involved in developing an abdominal approach to radical trachelectomy which is technically similar to a traditional radical hysterectomy but still offers prospects for future fertility.

When considering more conservative surgery, one has to consider both the pathology of the disease and its mode of metastasis. The spread of squamous cervical carcinoma is predominantly lateral; it may be continuous, where the tumor spreads in a confluent manner toward the pelvic sidewall, or discontinuous, with vessel or parametrial node involvement.

Vertical spread of cervical cancer is much less common than lateral disease. In Burghardt's series of 395 women, there were no cases of vertical spread in any stage IB or IIA tumors, while 11 out of 220 cases (20%) of stage IIB tumors had spread to the uterine corpus (Burghardt et al. 1991). Age appears to be an important factor in spread to the uterine body. Baltzer (1978) found that in women under the age of 50 the vertical spread of stage IIB tumors was 9.5%, whereas in women over 50 years old the figure rose to 32%.

ANATOMICAL CONSIDERATIONS

To retain fertility without the need for assisted conception techniques, a woman must retain her ovaries, fallopian tubes, uterus, a residuum of cervix with a patent cervical os, and a functioning vagina. With the use of assisted conception and ovum donation techniques, a woman requires as an absolute minimum to have retained her uterus and perhaps a tiny slip of cervix to retain a cervical cerclage suture.

VASCULAR CONSIDERATIONS

The uterus is supplied by three pairs of arteries: the uterine, ovarian, and vaginal arteries, the latter two via collateral circulation. Viability of the uterus can certainly be maintained in the absence of uterine arteries, but it was initially thought to only be the case if there was no interruption of the ovarian or vaginal arterial supply. At the Society of Gynecologic Oncology (SGO) meeting in New Orleans in February 1996,

Table 12.1 Results of Pelvic Lymphadenectomy in Microinvasive Carcinomas (65 mm Invasion, Early Stromal Invasion Excluded)

Author, Year	No. depth (%)	Maximal size (%)	CLS involvement (%)	Confluent Pattern (%)	Lymph-Node Involvement	Died of Disease
Roche and Norris 1975	30	5 mm	57	37	0	–
Sedlis et al. 1979	74	5 × 3 > 8 mm	NS	22.5 (of 133 cases)	0	–
Lohe et al. 1978	37	5 × 10 mm	NS	NS	0	–
Taki et al. 1979	55	3 mm	0	0	0	–
Hasumi et al. 1980	29	3.1–5 mm	11.1	100	4	–
van Nagell et al. 1983	52	3.1–5 mm			3	–
Creasman et al. 1985	32	5 mm	15.6 (of 95 cases)	20 (of 96 cases)	0	–
Simon et al. 1986	69	5 × 12 mm	6.6 (of 105 cases)	NS	1	–
Maiman et al. 1988	30	3.1–5 mm				
Kolstad 1989	63	5 mm	16.1 (of 411 cases)	NS	1	–
Burghardt et al. 1991	39	5 × 10 mm	NS	NS	0	–
Creasman et al. 1998	51	5 mm	25	NS	0	–

Abbreviations: CLS, capillary-like space; NS, not stated.
Source: Adapted from Burghardt E. 1993. Cervical cancer. In: Burghardt E, Webb MJ, Monaghan JM, Kindermann G, eds. *Surgical Gynecologic Oncology*. New York: Thieme, p. 306.

the membership in an interactive session were asked to vote on how many vessels they felt were required for uterine preservation. The majority felt that the uterus required three of its six supplying vessels to remain viable. Interestingly, we now know that uterine viability may be maintained by the ovarian arteries alone, as demonstrated by the several hundreds of successful radical abdominal trachelectomies already undertaken worldwide.

ONCOLOGICAL CONSIDERATIONS

Any form of radical surgery for treatment of cervical carcinoma requires the removal of at least the cervix, some of or all of the parametrium and upper vagina, along with pelvic lymphadenectomy. The extent of parametrial resection required is still a subject of controversy (Hagen et al. 2000). Pelvic lymphadenectomy should involve removal of the paracervical, presacral, obturator, and internal, external, and common iliac nodes, and possibly also the para-aortic nodes.

Plante and Roy describe the vaginal approach to radical trachelectomy in Chapter 11. Laparoscopic and robotic lymphadenectomy techniques are described in Chapters 26 and 28, respectively.

OPERATIVE PROCEDURE

Figure 12.1 demonstrates the area to be removed and the vascular supply to the uterus. In our technique for performing a radical abdominal trachelectomy, the abdomen is opened in standard fashion, through either a midline incision or a modified Cherney incision, and the operation proceeds initially like a standard radical abdominal hysterectomy. The dissection commences by dividing the round ligaments, opening the broad ligament and the paravesical, and pararectal spaces (Figure 12.2).

The ovarian pedicles must be handled with great care and preserved at all costs. The external iliac, common iliac, internal iliac, and obturator nodes are removed (Figure 12.3). The ureter is dissected from its entry into the pelvis until it runs under the uterine artery. The dissection of the anterior division of the

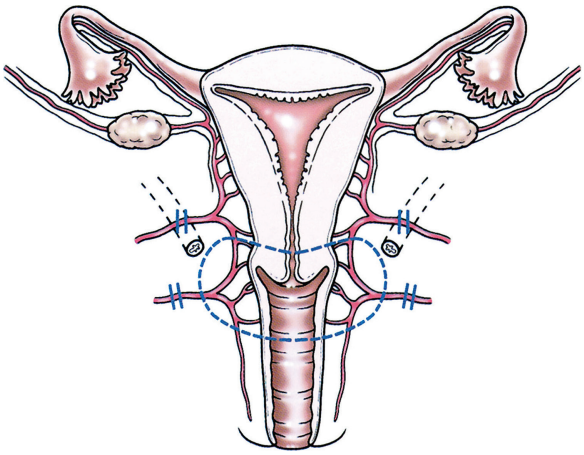

Figure 12.1 The area to be removed during the procedure.

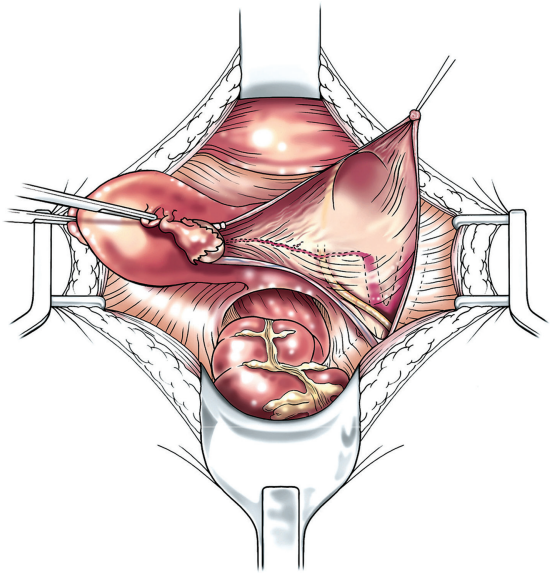

Figure 12.2 The round ligaments are divided and the broad ligament opened onto the pelvic sidewall.

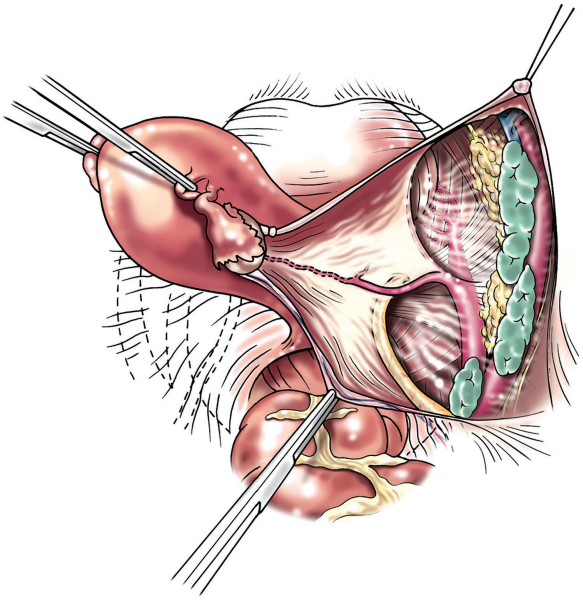

Figure 12.3 The internal iliac and uterine arteries are skeletonized.

internal iliac artery into the superior vesical and uterine vessels is continued with skeletonization of the proximal part of these vessels (Figure 12.4). The uterine artery is ligated at its origin unless the procedure is being performed in a pregnant woman, where meticulous dissection must ensure it is not damaged. The ureteric tunnels are then opened and dissected and the bladder deflected anteriorly (Figure 12.5). In method 1, the rectovaginal septum is opened to the level of the pelvic floor. The uterosacral ligaments are divided close to the sacrum and the vagina and parametrium are then incised. The uterus, cervix, upper third of vagina, and parametrium are then swung superiorly, still attached to the ovarian pedicle (Figure 12.6). This allows excision of the cervix, parametrium, and upper vagina (Figure 12.7). A small residuum of cervix may be left as the site

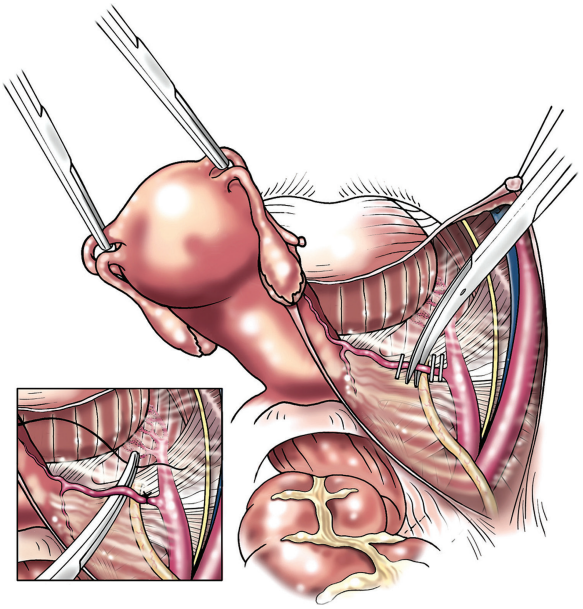

Figure 12.4 The uterine artery is divided close to its origin following application of hemoclips or ligation (see the inset).

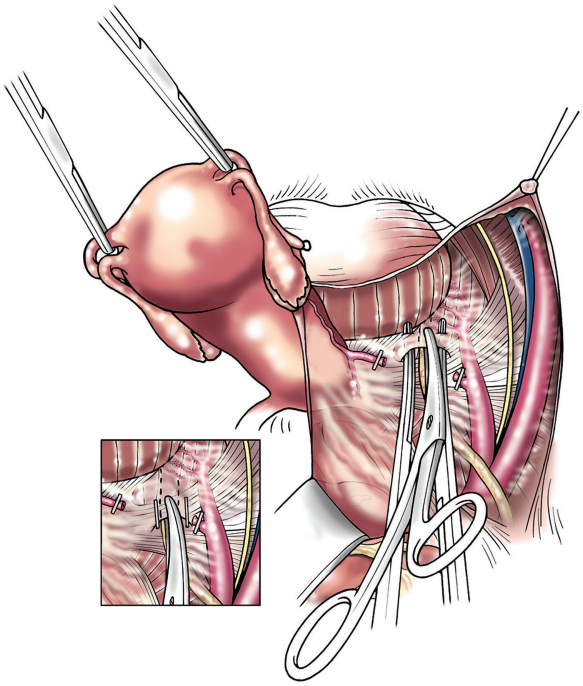

Figure 12.5 The ureteric tunnel is opened. Bleeding can be profuse at this point and the application of hemoclips or the use of Lotus harmonic scissors may be helpful. (From Lotus, S.R.A. Developments Ltd., Bremridge House, Ashburton, South Devon TQ13 7JK, UK.)

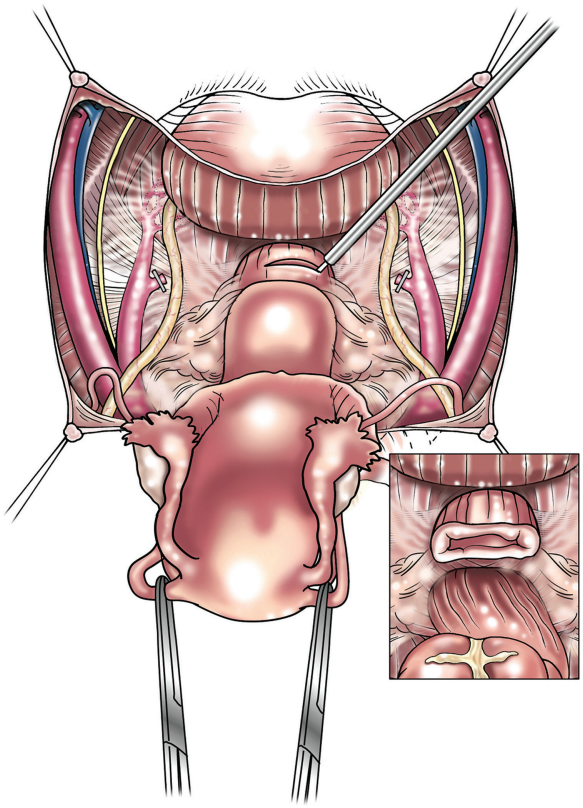

Figure 12.6 The vagina has been incised. Arterial supply at this point is via the ovarian vessels alone.

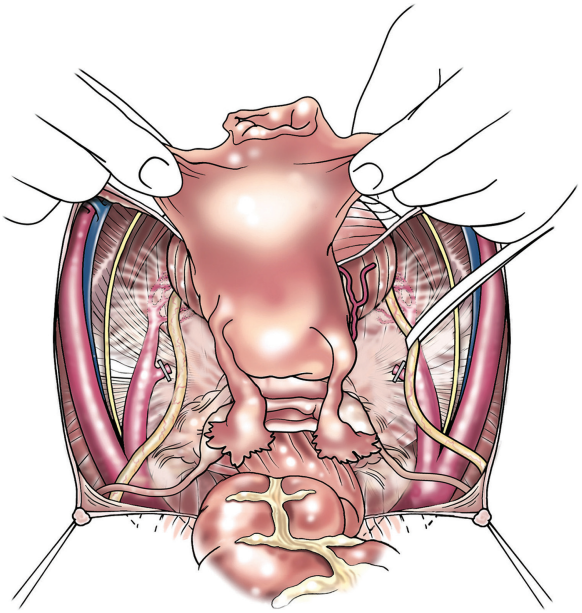

Figure 12.7 The uterus, cervix, and parametrium are shown here, swung superiorly with the ovaries and uterine tubes attached.

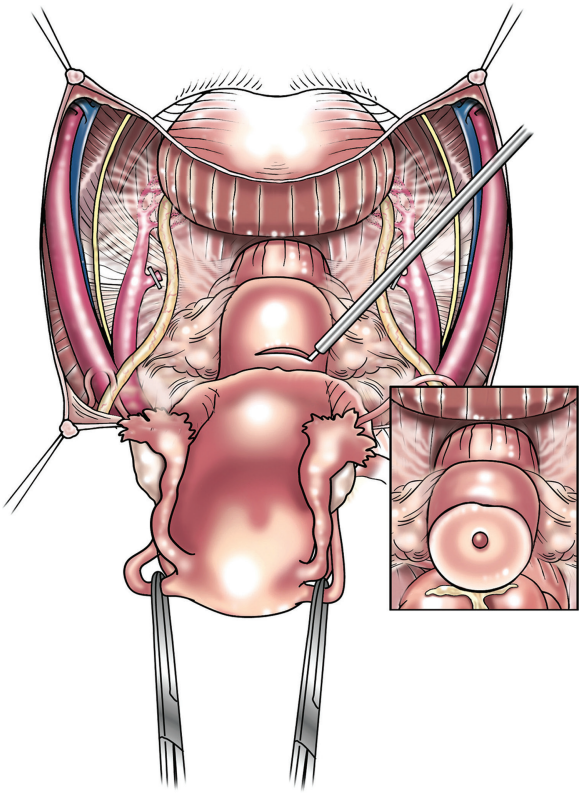

Figure 12.8 The uterocervico junction is transected.

for inserting a cervical cerclage suture. In method 2, it is also possible to cut across the cervix/cervicouterine junction (Figure 12.8) and place the uterus still attached to the ovarian vessels into the abdomen (Figure 12.9). One can then undertake the opening of the rectovaginal septum and radical removal of cervix, parametrium, and vagina without danger of damaging the uterus (Figure 12.10).

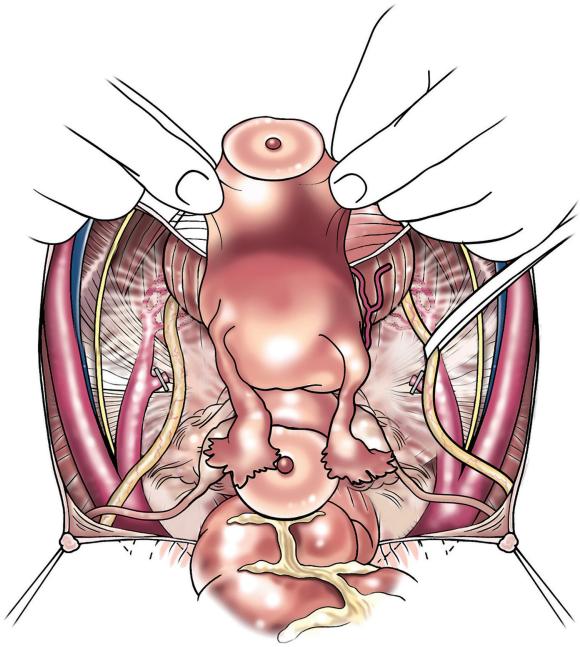

Figure 12.9 Insertion of the cervical suture with the knot placed posteriorly. This allows the uterus to be placed in the abdomen prior to completion of the trachelectomy.

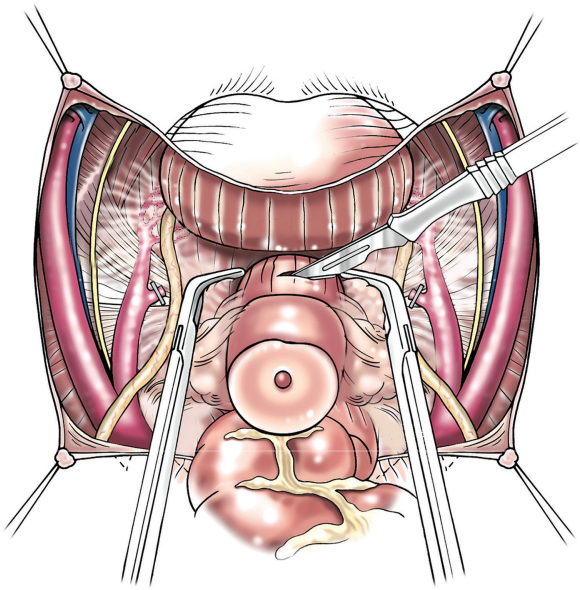

Figure 12.10 The parametrium is clamped, divided, and ligated. Alternatively, Lotus harmonic scissors may be used.

The authors have utilized both methods. Whichever method is used, frozen section histological examination should be performed on tissue from the upper surface of the cervix, to ensure adequate resection margins, and also from lymph nodes. If the cervix demonstrates inadequate resection margins or the pelvic lymph nodes contain tumor, the procedure is abandoned and a full radical hysterectomy performed.

Assuming the margins to be acceptable, if a thin plate of cervix has been retained, a cervical cerclage suture may be inserted. Polypropylene can be used with the knot tied so as to lie posteriorly (Figure 12.11), to facilitate easy removal by the vaginal

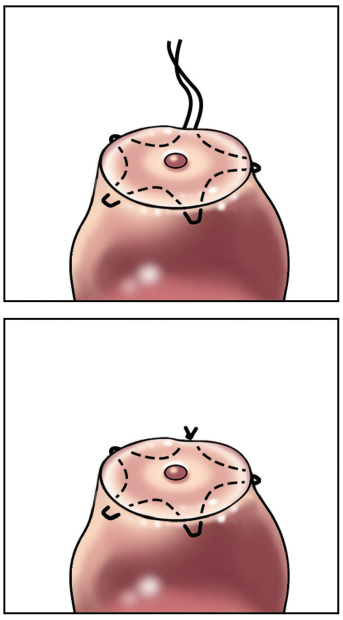

Figure 12.11 Insertion of cervical suture with care to apply the knot posteriorly.

route via the pouch of Douglas, should this ever be required. In addition, it prevents potential bladder irritation by the knot. The vast majority of cases have been performed without use of a cerclage suture, and in many cases the cervix has been removed in its entirety.

The next step is to re-anastomose the cervical plate/lower part of the uterus to the vagina. The authors have utilized two methods, one being insertion of a circumferential single-layer running suture between uterus and vaginal cuff (Figures 12.12 and 12.13), the other being insertion of six interrupted

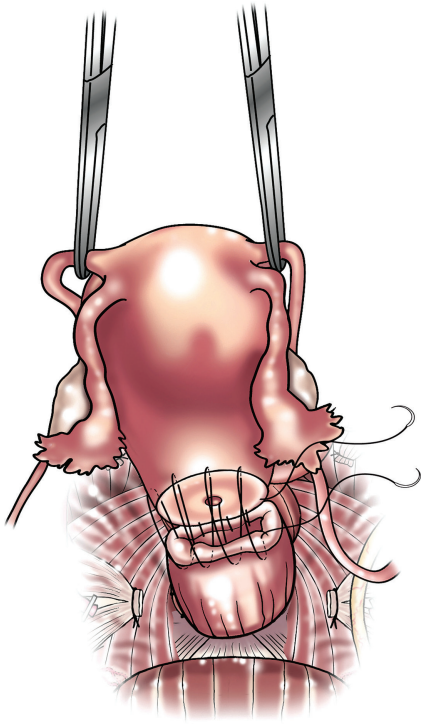

Figure 12.12 Insertion of the circumferential single layer running suture to achieve final end result.

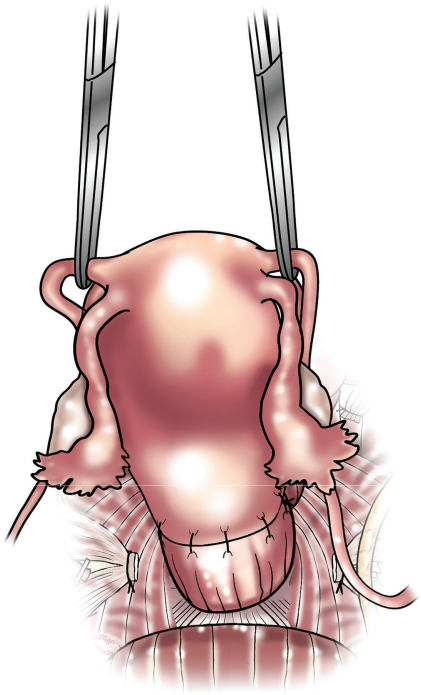

Figure 12.13 Insertion of the circumferential single layer running suture to achieve final end result.

sutures running from the outside of the vagina to the inside, then through the cervical plate from inside to outside. If this method is used it is made easier by moistening the polyglactin sutures with lubricating jelly. After the six sutures are inserted, the uterus is "parachuted" into position and the sutures ligated (Figures 12.14 and 12.15). Figure 12.16 shows the end result. The abdomen is then closed in standard fashion.

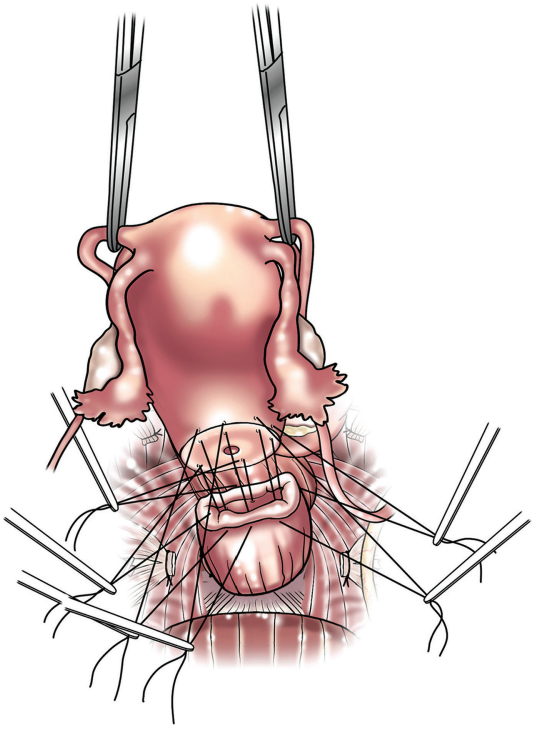

Figure 12.14 Insertion of six interrupted sutures to allow the uterus to be parachuted back into position to achieve the final end result.

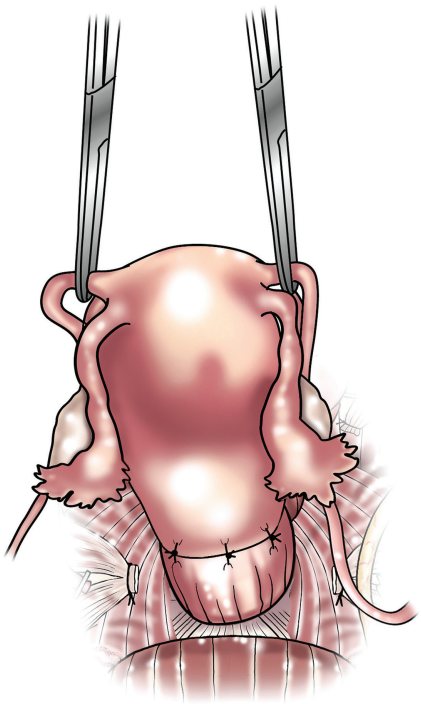

Figure 12.15 Tying parachute sutures brings uterine fundus onto residual vaginal canal. A temporary pediatric Foley placed into the fundus and inflated, can help guide the alignment.

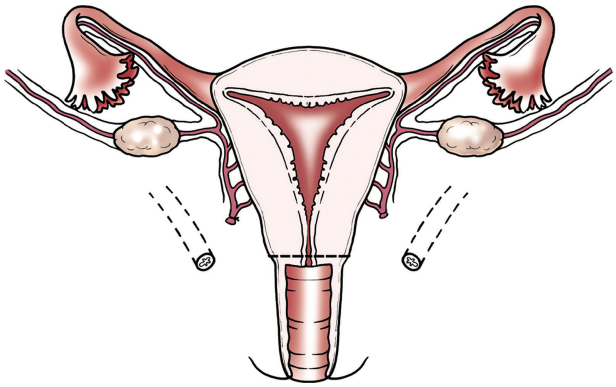

Figure 12.16 Shows an overview of the final result.

POST-OPERATIVE CONSIDERATION

Criticism of our procedure is not oncological, since our operation, in terms of clearance, is virtually the same as a radical hysterectomy and we believe has equal capacity to deliver clearance of tumor. Either a portion of or all the parametrium can be removed, depending upon the tumor being excised (Li et al. 2011).

The authors have now performed the operation in approximately 400 women. When the data were fully analyzed for presentation at the SGO conference in Palm Springs in 2007, it included 91 patients. The procedure was completed in 83 patients. Seven were abandoned after positive pelvic nodes (six patients were stage IB2, and one was stage IB1) and one had involvement of the cervical uterine margin. Of the 83 who completed the procedure, 11 were stage IA2, 54 stage IB1, and 18 stage IB2.

During follow-up, one patient subsequently underwent a hysterectomy following an abnormal cervical smear result (the histology was subsequently negative). The median follow-up was 30 months (range 4–99 months). Normal menses resumed within 12 weeks in 95.2% of women. There were two recurrences (2.4%). One initially had a rapidly growing exophytic stage IB1 SCC with negative lymph nodes and good margins, and had a large vaginal recurrence after 6 months. The other had a 5-cm stage IB2 glassy cell adenocarcinoma with LVSI and perineural spread positive. She developed a recurrence 14 months later. In the original series, two women have delivered live, healthy babies by caesarean section with no complications (Palfalvi et al. 2003). The babies weighed 3200 and 3350 g despite the reliance on ovarian vessels alone. Doppler flow studies in pregnancy unsurprisingly showed massively increased flow via these vessels. In the total series of 83, there have been five term deliveries, one pre-term at 36 weeks, and at the time of analysis there were three ongoing gestations. There were four spontaneous first trimester miscarriages.

In addition, five women have undergone the procedure during pregnancy between 7 and 18 weeks. Two had spontaneous first trimester miscarriage 2 days post-procedure and one had a second trimester miscarriage 3 weeks following the operation. Two were delivered by elective caesarean section at 39 weeks (Ungar et al. 2006). Further successful operations during pregnancy have since been reported.

In an analysis at the West London Gynecological Centre, 30 patients underwent abdominal radical trachelectomy between 2000 and 2009, 27 of which were performed utilizing an open approach; the remaining three were undertaken laparoscopically. Three patients presented with recurrence, two of whom died, while the other is in remission following chemoradiotherapy. Ten patients attempted to conceive, resulting in three conceptions and two live births. Both live births were conceived spontaneously and were delivered at 37 weeks' gestation by caesarean section (Saso et al. 2012). In a recent systematic review including 485 patients, 85% of patients maintained their fertility after radical abdominal trachelectomy, and of those who attempted to become pregnant 59.3% were able to conceive (Pareja et al. 2013). These conception rates are similar to the 5-year cumulative pregnancy rate of 52.6% described in 123 patients following radical vaginal trachelectomy (Shepherd et al. 2006). However, the results of a multicenter study in China comparing vaginal and abdominal radical trachelectomy in 150 patients revealed that while the abdominal route fared better from an oncological perspective (0% vs. 9.8% recurrence), the vaginal route showed significantly higher conception rates (39.5% vs. 8.8%) (Cao et al. 2013). Our own series, as described above, carried a 30% fertility rate.

SUMMARY

Radical abdominal hysterectomy offers an oncologically sound procedure with a good chance of cure, but fertility is not preserved. It is the most commonly performed operation, with the best follow-up data. Radical vaginal trachelectomy, the current accepted fertility-preserving procedure in Europe, requires advanced vaginal and laparoscopic surgical skills. It has proven fertility following surgery, and so far, at least for tumors of <2 cm diameter, the long-term survival data look impressive.

Radical abdominal trachelectomy appears to be oncologically sound, and is perhaps more accessible, from a training perspective, than radical vaginal trachelectomy. It is fast becoming a

favored fertility-sparing procedure in the UK, Europe, and the US, with extremely promising oncological and fertility outcomes. Clinicians should consider trachelectomy, by abdominal or vaginal routes, in all patients wishing to preserve fertility with early-stage cervical cancer. For tumor size ≤2 cm, the vaginal approach or large cone biopsy and laparoscopic lymphadenectomy may be considered. For tumors >2 cm it is more appropriate to consider the abdominal route, performed open, laparoscopically, or robotically. Sentinel lymph node biopsy may have a role, but at present the evidence supporting its use in cervical cancer is variable. It is essential that patients are made aware of the recurrence and mortality rates along with fertility outcomes pre-operatively.

REFERENCES

Baltzer J. 1978. *Die operative Behandlung des Zervixcarcinoms. Klinische, histologische und tumormetrische Untersuchungsergebnisse einer kooperativen Studie an vier Universitätsfrauenkliniken bei 1092 Patien- tinnen mit Zervixcarcinom (dissertation)*. Munich: University of Munich.

Burghardt E. 1993. Cervical cancer. In: Burghardt E, Webb MJ, Monaghan JM, Kindermann G, eds. *Surgical Gynecologic Oncology*. New York: Thieme, p. 306.

Burghardt E, Girardi F, Lahousen M, et al. 1991. Microinvasive carcinoma of the uterine cervix. *Cancer* **67**:1037–45.

Cao DY, Yang JX, Wu XH, et al. 2013. Comparisons of vaginal and abdominal radical trachelectomy for early-stage cervical cancer: Preliminary results of a multi-center research in China. *Br J Cancer* **109**(11):2778–82.

Creasman WT, Fetter BF, Clarke-Paterson DL, et al. 1985. Management of stage 1A carcinoma of the cervix. *Am J Obstet Gynecol* **153**:164–72.

Creasman WT, Zaino RJ, Major FJ, et al. 1998. Early invasive carcinoma of the cervix (3–5 mm invasion): Risk factors and prognosis. *Am J Obstet Gynecol* **178**:62–5.

Dargent D, Martin X, Sacchetoni A, et al. 2000. Laparoscopic radical vaginal trachelectomy: A treatment to preserve the fertility of cervical carcinoma patients. *Cancer* **88**:1877–82.

Hagen B, Shepherd JH, Jacobs IJ. 2000. Parametrial resection for invasive cancer. *Int J Gynecol Cancer* **10**:1–6.

Hasumi K, Sakamoto A, Sugano H. 1980. Microinvasive carcinoma of the uterine cervix. *Cancer* **45**:928–31.

Kolstad P. 1989. Follow-up study of 232 patients with stage Ia1 and 411 patients with Ia2 squamous cell carcinoma of the cervix (microinvasive carcinoma). *Gynecol Oncol* **33**:265–72.

Li J, Li Z, Wang H, et al. 2011. Radical abdominal trachelectomy for cervical malignancies: Surgical, oncological and fertility outcomes in 62 patients. *Gynecol Oncol* **121**:565–70.

Lohe KJ, Burghardt E, Hillemans HG, et al. 1978. Early squamous cell carcinoma of the uterine cervix: Clinical results of a cooperative study in the management of 419 patients with early stromal invasion and microcarcinoma. *Gynecol Oncol* **6**:31–5.

Maiman MA, Fruchter RG, DiMaio TM, et al. 1988. Superficially invasive squamous cell carcinoma of the cervix. *Obstet Gynecol* **72**:399–403.

Palfalvi L, Ungar L, Boyle DCM, et al. 2003. Announcement of healthy baby boy born following abdominal radical trachelectomy. *Int J Gynecol Cancer* **13**:249.

Pareja R, Rendon GJ, Sanz-Lomana CM, et al. 2013. Surgical, oncological, and obstetrical outcomes after abdominal radical trachelectomy: A systematic literature review. *Gynecol Oncol* **131**:77–82.

Roche WD, Norris HJ. 1975. Microinvasive carcinoma of the cervix: The significance of lymphatic invasion and confluent patterns of stromal growth. *Cancer* **36**:180–6.

Saso S, Ghaem-Maghami S, Chatterjee J, et al. 2012. Abdominal radical trachelectomy in West London. *Br J Obstet Gynaecol* **119**:187–93.

Sedlis A, Sall S, Tsukada Y, et al. 1979. Microinvasive carcinoma of the uterine cervix: A clinical–pathologic study. *Am J Obstet Gynecol* **133**:64–74.

Shepherd JH, Spencer C, Herod J, Ind TE. 2006. Radical vaginal trachelectomy as a fertility-sparing procedure in women with early-stage cervical cancer-cumulative pregnancy rate in a series of 123 women. *BJOG* **113**(6):719–24.

Simon NL, Gore H, Shingleton HM, et al. 1986. Study of superficially invasive carcinoma of the cervix. *Obstet Gynecol* **68**:19–24.

Taki I, Sugimori M, Matsuyami T, et al. 1979. Treatment of microinvasive carcinoma. *Obstet Gynecol Surv* **34**:839–43.

Ungar L, Smith JR, Palfalvi L, Del Priore G. 2006. Abdominal radical trachelectomy during pregnancy to preserve pregnancy and fertility. *Obstet Gynecol* **108**:811–4.

van Nagell JR Jr, Greenwell N, Powell DF, et al. 1983. Microinvasive carcinoma of the cervix. *Am J Obstet Gynecol* **145**:981–91.

BIBLIOGRAPHY

Schauta R. 1908. *Die erweiterte vaginale Totalextirpation des Uterus beim Kollumkarzinom*. Vienna: Safar.

Smith JR, Boyle D, Corless D, et al. 1997. Abdominal radical trachelectomy: A new approach to the management of early cervical cancer. *Br J Obstet Gynaecol* **104**:1196–200.

Ungar L, Palfalvi L, Hogg R, et al. 2005. Abdominal radical trachelectomy: A fertility preserving option for women with early cervical cancer. *Br J Obstet Gynaecol* **112**:366–9.

13 Central recurrent cervical cancer: The role of exenterative surgery

John M. Monaghan

INTRODUCTION

The procedure of pelvic exenteration was first described in its present form by Brunschwig in 1948. Over the years, it has been used mainly in the treatment of advanced and recurrent carcinoma of the cervix (Barber 1969). Its primary role at the present time is the management of the numerous patients who develop recurrent cancer of the cervix following primary radiotherapeutic treatment (Disaia and Creasman 1981). It has also been used for treatment of uterine, ovarian, rectal, bladder and other cancers. It has been estimated that between one-third and one-half of patients with invasive carcinoma of the cervix will have residual or recurrent disease after treatment. Approximately one quarter of these cases will develop a central recurrence which may be amenable to exenterative surgery. However, pelvic exenteration as a therapy for recurrent cancer of the cervix has not been widely performed, and many patients will succumb to their disease having been through the process of radiotherapy followed by chemotherapy and other experimental treatments without being given the formal opportunity of a curative procedure. The published results of exenterative procedures show an acceptable primary mortality of approximately 3% to 4% and an overall survival/cure rate of 30% to 60% (Hockel and Dornhofer 2006). The procedure is also applicable to a wide range of other pelvic cancers including cancer of the vagina, vulva, and rectum, both for primary and secondary diseases. It is less often applicable to ovarian epithelial cancers and melanomas and sarcomas because of their tendency for widespread metastases.

The surgery involved is extensive, and postoperative care is complex; as a consequence, the operation has become part of the repertoire of the advanced gynecological oncologist working in a center with a wide experience of radical surgery. The procedure does demand of the surgeon considerable expertise and flexibility: virtually no two exenterations are identical, and considerable judgment and ingenuity are required during the procedure in order to achieve a comprehensive removal of all tumor. With small recurrences, more limited procedures may be carried out with a degree of conservation of structures in and around the pelvis. With extensive procedures, and particularly following extensive radiotherapy, complete clearance of all organs from the pelvis (total exenteration) together with widespread lymphadenectomy may be essential in order to achieve a cure. There is now considerable evidence that even in patients with node metastases at the time of exenteration a significant survival rate can be achieved.

Selection of the Patient for Exenterative Surgery

Exenterative surgery should be considered for both advanced primary pelvic carcinoma and recurrent disease. Many patients will be eliminated from the possibility of surgery at an early stage because of complete fixity of the tumor mass to the bony structures of the pelvis. The only exception to this rule is the rare circumstance in which a vulval or vaginal cancer is attached to one of the pubic rami: the ramus can be resected and a clear margin around the cancer obtained. Intra-operative radiation therapy, either teletherapy or brachytherapy, has increased exententeration candidates to include those with potential positive margins or fixed boney involvement. In general terms, exenterative surgery should not be used as a palliative, except perhaps in the presence of malignant fistulas in the pelvis when it may significantly improve the quality of the patient's life without any significant extension to her life. It is important that the surgical team, including nurses and ancillary workers, are confident in their ability to manage not only the extensive surgery involved but also the difficult testing, and sometimes bizarre complications that can sometimes occur after exenteration. The average age of patients who are subject to exenteration is 50 to 60 years, but the age range is wide—from early childhood through to the eighth or ninth decade.

PATIENT ASSESSMENT

It is frequently difficult following radiotherapeutic treatment to be certain that the mass palpable in the pelvis is due to recurrent disease and not to radiation reaction or persistent scarring associated with infection or the effects of adhesion of bowel to the irradiated areas.

In recent years both computed tomography (CT) and magnetic resonance imaging (MRI) have been used extensively in the preoperative assessment of patients for many oncological procedures. The considerable difficulties of assessing CT scans in patients who have had preceding surgery or radiotherapy are a particular problem in patients being assessed for exenteration. Some clinicians feel that CT scanning is useful (Crawford et al. 1996), whereas the author has not found the level of reliability to be acceptable. There will be many individual variations from center to center, depending upon the skills available to the clinician. A tissue diagnosis is essential prior to embarking on exenterative surgery, and needle biopsy, aspiration cytology, or even open biopsy at laparotomy will be required. As distant metastases tend to occur with recurrent and residual disease, it is sometimes helpful to perform scalene node biopsies and radiological assessments of the pelvic and para-aortic lymph nodes together with fine-needle aspiration in order to assist with the assessment. PET scans are used in some centers. The mental state of the patient is also important, but should not in itself be a bar to the performance of such surgery.

Absolute Contraindications

If there are metastases in extra-pelvic lymph nodes, abdominal viscera, lungs, or bones there appears to be little value in performing such major surgery (Stanhope and Symmonds 1985). However, there is evidence that patients with pelvic lymph node metastases may well survive, and a good quality of life is reported in a small but significant percentage of such patients.

Local resection of pelvic sidewall vasculature together with the lymphatic ray has been shown to achieve salvage in selected patients (Austin and Solomon 2009).

Relative Contraindications

- Pelvic sidewall spread: if the tumor has extended to the pelvic sidewall either in the form of direct extension or nodal metastases, the prospects of a cure are extremely small and the surgeon must decide whether the procedure will materially improve the patient's quality of life. The triad of unilateral uropathy, renal nonfunction, or ureteric obstruction together with unilateral leg edema and sciatic leg pain is an ominous sign. The prospects of a cure are poor; readers are, however, referred to Chapter 14 for possible combination therapies. Perineural lymphatic spread is not visible on CT and can be a major source of pain and eventual death.
- Obesity has always been a problem with all surgical procedures, producing many technical difficulties as well as postoperative respiratory and mobilization problems. In the present day, obesity is almost endemic in some societies, markedly increasing the complexity of surgery and recovery. The more massive the surgery, the greater are these problems.

Type of Exenteration

In North America, the majority of exenterations performed are total; in the author's series approximately half of his exenterations have been of the anterior type, removing the bladder, uterus, cervix and vagina, but preserving the rectum (Figure 13.1). For very small, high lesions around the cervix and lower uterus and bladder, it may be possible to carry out a more limited procedure (a supralevator exenteration) retaining considerable parts of the pelvic floor. Posterior exenteration (abdominal perineal procedure) is less often performed by gynecological oncologists.

Preoperative Preparation

Probably the most important part of the preoperative preparation is the extensive counseling needed to make certain that the patient and her relatives, particularly her partner, understand fully the extent of the surgery and the marked effect it will have upon normal lifestyle, in particular the loss of normal sexual function when the vagina has been taken out. The transference of urinary and bowel function to the chosen type of diversionary procedure should be discussed, as should the possibility of reconstructive surgery of the vagina and bladder, and the significant risks of such extensive surgery must be honestly explained. During the course of this counseling the patient should be seen by a stoma therapist. The author finds it ideal for the patient to meet others who have had the procedure, to discuss on a woman-to-woman basis the real problems and feelings about exenteration.

The patient is occasionally admitted to hospital prior to the planned procedure. Bowel preparation and prolonged antibiotics have been demonstrated to be potentially harmful based on randomized clinical trials. Never the less, surgeons continue to utilize modified versions of both in select cases. The anesthesiologist responsible for the patient's care will see the patient and explain the process of anesthesia. The author prefers to carry out all radical surgery under a combination of epidural or spinal analgesia together with general anesthesia. Cardiac and blood gas monitoring is essential. Although the majority of patients do not require intensive care therapy, its availability must be ensured prior to the surgical procedure. Prophylaxis against deep venous thrombosis is usually organized by the ward team, utilizing a combination of modern elastic stockings and low-dose heparin, which is initiated immediately following surgery.

The Final Intraoperative Assessment

The final decision to proceed with exenteration will not be made until the abdomen has been opened and assessment of the pelvic sidewall and posterior abdominal wall has been made, utilizing frozen sections where necessary. As laparoscopic surgery has extended its application, it has become inevitable that

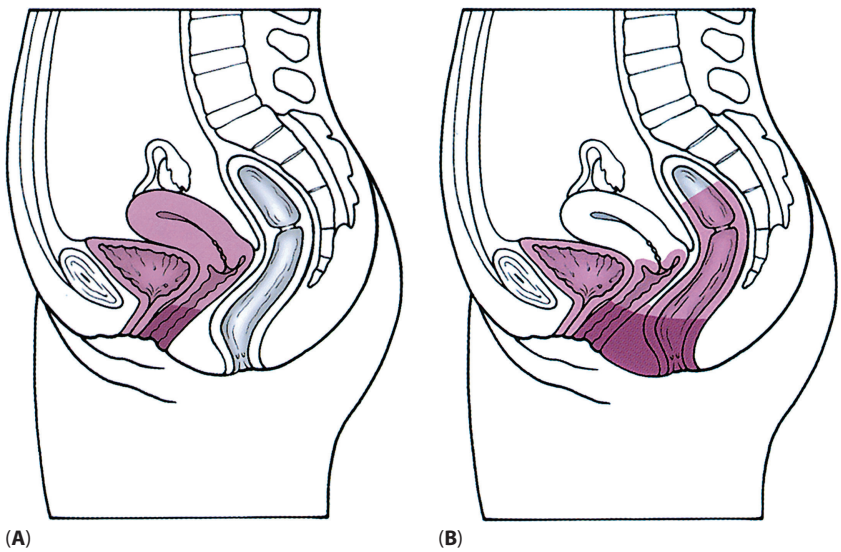

Figure 13.1 The limits of resection for (**A**) anterior and (**B**) total exenteration.

its use has extended to exenterative surgery. The value of laparoscopic techniques in the early assessment of the extent of disease is clear. However, its use for the totality of exenterative surgery is limited by the need to develop neovaginas and bladders (Schneider et al. 2009). Similarly, robotic surgery may have a place in some aspects of radical gynecological surgery (Magrina and Zanagnolo 2008). In the author's practice the procedure is performed by a single team. If plastic surgical procedures such as the formation of a neovagina are planned, then a second plastic surgical team will carry out the necessary operation at the same time as the diversionary procedures are being performed by the primary team, unless intra-operative RT or salvage post-operative advanced image guided RT may be possible.

OPERATIVE PROCEDURE

Once the patient has been anesthetized and placed in the supine position in the operating theater, the abdomen is opened using either a longitudinal midline incision extending above the umbilicus, or a high transverse (Maylard) incision (Figure 13.2), cutting through muscles at the interspinous level. Exploration of the abdomen will confirm the mobility of the central tumor mass; thereafter the para-aortic lymph nodes and pelvic side-wall nodes are dissected (Figure 13.3) and sent for frozen section examination. Once the frozen sections show no extension of tumor, the procedure of total exenteration can begin. At the same time as this initial intraoperative assessment, the experienced exenterative surgeon will have opened tissue planes, including the paravesical, pararectal, and presacral spaces, to a deep level (Figures 13.4 and 13.5) in the pelvis in order to become familiar with the full extent of the tumor. The dissection is achieved by opening the broad ligament: this can be done directly, or the round ligament can be ligated and divided first. These dissections can be carried out without any significant blood loss and will yield considerable

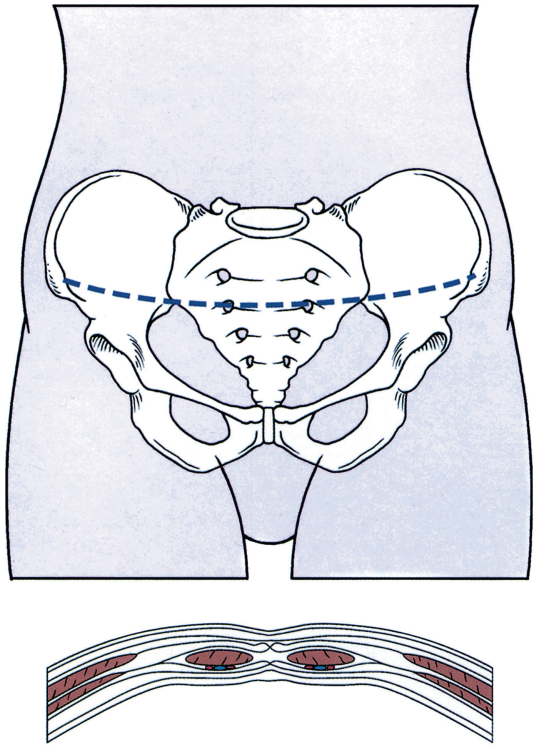

Figure 13.2 A Maylard or high transverse incision.

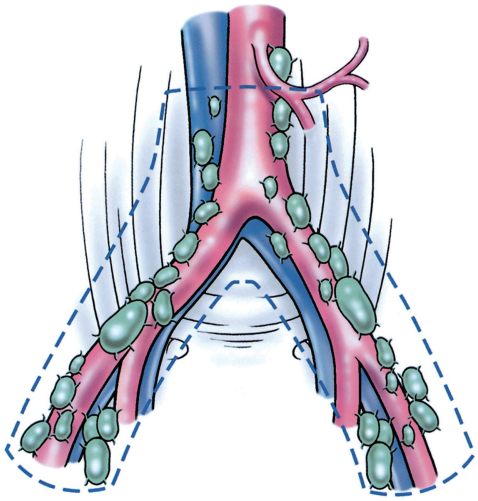

Figure 13.3 Pelvic and para-aortic node assessment.

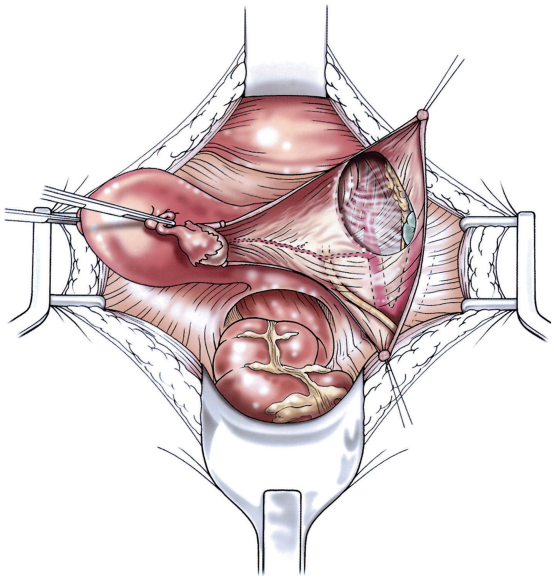

Figure 13.4 Division of the round and infundibulopelvic ligaments and the beginning of the lateral pelvic dissection.

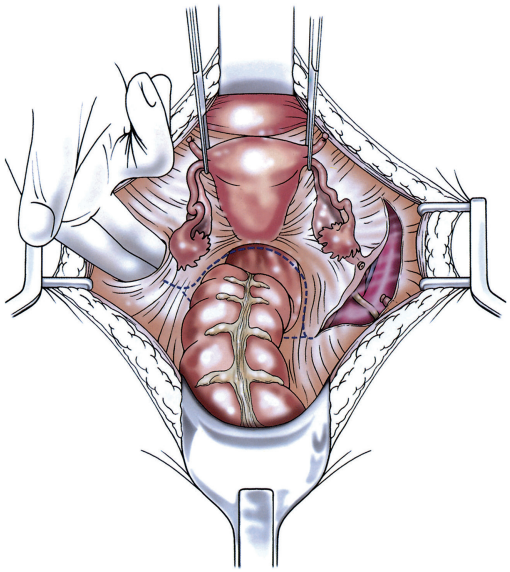

Figure 13.5 Deepening the lateral pelvic dissection to reveal the pelvic spaces.

information. If it is not possible to proceed with the operation, the abdomen may be closed at this stage, as no significant trauma has been inflicted by the surgeon. Considerable experience and judgment are required in order to make this decision. Often the most difficult decision is to stop operating. Very occasionally, for example with some vulval cancers, resection of pubic bones may be attempted, but in general terms if there is bony involvement of tumor the procedure should be abandoned.

Total and Anterior Exenteration

After the comprehensive manual and visual assessment of the pelvis and the abdominal cavity, the surgeon proceeds by dividing the round ligament (if it is not already divided), drawing back the infundibulopelvic ligament and opening up the pelvic sidewall (Figure 13.6). The line of incision for removal of the entire pelvic organs begins at the pelvic sidewall, over the internal iliac artery, and will pass forward through the peritoneum of the upper part of the bladder, meeting with the similar lateral pelvic sidewall incision at the opposite side. The sigmoid colon will be elevated and at a suitable point will be transected; the peritoneal incision will be continued around the brim of the pelvis—with identification of the ureter as it passes over the common iliac artery—and will meet up with the similar incision on the opposite side. After the round ligaments have been divided and tied and the pelvic sidewall space opened, the infundibulopelvic ligament can also be identified, divided, and tied. The incision is continued posteriorly and the ureters are separated and identified. If an anterior exenteration is to be performed, the peritoneal dissection will be brought down into the pelvis to run across the anterior part of the rectum, just above the pouch of Douglas; this will allow a dissection from the anterior part of the rectum passing posteriorly around the uterosacral ligaments to the sacrum, releasing the entire anterior contents of the pelvis. For a total exenteration the dissection is even simpler: the mesentery of the sigmoid colon is opened and individual vessels clamped, divided, and tied. The colon is divided, usually with a stapling device which allows the

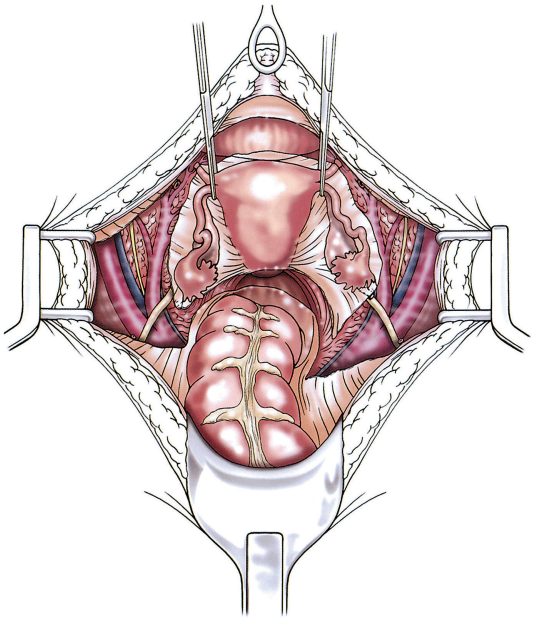

Figure 13.6 The pelvic incision for an anterior exenteration.

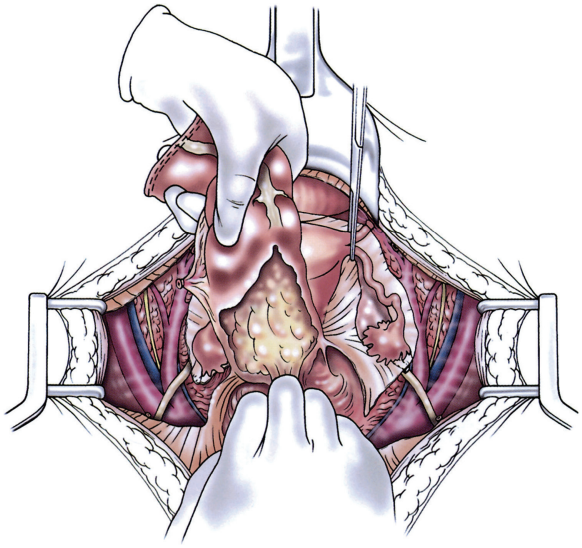

Figure 13.7 The pelvic incision for a total exenteration.

sealed ends of the colon to lie, without interfering with the operation in the upper abdomen (Figure 13.7). A dissection posterior to the rectum is then carried out from the sacral promontory, deep behind the pelvis; this dissection is rapid and simple and permits complete separation of the rectum from the sacrum. This allows complete and usually bloodless removal of the rectal mesentery including lymph nodes. Anteriorly, the bladder is dissected with blunt dissection from the cave of Retzius, resulting in the entire bladder with its peritoneal covering falling posteriorly. This dissection is carried down to the pelvic floor, isolating the urethra as it passes through the pelvic floor (perineal diaphragm). As dissection is carried posteriorly into the paravesical spaces, the uterine artery and the terminal part of the internal iliac artery will become clearly visible. By steadily deepening this dissection, the anterior division of the internal iliac will be isolated and the tissues of the lower obturator fossa identified; at this point, large exenteration clamps may be placed over the anterior division of the internal iliac artery and its veins (Figure 13.8). The ureter by this time will have been divided a short distance beyond the pelvic brim. The pelvic phase of the procedure is at this point completed and the perineal phase is now to be carried out.

The patient is placed in the extended lithotomy position and an incision made to remove the lower vagina (for an anterior exenteration) or the lower vagina and rectum (for a total exenteration) (Figure 13.9). Anteriorly the incision is carried through above the urethra just below the pubic arch to enter the space of the cave of Retzius which has been dissected in the pelvic procedure. The dissection is carried laterally and posteriorly, dividing the pelvic floor musculature, and the entire block of tissue is then removed through the inferior pelvic opening. Small amounts of bleeding will occur at this point, usually arising from the edge of the pelvic floor musculature. These can be picked up by either isolated or running sutures which will act as a hemostat.

Once the perineal dissection has been completed and hemostasis achieved, the surgeon's choice will depend on the preoperative arrangements made with the patient. If in the preoperative assessment period it was decided by the clinician and the patient that a neovagina should be formed, then at this point either the primary surgeon or the plastic surgeon will initiate the development

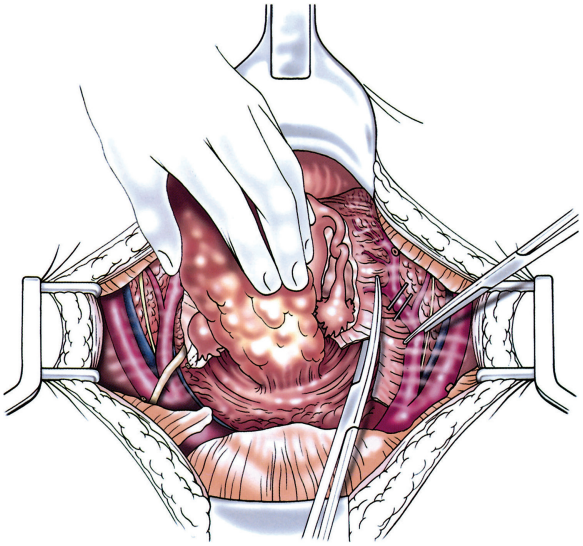

Figure 13.8 Exenteration clamps applied to the anterior division of the internal iliac arteries.

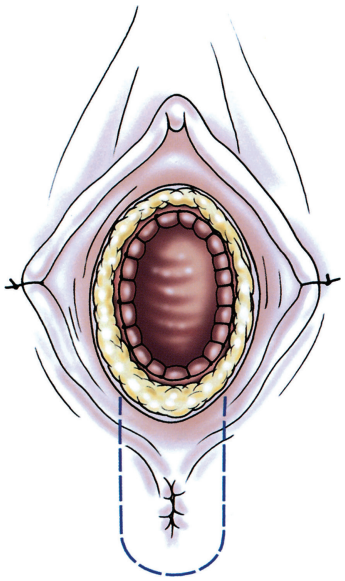

Figure 13.9 The perineal incisions for anterior and total exenterations.

of a neovagina. This may be in the form of a myocutaneous graft using the gracilis muscle (see Chapter 32), or a Singapore graft may be used from alongside the vulva; other possible techniques involve the development of a skin graft placed within an omental pad, or transposition of a segment of sigmoid colon in order to form a sigmoid neovagina. For many patients, however, the desire to have a new vagina is a very low priority, and it is surprising how frequently patients will put off these decisions until well after the time of exenteration. Surviving the cancer appears to be their uppermost desire. To this end, the careful closure of the posterior parts of the pelvic musculature, a drawing together of the fat (Figure 13.10) anterior to that, and a careful closure of the skin is all that is required. Biologic or synthetic meshes may simplify the closure of large defects and considerably shorten operative times (Schiltz et al. 2017). It is usually possible to preserve the clitoris, the clitoral fold, and significant proportions of the

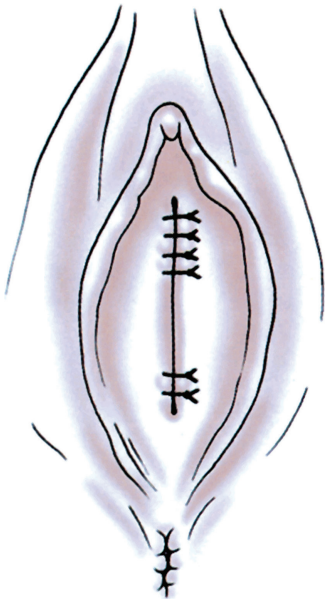

Figure 13.10 Closure of the pelvic floor musculature.

anterior parts of the labia minora and labia majora so that when recovery is finally made the anterior part of the genitalia has a completely normal appearance. On some occasions patients will be able to have a neovagina formed some significant period of time following the exenteration. This is becoming the predominant pattern in the author's experience of some 89 cases.

Once the perineal phase is finished, the legs can be lowered so that the patient is once more lying supine and attention can be addressed to dealing with the pedicles deep in the pelvis. All that remains following a total exenteration will be the two exenteration clamps on either side of the pelvis and a completely clean and clear pelvis. The pelvic sidewall dissection of lymph nodes can be completed before dealing with the clamps, and any tiny blood vessels that require hemostasis are ligated. As the exenteration clamps are attached to the distal part of the internal iliac arteries it is important that comprehensive suture fixation is carried out (Figure 13.11). This is usually readily and easily done, although occasionally the large veins of the pelvic wall can provide

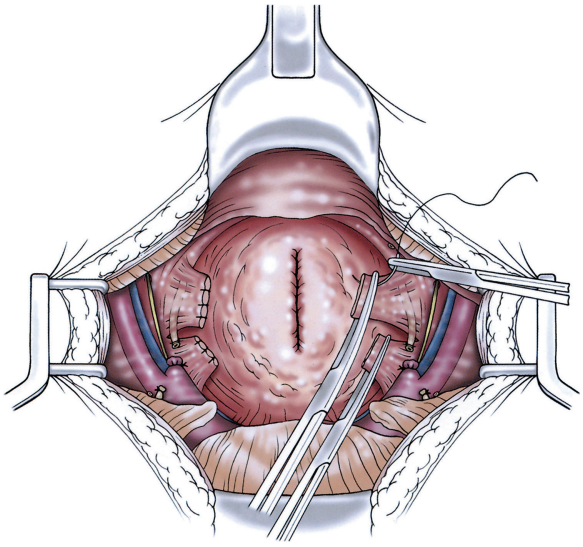

Figure 13.11 Suture of the internal iliac arteries and lateral pelvic pedicle.

difficulties, and the use of mattress sutures may be necessary in order to deal with these complex vascular patterns. Having completed the dissection of the pelvis, the clinician now moves to produce either a continent urinary conduit or a Wallace or Bricker ileal conduit, and if the procedure has been a total exenteration a left iliac fossa stoma will be formed (see Chapters 28 and 29).

Dealing with the Empty Pelvis

A problem which must be avoided is that of small bowel adhesion to the tissues of a denuded pelvis. This is particularly important when patients have previously had radiotherapy, as the risk of fistula formation in these circumstances is extremely high. A variety of techniques have been utilized to deal with this potentially life-threatening complication, including the placing in the pelvis of artificial materials such as Merselene (Ethicon, Edinburgh, UK), Dacron (DuPont) and Gortex sacs (WL Gore & Associates, Flagstaff, Arizona, USA), or other biologic meshes.

The author's predecessor Stanley Way used a "sac technique," bringing together precut flaps of peritoneum to cover the denuded pelvis (Way 1974). This sac technique, in which he manufactured a bag of peritoneum, allowed the entire abdominal contents to be kept above the pelvis. This resulted in an empty pelvis, which from time to time became infected and generated a new problem, that of the empty pelvis syndrome. Intermittently over the years patching with the peritoneum has been used. From time to time procedures such as bringing gracilis muscle flaps into the empty pelvis have been carried out to deal with the difficulty of a devitalized epithelium due to previous radiation.

The mobilization of the omentum from its attachment to the transverse colon leaves a significant blood supply from the left side of the transverse colon, allowing the formation of a complete covering of the pelvis by a soft "trampoline" of omentum which will then stretch, completely covering and bringing a new blood supply into the pelvis.

The technique involves separating the omentum from the transverse colon using a powered autosuture; this allows a broad pedicle to remain at the left-hand end of the transverse colon, maintaining an excellent blood supply to the omentum. This is brought down to the right side of the large bowel, dropping into the pelvis immediately to the left side of the ileal conduit which is anchored just above the sacral promontory. By careful individual suturing around the edge of the pelvis and sometimes by refolding the omentum upon itself, a complete covering of the true pelvis with a soft central "trampoline" area can be generated (Figure 13.12). A suction drain is inserted below the omentum, which when activated will draw the omentum down into soft contact with the pelvic floor. The small bowel can thus come into contact with an area with a good blood supply, obviating the risk of adherence and subsequent fistula formation. At the end of the procedure the bowel is carefully oriented to make sure that no hernia can develop, and the abdomen is closed with a mass closure. The stomas are dressed in theater and their appliances put in place. The patient leaves the operating theater into recovery or intensive care and is then transferred back to the ward at the appropriate time.

POSTOPERATIVE CARE

The postoperative care of exenterations is straightforward, essentially being a matter of maintaining good fluid balance, good hemoglobin levels, and ideally a significant flow of urine. Bowel function often returns at the usual time of 2 to 4 days following the procedure, and a nasogastric tube (the author's preference) can be removed after 3 to 4 days; the return to oral intake, beginning with simple fluid, is initiated as soon as possible. Preoperative supplemental feeding and other measures consistent with evidence guided rapid recovery after surgery may reduce ileus and shorten post-operative complications. For instance, many surgeons do not use nasogastric tubes at all or remove them intra-operatively. During and following the procedure, prophylactic antibiotic cover may be maintained, as is subcutaneous heparin cover as prophylaxis against deep venous thrombosis. Mobilization should be rapid. Patients are usually discharged

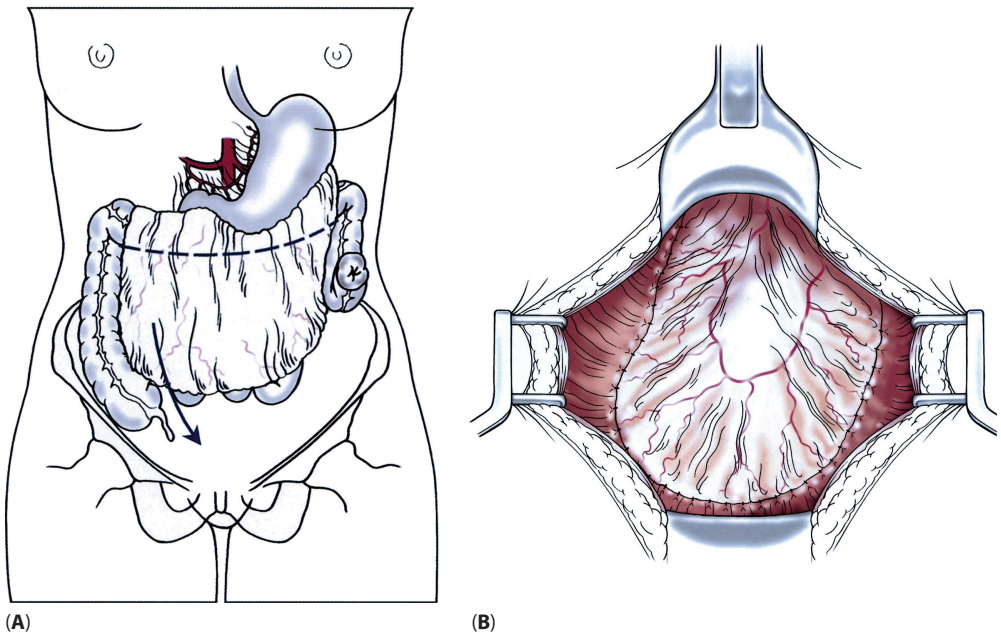

Figure 13.12 Development of the "omental pelvic floor": (**A**) omental incision, (**B**) soft "trampoline" area.

10 to 15 days postoperatively, once they are used to dealing with the stomas and the ileal conduit tubes have been removed.

RESULTS OF EXENTERATION

Most series show that the 5-year survival rate following exenteration is of the order of 40% to 60%; these figures depend very largely upon the selection of patients (Goldberg et al. 2006, Robertson et al. 1994). A figure that is rather more difficult to obtain is the exact number of patients who are assessed for exenteration but fail at one of the many hurdles the patient must face before finally undergoing the procedure. It is therefore likely that the final, truly salvageable figure is an extremely low percentage. The value of exenteration procedures in patients who have lymph node involvement has been shown to be low but significant, and it is now many clinicians' practice to carry on with an exenterative procedure even in circumstances where one or two pelvic lymph nodes are involved by tumor.

REFERENCES

Austin KK, Solomon MJ. 2009. Pelvic exenteration with en bloc iliac vessel resection for lateral pelvic wall involvement. *Dis Colon Rectum* **52**(7):1223–33.

Barber HRK. 1969. Relative prognostic significance of preoperative and operative findings in pelvic exenteration. *Surg Clin North Am* **49**(2):431–7.

Brunschwig A. 1948. Complete excision of the pelvic viscera for advanced carcinoma. *Cancer* **1**:177.

Crawford RAF, Richards PJ, Reznek RH, et al. 1996. The role of CT in predicting the surgical feasibility of exenteration in carcinoma of the cervix. *Int J Gynecol Cancer* **6**:231–4.

Disaia PJ, Creasman WT. 1981. *Clinical Gynaecologic Oncology; Cancer of the Cervix, Pelvic Exenteration*. Chapters 2–8. New York: Mosby, pp. 82–8.

Goldberg GL, Sukumvanich P, Einstein MH, et al. 2006. Total pelvic exenteration: The Albert Einstein College of Medicine/Montefiore Medical Center Experience (1987 to 2003). *Gynecol Oncol* **101**(2):261–8.

Hockel M, Dornhofer N. 2006. Pelvic exenteration for gynecologic tumours; achievements and unanswered questions. *Lancet Oncol* **7**(10):837–47.

Magrina JF, Zanagnolo VL. 2008. Robotic surgery for cervical cancer. *Yonsei Med J* **49**(6):879–85.

Robertson G, Lopes A, Beynon G, et al. 1994. Pelvic exenteration: A review of the Gateshead experience 1974–1992. *Br J Obstet Gynaecol* **96**:1395–9.

Schiltz B, Buchs NC, Penna M, et al. (2017). Biological mesh reconstruction of the pelvic floor following abdominoperineal excision for cancer: A review. *World Journal of Clinical Oncology*. 8(3):249–254. doi:10.5306/wjco.v8.i3.249.

Schneider A, Kohler C, Erdemoglu E. 2009. Current developments for pelvic exenteration in gynecologic oncology. *Curr Opin Obstet Gynecol* **21**(1):4–9.

Stanhope CR, Symmonds RE. 1985. Palliative exenteration—What, when and why? *Am J Obstet Gynecol* **152**:12–16.

Way S. 1974. The use of the sac technique in pelvic exenteration. *Gynecol Oncol* **2**:476–81.

14 Total mesometrial resection

Michael Höckel

INTRODUCTION

About 40% of cervical cancer patients are diagnosed with early macroscopic disease, i.e., FIGO stages IB to IIA, being candidates for surgical treatment with radical hysterectomy, an operation which is conceptually over 100 years old (Quinn et al. 2006, Wertheim 1912). Although various modifications have been applied since the introduction of abdominal radical hysterectomy by Wertheim in the early twentieth century—such as the vaginal approach, systematic pelvic and para-aortic lymph node dissection, extension of the paracervical dissection by including the "vesicouterine ligament," tailoring the radicality of the pericervical dissection, autonomic nerve sparing, fertility preserving, minimally invasive techniques, and recently robotic assistance—the principles on which these operations are based have remained essentially unchanged (Zakashansky et al. 2008). These are (a) surgical anatomy deduced with regard to tissue function, and (b) a model of local tumor spread assuming isotropic intra- and transcervical permeation with microscopic and occult disease preceding the macroscopic tumor front. Consequently, for radical treatment the tumor is resected with a ubiquitous metrically defined margin of intra- and paracervical tumor-free tissue (Piver et al. 1974, Querleu and Morrow 2008). Close margins are regarded an indication for adjuvant radiation (Viswanathan et al. 2006). Moreover, it is anticipated that surgical treatment is not sufficient to control discontinuous local and metastatic pelvic disease (Peters et al. 2000, Sedlis et al. 1999).

To overcome major inconsistencies of the traditional concept on cancer spread and weaknesses of the current surgical treatment principles (Höckel and Dornhöfer 2009, Höckel and Horn, 2013) we have proposed the cancer field theory (Höckel et al. 2005, 2009, 2014, Höckel 2015). Cancer is considered as a clinical manifestation of retrograde dysontogenesis through pathologic reactivation and maintenance of developmental programs in the tumor cells within the context of the mature and immunocompetent organism. Clinical translation of these insights into ontogenetic tumor staging, cancer field resection, and therapeutic lymph node dissection holds great potential to improve prognostic assessment and curative treatment.

The cancer field theory sets up the new principles of radicality for surgical tumor treatment, namely the resection of the tumor-bearing compartment with intact borders and of the basin lymph nodes as well as the intercalated lymph nodes for which the cancer field is tributary. If the first-line lymph nodes, which are the nodes that are directly connected to the cancer field by afferent lymphatics, contain metastases, downstream second-line nodes have to be resected as well; otherwise the resection of the first-line nodes alone is therapeutic.

Tissues outside the cancer field can safely be retained despite their close proximity to the tumor front. Cancer field resection and therapeutic lymph node dissection should result on the one hand in maximum locoregional tumor control without adjuvant radiation, and on the other hand in minimal treatment-related morbidity. Only at the site of intracompartmental resection, which may be indicated to preserve functional aspects, a metrically defined tumor-free resection margin has to be achieved. *Total mesometrial resection* (*TMMR*) is the translation of this principle for the surgical treatment of early cervical cancer.

ONTOGENETIC SURGICAL ANATOMY

We have identified the Müllerian compartment in the adult female by following the differentiation and maturation of the paramesonephric–mesonephric complex connected to the urogenital sinus (Höckel et al. 2005). The complex topography of the Müllerian compartment is highlighted in Figure 14.1.

The cranial part of the compartment is located intraperitoneally, consisting of the Fallopian tubes, parasalpinx, uterine corpus, and paracorpus. The retro- and subperitoneal caudal part is represented by the cervix, the vagina (except its distal part), and the proximal part of enveloping mesotissue, designated as mesometrium. The mesometrium tapers off with bilateral wings made up of dorsolaterally directed supply tissue with the uterine and vaginal arteries and veins, lymphatic drainage, and a few lymph nodes (termed "vascular mesometrium"), and dorsally directed suspensory and fatty tissue fused to the anterior and lateral mesorectum that occasionally contains small lymph nodes as well (termed "ligamentous mesometrium"). The vascular mesometrium is adherent to the bladder and its mesenteries anterolaterally and is traversed by the ureters with their mesureters. The ligamentous mesometrium is a semicylindrical tissue sheet attached to the mesorectum following the pelvic curvature sagittally. It corresponds to parts of the posterior broad ligaments, uterosacral ligaments, the rectouterine and rectovaginal ligaments, and the rectovaginal septum. Laterally, both the plexus hypogastricus inferior and the mesureter adhere to the ligamentous mesometrium. Dorsally and inferiorly it is continuous with the mesorectum. The iliac lymph basins contain the external iliac, paravisceral, common iliac, presacral, and aortic bifurcation subregions. The lumbar lymph basins contain the para- and retro-aortic and para- and retrocaval subregions. The mesenteric lymph basin contains the para- and pre-aortic and para- and precaval subregions. Intercalated (secondary) lymph nodes are present in the gonadal mesentery corresponding to the infundibulopelvic ligament, the upper (corporal) vascular mesometrium above the level of the umbilical artery corresponding to the broad ligament, the lower (cervical) vascular mesometrium below the level of the umbilical artery, and the ligamentous mesometrium. First-line lymph nodes of cervical cancer confined to the Müllerian compartment involve the external iliac, paravisceral, and mesometrial subregions.

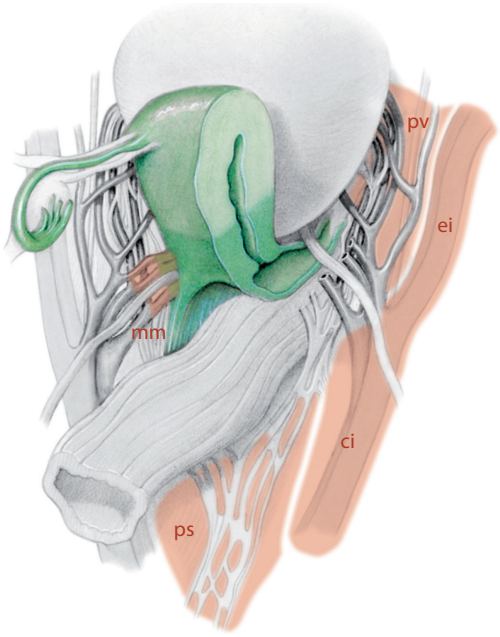

Figure 14.1 Schematic representation of the Müllerian compartment (*green*) and the draining pelvic lymph node basins (*red*) deduced from ontogenetic surgical anatomy. To display the topographic relations the right half of the compartment and the complete pelvic peritoneal covering are omitted and the visceral branches of the internal iliac vessel system have been spread. *Abbreviations*: pv, paravisceral; ei, external iliac; ci, common iliac; ps, presacral; mm, mesometrial. (From Höckel M, Horn LC, Manthey N, et al. 2009. *Lancet Oncol* **10**:683–92. Figure 1, with permission.)

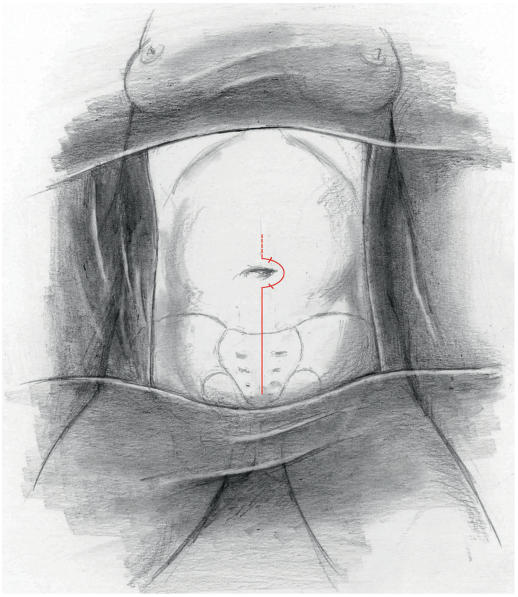

Figure 14.2 Laparotomy. (Courtesy of E.W. Hanns; from Höckel M, Horn LC, Manthey N, et al. 2009. *Lancet Oncol* **10**:683–92. Webappendix Figure 1, with permission.)

SURGICAL PROCEDURE

Indications

Carcinoma of the uterine cervix, FIGO stages IB and IIA; FIGO stage IIB if confined to the Müllerian compartment.

Contraindications

Medical conditions compromising operability.

Treatment Goals

- Local tumor control through extirpation of the Müllerian compartment with a wide tumor-free vaginal margin
- Regional tumor control through clearance of embryologically deduced lymp h node basins and inclusion of the complete vascular and ligamentous mesometria in the specimen of local resection
- Eventually ascending para-aortic lymph node dissection or M(LYM)* control

Technique

TMMR is performed in defined steps as previously published (Höckel et al. 2005, 2009), illustrated with Figures 14.2–14.19.

Step 1 (Figure 14.2)

Hypogastric midline laparotomy is carried out with left circumcision of the umbilicus. In obese patients and for para-aortic lymph node dissection, epigastric advancement of the incision may be necessary.

Step 2 (Figure 14.3)

Peritoneal incisions above the psoas muscles, in the para-aortic gutters, and along the radix mesenterii are made to gain access to the pelvic and mid-abdominal retroperitoneum. Connatal peritoneal adhesions are lysed marking the site of colon sigmoid

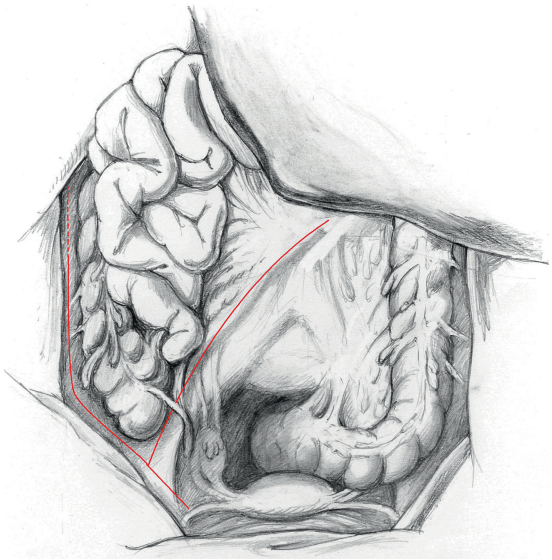

Figure 14.3 Peritoneal incisions. (Courtesy of E.W. Hanns; from Höckel M, Horn LC, Manthey N, et al. 2009. *Lancet Oncol* **10**:683–92. Webappendix Figure 2, with permission.)

* M(LYM) is the international pathological classification term for distant lymph node metastases.

fixation. Cecum, duodenum, and sigmoid colon are mobilized cranialward. Mesosigma is undermined.

Step 3 (Figure 14.4)

At the pelvic brim the infundibulopelvic ligaments and ureters are exposed. The superior hypogastric plexus is identified between the mesosigma and the bifurcation of the aorta. Mesosalpinx is separated from mesovar. Ligamentum rotundum, ligamentum latum, and ligamentum ovarii propium are severed. Ovary attached to infundibulopelvic ligament is mobilized cranialward.

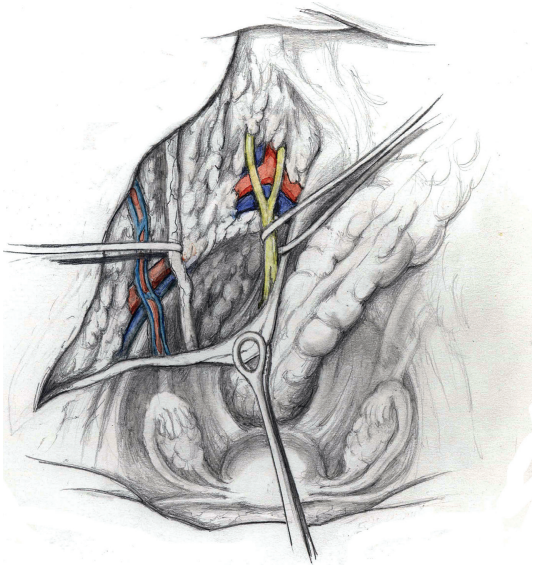

Figure 14.4 Exposition of the superior hypogastric plexus. (Courtesy of E.W. Hanns; from Höckel M, Horn LC, Manthey N, et al. 2009. *Lancet Oncol* **10**:683–92. Webappendix Figure 3, with permission.)

Step 4 (Figure 14.5)

The pelvic ureter with complete mesureter is mobilized medially from perirectal peritoneum, ligamentous mesometrium, and plexus hypogastricus inferior and laterally from iliac vessels and lymphoid tissue. Caudally the ureter is exposed up to the crossing vascular mesometrium.

Step 5 (Figure 14.6)

Fatty tissue is dissected to expose the retroinguinal lacuna vasorum and the obliterated umbilical artery, which should be visible from its origin at the arteria iliaca interna up to the formation of the medial umbilical peritoneal fold. The complete paravisceral space is developed by separation of the urogenital mesentery from the parietal paravisceral fat pad down to the levator ani muscle. The external iliac lymphoid tissue is harvested by adventitia stripping, taking care to preserve the genitofemoral nerves. Next, the complete paravisceral fat pad is removed. The obturator nerve and the proximal sciatic nerve along with its lumbar and first sacral trunci are exposed by sealing and dissecting parietal branches of the internal iliac venous system. The obturator muscle, levator ani muscle, and its arci tendinei and the endopelvic aspect of the sciatic spine are exposed.

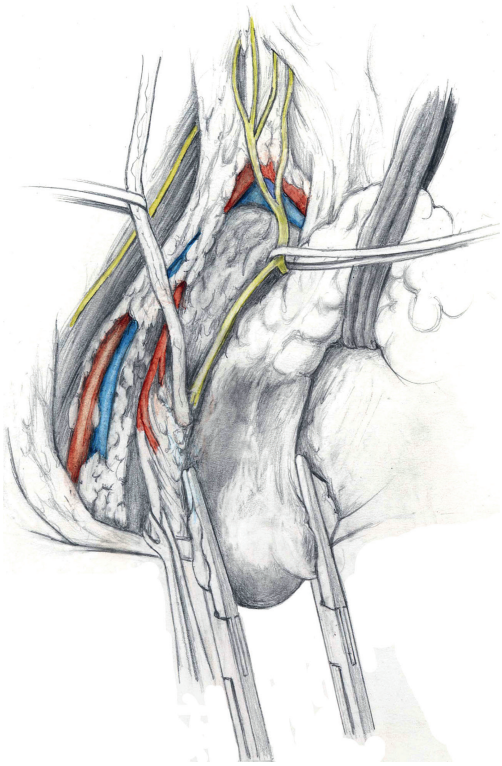

Figure 14.5 Mesureteral mobilization I°. The mesureter is not shown in this drawing. (Courtesy of E.W. Hanns; from Höckel, et al. 2009, Webappendix Figure 4, with permission.)

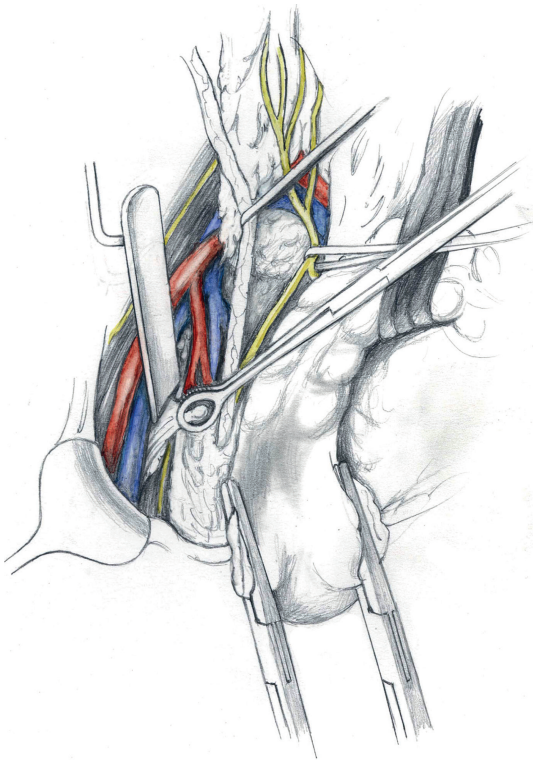

Figure 14.6 Therapeutic pelvic lymph node dissection, part I. The mesureter is not shown in this drawing. (Courtesy of E.W. Hanns; from Höckel M, Horn LC, Manthey N, et al. 2009. *Lancet Oncol* **10**:683–92. Webappendix Figure 5, with permission.)

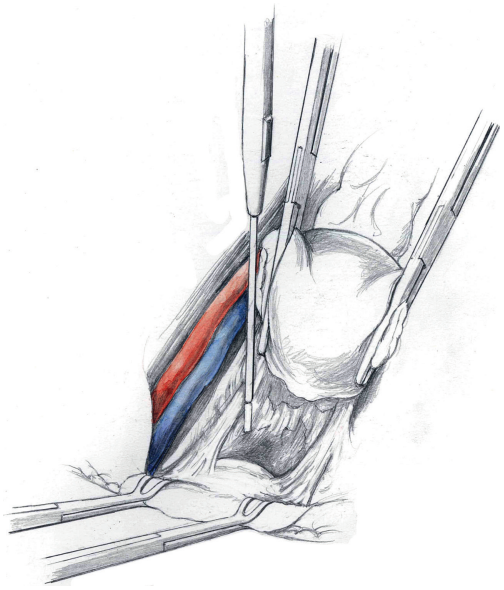

Figure 14.7 Separation of the Müllerian compartment from the bladder compartment. (Courtesy of E.W. Hanns; from Höckel M, Horn LC, Manthey N, et al. 2009. *Lancet Oncol* **10**:683–92. Webappendix Figure 6, with permission.)

Steps 3 through 6 are carried out at the contralateral side as well.

Step 6 (Figure 14.7)

The vesicouterine peritoneal fold is incised and the bladder is separated from the anterior cervix and proximal vagina. The medial ureterovesical junctions are exposed.

Step 7 (Figure 14.8)

The vascular mesometrium containing the uterine artery and superficial veins, lymphatics, and a few small lymph nodes is completely separated from the superior bladder mesentery and from the mesureter posteriorly.

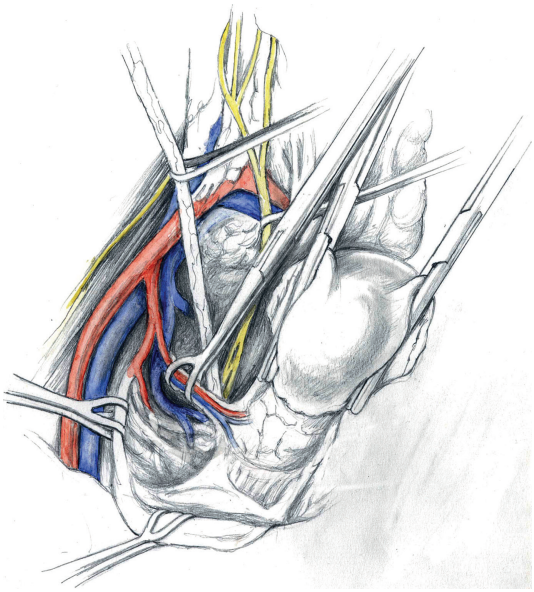

Figure 14.8 Separation of the vascular mesometrium from the "superior bladder mesentery and the mesureter." The mesureter is not shown in this drawing. (Courtesy of E.W. Hanns; from Höckel M, Horn LC, Manthey N, et al. 2009. *Lancet Oncol* **10**:683–92. Webappendix Figure 7, with permission.)

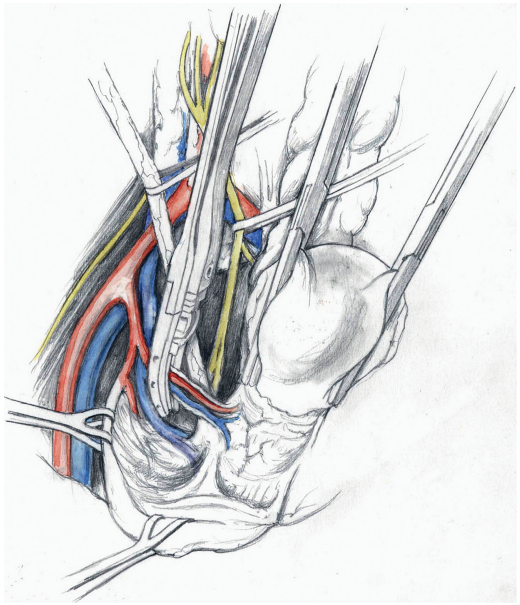

Figure 14.9 Sealing of the vascular mesometrium at the branching site of the uterine vessels from the internal iliac vessels. The mesureter is not shown in this drawing. (Courtesy of E.W. Hanns; from Höckel M, Horn LC, Manthey N, et al. 2009. *Lancet Oncol* **10**:683–92. Webappendix Figure 8, with permission.)

Step 8 (Figure 14.9)

The vascular mesometrium is sealed and dissected at the level where the uterine vessels branch from the hypogastric vessels and flipped medially over the ureter with intact mesureter.

Step 9 (Figure 14.10)

The vesicouterine vessel connections above and below the ureter are sealed and severed, taking care not to violate the mesureter containing the feeding vessels from the superior and inferior vesical artery. The inferior hypogastric plexus is separated from the ligamentous mesometrium and its uterine branches are dissected.

Perform steps 7 through 9 on the contralateral side as well.

Step 10 (Figure 14.11)

Tension is exerted on the pouch of Douglas and the peritoneum is incised at its lowest level. During the next steps, the bilateral ligamentous mesometria and the rectovaginal fibrofatty tissue are sealed and severed at the anterior mesorectal surface, keeping the inferior hypogastric plexus lateral.

Step 11 (Figure 14.12)

After lateral mobilization of the inferior hypogastric plexus, the cranial part of the ligamentous mesometrium corresponding to the posterior leaf of the broad ligament is transected.

Step 12 (Figure 14.13)

Sealing and dissection of the ligamentous mesometrium is continued caudally at the lateral mesorectum (uterosacral ligaments).

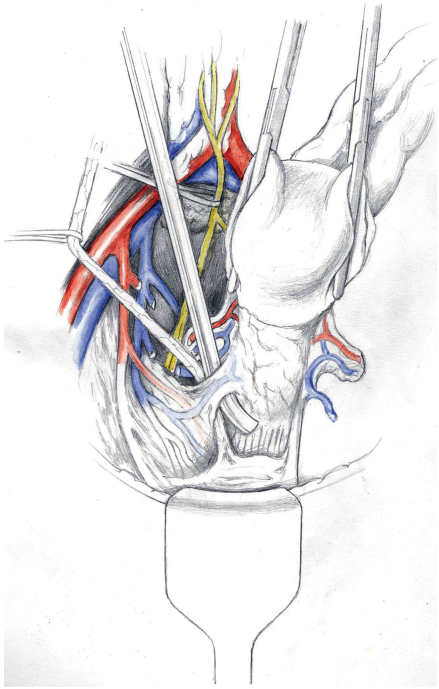

Figure 14.10 Mesoureteral mobilization II°. The mesureter is not shown in this drawing. (Courtesy of E.W. Hanns; from Höckel M, Horn LC, Manthey N, et al. 2009. *Lancet Oncol* **10**:683–92. Webappendix Figure 14, with permission.)

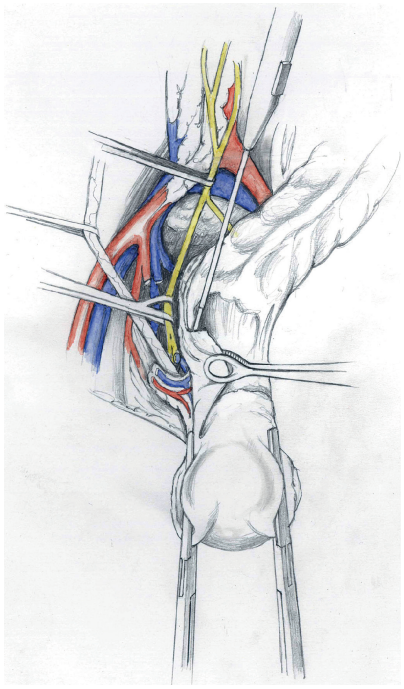

Figure 14.12 Lateral mobilization of the hypogastric nerves and proximal inferior hypogastric plexus from the ligamentous mesometrium and transection of the posterior leaf of the broad ligament. The mesureter is not shown in this drawing. (Courtesy of E.W. Hanns; from Höckel M, Horn LC, Manthey N, et al. 2009. *Lancet Oncol* **10**:683–92. Webappendix Figure 11, with permission.)

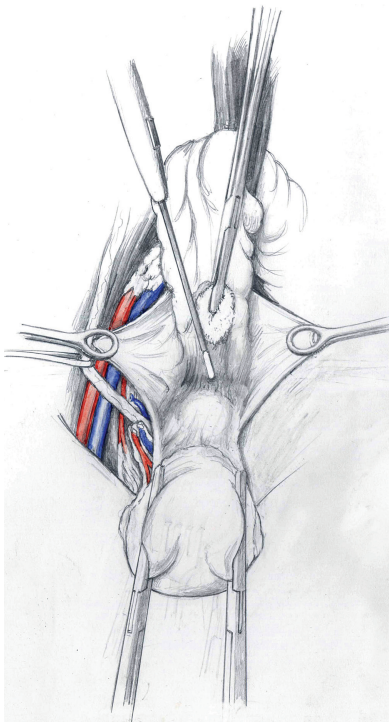

Figure 14.11 Incision of the rectouterine peritoneum. The mesureter is not shown in this drawing. (Courtesy of E.W. Hanns; from Höckel M, Horn LC, Manthey N, et al. 2009. *Lancet Oncol* **10**:683–92. Webappendix Figure 10, with permission.)

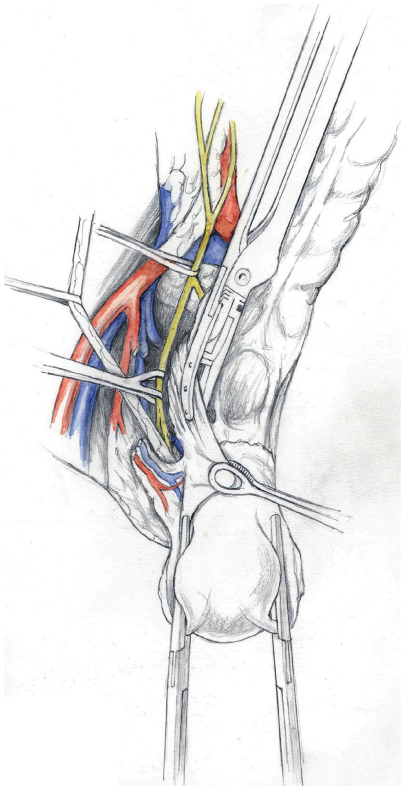

Figure 14.13 Continued dissection of the ligamentous mesometrium (uterosacral ligament). The mesureter is not shown in this drawing. (Courtesy of E.W. Hanns; from Höckel M, Horn LC, Manthey N, et al. 2009. *Lancet Oncol* 10:683–92. Webappendix Figure 12, with permission.)

Step 13 (Figure 14.14)

The ligamentous mesometrium is sealed and dissected at the anterior mesorectum (rectovaginal ligaments and septum).

Step 14 (Figure 14.15)

After clamping the vagina with a wide margin to the most caudal tumor extension, the anterior vaginal wall is incised. The transverse colpotomy is advanced and completed after sealing the dissection site.

Step 15 (Figure 14.16)

Comprehensive pelvic lymph node dissection is continued by removing the lymph nodes along the common iliac and gluteal vessels. The lumbar branch of the lumbosacral trunk, the proximal sciatic nerve, and the parietal branches of the internal iliac vessels are exposed.

Step 16 (Figure 14.17)

Presacral lymph node dissection is performed caudally to the level of S2. The superior hypogastric plexus and the hypogastric nerves are mobilized and preserved.

Step 17 (Figure 14.18)

Ascending para-aortic lymph node dissection is added in the case of intraoperatively detected pelvic lymph node metastases. The cranial border of the paracaval, interaortocaval, and para-aortic lymph

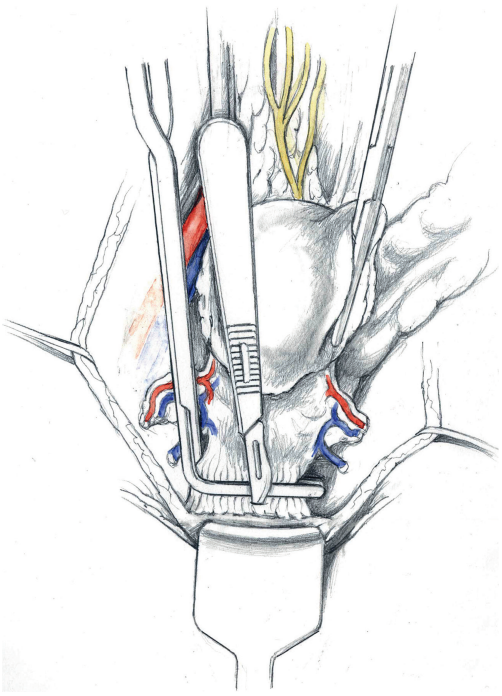

Figure 14.15 Colpotomy. The mesureters are not shown in this drawing. (Courtesy of E.W. Hanns; from Höckel M, Horn LC, Manthey N, et al. 2009. *Lancet Oncol* **10**:683–92. Webappendix Figure 15, with permission.)

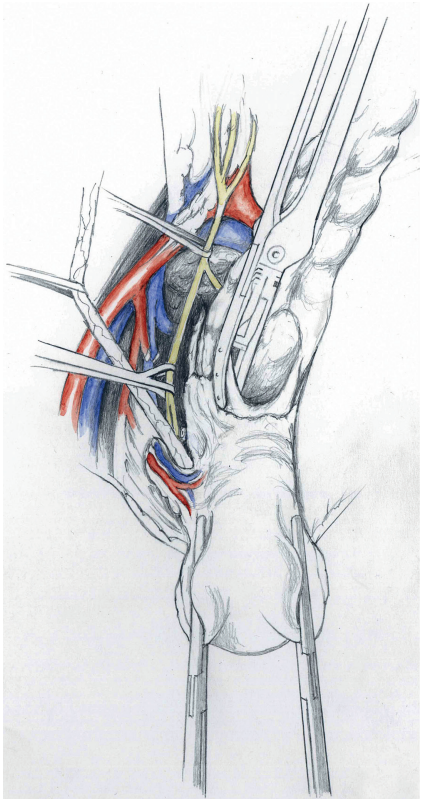

Figure 14.14 Continued dissection of the ligamentous mesometrium (rectovaginal ligaments and septum). The mesureter is not shown in this drawing. (Courtesy of E.W. Hanns; from Höckel M, Horn LC, Manthey N, et al. 2009. *Lancet Oncol* 10:683–92. Webappendix Figure 13, with permission.)

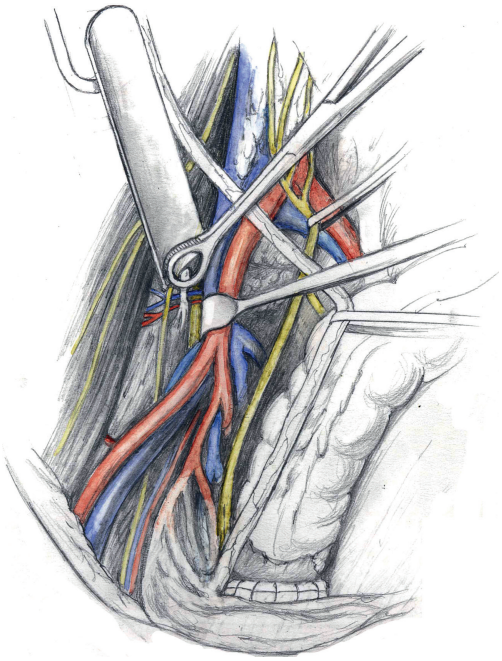

Figure 14.16 Therapeutic pelvic lymph node dissection, part II. The mesureter is not shown in this drawing. (Courtesy of E.W. Hanns; Höckel M, Horn LC, Manthey N, et al. 2009. *Lancet Oncol* **10**:683–92. Webappendix Figure 16, with permission.)

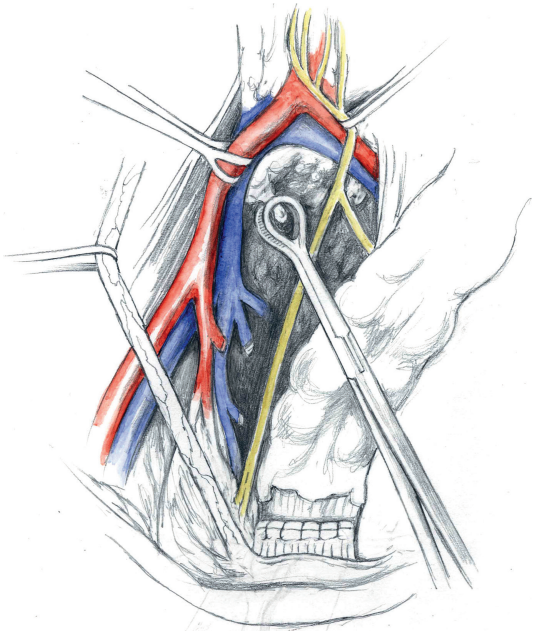

Figure 14.17 Therapeutic pelvic lymph node dissection, part III. The mesureter is not shown in this drawing. (Courtesy of E.W. Hanns; from Höckel M, Horn LC, Manthey N, et al. 2009. *Lancet Oncol* **10**:683–92. Webappendix Figure 17, with permission.)

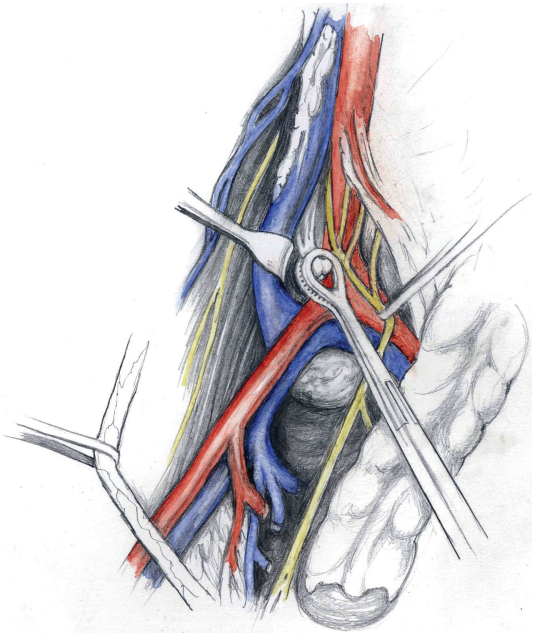

Figure 14.18 Ascending therapeutic periaortic lymph node dissection. The mesureter is not shown in this drawing. (Courtesy of E.W. Hanns; from Höckel M, Horn LC, Manthey N, et al. 2009. *Lancet Oncol* **10**:683–92. Webappendix Figure 18, with permission.)

node dissection is set to the level of the inferior mesenteric artery if the lymph nodes do not contain metastases. It will be elevated to the left renal vein if para-aortic lymph node metastases are detected on frozen section histological investigation.

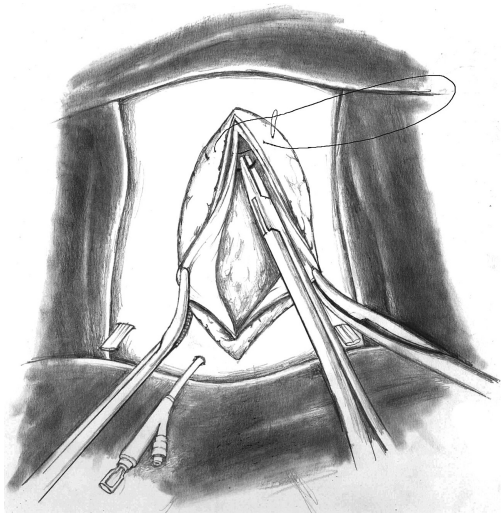

Figure 14.19 Laparotomy closure. (Courtesy of E.W. Hanns; from Höckel M, Horn LC, Manthey N, et al. 2009. *Lancet Oncol* **10**:683–92. Webappendix Figure 20, with permission.)

Step 18 (Figure 14.19)

The visceral peritoneum is united midsagitally. The sigmoid colon is refixed to the parietal peritoneum at the site of the connatal adhesions. The ovaries are sutured to the parietal peritoneum above the psoas muscles.

After suprapubic cystostomy, the laparotomy is closed with a running Smead-Jones suture. The skin is stapled.

Pathological Evaluation

- Histopathological diagnosis of pretreatment biopsies
- Intraoperative frozen section evaluation of
  - External iliac, paravisceral, and mesometrial lymph nodes
  - Ascending periaortic lymph nodes and mesometrial fractions in the case of pelvic lymph node metastases
  - Vaginal (intracompartmental) margin of the TMMR specimen
  - Eventually, compartmental border of the TMMR specimen at the site of fibrotic fixation to adjacent non-Müllerian tissues
- Preparation and investigation of the formalin-fixed TMMR specimens and topographically specified lymph node fractions according to the protocol of the Cancer Committee of the College of the American Pathologists (Kurman and Amin 1999)

OUTLOOK

TMMR holds a great potential to improve the therapeutic index of surgical cervical cancer therapy. Although standardized TMMR may be applied for the treatment of cervical cancer stages IB, IIA, and selected IIB, the new principles of surgical

radicality are also compatible with fertility-preserving mesometrial resection for small cervical cancers and peritoneal mesometrial resection for endometrial cancer. Mesometrial resections should also be feasible for being performed by minimally invasive and robotic means.

REFERENCES

Höckel M, Horn LC, Fritsch H. 2005. Association between the mesenchymal compartment of uterovaginal organogenesis and local tumor spread in stage IB-IIB cervical carcinoma: A prospective study. *Lancet Oncol* **6**:751–6.

Höckel M, Horn LC, Manthey N, et al. 2009. Resection of the embryologically defined uterovaginal (Müllerian) compartment and pelvic control in patients with cervical cancer: A prospective analysis. *Lancet Oncol* **10**:683–92.

Höckel M, Dornhöfer N. 2009. Understanding and preventing local tumour recurrence. *Lancet* **10**:645−46.

Höckel M, Horn L-C. 2013. The puzzle of close surgical margins is not puzzling. *Gynecol Oncol* **130**:224−25.

Höckel M, Hentschel B, Horn L-C. 2014. Association between developmental steps in the organogenesis of the uterine cervix and locoregional progression of cervical cancer: A prospective clinicopathological analysis. *Lancet Oncol* **15**:445−56.

Höckel M. 2015. Morphogenetic fields of embryonic development in locoregional cancer spread. *Lancet Oncol* **16**:148−51.

Kurman RJ, Amin MB. 1999. Cancer Committee College of American Pathologists. Protocol for the examination of the specimens from patients with carcinomas of the cervix. A basis for checklists. *Arch Pathol Lab Med* **123**:55–61.

Peters WA, Liu PY, Barrett RJ, et al. 2000. Concurrent chemotherapy and pelvic radiation therapy compared with pelvic radiation alone as adjuvant therapy after radical surgery in high-risk early-stage cancer of the cervix. *J Clin Oncol* **18**:1606–13.

Piver MS, Rutledge F, Smith JP. 1974. Five classes of extended hysterectomy for women with cervical cancer. *Obstet Gynecol* **44**:265–72.

Querleu D, Morrow CP. 2008. Classification of radical hysterectomy. *Lancet Oncol* **9**:297–303.

Quinn MA, Benedet JL, Odicino F, et al. 2006. 26th annual report on the results of treatment in gynecological cancer. *Int J Gynecol Obstet* **95**:S43– S103.

Sedlis A, Bundy BN, Rotman MZ, et al. 1999. A randomized trial of pelvic radiation therapy versus no further therapy in selected patients with stage IB carcinoma of the cervix after radical hysterectomy and pelvic lymphadenectomy: A Gynecologic Oncology Group study. *Gynecol Oncol* **73**:177–83.

Viswanathan AN, Lee H, Hanson E, et al. 2006. Influence of margin status and radiation on recurrence after radical hysterectomy in stage IB cervical cancer. *Int J Rad Oncol Biol Phys* **65**:1501–7.

Wertheim E. 1912. The extended abdominal operation for carcinoma uteri (based on 500 operative cases). *Am J Obstet Dis Women Child* **66**:169–232.

Zakashansky K, Bradley WH, Nezhat FR. 2008. New techniques in radical hysterectomy. *Curr Opin Obstet Gynecol* **20**:14–19.

15 Laterally extended endopelvic resection

Michael Höckel

INTRODUCTION

We have shown for cancer of the lower female genital tract (cervix, vagina, vulva) that tumors are confined to permissive tissue domains corresponding to their state of malignant progression. The cancer field theory states that the domains of potential tumor permeation can be deduced from the staged embryonic development of the tissue diseased by neoplastic transformation (Höckel et al. 2005, 2009, 2014, Höckel 2015). Considering human morphogenesis from the post-neurulation stage onward, early and late metacompartments as well as compartments can be identified by following successive morphogenetic bifurcations.

As malignant tumors represent the clinical manifestation of pathologically reactivated developmental programs that are unwound in retrograde sequence and executed in response to positional information conserved in the mature tissue, a principle of order becomes evident: During malignant progression, tumors expand their domains of permeation in tissue space quanta starting with the tissue matured from a morphogenetic subcompartment through tissues derived from compartments to those of late and early metacompartments. Locally advanced primary tumors permeate within the tissues derived from the late or even the early metacompartment in the majority of cases.

Locally recurrent tumors are not only advanced in malignant progression but also grow in a tissue landscape which may have been altered through the previous anticancer treatment. Particularly after surgical therapy, compartment borders may have been damaged and substituted by scar tissue, blurring their boundary function. Therefore, local tumor relapses are often metacompartmental even at small sizes. According to the cancer field theory, radical surgical treatment of a malignant neoplasm mandates its resection within the intact borders of the corresponding developmental tissue domain. As a consequence, most advanced primary and recurrent tumors necessitate metacompartmental resection for local tumor control.

The post-neurulation development of the uterine cervix involves the urogenital ridge (early) metacompartment, genital (late) metacompartment, and Müllerian compartment as morphogenetic fields. The Müllerian compartment develops as the closed developmental module matures into the tubes, uterus, and proximal vagina. The genital metacompartment gives rise to the gonadal and Müllerian compartments. This morphogenetic field also includes the precursor tissues of the genital peritoneum, infundibulopelvic, ovarian and round ligaments, dorsal bladder wall, superior bladder mesentery, vascular and ligamentous mesometria, rectovaginal septum, distal vagina, and dorsal urethra. The urogenital ridge metacompartment includes, in addition to the precursor tissues of the non-genital peritoneum, complete retroperitoneum, bowel mesentery, urinary mesentery, pubovesical fascia, ureter and kidneys, bladder mucosa, urethra, rectum and mesorectum, anal canal, and vulvar vestibulum (Figure 15.1).

Exenteration has been used for six decades to treat selected mostly irradiated patients with locally advanced and recurrent cancer of the lower and middle female genital tract. The mainstay for treatment success in terms of locoregional control and survival is the resection of the pelvic tumor with microscopically clear margins (R0). Although careful patient selection has led to overall survival rates of about 50%, exenterative treatments are aborted in 30% to 50% of the cases and intralesional resection is postoperatively diagnosed in up to 25%, according to a survey (Höckel and Dornhöfer 2006). New ablative techniques based on the cancer field theory termed *laterally extended endopelvic resection* (LEER) aim at increasing the curative resection rate even of tumors extending to and fixed to the pelvic sidewall (Höckel 2003, 2008, Höckel et al. 2012, Höckel 2015).

LEER resects all tissues matured within the genital (late) metacompartment. By inclusion of pelvic sidewall and floor muscles and the internal iliac vessel system into the en bloc resection, selected cases of tumors involving the urogenital ridge (early) metacompartment can be locally controlled as well (Figure 15.1). LEER is usually combined with a therapeutic pelvic and periaortic lymph node dissection unless this treatment for regional tumor control has been performed with previous surgery. For reconstruction or substitution of the pelvic functions lost due to LEER, a broad spectrum of procedures has to be available comprising ileum and transverse colon conduits, ileum neobladder, ileocecal and transverse colon pouches, rectal J-pouches, colorectal anastomosis or colostomy, rectus abdominis musculocutaneous flaps, and sigmoid colon neovagina. Therapeutic angiogenesis of the denuded and mostly irradiated pelvis, preferably by an omentum majus flap, is essential. In abdominoperineal LEER procedures, vulvovaginal and perineal reconstruction is accomplished with fasciocutaneous and musculocutaneous flaps, such as pudendal thigh flaps, gracilis flaps, and gluteal thigh flaps (Höckel and Dornhöfer 2008). General principles include using no irradiated tissue for reconstruction, and setting safety over comfort in all situations of potential surgical compromise. Secondary healing is used as a primary surgical strategy in situations where therapeutic angiogenesis is not applicable.

ONTOGENETIC SURGICAL ANATOMY

Ontogenetic surgical anatomy of the female pelvis has been introduced with regard to TMMR in Chapter 14. For local tumor control of genital cancer exceeding the Müllerian compartment, the vascular mesometrium is no longer separated from the bladder mesentery and the mesoureter. Instead, this composite tissue is resected en bloc with the Müllerian compartment, bladder, and urethra compartments and the distal ureters by sealing

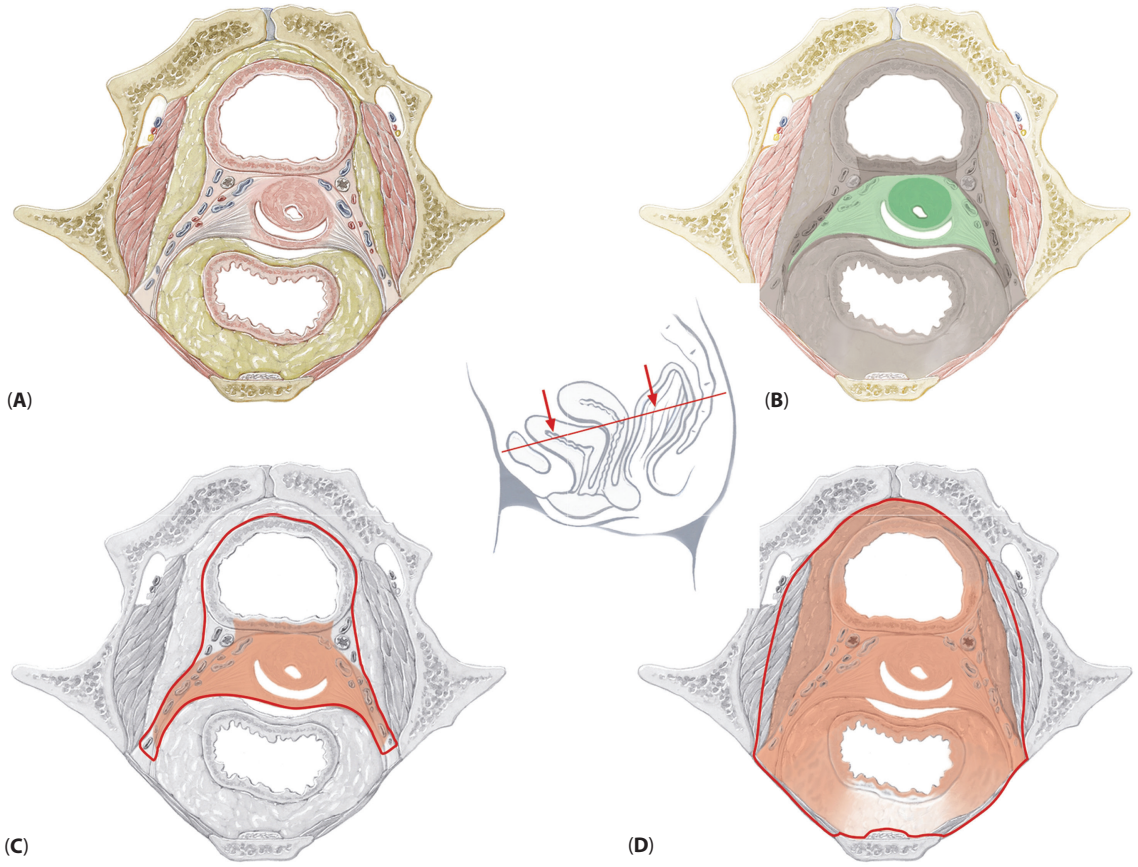

Figure 15.1 Illustration of the LEER principle demonstrated at a transverse section of the female pelvis of the level indicated in the central panel. (**A**) functional anatomical aspect showing visceral and parietal structures; (**B**) ontogenetic anatomical mapping highlighting the tissues matured from the early metacompartment in light gray, late metacompartment in dark gray, compartment in light green, and subcompartment in dark green; (**C**) resection line for a cancer field involving the tissues of the late metacompartment; (**D**) resection line for a cancer field involving the tissues of the early metacompartment. (Courtesy of N. Lechenbauer; from Höckel M, Hentschel B, Horn L-C. 2014. *Lancet Oncol* **15**:445 56.4; Höckel M. 2015. *Current Oncol Reports* **17**:1–6, with permission.)

and severing all visceral branches of the internal iliac vessel system. The resection of the vascular urogenital mesentery can be extended laterally by including the internal iliac vessel system totally or in part into the LEER specimen. To accomplish this, the parietal branches have to be sealed and dissected.

Lateral extension of the resection of the pubovesical fascia and ligamentous mesometria necessitates the inclusion of the whole or parts of the inferior hypogastric plexus and the levator ani or even coccygeus and obturator internus muscles into the LEER specimen. For selected tumors involving the early metacompartment, the rectum should be part of the integrated resection. The dorsal dissection plane is then set to the mesorectal bordering lamella. Caudal dissection of tumors exceeding the Müllerian compartment usually necessitate the inclusion of the urogenital sinus compartment, i.e., the distal vagina, urethra, and rectovaginal septum, and may even demand the integration of the vestibulum of the vulva, distal rectum, and anal canal (Figure 15.2).

SURGICAL PROCEDURE

Indications

- Post-irradiation local recurrences of uterovaginal cancer
- Locally advanced primary disease and post-surgical relapses without a radiotherapeutic treatment option

Contraindications

- Distant metastases
- Multifocal local disease
- Parietal involvement at the site of the sciatic foramen or of the pelvic vessel axis
- Insufficient fitness to tolerate the operation and cope with its sequelae

TECHNIQUE

The patient is informed about the potential minimal and maximal version of the operation with respect to resection and reconstruction. Forty-eight hours before surgery, mechanical bowel cleaning is begun. Using a central venous access, total parenteral nutrition is established and a broad-spectrum antibiotic combination (e.g., ampicillin with clavulanic acid and metronidazole) is infused. Bilateral stoma sites in the epigastric and hypogastric regions are marked. If a gluteal thigh flap is considered for reconstruction, the course of the inferior gluteal artery branch at the posterior thigh is drawn on the skin. In addition to standard surgical instruments for radical hysterectomy, Cobb periosteal dissectors are required. Surgical access is achieved through a hypogastric and epigastric midline

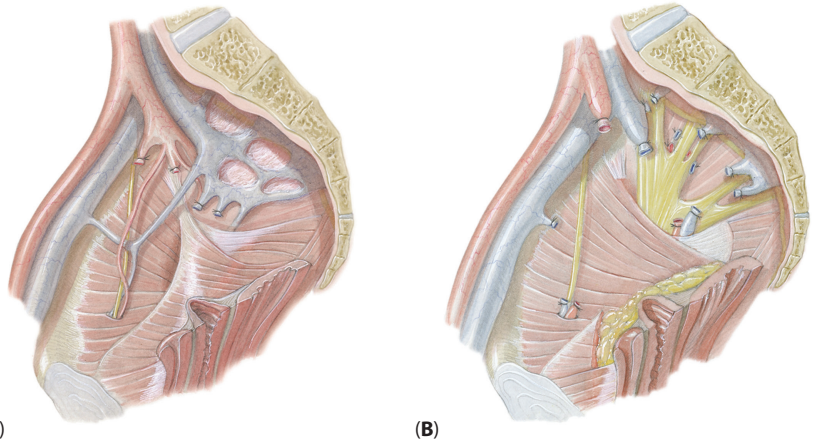

Figure 15.2 Surgical anatomy of the pelvic floor and sidewall with regard to LEER. If the tumor to be resected is fixed to the pelvic sidewall, the obturator internus, pubococcygeus, iliococcygeus, and coccygeus muscles (**A**) and eventually the internal iliac vessel system (**B**) are removed to assure completeness of the resected metacompartment. Tumor fixation to the sites of the pelvic vessel axis and sciatic foramen is regarded as contraindication for LEER. (Courtesy of N. Lechenbauer; from Höckel M, Horn L-C, Einenkel J. 2012. *Gynecol Oncol* **127**:297–302, with permission.)

laparotomy circumventing the umbilicus. For low recurrences, additional perineal incisions are necessary.

The surgical techniques of the most extensive version of LEER, the laterally extended total endopelvic resection, are illustrated in Figures 15.3 to 15.11. Pelvic wall and floor resection is performed at the left side in this example.

All peritoneal adhesions are lysed and the abdominal and pelvic intraperitoneal regions are systematically explored by inspection and palpation.

On both sides, the paracolic and pelvic parietal peritoneum is incised along the psoas muscles and the round ligaments are separated. The peritoneum at the base of the small bowel mesentery is dissected and the duodenum is mobilized against the vena cava and aorta. The small bowel and the right and transverse colon are packed into a bowel bag. The anterior visceral peritoneum of the bladder is incised and the space of Retzius is entered. The paravisceral spaces are developed as far as the location of the recurrent tumor allows. Intralesional dissection should be strictly avoided. Both ureters are liberated. Periaortic and pelvic lymph node dissection is performed as dictated by the previous treatment and the intraoperative findings.

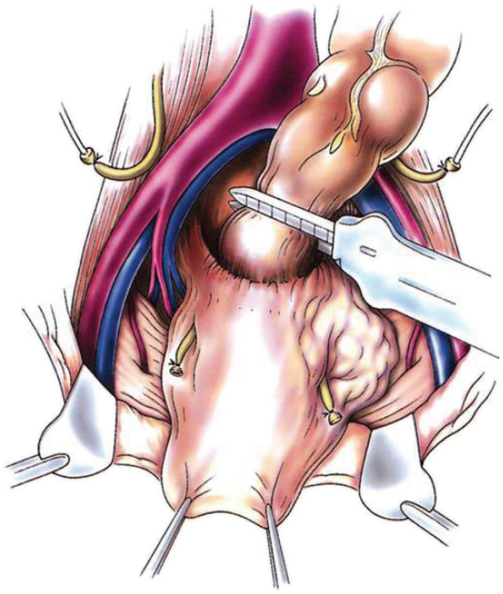

Figure 15.3 After the retroperitoneum is entered the paravisceral spaces are developed. Following periaortic and pelvic lymph node dissection both ureters are transected as deep in the pelvis as possible and stented. The bowel continuity is interrupted at the rectosigmoid transition. (Courtesy of E.W. Hanns.)

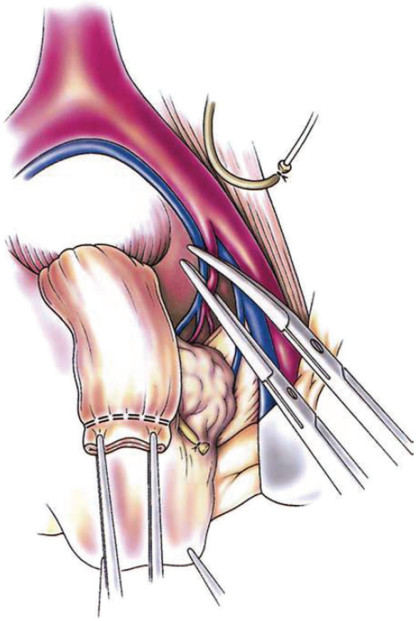

Figure 15.4 Ligation of the internal iliac artery. (Courtesy of E.W. Hanns.)

The infundibulopelvic ligaments are sealed and divided at their origins. The ureters are cut as low as possible in the pelvis. Biopsies of the distal ureters are examined with frozen sections to exclude neoplastic infiltration. Stents are inserted into the ureters. The mesosigmoid is skeletonized and the blood vessels are ligated at the rectosigmoidal transition. The bowel continuity is interrupted at this site using a gastrointestinal

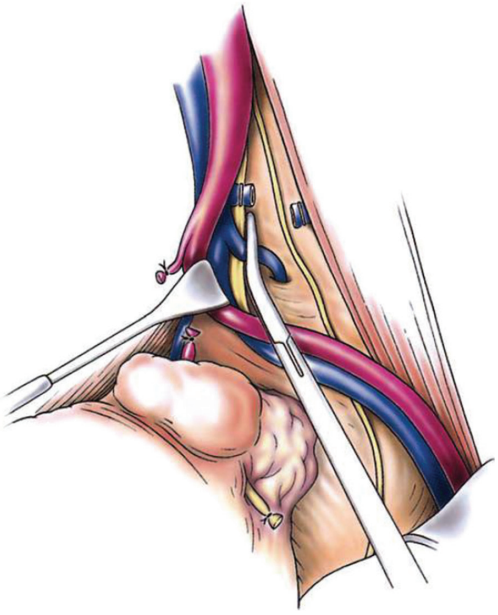

Figure 15.5 Transection of the parietal branches of the internal iliac artery and vein after retracting the common/external iliac vessels medially as a prerequisite for the ligation of the internal iliac vein. (Courtesy of E.W. Hanns.)

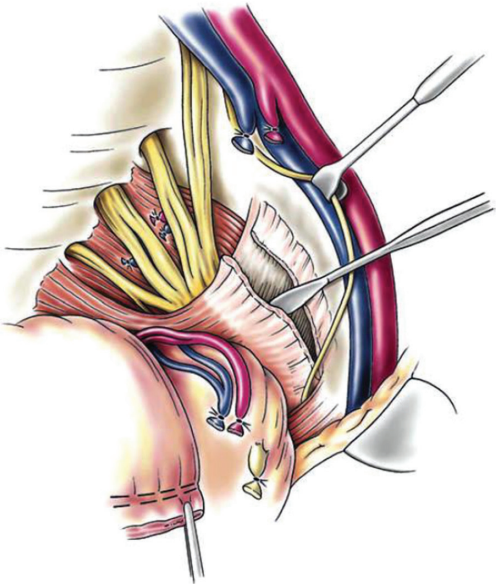

Figure 15.7 Separation of the obturator internus muscle from the acetabulum and obturator membrane with a Cobb periosteal dissector. (Courtesy of E.W. Hanns.)

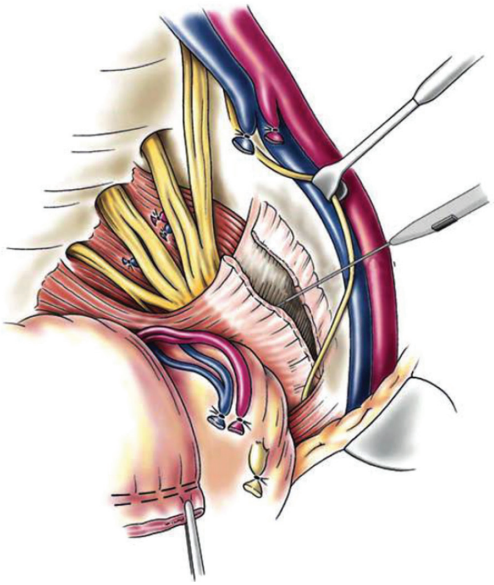

Figure 15.6 Ventral incision of the obturator internus muscle at the site of the obturator nerve which is retracted. (Courtesy of E.W. Hanns.)

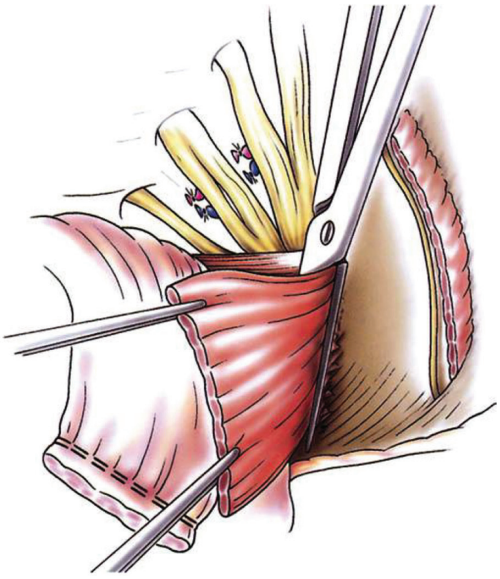

Figure 15.8 The obturator internus muscle is cut after its remaining part has been clamped at the lesser sciatic foramen. (Courtesy of E.W. Hanns.)

stapler (Figure 15.3). The sigmoid colon is included into the bowel bag.

The left internal iliac artery is ligated and divided where it branches off from the common iliac artery (Figure 15.4). Thereafter, all parietal branches of the iliac vessel system are transected after sealing the ascending lumbar vein, superior gluteal artery and vein, inferior gluteal artery and vein, and internal pudendal artery and vein (Figure 15.5). The internal iliac vein can now be divided at its bifurcation as well. The lumbosacral plexus and the piriform muscle are exposed by this maneuver.

The internal obturator muscle is incised at the site of the obturator nerve (Figure 15.6). This nerve can be preserved in most cases; rarely, it has to be divided if it is incorporated in the tumor. The muscle is separated from the acetabulum and the obturator membrane by use of a Cobb periosteal dissector (Figure 15.7). Below the ischial spine the obturator muscle which leaves the endopelvis at this point is divided again, with ligation or sealing of the muscle stump (Figure 15.8). The separated endopelvic part of the obturator muscle, in continuity with the attached iliococcygeus and pubococcygeus muscles, is retracted medially, exposing the ischiorectal fossa.

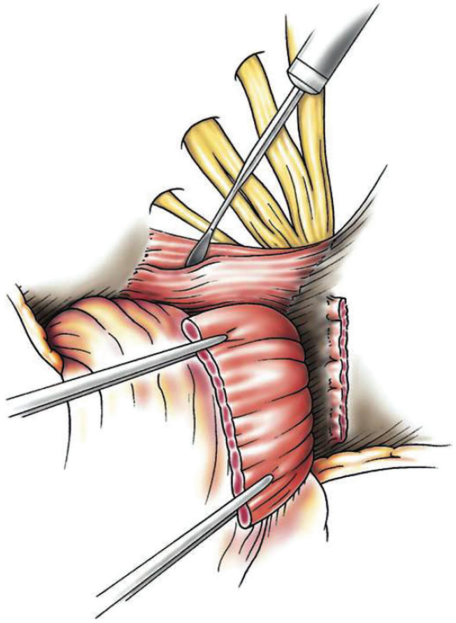

Figure 15.9 Elevation of the coccygeus muscle from the sacrospinous ligament with a Cobb periosteal dissector. (Courtesy of E.W. Hanns.)

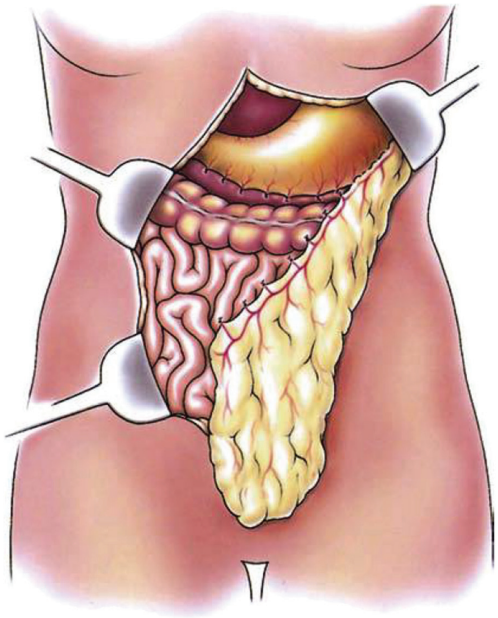

Figure 15.10 Omentum flap nourished by the left gastroepiploic vessels. (Courtesy of E.W. Hanns.)

A superficial incision is made below the lumbosacral plexus between the ischial spine and the fourth sacral body and the coccygeus muscle is elevated from the sacrospinous ligament with a Cobb periosteal dissector (Figure 15.9).

For the caudal dissection, the patient is placed into the lithotomy position. The perineal skin incision is made slightly distal to the Hart's line of the vulva including the complete vestibular compartment. Posteriorly, skin incision is continued through the anal margin. Dissection then proceeds cranially into the ischioanal fossa. Remaining origins of the levator ani muscles have to be cut. Following transection of the pubourethral ligament, the LEER specimen can be delivered either perineally or abdominally.

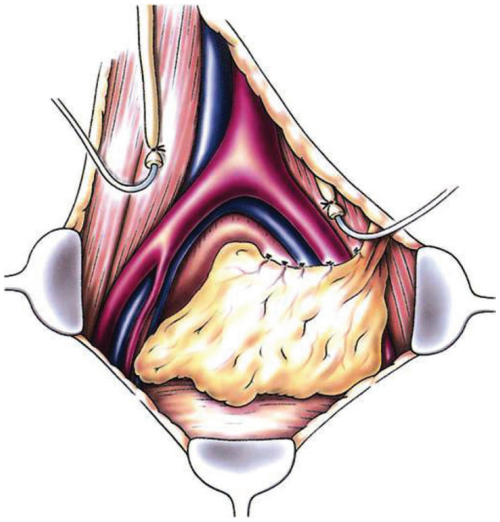

Figure 15.11 Omentum flap transposed to the pelvis for therapeutic angiogenesis. (Courtesy of E.W. Hanns.)

If the local tumor extension allows reduced surgical radicality, the internal iliac vessels, obturator and coccygeus muscles, anorectum, and vestibulum may be preserved. Vascular dissection may then involve the visceral branches of the internal iliac vessel system only. Muscular incision is made at the level of the tendineous arc and perineal skin incision is placed at the hymenal margin. Peritoneal incision in the pouch of Douglas is done as described with TMMR, however, the ligamentous mesometria are dissected at the level of the pelvic floor, and only the anterior part of the inferior hypogastric plexus is included into the LEER specimen.

To improve wound healing in the pelvis, an omentum flap nourished by the ipsilateral gastroepiploic artery is elevated (Liebermann-Meffert and White 1983), transposed to the pelvis along the paracolic gutter, and fixed to the pelvic surface (Figures 15.10 and 15.11). The inclusion of the anus and anal canal into the laterally extended pelvic evisceration necessitates the reconstruction of the perineum and pelvic floor. This can be accomplished together with the formation of a neovagina if desired by the patient by the use of gluteal thigh (Hurwitz et al. 1981), gracilis (McGraw et al. 1976), and rectus abdominis musculocutaneous (Taylor et al. 1984) flaps or pudendal thigh flaps (Wee and Joseph 1989). For supravesical urinary diversion, either a conduit or a continent pouch is constructed from non-irradiated colon segments. Fecal diversion is accomplished by an end sigmoidostomy.

The laparotomy is closed with a running Smead-Jones suture and skin stapling.

OUTLOOK

LEER holds significant potential to improve locoregional tumor control in advanced primary and recurrent uterovaginal cancer without a radiotherapeutic treatment option. Selected patients including those with tumors fixed to the pelvic sidewall and hydronephrosis traditionally not considered for surgical therapy can be salvaged.

REFERENCES

Höckel M. 2003. Laterally extended endopelvic resection: Novel surgical treatment of locally recurrent cervical carcinoma involving the pelvic side-wall. *Gynecol Oncol* **91**:369–77.

Höckel M. 2008. Laterally extended endopelvic resection (LEER)—Principles and practice. *Gynecol Oncol* **111**:513–7.

Höckel M. 2015. Long-term experience with (laterally) extended endopelvic resection (LEER) in relapsed pelvic malignancies. *Current Oncol Reports* **17**:1–6.

Höckel M, Dornhöfer N. 2005. The hydra phenomenon of cancer. Why tumors recur locally after microscopically complete resection. *Cancer Res* **65**:2997–3002.

Höckel M, Dornhöfer N. 2006. Pelvic exenteration for gynaecological tumours: Achievements and unanswered questions. *Lancet Oncol* **7**:837–47.

Höckel M, Dornhöfer N. 2008. Vulvovaginal reconstruction for neoplastic disease. *Lancet Oncol* **9**:559–68.

Höckel M, Horn LC, Fritsch H. 2005. Association between the mesenchymal compartment of uterovaginal organogenesis and local tumor spread in stage IB IIB cervical carcinoma: A prospective study. *Lancet Oncol* **6**:751–6.

Höckel M, Horn LC, Manthey N, et al. 2009. Resection of the embryologically defined uterovaginal (Müllerian) compartment and pelvic control in patients with cervical cancer: A prospective analysis. *Lancet Oncol* **10**:683–92.

Höckel M, Horn L-C, Einenkel J. 2012. (Laterally) extended endopelvic resection: Surgical treatment of locally advanced and recurrent cancer of the uterine cervix and vagina based on ontogenetic anatomy. *Gynecol Oncol* **127**:297–302.

Höckel M, Hentschel B, Horn L-C. 2014. Association between developmental steps in the Organogenesis of the uterine cervix and locoregional progression of cervical cancer: A prospective clinicopathological analysis. *Lancet Oncol* **15**:445–56.

Hurwitz DJ, Swartz WW, Mathes SJ. 1981. The gluteal thigh flap: A reliable sensate flap for the closure of buttock and perineal wounds. *Plast Reconstr Surg* **68**:521–32.

Liebermann-Meffert D, White H. 1983. Protective and reconstructive surgery with the omentum in man. In: Liebermann-Meffert D, White H, eds. *The Greater Omentum*. Berlin: Springer, pp. 211–329.

McGraw JB, Massey FM, Shanklin KD, et al. 1976. Vaginal reconstruction with gracilis myocutaneous flaps. *Plast Reconstr Surg* **58**:176–83.

Taylor GI, Corlett RJ, Boyd JB. 1984. The versatile deep inferior epigastric (inferior rectus abdominis) flap. *Br J Plast Surg* **37**:330–50.

Wee JT, Joseph VT. 1989. A new technique of vaginal reconstruction using neurovascular pudendal-thigh flaps: A preliminary report. *Plast Reconstr Surg* **83**:701–9.

16 Vaginectomy

John M. Monaghan

INTRODUCTION

The procedure of simple vaginectomy, or colpectomy, whether partial or complete, is infrequently performed as an isolated procedure but can be of value in selected situations. The most common contemporary indication is vaginal intraepithelial neoplasia (VAIN; melanoma in situ), which is most often identified in the upper vagina (Lotem et al. 2003). The lesion may appear concomitantly with cervical intraepithelial neoplasia (CIN), a de novo lesion (in the presence or absence of a uterus), or appear as persistent or recurrent disease following noninvasive or ablative strategies, such as 5-florouracil cream or laser ablation. If hysterectomy is indicated for CIN, then ideally this should be performed vaginally in conjunction with colposcopy to reduce the likelihood of the CIN and any associated VAIN being incompletely excised. In a small minority of patients (<2%), the transformation zone may naturally extend onto the vaginal vault. If such patients have had a hysterectomy for CIN without accurate colposcopy, there is a risk of leaving part of the lesion behind. Due to the prevalent habit of closure of the vaginal vault, the lesion may be included in the suture line, resulting in the risk of an occult focus of CIN developing into a cancerous lesion with time. The performance of radical vaginectomy, with or without reconstruction, is discussed elsewhere in this book.

PREOPERATIVE ASSESSMENT

The most common path to patient identification is via abnormal cytology, either from vaginal or cervix sampling. Occasionally, thickened or discolored vaginal mucosa may be identified during vaginal exam. Identification of the true site of the source of the abnormal smear may present colposcopic difficulties. Colposcopy with biopsy of any identified lesion is usually performed on an outpatient basis.

Once biopsy confirmation of a precancerous lesion is available, it is important to fully identify the full extent of the lesion in the vagina so that a tailored procedure can be planned and the patient may understand the extent of the surgery and its impact upon her sexual function. Where a complete vaginectomy is contemplated, replacement of function should be planned for the development of a neovagina.

If the lesion or lesions can be seen and fully outlined, a local excisional procedure performed vaginally is the best management method (see below). If the lesion cannot be fully visualized or it extends into the vaginal recesses following a previously created vaginal closure (so-called "dog-ears") at the angles of the vaginal vault, then a more extensive surgical procedure, sometimes aided by an intra-abdominal assessment (laparoscopic) is needed. In rare cases (e.g., medically infirm patients) radiotherapy may be considered, but the consequences must be carefully discussed with the patient or guardian.

Colpectomy is not an adequate procedure for invasive carcinoma of the vagina but may be considered in cases of microinvasive disease to rule out more extensive histology, and if limited, could be curative.

ANATOMIC CONSIDERATIONS

The close relationship of the vagina to the bladder anteriorly and to the rectum posteriorly clearly require great care when dissecting the vaginal mucosa from its supporting tissues. The close relationship of the ureters to the vaginal remnant requires careful consideration and attention during the procedure. For clinicians experienced in vaginal reconstructive surgery, identification of the clear tissue planes beneath the vaginal mucosa does not present problems. Special regard has to be taken below the urethra and also when dealing with the inevitably scarred areas at the vaginal vault.

THE VAGINAL PROCEDURE

Instruments

The instruments in the general gynecology set will be required together with colposcopy to identify smaller lesions in the upper vagina.

The Operation

1. *Identification of the lesion.* The patient is placed in a lithotomy position, cleansed, draped, and the bladder emptied. A bimanual and rectal examination is performed to exclude the possibility of a discrete invasive lesion lying above the suture line at the vaginal vault. A colposcopic assessment of the upper vagina is performed, followed by mapping of the lesion using Lugol's iodine. Infiltration of the subepithelial tissues with a solution of 1% local anesthetic with adrenaline 1:200,000 helps to define tissue planes and reduce minor bleeding. Access to the vault is best achieved by use of a large Sim's retractor placed in the posterior vagina, with a smaller vaginal retractor placed in the anterior vagina which may be moved laterally during the course of the procedure as required.
2. *The incision.* A 2-cm vaginal epithelial incision is made just inferior to the posterior margins of the lesion. This incision should give good clearance of the identified lesion and provide a rim of normal tissue which may be grasped by instruments to manipulate the tissue being dissected. It is important not to generate "crush artifacts" in the lesion, which may present diagnostic difficulties for the pathologist. It is important to "work upward" so that any bleeding does not interfere with the surgeon's view

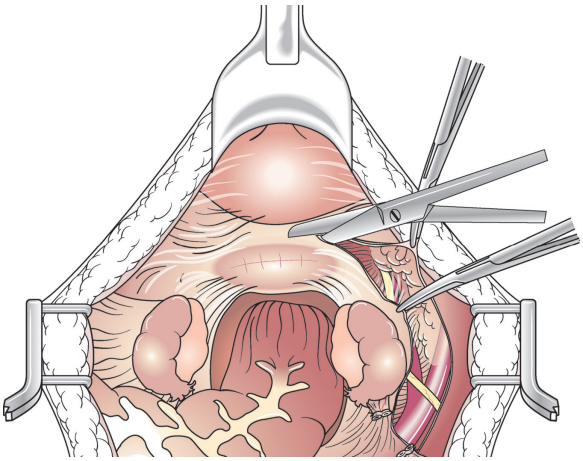

Figure 16.1 Incising the peritoneum behind the bladder.

of the operative field. A toothed dissector is used to apply traction to the skin flap anteriorly, while the blunted scissors are used to develop the subepithelial plane further toward the vaginal vault and laterally (Figure 16.1). The skin edges are incised further around the circumference of the mapped lesion as the development of the tissue planes continues. Attention is required not to "button-hole" the specimen, as this will increase the possibility of leaving diseased tissue remnants behind. Eventually, the incision is completed around the entire lesion, with the only attachment remaining being a thin strip at the vaginal vault with underlying scar tissue. Applying firm traction to the vaginal skin, the attachments at the vaginal vault are now cut to release the entire specimen and without damage to the underlying structures (Figure 16.2). In leaving the scarred tissue at the vaginal vault until last, the risk of injury to the underlying rectum, bladder, and ureters is kept to an absolute minimum, while increasing the likelihood of achieving complete excision of the entire lesion with a single specimen.

3. *Dealing with the denuded vault.* If the peritoneal cavity has been entered at the vaginal vault during the procedure, this can be either left open or closed using a continuous stitch. Individual vessels can be dealt with using a combination of sutures or diathermy. Once hemostasis is achieved, the denuded tissue at the vaginal vault may be closed primarily or left unsutured to close by secondary intention, depending on the size and location of the excision. Reconstruction with a skin graft or a local mobilization flap can be considered, depending again on the size and location of the resection, provided invasive disease has been eliminated diagnostically. A bacteriostatic soaked vaginal pack may be considered if the vaginal cuff is left open.

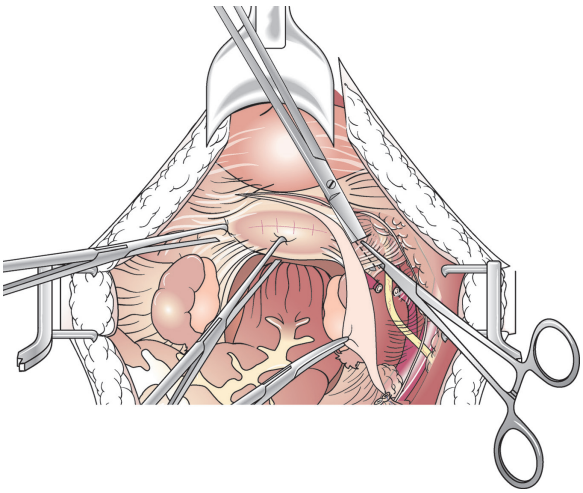

Figure 16.2 Dealing with scar tissue at the angles of the bladder and opening the ureteric tunnel.

Postoperative Care

No special attention is required, and the patient can be discharged home following removal of the pack, if placed, and catheter. Satisfactory urinary function should be checked prior to discharge.

THE ABDOMINAL PROCEDURE

An open or endoscopic approach for colpectomy in a patient in whom a hysterectomy has been previously completed is rare for preinvasive disease. However, in situations where adequate exposure or delineation of the disease is compromised such an approach may be necessary.

Instruments

The instruments for a radical hysterectomy may be required.

Preoperative Preparation

Identification of the lesion and biopsy should be as described above.

The patient should be prepared as for a radical hysterectomy with normal cross-matching of blood and simple bowel preparation. An additional procedure to mark the inferior aspect of the vaginal lesion with a marker stitch can be useful later during the operation to confirm adequate excision. A firm vaginal pack is inserted following anesthesia to facilitate dissection of the vagina from the bladder and the rectum, and a catheter on free drainage with a small (5 mL) balloon should be inserted into the bladder.

The Operation

The following describes the procedure performed during a laparotomy. Similar steps/considerations should be followed if an endoscopic (laparoscopic or robotic-assisted) approach is used. In some situations, the latter approach may provide better and more precise evaluation of the pelvic anatomy. Not unexpectedly, adhesions from previous surgery may be present and will need clearance to fully visualize the pelvic structures. Areas of special concern lie at the angles of the vaginal cuff closure where vascular plexuses may be present and the normal course of the ureter may be altered.

1. *Identifying the ureters.* After clearing obstructions and adhesions from previous surgery, the ureters should be identified as they pass along the pelvic sidewall

behind the peritoneum. The peritoneum at the brim of the pelvis is opened along a line between the remnant of the round ligament and the infundibulopelvic ligament. Using the fingers, the retroperitoneal space is opened and the ureter identified and separated from the overlying peritoneum.

2. *Dealing with the scar tissue at the angles of the vault.* The uterine artery should be identified as far laterally as possible and then divided and drawn medially. This will have the effect of identifying the entrance to the ureteric tunnel at its lateral end. This area is often surrounded by dense scarring from the previous surgery; however, if the ureteric tunnel can be accurately defined, the scar overlying it can be cut with confidence and without trauma to the ureter.
3. *Identifying the medial end of the ureteric tunnel.* Now, the uppermost point of the vagina must be palpated and a transverse incision made in the peritoneum so that the bladder can be separated from the anterior surface of the vagina. It may be necessary to use sharp dissection in order to identify the correct plane. Once this has been identified, the bladder should be pushed down in the midline; this will have the effect of making the scar tissue and the fascia overlying the ureteric tunnel laterally more prominent.
4. *Incising the roof of the ureteric tunnel.* The ureter can be identified as it passes into the bladder. If this is possible, Bonney scissors should be gently introduced over the upper surface of the ureter, and using a separating movement without cutting, the scissors are gently insinuated laterally to appear at the lateral end of the ureteric tunnel. This dissection may be performed from medial to lateral or in the reverse direction. It is important not to kink or to nip the ureter in the edges of the scissors; the simple maneuver of lifting the scissors while in the tunnel will allow a good view of the entire length of the ureter. A medium straight tissue forceps is then placed over the scissors and the ureteric tunnel and the scar tissue incised (Figure 16.3). The pedicle is then tied, as it carries some veins and small arteries to and from the bladder. At this point, there may still be a few strands of fascia passing across the ureter; these should be divided and the tissue plane between the ureter and the vagina identified. The cardinal ligament is now visible below and medial to the ureter. Sharp dissection may still be required if there has been extensive scarring from the previous surgery. The upper vagina is revealed very quickly and the ureters dislocated laterally. The firm pack in the vagina greatly facilitates this dissection.
5. *Releasing the vagina posteriorly.* An incision is made in the peritoneum at the upper posterior part of the vagina. This incision is then extended laterally over the remnants of the uterosacral ligaments. The rectum is now easily pushed away from the posterior surface of the vagina by passing the fingers down into the rectovaginal space.
6. *Removing the vagina.* At this point, having released the ureters laterally, the bladder anteriorly, and the rectum posteriorly, the surgeon can decide just how much vagina is needed to remove. The uterosacral and then the paracolpos is grasped and clamped in non-penetrating (e.g., Zeppelin) clamps and the chosen length of vagina removed. If the requirement is to remove the upper part of the vagina to excise VAIN, no further dissection is necessary and the vagina can be opened at this point to confirm placement of the original marker stitch and adequate excision of tissue. If a total vaginectomy is necessary, the abdominal dissection should be extended down the vagina to the pelvic floor. Thereafter, the patient is put in a lithotomy position and the lower vagina dissected free from the urethra and bladder anteriorly and the rectum posteriorly. Great care should be exercised when dissecting below the urethra, as the fascia is very dense and the dissection must be accurate. Having joined up with the abdominal dissection, the entire vagina can be removed. Bleeding around the pelvic floor is readily dealt with.
7. *Draining the vagina.* The space left behind after vaginectomy will vary in size depending on the extent of the procedure. Following partial vaginectomy there is no need for special drainage procedures except to leave the vaginal remnant open. However, after total vaginectomy either a vaginal passive drain or a suction drain should be put in place. This may be augmented by a pelvic suction drain brought out abdominally if it has been necessary to perform an extensive dissection in the pelvis. It is the author's experience that remarkably little drainage is necessary.
8. Where it has been decided that a neovagina should be developed, this part of the procedure will immediately follow the vaginectomy.

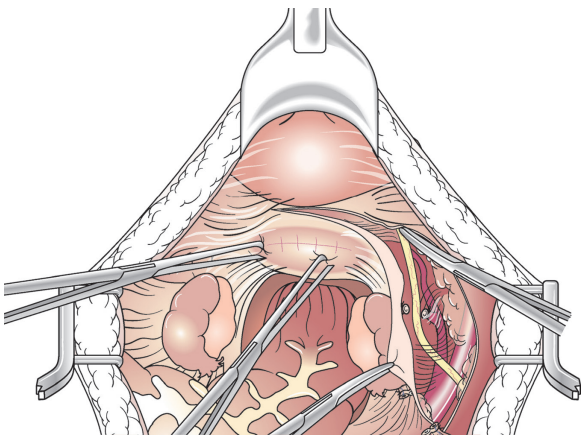

Figure 16.3 Dividing the roof of the ureteric tunnel.

Complications

The main postoperative problems following this procedure will be similar to those following radical hysterectomy, particularly bladder dysfunction and difficulties in initiating micturition.

Postoperative Care

The patient should be managed in the same manner as the radical hysterectomy patient, particular emphasis being placed on bladder care, and in the long-term continued surveillance of any remnants of vaginal tissue remaining.

REFERENCE

Lotem M, Anteby S, Peretz T, et al. 2003. Mucosal melanoma of the female genital tract is a multifocal disorder. *Gynecol Oncol* **88**(1):45–50.

17 Radical vulvar surgery

John M. Monaghan

INTRODUCTION

When Basset published his monograph on the surgical treatment of cancer of the clitoris in 1912, he outlined the major criteria for the operative management of cancer of the vulva which was utilized worldwide for most of the twentieth century. Basset outlined the importance of the metastases to the groin and the equal importance of removing the lymphatic ray connecting the primary tumor on the vulva with the primary lymph node drainage site in the groin. It is important to remember that although Basset outlined these surgical maneuvers, all his work was performed on cadavers and the procedure was rarely used in live subjects.

In the 1920s, Victor Bonney (1920) continued the tradition of radical vulvectomy and groin node dissection in British patients. However, it was Stoekel, working initially in Munich, and later in Berlin, who demonstrated the need for individualization of surgical treatment. Stoekel, in his seminal monograph of 1930, outlined every known variant of surgical treatment, many of which have later been "rediscovered" by other experts around the world. Closer to home, Stanley Way, working in Gateshead (UK) in the 1940s, reconfirmed the importance of the lymphatic ray and the drainage of the vulva, and suggested that a wide local excision of the lesion on the vulva should be combined with an extensive dissection of the skin of the suprapubic area and the groin (Way 1948). Unfortunately, although the cure rates for cancer of the vulva improved markedly when radical treatment was adopted, the adverse effects of such massive surgery were that patients spent a considerable time in hospital and were left with large wounds requiring intensive nursing care. Interestingly, the long-term result of these large wounds was frequently a remarkably satisfactory cosmetic effect.

As a consequence of the realization that not all patients required such radical surgery, in the latter part of the twentieth century, moves toward individualization of care, first outlined by Stoekel in 1930, were resurrected. It is now common practice to accurately stage the cancer of the vulva with careful measurement, both clinical and pathological, and based on these measurements, to determine exactly the most appropriate surgical procedure to achieve high cure rates with minimal adverse cosmetic effect.

ANATOMIC CONSIDERATIONS

Blood Supply

The blood supply to the vulva is derived from the internal pudendal artery, a terminal branch of the anterior division of the hypogastric artery (internal iliac artery). A contribution from the superficial and deep external pudendal artery originating from the femoral artery is of variable amount. The internal pudendal artery continues as the posterior labial vessels that supply the posterior part of the labia majora, labia minora, and the vestibule. The anterior labial branches of the external pudendal vessels and the small arteries of the ligamentum teres, a branch of the inferior epigastric, may also contribute to the blood supply.

Nerve Supply

The nerve supply of the vulva is derived from a variety of sources. The mons pubis and upper labia majora are innervated by the ilioinguinal nerve and the genital branch of the genitofemoral nerve. The superficial perineal branches of the pudendal nerve supply the labia majora and the structures of the external genitalia. The deep branches supply the clitoris, vestibular bulb, and muscles of the region.

Lymphatic Drainage

Most carcinomas of the vulva affect the labia majora and minora. The second commonest site is the clitoris. All these skin areas have a lymphatic drainage which passes in a narrow ray through the groin into the superficial inguinal lymph nodes and then through the cribriform fascia into the femoral nodes, which are in close proximity to the femoral artery and vein immediately below the fossa ovale. While the superficial groin nodes are disparate and variable in their position, the femoral nodes are more constant, lying in close proximity to the vessels. The drainage from the femoral nodes then passes cranially through the inguinal ligament to enter the lymphatics of the external iliac system.

Alternative Routes of Lymph Drainage

In the past, there was concern that lymphatic drainage may occur directly through the perineal membrane into the external iliac lymphatic system, but this has been disproved in a variety of studies. However, it will be noted that retrograde spread may sometimes occur down into the nodes alongside the saphenous vein when the nodes of the femoral group are heavily involved with tumor. Current sentinel node experience reflect these historic observations.

INDICATIONS

Over many years it has been demonstrated that for virtually all patients with truly invasive cancer of the vulva it is mandatory not only to perform a wide local excision of the tumor on the vulva, but also to remove the groin nodes. This broad instruction initially generated by Basset in 1912 has been modified and made more sophisticated due to an understanding of the metastatic spread patterns depending on the depth of invasion of the tumor. Careful measurement of tumor invasive depths has demonstrated that where the tumor invades for <1 mm, that is, stage IA, then the risk of nodal metastases is zero. In these circumstances, a wide local excision of the lesion on the vulva is all

that is required. For any depth of invasion beyond 1 mm the risk of nodal metastases rises markedly and it is vital that all patients should be subjected to groin node dissection.

Initially, this instruction was interpreted as requiring a radical excision of the lesion on the vulva in continuity with the lymphatic ray and the groin node dissection itself. Stoekel (1930) and other authors since have demonstrated that because of the initial pattern of metastatic spread, that is, embolization rather than permeation of lymphatic vessels, it is possible to leave behind the skin bridge between the groin and the vulva, and by carrying out separate groin dissections the patient can safely and confidently be cured of her condition (Grimshaw et al. 1993). For all small tumors, where there is no clinical involvement of the groin nodes, the use of separate groin incisions is now the preferred method of management.

It has also been shown where a tumor is placed laterally on the vulva, that is, that the tumor does not impinge on a line drawn below the clitoris, or behind a line drawn through the fourchette, then the patient need only be subjected to a unilateral (ipsilateral) groin node dissection. The risk of contralateral groin node spread is vanishingly small.

Role of the En Bloc Dissection

It is the author's belief that when groin nodes are obviously grossly involved that a full radical vulvectomy with an en bloc dissection of the groin nodes is the optimal management. The reason for this is that once nodes are filled with metastatic tumor there will be stasis in the lymphatic ray and a high risk of leaving active tumor behind if separate incisions are used.

Pelvic Node Dissection

In the past, the pelvic nodes were also routinely dissected, but these should only be dissected and/or included in a treatment field when there is gross involvement of the groin nodes and where there is clear evidence of tumor continuity through the femoral canal into the external iliac system. Few modern series will be able to comment on survival data for patients with positive pelvic nodes. In the author's early series when this dissection was commonly performed, 19% of patients with positive pelvic nodes survived 5 years (Monaghan and Hammond 1984).

Identification of Lymphatic Spread and Nodal Involvement

The techniques available for identification of involved groin nodes have been many and various. It has been known for many years that palpation is of very limited value and modern imaging techniques, including computed tomography (CT), nuclear magnetic resonance (NMR) imaging, ultrasound, and sentinel nodes, have all demonstrated variable results. Philip Disaia et al. (1979) described the use of a "sentinel node" technique for determining metastatic spread to the groin nodes. The concept was perfect but the difficulties in identifying the true sentinel node made its use uncertain until now. Levenbach et al. (2001) have demonstrated that by injecting vital blue dye into the leading edge of the tumor it is possible to pick up blue nodes in the groin, which can be regarded as the sentinel nodes for the remainder of the groin lymphatics in breast cancer, sentinel node identification using a radiolabeled material (technetium) has been elevated to the point at which one can confidently utilize the sentinel node technetium technique in order to determine the involvement of the remaining nodes (De Cicco et al. 2000). If the sentinel node is negative when removed, then the clinicians may be able to dispense with a formal groin node dissection, thus markedly reducing the morbidity for the patient. If the groin node shows involvement, then a formal dissection of the groin may be contemplated. The most difficult aspect of the use of sentinel node assessment is the possibility of micrometastases being missed by the examining pathologist. One technique now commonly utilized is to perform cytokeratin immunohistochemical staining in cytologically negative sentinel nodes. These techniques were utilized in two large observational trials of sentinel node mapping in early-stage vulvar cancer—GROINSV-1 and GOG-173 (van der Zee 2008). Both clinical trials were performed to assess whether sentinel node assessment would be a reasonable surrogate of pathology in the groin. The determinant of failure was an unacceptable rate of false negatives—that is, the situation where the sentinel node was identified and histologically negative, yet tumor deposits were identified in the non-sentinel nodes. In both studies, the false negative predictive value was about 2% to 4%. Whether triage by sentinel node status can avert lymphadenectomy completely is the subject of the ongoing GROINSV-II trial. As sentinel node assessment has moved to be the norm in the workup of the patient, occasional reports of recurrence after negative sentinel nodes have been reported. Despite these reports, the use of sentinel node assessment is now considered de rigeur for vulval cancer patients (Knopp et al. 2008).

SURGICAL PROCEDURE

Patient Preparation

Previous recommendations for preoperative preparation included preadmission for 1 to 2 days. Currently, this is neither warranted nor covered under most health care plans. However, in addition to routine preoperative testing and anesthesia evaluation, there is a need for the patient to fully understand all real and potential complications of surgery, as wound breakdown continues to occur in spite of many modifications and some femoral nerve bundles may be resected during the groin dissection, leaving anesthesia and paresthesia over areas of the anterior thigh.

Thromboembolic Prophylaxis

The average age of patients developing vulval cancer is in the late seventh decade, and the risk of developing thromboembolic disease is high. It is important to initiate thromboembolic prophylaxis shortly before surgery and to maintain it using a variety of methods until the patient is fully ambulant. The use of subcutaneous heparin, anti-thromboembolic stockings, and intraoperative muscle pumps are all of great value (see Chapter 2). Early mobilization following surgery, however, remains the cornerstone of efforts to reduce thromboembolic risks.

Operative Procedure

The patient is placed in the supine position on the operating table with the ankles separated by approximately 20 cm. This allows the groin folds to be opened and gives easy access for the groin dissection.

Skin Incision

For the vast majority of patients, separate groin node dissections will be performed. The incision should run from approximately 4 cm medial to the anterior superior iliac spine down to a point some 4 cm below the pubic tubercle. Although it is common for surgeons to use a single incision, the author has found that by performing a double incision, leaving a skin strip approximately 1 cm wide along the length of this incision will allow easier manipulation of the block of lymph nodes which will be dissected below this incision. The incision is carried down in a manner which allows a triangular block of tissue to be removed down to the superficial fascia. When outlining the incision, it is important to utilize bony landmarks and to ignore natural skin folds, which may be very variable, particularly in obese patients. Figure 17.1 shows the incisions to the groin and vulva.

Defining the Fascial Planes in the Groin Incisions

The thin strip of skin in the groin is picked up using tissue forceps so that the whole block of tissue in the groin can be maneuvered during the dissection. Gentle tension is put on the upper edge of the skin incision with the left hand and the surgeon incises in a slightly angular fashion upward, down to the level of the aponeurosis of the external oblique muscle above the groin. In a similar fashion, the fascia over the sartorius muscle that forms the lateral boundary of the femoral triangle can now be identified. The fascia over the sartorius muscle is incised longitudinally from just below the anterior superior iliac spine to the lower apex of the femoral triangle (Figure 17.2). Small vessels in the fat and on the muscle surface may be cut and should be meticulously identified and tied or diathermied.

Division of the Saphenous Vein

In the lower part of the femoral triangle the saphenous vein may be identified as it curves inferiorly. It can be easily isolated where it lies above the fascia lata and is then divided and ligated at the apex of the lower part of the dissection.

Some surgeons preserve the saphenous vein, dissecting it out and cleaning it in its superficial passage, and then identifying it as it drops through the fossa ovale. The author does not believe that cutting the saphenous vein significantly increases the risk of lymphedema. However, it is appreciated that this vein is sometimes harvested for other indications if patent.

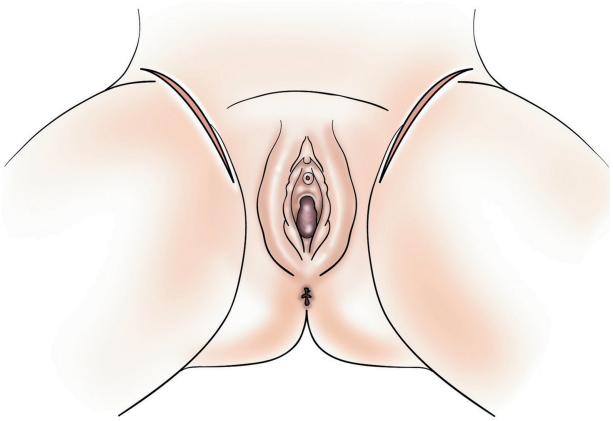

Figure 17.1 The incision used in the "triple incision" technique.

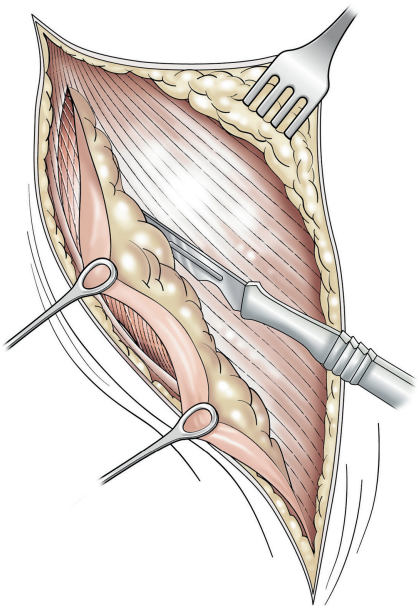

Figure 17.2 Incising the fat and fascia down to the external oblique aponeurosis and the sartorius muscle.

Developing the Deep Dissection

The medial edge of the incised fascia over the sartorius muscle is now picked up using two small Spencer Wells clips (Figure 17.3). Strands of the femoral nerve can now be seen in the soft tissue at the medial side of the sartorius muscle and should be preserved wherever possible. On the medial side of the sartorius muscle the femoral artery will be identified and should be cleaned from the lower part of the femoral triangle cranially to the inguinal ligament. This meticulous cleaning will then reveal the femoral vein lying on the medial side of the femoral artery. The saphenous vein will now be noted to be passing from the superficial lymph node area through the fossa ovale into the femoral vein, roughly at its midpoint in the exposed femoral triangle. The saphenous vein should be clamped close to its entry into the

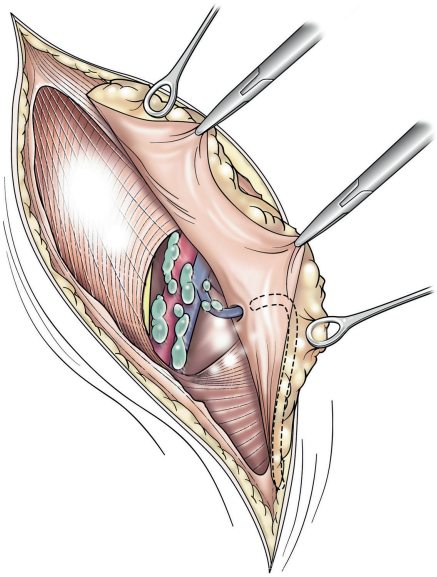

Figure 17.3 The medial edge of the sartorius fascia is elevated by forceps.

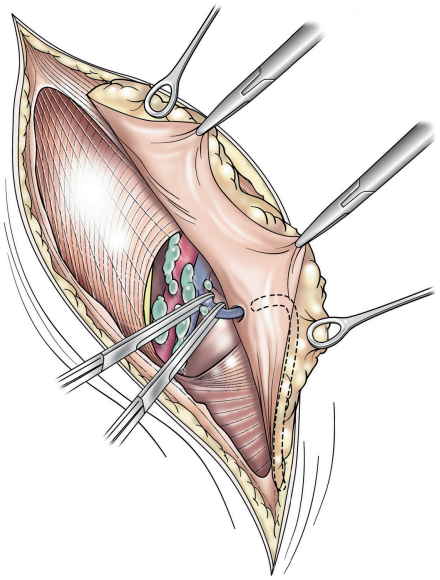

Figure 17.4 The saphenous vein is identified as it passes through the fossa ovale from the superficial compartment.

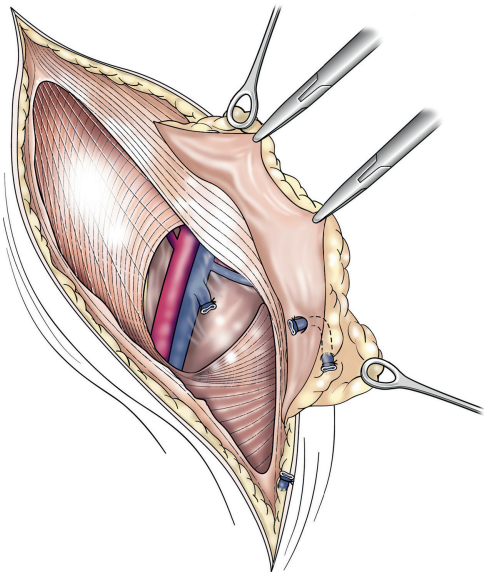

Figure 17.5 The superficial groin nodes are removed en bloc and the final cleansing of the femoral vessels can be achieved.

femoral vein as shown in Figure 17.4. With the surgeon's left hand raising the block of tissue containing the superficial lymph nodes, the femoral vein can be seen lying on the medial side of the femoral artery with the divided saphenous vein passing through the fossa ovale, which is now turned over to reveal its underside. Meticulous cleaning of all tissue around the femoral artery and vein will remove all the femoral lymph nodes. This cleansing should be carried out up to the inguinal ligament and occasionally the node of Cloquet or Rosenmuller will be identified as it fills the femoral canal. In normal circumstances this will be the upper limit of the nodal dissection.

Cleaning the Adductor Muscles

The block of tissue elevated by the surgeon containing all superficial and femoral nodes can now be put on tension by drawing it medially, and the surgeon continues a dissection under the fascia covering the adductor muscles on the medial side of the femoral vein. This dissection will continue through to the outer part of the adductor muscles over a distance of approximately 5 to 6 cm. Small veins that enter the muscles may require ligating at this point but most of the tissue plane is avascular. The dissection is completed by cutting through small amounts of fat on the medial side of the elevated block of tissue, and the comprehensive dissection of the groin nodes has been achieved (Figure 17.5). The completely cleansed femoral triangle will now be lying open. The two skin edges will lie together very closely without any tension. It is important first of all to put in place a small suction drain. The author finds it valuable to utilize a continuous fat stitch, drawing together the subcutaneous fat, and thereafter the skin incisions can be easily stapled in a linear fashion.

The fat stitch assists in making the sutured incision airtight. Once the suction drain is activated, the skin will depress into the defect generated by removal of the groin nodal mass. This suction should be maintained for some days until drainage reduces markedly or ceases altogether.

The Vulval Incision

The most important element in performing radical vulvectomy is designing an appropriate incision that will both lead to adequate excision of the primary tumor and optimize a strategic closure. The margin generally recommended is a minimum of 1 cm, and it is important to remember that the margins not only occur laterally and medially, but also deeply, so that the dissection should be carried down to the superficial fascia below the fat layers.

Where the tumor lies close to the urethra or anus it may not always be possible to gain the full 1-cm margin, but it is important to remember that the terminal urethra can be sacrificed and extension of the incision closer to the anus will be achievable without compromising continence. Figure 17.6 shows the incisions which can be utilized in a small tumor with extensive skin change affecting most of the vulva. The use of posterior releasing incisions may only be necessary where the tumor is very large and apposition of the skin is not so easily achieved at the end of the dissection.

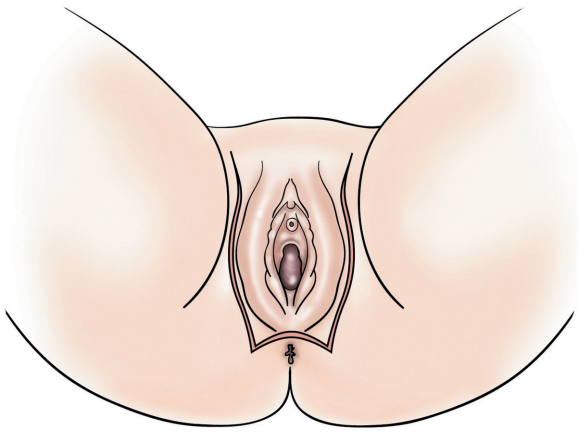

Figure 17.6 The vulvar incision to be used when there is a small tumor and the removal of associated skin changes is required, such as Vulvar intra-epithelial neoplasm (VIN).

The author would recommend that the incision begins anteriorly some 2 cm above the clitoris, passing in an elliptical fashion, providing the 1- to 2-cm margin around the tumor, and also performed in a similar fashion on the opposite side in order to produce a symmetrical result. In those circumstances where the tumor is small and laterally placed it may be possible to perform a hemivulvectomy and ipsilateral groin node dissection achieving a high chance of cure with an excellent cosmetic result. However, the preservation of vulval skin on the opposite side may increase the risk of new tumor occurring in the future.

During radical vulvectomy surgery, significant vessels will be identified around the clitoral base, and posteriorly the deep labial branches of the internal pudendal artery. These three sites are the major sources of bleeding. It may be necessary to utilize square mattress sutures in dealing with the bleeding around the clitoral base, but the pudendal vessels can normally be dealt with by simple clipping and tying. Diathermy and tying of small vessels below the skin in other parts of the vulva should be meticulous achieving a high level of hemostasis.

Primary closure of the vulval wound may be achieved utilizing a series of interrupted sutures or following any number of plastics closures (advancement graft, skin graft, myocutaneous graft, etc.; see Chapter 23). The most important aspect of closure is minimizing tension across the closure, keeping in mind natural movement stresses on the resection site. Vertical mattress suture is particularly helpful where the tissues are deep due to excessive fat.

Pelvic Node Dissection

As noted above, indications for removing the pelvic nodes are rare. In order to achieve a margin when the groin nodes are involved it may be necessary to dissect the pelvic nodes, although in many practices radiotherapy is utilized as an adjuvant treatment to extend the field of management.

If the pelvic nodes are to be dissected, they are best approached following the completion of the groin phase. The incision to access the pelvic nodes is made some 2 cm above the inguinal ligament (Figure 17.7) in a line along the external oblique aponeurosis. A second incision is now made deep to this along the line of the internal oblique muscle fibers, roughly at right angles to the first incision. The second incision is taken down through the transversalis muscle to the peritoneum. The peritoneum is kept intact, and using the fingers, it is gently swept medially, revealing the brim of the pelvis and the external iliac vessels.

Using appropriate retraction, the entire external iliac, obturator, and internal iliac nodes to the common iliac can be dissected. It is sometimes prudent to split the inguinal ligament to improve access, but care to identify and sometimes ligate the inferior epigastric artery is necessary at this time.

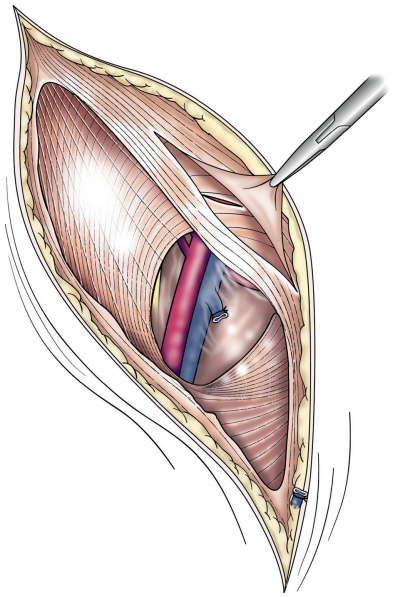

Figure 17.7 The external oblique aponeurosis is incised superolaterally.

The wounds in the muscles are repaired in reverse order to achieve a strong closure with minimal risk of hernia development.

REFERENCES

Basset A. 1912. Traitement chirurgical operatoire de l'epithelioma primitif du clitoris. *Rev Chir (Paris)* **46**:546.

Bonney V. 1920. In: Berkeley C, Bonney V, eds. *A Textbook of Gynaecologica Surgery*. London: Cassell, p. 122.

De Cicco C, Sideri M, Bartolomei M, et al. 2000. Sentinel node biopsy in early vulvar cancer. *Br J Cancer* **82**(2):295–9.

Disaia PJ, Creasman WT, Rich WM. 1979. An alternate approach to early cancer of the vulva. *Am J Obstet Gynecol* **133**:825–30.

Grimshaw RN, Murdoch JB, Monaghan JM. 1993. Radical vulvectomy and bilateral inguinal-femoral lymphadenectomy through separate incisions—Experience with 100 cases. *Int J Gynecol Cancer* **3**:18–23.

Knopp S, Nesland JM, Trope C. 2008. SLNB and the importance of micrometastases in vulvar Squamous cell carcinoma. *Surg Oncol* **17**:219–25.

Levenbach C, Coleman RL, Burke TW, et al. 2001. Intraoperative lymphatic mapping and sentinel node identification with blue dye in patients with vulvar cancer. *Gynecol Oncol* **83**(2):276–81.

Monaghan JM, Hammond IG. 1984. Pelvic node dissection in the treatment of vulval carcinoma—Is it necessary? *Br J Obstet Gynaecol* **91**:270–4.

Stoekel W. 1930. Zur Therapie des Vulvakarzinoms. *Zentralbl Gynakol* **1**:47–71.

van der Zee A, et al. 2008. Sentinel node dissection is safe in the treatment of early-stage vulvar cancer. *J Clin Oncol* **26**:884–9.

Way S. 1948. The anatomy of the lymphatic drainage of the vulva, and its influence on the radical operation for carcinoma. *Ann R Coll Surg Engl* **3**:187.

18 Sentinel lymph node biopsy

Michael Frumovitz, Robert L. Coleman, and Charles M. Levenback

INTRODUCTION

Advances in surgical management among the solid tumors have developed in response to a variety of catalysts over the years. One of these has been the pursuit of surgical precision—balancing maximal survival against morbidity of therapy. This relatively recent concept derives from a combination of an improved understanding of disease biology and the identification of effective adjuvant therapies, which have allowed modification of traditional surgical paradigms and procedures. Lymphatic mapping and sentinel node identification represents one of these advances, which among diseases, such as malignant melanoma and breast cancer, have radically altered classic surgical practices once deemed "the final achievement of surgery" (Way 1951). Integration of lymphatic mapping into triage and management has dramatically improved treatment precision by offering better disease characterization with the potential for reduced toxicity through less radical intervention. The purpose of this chapter is to introduce the concept of lymphatic mapping and sentinel node identification as it is being developed among the gynecologic cancers and to report on the early, albeit promising, experience, particularly in vulvar and cervical malignancy.

WHAT IS LYMPHATIC MAPPING?

Lymphatic mapping is simply documentation of the regional lymphatic spillways from an organ of interest. While obvious in our current understanding of the metastatic process, the role of the regional lymphatics and their direct relationship with the major anatomic structures was somewhat elusive in early studies and anatomical dissections. Limited by evaluation of putrefied and fixed tissue, reliable identification of the lymphatic channels to the regional lymph nodes was a major challenge for early anatomists. Painstaking dissections led to the production of remarkable drawings of lymphatic anatomy, which served as reference materials for future generations of surgeons who ultimately designed operative procedures to remove these "at risk" sites. Indeed, the "en bloc" resection of these "at risk" nodal basins championed by Halsted is heralded as one of the first great advances in the primary surgical treatment of solid tumors (Halsted 1907). To aid the visualization of individual lymphatic vessels, various dyes have been developed and used, including early adoption of a number of mercurial compounds. While an important adjuvant, this dye technique most likely contributed to some early erroneous depictions of lymphatic anatomy, such as Sappey's illustration of vulvar lymphatics crossing the labiocrural fold (Parry-Jones 1963) (Figure 18.1). Subsequent development of more lymphotrophic dyes, techniques of administration, and study of live tissues provided a more "functional" understanding of the regional lymphatics. Focused on gynecology, these functional pathways have been well characterized by Plentl and Friedman (1971) in their landmark monograph, *Lymphatic System of the Female Genitalia.*

HISTORICAL PERSPECTIVE

The purpose of clinical lymphatic mapping is identification of the node or nodal group that receives the principal and primary flow from the target organ (Figure 18.2). Theoretically, these tissues hold the highest promise for disease characterization, as they should represent the first localization and highest statistical risk for early metastatic spread. In the early twentieth century, the French gynecologists Leveuf and Godard (1923) studied the lymphatic anatomy of the cervix by injecting Gerotti blue into the cervices of neonatal cadavers. They found that the injected dye reproducibly drained to a lymph node usually found in the obturator space or at the bifurcation of the iliac vessels. They named this the *principal* lymph node. The term *sentinel node* is most often credited to Ernest Gould, who proposed that the lymph node found at the junction of the anterior and posterior facial veins was the first and most important basin for patients with parotid cancer (Gould et al. 1960). Based on observations in 28 patients, he reasoned that if a negative node in this anatomic region was found it would be unlikely that other regional nodes would contain disease, and thus one could forego a full neck dissection. However, it was Ramon Cabanas (1997), who combined the concepts of regional lymphatic flow and selective regional node identification into the technique of modern lymphatic mapping. Studying penile cancer patients with lymphography (performed via cut-down and canalization of the dorsal lymphatic of the penis), he found that a sentinel lymph node was always located among the superficial inguinal nodes. He also noted that the sentinel node was involved with disease in all patients who had metastases and that it was the only node positive in a proportion of patients (12 of 80 cases). He suggested that only those patients with a positive sentinel node required complete lymphadenectomy. These findings have been corroborated in other solid tumors, including malignant melanoma and breast and vulvar carcinomas.

MAPPING TECHNIQUES

Blue Dye

Developmental steps in refining the lymphatic mapping technique have been promulgated by a need to simplify the procedure and to develop an effective intraoperative strategy enabling precise nodal identification and treatment triage in one step. The first compounds used in this progression were selective lymphotrophic dyes. Wong et al. (1991) experimented with isosulfan blue, methylene blue and cyalumede in a feline model, and found that isosulfan blue associated better with lymphatic vessel uptake and sentinel node identification (Figure 18.3). Alternative mapping materials that have been successful include

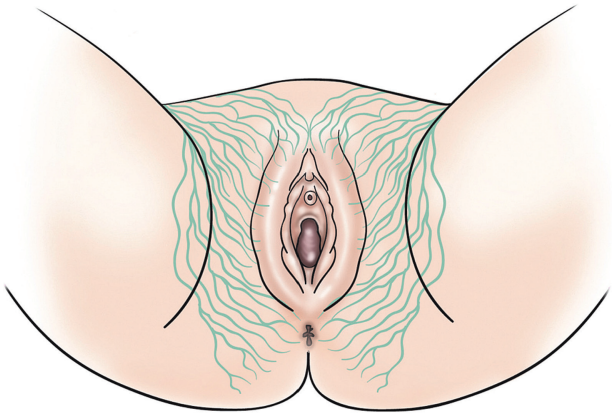

Figure 18.1 Vulvar and perineal lymphatics as depicted by Sappey in 1874. Use of mercurial dyes in cadaveric tissue led to the erroneous depiction of lymphatic vessels in the vulva and perineum draining across the labiocrural folds to regional lymph nodes.



Figure 18.3 Vial of isosulfan blue trademarked as Lymphazurin 1% (5 cm^3).

fluorescein and patent blue-V; however, the former requires a dark room and is associated with tissue extravasation (Bostick and Giuliano 2000). Typically, 2 to 5 mL of dye is injected via a small gauge needle (e.g., 25 gauge) into the dermis of the normal tissue surrounding the primary tumor. Intradermal injection is important in lesions of the vulva in order to access the superficial dermal lymphatics that communicate with the groin (Figure 18.4). Deep subcutaneous injection will result in uptake into the deep lymphatics accompanying the named vessels of the vulva and perineum to the pelvis. In the cervix and other solid organs, such as the uterus and ovaries, the injection is made deep enough to access the stromal lymphatic elements. These are generally located within 5 mm of the overlying epithelium. In some organs, such as the vagina, the anastomotic plexus is well developed and intercommunication throughout the entire organ can be accomplished with a single injection. Preferred routes of lymphatic drainage were thought to exist even among these situations, best illustrated in the vagina where distal lesions were thought to drain into the inguinal femoral system and proximal lesions into the low pelvic lymphatics, mirroring cervical drainage (Plentl and Friedman 1971). However, more recent mapping studies of the vagina show that these traditional anatomic routes do not always hold true, and lower vaginal lesions may drain into the pelvis, while tumors at the apex may preferentially drain to the groins (Figure 18.5) (Frumovitz et al. 2008). Once the dye is deposited, uptake is rapid and can be observed in real time for some sites. Localization into the sentinel node occurs between 5 and 15 minutes and may remain in the node for up to 60 minutes before dissipating. Procedures that require time to identify "at-risk" nodal basins should take into account these temporal constraints prior to dye delivery. For instance, in cases of cervical cancer mapping where laparotomy is planned, it is preferable to have the abdominal field exposed at the time of dye deposition, given the large number of potential lymphatic basins to be evaluated and the rapidity of the dye uptake in the vessel-rich parametrium. Although these dyes are largely

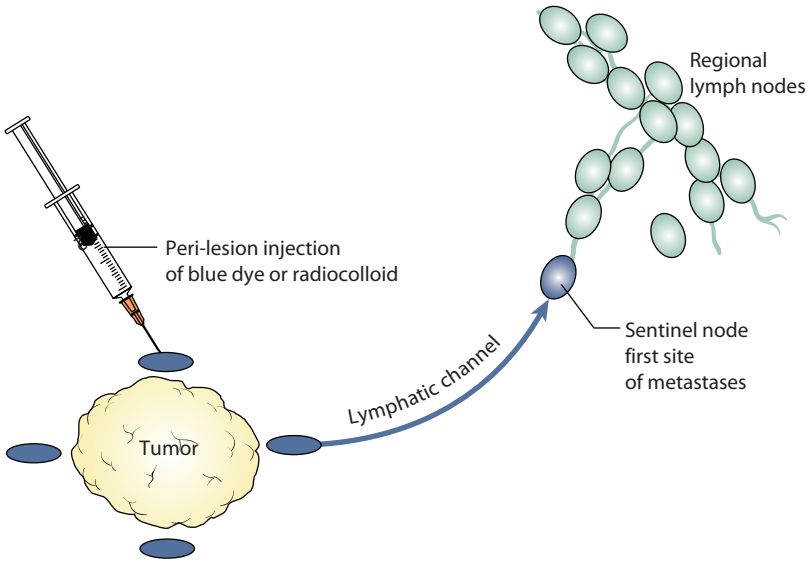

Figure 18.2 Schematic of the concept of lymphatic mapping. A preferred pathway from the tumor primary to the regional basin drains into the sentinel node.



Figure 18.4 Intradermal injection around a vulvar carcinoma. Deeper injections will drain along the deep lymphatics that line the vascular supply to the vulva.

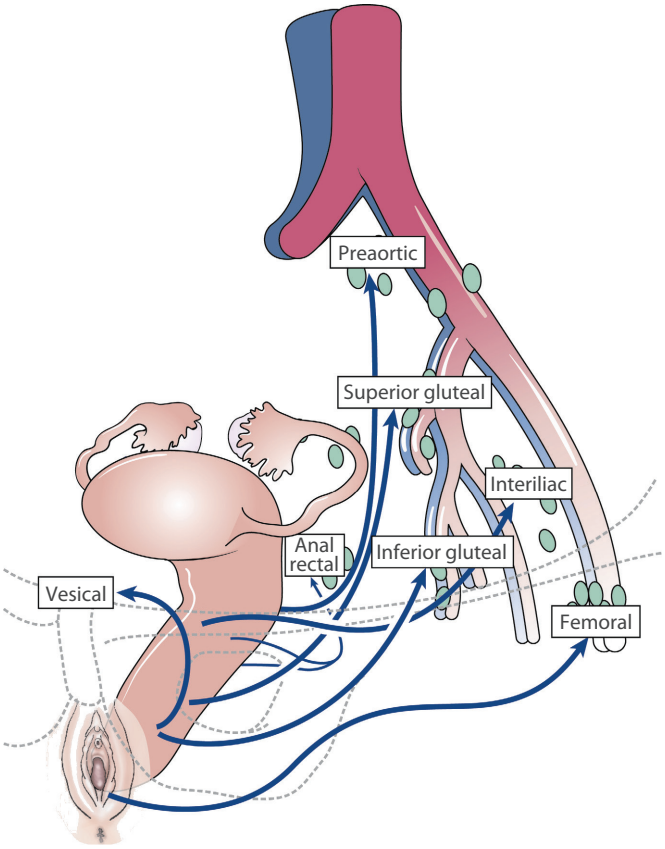

Figure 18.5 Lymphatic drainage of the vagina. A rich anastomotic network exists that allows intercommunication of lymph throughout the organ. However, specific locales of the vagina will preferentially drain to regional basins from the inguinofemoral nodes to the external iliac nodes.

lymphotropic and weakly bound to serum proteins, side effects and complications have been observed. Fortunately, these are infrequent, occurring in approximately 1% to 2% of patients (Leong et al. 2000). Primary excretion of isosulfan blue is biliary, and thus patients with hepatic insufficiency may be at increased risk for complications. The most common effect seen with dye administration is a transient cohort change (gray or blue hue) in the skin with discoloration of the urine. In some cases it may be quite dramatic, albeit of limited duration. Allergic reaction and anaphylaxis have been rarely reported and manifest in classic manner with cardiovascular collapse, erythema, angioedema, bronchospasm, urticaria, gastrointestinal symptoms, and pulmonary edema (Sadiq et al. 2001). While these effects are generally observed within 10 minutes of intravenous injection, most mapping procedures are performed by intradermal injection, and thus could be delayed as much as 30 minutes. Treatment is supportive. Occasionally, a pseudo-anaphylaxis clinical picture may present, usually first indicated by progressive loss of oxygen saturation. Compounded by gray skin coloring, the condition is of concern but lacks features of cardiovascular collapse. Coleman et al. (1999) described this condition and hypothesized its etiology as related to dye interference with noninvasive pulse oximetry saturation algorithms. Peak absorbance of isosulfan blue is 646 nm, which is very near that of oxyhemoglobin (660 nm), one of two hemoglobin species measured by noninvasive pulse oximetry. The short-lived condition may be confirmed by a simple arterial blood gas determination. Many hospital operating rooms now have standard protocols for the administration of H2-blockers, antihistamines, and/or steroids prior to injection of mapping dyes in order to reduce anaphylactic reactions.

Radiocolloid, Lymphoscintigraphy, and Intraoperative Gamma Counters

The blue staining of a node with identification of at least one blue-stained afferent lymphatic channel entering the node remains the gold standard for assessment of whether a lymph node is or is not a true sentinel node. However, introduction of techniques such as radioactive colloid injections and lymphoscintigraphy have enhanced the accuracy of detecting the sentinel node. These have been particularly useful in identifying nodes outside of their routine anatomical landmarks of dissection and in aiding the surgeon intraoperatively via a hand-held gamma probe to identify sentinel nodes which have stained poorly or ambiguously. Historically, injection of radionuclides into human subjects to localize regional lymph nodes was first reported by Sherman and Ter-Pogossian in 1953. Numerous radiolabeled compounds have since been used for this purpose. The first gynecologic application of lymphoscintigraphy was in 1982, when Iversen and Aas (1983) studied lymphatic drainage in 24 patients with stage IB cervical cancer. While they were unable to distinguish metastatic from nonmetastatic nodes by radiocolloid uptake, they did remark that radioactivity was higher in certain nodes compared to the background—possibly an early representation of a sentinel node. However, it was Morton et al. in 1992 who brought this modality to the clinical arena by demonstrating its utility in identifying "at-risk" node basins among 223 cutaneous melanoma patients. Since this report, validation of the strategy has occurred in a number of solid tumors, including head and neck, endocrine, gastrointestinal, genitourinary, breast, and reproductive tract cancers. The ideal radiocolloid must gain access to the lumen of the initial lymphatic channel in sufficient quantity for the lymph vessels to be seen on the dynamic scans. It should combine a

Table 18.1 Characteristic of Radionuclides

	^{99m}Tc-SC	^{99m}Tc-HCA	^{99m}Tc-HSA
Particle size (nm)	100–400 (Filtered: 15–50 nm)	5–80	2–3
Transit time to SN (min)	11	10	5
Range (min)	(1–60)	(1–65)	(1–75)
Injection dose at site (3 hr)	76%	83%	–
Visible nodes (30 min) ± SD	2.1 ± 1.9	2.1 ± 1.3	2.2 ± 0.9
Washout t1/2 ± SD (hr)	14 ± 12.7	7.5 ± 6.4	4.3 ± 1.4

^{99m}Tc-SC, technetium-99 sulfur colloid; ^{99m}Tc-HCA, technetium-99 human colloidal albumin; ^{99m}Tc-HAS, technetium-99 human serum albumin.
Source: Adapted from Wilhelm AJ, Mijnhout GS, Franssen EJ. 1999. *Eur J Nucl Med* **26**:S36–S42.

rapid and predictable transport toward the sentinel node with persistent retention. The particle size of the 180-min radiocolloid is a critical factor in the ease with which these tracers enter the lymphatic system (Table 18.1). Large particles (500–2000 nm) remain trapped at the injection site, and small particles (4–5 nm) will penetrate the capillary membranes and will not be available to migrate through the lymphatic channels (Ege 1976, Henze et al. 1982). In the United States, the most commonly used radiopharmaceutical is filtered technetium-99 m sulfur colloid. This agent has a small particle size (<100 nm); it is uniformly dispersed, highly stable, and has a short half-life (gamma-emitter). Injection flow rate of a radiocolloid is important in the success of sentinel node identification. Once the particles enter the lumen of the lymphatic capillaries, they will move freely and uniformly toward the draining lymph nodes. The valves in the lymphatic vessels will generally not allow retrograde flow. Lymphatic flow is fastest in the leg and foot and slowest in the head and neck. The study is performed by injection of 2 to 4 mL (1–2.5 mCi) intradermally and perilesionally as with blue dye. A lymphoscintigram is then made to visualize localized uptake (Figure 18.6). Dynamic images are usually acquired for a total of 20 minutes. The lymphatic channels are best appreciated by summing the individual dynamic frames to produce a composite dynamic image. Delayed scans are then performed at 2.5 to 3 hours following injection of the radiocolloid tracer. These delayed scans should include all node fields that can possibly receive drainage from the injection site. Each static acquisition should be 5 to 10 minutes in length to ensure that even very faint sentinel nodes are detected (Uren and Howman-Giles 2002). Newer radiologic technologies such as single photon emission computed tomography (SPECT-CT) (Figure 18.7) are becoming more routinely used. This exam combines traditional planar lymphoscintigraphy with computed topography (CT) to locate the sentinel node in a three-dimensional image, as opposed to the traditional two dimensions seen on lymphoscintograms. The intraoperative detection of the sentinel node relies not only on the visual inspection of the lymphatic basin, but also on the assessment of the radioactive colloid in the sentinel node through the aid of a gamma detection device. This hand-held sensor contains a gamma-sensitive crystal with a preamplifier, and a reading unit (Figure 18.8). There are several gamma probes for intraoperative use including laparoscopic devices that can be used in a large spectrum of clinical scenarios. Specificity and accuracy of these devices can be augmented with the use of collimation which will help to reduce background and "bleed-through" radioactivity, frequently encountered in sites where the primary tumor is near its drainage lymphatic basin (Figure 18.9). The parametrial nodes in uterine cervical primary and the medial inguinofemoral nodes in an anterior vulvar cancer are good examples of challenging mapping areas. Use of these radiopharmaceuticals appears to be safe given their low dose energy, particle size, and rapid washout rate. Extensive testing has been conducted to determine the safety to healthcare workers. The amount of radiation exposure from the technique is very small, and the cumulative effect is still well within acceptable levels (Eshima et al. 2000).

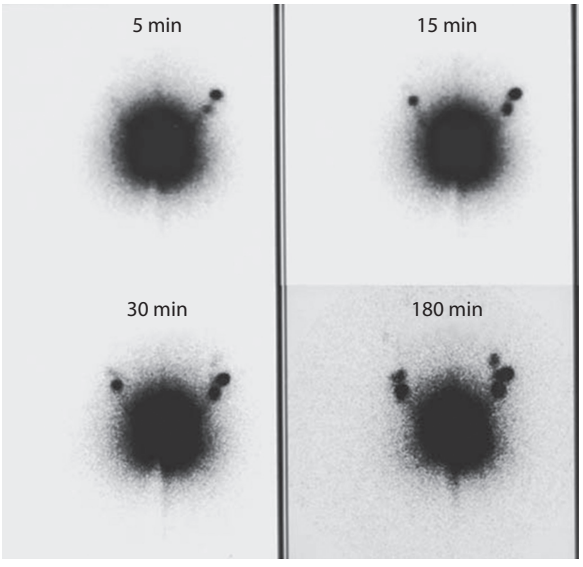

Figure 18.6 Example of the temporal relationship between time of injection and visualization of the regional basins. This example is from a woman with a stage II vulvar cancer. The time between scans is listed. It is debated as to whether the lateral and newly visualized nodes at 180 minutes represent secondary basins or "second echelon" nodes.

Indocyanine Green and Near-Infrared Fluorescence Imaging

Indocyanine green (ICG) is a water soluble amphiphilic molecule that "fluoresces" when excited by a laser in the near-infrared light spectrum range of 700 to 850 nm (Figure 18.10). This is well above the visible light spectrum which lies below 600 nm. ICG has a plasma half-life of 3 to 5 minutes and is eliminated via the liver. It should not be utilized in women with iodine allergies but otherwise has a very low risk of anaphylactic reactions.

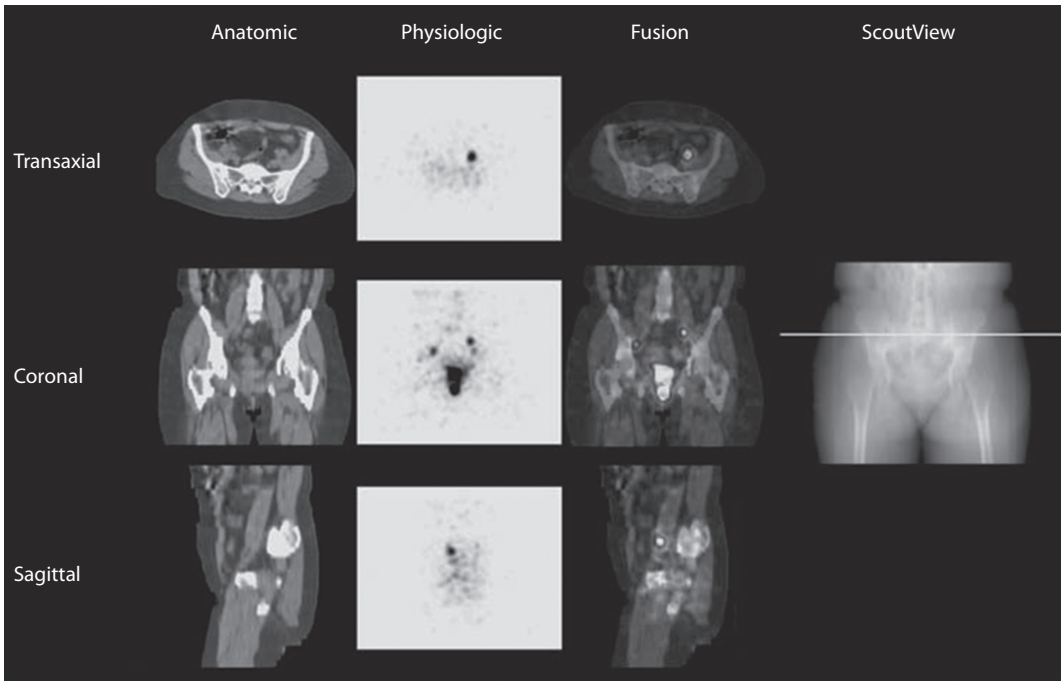

Figure 18.7 Example of a single photon emission computed tomography (SPECT-CT).



Figure 18.8 Portable gamma probe for use in vulvar and laparotomy facilitates intraoperative lymphatic mapping.



Figure 18.9 Local injection of radiocolloid may concentrate so highly as to obscure potential identification of proximally situated sentinel nodes. In this example of cervical injection, it is easy to appreciate the difficulty of identifying a parametrial node.

Other advantages of ICG and immunofluorescence include the ability to follow lymphatic channels and detect sentinel nodes in real time during dissection. Near-infrared imaging of ICG can penetrate tissue 2 to 3 mm, therefore allowing for localization of sentinel nodes through tissue planes. This is particularly helpful in obese tissue where detecting blue dye through thick adipose tissue can be very difficult. Use of near-infrared imaging allows for detection of ICG even when fields are stained or obscured by bleeding. Finally, ICG has a long track record for safety and is very inexpensive. A major disadvantage, however, is that although ICG is inexpensive, utilization of the tracer requires specialized near-infrared imaging equipment, which can be quite expensive. That being said, near-infrared imaging systems are currently available for open, laparoscopic, and robotic approaches.

ICG is injected in a manner similar to what has been described for the other mapping substances. ICG comes as a powder that must be reconstituted with sterile water. Most dilute the powder to a concentration of 0.5 mg/mL to 1.25 mg/mL and inject 2 to 4 mL total volume for lymphatic mapping. Studies evaluating ICG as a mapping substance for gynecologic malignancies have focused mainly on uterine and cervical cancers (Holloway et al. 2017). In these studies, ICG has been shown to be superior to blue dye alone and comparable to blue dye and radiocolloid.

Currently ICG is only FDA approved for vascular and hepatobiliary imaging via intravascular injection; however, an indication for use in lymphatic mapping is expected soon.

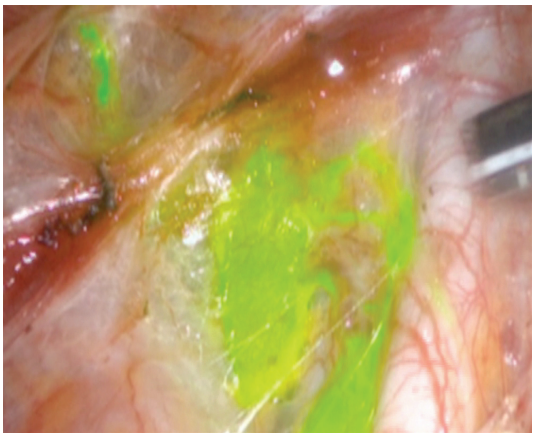

Figure 18.10 Indocyanine green and immunofluorescence delineating right external iliac sentinel node.

SENTINEL NODES: PATHOLOGIC EXAMINATION

Traditionally, pathologic assessment of a lymphadenectomy specimen entails teasing out individual lymph nodes from the surrounding fat pad, bisecting each, and embedding them in paraffin for hematoxylin and eosin (H&E) staining. Typically, one slide from each side of the nodes is evaluated. From the pathologist's point of view, each slide has an equal chance of containing metastatic disease. While standardized, the technique evaluates only an estimated 0.1% of the total nodal volume, raising the possibility of a false negative diagnosis. Sentinel node retrieval provides the opportunity for improved precision, since the pathologist can focus his/her search for metastatic disease. In this manner, the sentinel node larger than 1 cm can be step-sectioned at 2- to 5-mm intervals and slides developed from each cut surface (Figure 18.10). Nodes smaller than this may be totally imbedded or bivalved for evaluation. In breast cancer patients, step-section processing has revealed underestimation of micrometastatic disease in 9% to 33% of node-negative cases (International (Ludwig) Breast Cancer Study Group 1990). In our experience, 20% of patients with metastatic cervical cancer to the lymph nodes will have false negative findings without ultrastaging of the sentinel nodes (Euscher et al. 2008). The expansion and availability of immunohistochemical techniques during the 1990s has afforded an additional measure of accuracy by allowing pathologists to evaluate the sentinel node tissue sections for specific markers (Table 18.1).

In the case of gynecologic epithelial tumors such as cervical and vulvar cancer, specific cytokeratins (AE1/AE3 and DF3) are made from pairs of step-sectioned nodal tissue (Figure 18.11)

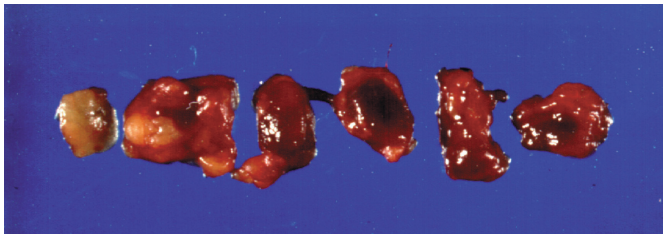

Figure 18.11 Harvested sentinel nodes are serially sectioned (bread-loafed) to provide additional material for hematoxylin and eosin staining as well as immunohistochemistry.

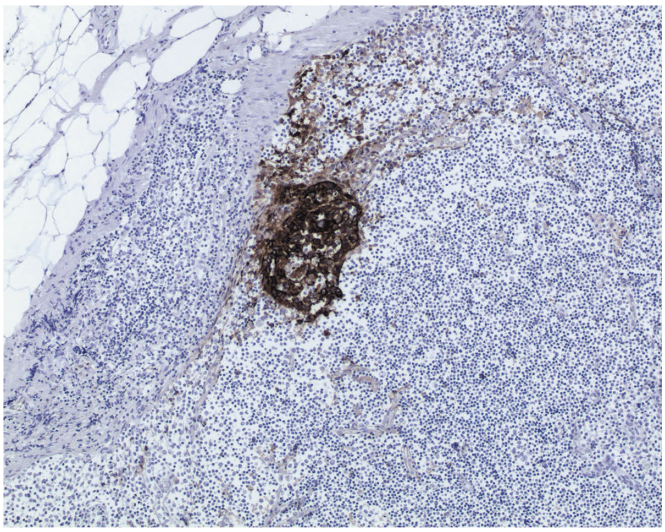

Figure 18.12 Micrometastasis of squamous cell carcinoma in an inguinofemoral sentinel lymph node. Small tumor deposits may be difficult to distinguish by hematoxylin and eosin staining in the background nodal architecture. In this example, cytokeratin AE1/AE3 is highlighted through immunohistochemistry. (Courtesy of Ate van der Zee.)

and evaluated for micrometastatic deposits (Figure 18.12). The technique has been adapted to be available intraoperatively (Eudy et al. 2003, Munakata et al. 2003, Nahrig et al. 2003). The value immunohistochemistry adds to serial sectioning is debated, but individual series from gynecological lymphatic mapping procedures has reported unidentified micrometastatic disease in up to 4% of negative nodes (de Hullu et al. 2000). An increasingly important question will be how to manage patients with negative sentinel nodes on traditional H&E staining but positive by immunohistochemistry or other biochemical marker. Van Trappen et al. (2001) used rapid polymerase chain reaction (PCR) testing for cytokeratin 19 in the lymph nodes of radical hysterectomy patients. Lymphatic mapping was not performed; however, it appears that the highest concentration of CK-19-positive nodes was found at the common sites of sentinel nodes. CK-19 was found in only one lymph node from nine patients with benign disease, whereas 44% of the H&E-negative lymph nodes in the cervical cancer patients had CK-19 detected. A clearer understanding of micrometastatic disease and how the regional lymphatic process of these cells could form the basis of future molecular work.

CLINICAL EXPERIENCE

Vulvar Cancer

Several contributions have identified functional anatomic features that particularly suit vulvar carcinoma patients with the lymphatic mapping concept. The most important are the clear identification of an ordered pathway from the vulva to the regional inguinofemoral lymphatics and the infrequency of "in-flight" metastatic deposits in the skin bridge between the primary lesion and the regional basin. Parry-Jones (1963) demonstrated that the vulvar lymphatics did not cross the labiocrural folds as had been previously suggested. He demonstrated by lymphography that vulvar lymphatic flow drained predictably to the inguinofemoral basin. In the late 1970s, DiSaia et al. (1979) first attempted to apply these concepts in a treatment

strategy directed to reducing the morbidity associated with standard radical vulvectomy and inguinofemoral lymphadenectomy. In a manner similar to that of Gould in 1960, these investigators designated the 8 to 10 anatomically situated superficial inguinal lymph nodes as the *sentinel nodes* of the vulva. They reasoned that if these nodes were histologically negative then the femoral nodes would be negative and one could forego deep inguinal dissection resulting in, among others, reduced wound breakdown. Unlike Cabanas (1977), there was no attempt to identify a solitary node directly draining the primary tumor. Several other groups have investigated the sentinel node concept proposed by DiSaia with mixed results. While Berman et al. (1989) reported no groin relapses in a group of 50 early-stage vulvar cancer patients undergoing superficial inguinal lymphadenectomy. Stehman et al. (1992) documented groin recurrences in 7.3% of the 121 patients with negative superficial inguinal nodes. This compared with a recurrence rate of less than 1% following formal inguinofemoral lymphadenectomy with negative nodes in a group of more than 300 patients participating in a Gynecologic Oncology Group (GOG) protocol (Homesley et al. 1986). On the basis of the GOG results, most gynecologic oncologists have abandoned superficial inguinal lymphadenectomy as it was initially purported. It is noteworthy, though, that despite even this manner of limited groin dissection, wound complications and chronic lymphedema were observed in 29% and 19%, respectively, highlighting the true "carrot" of selective node evaluation, if validated. The first report to utilize blue dye to identify a single sentinel node in vulvar carcinoma appeared in 1994 by Levenback et al. (1994). This group, following the growing experience of similar mapping techniques in malignant melanoma, identified sentinel nodes in 7 of 9 patients and in 7 of 12 groins. These authors concluded that the technique was feasible. Subsequent reports have vastly expanded and largely confirmed this experience. Table 18.2 presents the available data from clinical trials evaluating one, either, or both node-localizing techniques (blue dye, lymphoscintigraphy) in patients with operable vulvar carcinoma (Figure 18.13). Due to a well-recognized learning curve and technique failures early in a surgeon's experience, the table includes only those published reports that have >20 patients. Although the individual experiences are small compared to the melanoma and breast literature, interest is expanding and has attracted an international investigative audience. The largest validation study was performed by the Gynecologic Oncology Group (GOG 173) (Levenback et al. 2012). This validation study performed sentinel lymph node biopsy followed by complete inguinofemoral lymphadenectomy in 418 women using blue dye and radiocolloid. Overall, at least one sentinel node was identified in 92.5% of patients and the overall sensitivity was 91.7%. The negative predictive value was 96.3%, and when tumor size was limited to <2 cm in size, the negative predictive value improved to 98%. Another validation study was reported by Hampl et al. (2008). This study enrolled 127 women with T1 to T3 vulvar cancers at seven centers in Germany. The investigators identified at least one sentinel node in 125 (98%) of the 127 women enrolled. Three women had negative sentinel nodes with positive metastatic disease found on complete lymphadenectomy specimens (false negative rate 7.7%). In two of these three patients, however, primary tumor size was ≥4 cm when sentinel nodes are often difficult to visualize. In addition, none of the three had combined blue dye and radiocolloid used in the mapping procedure (two had radiocolloid only, one had blue dye only). In contrast, the GROningen INternational *Study* on *Sentinel nodes* in Vulvar cancer (GROINSS-V) study was a multi-institutional observational study that performed sentinel node biopsy only then following patients with negative sentinel nodes with observation only (Van der Zee et al. 2008). In the

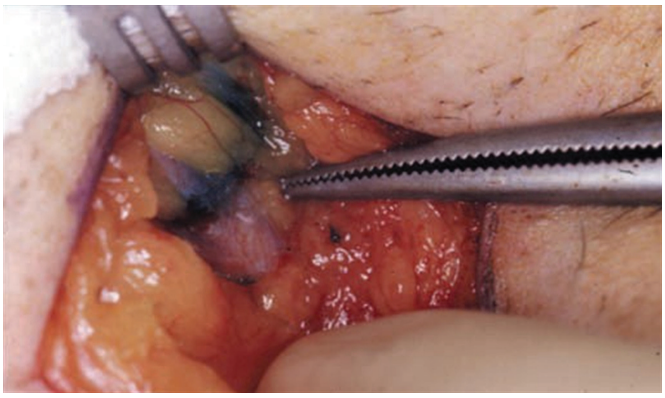

Figure 18.13 A potential evolution of vulvar lymphatic mapping is limited and selective node sampling through a biopsy incision of 3 cm or less. A blue node with radiocolloid activity is depicted in this photograph.

Table 18.2 Summary of Vulvar Sentinel Node Trials

Author	Number of Patients	Blue Dye	Tracer	Scintigraphy	ID Rate	False Negative SLN
Sideri	44	No	Yes	Yes	100%	0
Ansink	51	Yes	No	No	56%	2 (4%)
De Cicco	37	No	Yes	Yes	100%	0
De Hullu	59	Yes	Yes	Yes	100%	0
Levenback	52	Yes	No	No	88%	2 (4%)
Sliutz	26	Yes	Yes	Yes	100%	0
Moore	21	Yes	Yes	Yes	100%	0
Rob	16	Yes	No	No	69%	1 (6%)
	43	Yes	Yes	Yes	100	0
Vidal-Sicart	50	Yes	Yes	Yes	98	0
Nyberg	47	Yes	Yes	Yes	98	1 (2%)
Hampl	127	Yes	Yes	Yes	98%	3 (8%)

259 patients with unifocal disease and negative sentinel nodes, only 6 (2.3%) groin recurrences were observed. They also noted that the wound breakdown and cellulitis of the groin incisions were significantly less than in those who had undergone complete inguinofemoral lymph node dissection. Moore et al. (2008) also performed an observational study in 35 patients with vulvar cancer who underwent sentinel node biopsy only. In their cohort, four women had metastatic disease in the sentinel node. In the remaining 31 women with negative sentinel nodes, two women were noted to have groin recurrences (recurrence rate 6.4%) at a median follow-up of 29 months. Other than these three large, multi-institutional studies, the remainder of the literature's experience is from single-institution validation studies that performed the sentinel node procedure followed by complete inguinofemoral lymphadenectomy to evaluate for accuracy of mapping techniques. Levenback et al. (2001) updated their collective experience on 52 patients undergoing blue dye localization. A sentinel node was identified in 46 (88%) patients and in 57 of 76 (75%) dissected groins. Independent effects hampering sentinel node identification were prior excisional biopsy, midline tumor location, and operator experience. A median of one sentinel node was identified in each groin. The sentinel node was not found in 2 of the 12 groins that ultimately proved to have metastatic disease. Both events occurred in the first 2 years of the study. There were no false negative identified sentinel nodes. The authors demonstrated that following a short learning curve and limiting the procedure to patients with clinically non-suspicious nodes and T1 or T2 squamous cell carcinoma lesions, virtually all patients (95%) were found with sentinel nodes. A similar study by Ansink et al. (1999) had different results. In this multicenter study involving 51 patients undergoing blue dye lymphatic mapping, sentinel nodes were detected in just 56% of the 93 groins dissected. All tumors were squamous cell histology and had clinically non-suspicious groins. Nine groins were found with metastatic disease, in six (66%) of which the sentinel node was the only metastatic node. However, in two cases, a sentinel (blue) node was found and was histologically negative, yet metastatic disease was identified in non-sentinel nodes. The low sentinel identification rate and false negative cases led these authors to conclude that the blue dye alone technique was not feasible and that combination with lymphoscintigraphy should be further studied. Feasibility concerns notwithstanding, the recommendation is of merit given the relative rarity of this tumor and the ability for lymphoscintigraphy to shorten learning curve proficiency. As seen in Table 18.2, sentinel node localization using lymphoscintigraphy alone or combined with blue dye is highly successful. De Cicco et al. (1998) studied 37 squamous T1 and T2 patients with preoperative and intraoperative lymphoscintigraphy alone. Bilateral groin dissection was performed if the primary lesion was within 2 cm of a midline structure. At least one sentinel lymph node was identified in each patient. Eight patients were identified with metastatic disease, including five (63%) patients where the sentinel node was the only positive node. All 29 cases with negative sentinel nodes had negative groin histology. If lymphoscintigraphy did not identify a sentinel node in a groin, no metastases were found at surgery. Sideri et al. (2000) updated this group's experience with 44 similarly staged and studied patients. A sentinel node was identified in each case. In 77 dissected groins, 13 cases demonstrated metastatic disease—all in sentinel nodes. In 10 cases, the sentinel node was the only positive node. These authors addressing the negative predictive value of an identified sentinel node concluded that if the technique was validated, less aggressive dissection of the groin could be entertained if the sentinel was histologically negative. De Hullu et al. (2000) studied preoperative and intraoperative lymphoscintigraphy in combination with blue dye localization. In this study of 59 patients with T1 and T2 epidermoid cancers, sentinel nodes were identified in all patients with at least one of the techniques. Bilateral groin dissection was performed if the primary lesion was within 1 cm of a midline structure. Of the 107 groin dissections performed, a sentinel node was found in 95 (89%). The literature summary of vulvar sentinel node trials authors noted that they relied primarily on the gamma probe to isolate sentinel lymph nodes, as blue sentinel nodes were observed in just 60% of cases (Table 18.2). Metastatic disease was found in 20 (34%) patients and in 27 (25%) groins. In 15 (54%) groins, the sentinel node was the only positive node. In this study, immunohistochemical ultrastaging with cytokeratin staining was additionally performed. In 102 histologically negative sentinel nodes, four (4%) were found with micrometastatic disease. The authors concluded that lymphatic mapping was feasible in this manner and that ultrastaging by step-sectioning and staining with immunohistochemical methodology may identify micrometastatic disease in some cases. A similar experience was reported by Moore et al. (2003) in 21 clinically node-negative stage I to IV vulvar cancer patients. Using a combined technique, all nine patients with metastatic disease were identified by lymphoscintigraphy compared to just three of nine patients with blue dye alone. However, in 2 of 31 dissected groins the sentinel node was described as blue only, not containing radiocolloid; similarly, just 29 of 89 (33%) sentinel nodes retained characteristics of both tracers. The importance of using both radiocolloid and blue dye was best shown by Rob et al. (2007). In their prospective study, the first 16 patients underwent mapping with blue dye only with a sentinel node identification rate of only 69% and a false negative rate of 6% (1 one 16 patients). In the remaining 43 patients, the investigators used both blue dye and radiocolloid, and sentinel nodes were identified in 100% of cases with no false negatives. Although some of the improvement may be attributed to surgeon experience with the techniques, we believe the combined technique significantly improves sentinel node detection. It is not known which tumoral features impact the uptake of these individual components, thus making it prudent to use both. Overall, false negative rates among series using radiotracers in combination with blue dye have been very low but may reflect the single institution experience of skilled surgeons.

Future Directions

Lymphatic mapping and sentinel node identification appear at this point to be clinically enticing for patients with vulvar carcinoma. Prior to universal adoption, surgeons need to familiarize themselves with the techniques, as there exists a significant learning curve to performing lymphatic mapping and sentinel node detection consistently. We recommend "practicing" these techniques on 5 to 10 patients with lymphatic mapping and identification of sentinel nodes followed by complete

lymphadenectomy to assure no false negative results. The reproducibility of the above clinical experience in the multi-institutional setting is currently underway and if validated, patients will have new options based on triage programs that could offer them improved precision of their disease status and reduced morbidity.

Cervical Cancer

Cervical cancer is an excellent target for the lymphatic mapping strategy. First, most patients undergoing primary surgical treatment will not have metastatic disease. Second, the cervix is a midline structure with numerous potential drainage basins, although, as demonstrated by Leveuf and Godard (1923), the preferred sites are generally at the obturator and external iliac locales. Third, the cervix is easily visible and accessible for injection both prior to and during surgery. Finally, since fertility-sparing and minimally invasive options are now being described in highly selected, low-risk patients, developing a strategy to easily identify the patients in these groups with lymphatic metastases would be of benefit.

Clinical Experience and Data Review

In 2008, the AGO Study Group published the results from their multicenter prospective trial evaluating the sensitivity and specificity of sentinel node biopsy in women with cervical cancer. They enrolled 590 women in this study who underwent lymphatic mapping with blue dye, radiocolloid, or both, and sentinel node biopsy followed by complete pelvic and, if indicated, para-aortic lymphadenectomies. For all patients in the study, at least one sentinel node was detected in 89% of cases, but when combination blue dye and radiocolloid were used, the detection rate rose to 94%. Overall the sensitivity was disappointing at only 77% (Altgassen et al. 2008). However, when subgroup analysis limited analysis to women with tumors ≤2 cm in size, the sensitivity was 91%. The AGO Study Group reported a negative predictive value of 94% but again saw a significantly improved NPV when limiting the analysis to tumors ≤2 cm in size (99%). Other authors have also reported higher sentinel node detection rate in tumors ≤2 cm as compared to larger lesions (Darlin et al. 2010). Limited, single institution clinical trials (summarized in Table 18.3, studies with >20 patients only) exploring the sentinel node concept in cervical cancer have typically reported more promising results than the AGO Study.

The SENTICOL study, another large multisite study in Europe, enrolled 139 patients with early stage cervical cancer who underwent lymphatic mapping with blue dye and radiocolloid followed by complete pelvic lymphadenectomy (Lécuru et al. 2011). Using this combined technique, they had a detection rate of 98% for at least one sentinel node. Overall, they found a sensitivity of 92%; however, one patient with a reported false negative sentinel node actually had a positive pathologic node in a hemipelvis that did not map (i.e., a sentinel node was found in the contralateral hemipelvis but no sentinel node was identified in the hemipelvis with metastatic disease). Current mapping algorithms require complete lymphadenectomy in any nodal basin that does not map. If this false negative is removed, the sensitivity increases to 95.8%. The negative predictive value in the SENTICOL study was 98%.

In the largest retrospective study validating the sentinel node concept in cervical cancer, Salvo et al. found a sensitivity of 96.4% and a negative predictive value of 99.3% in 188 patients who underwent sentinel lymph node biopsy followed by complete bilateral pelvic lymphadenectomy (Salvo et al. 2017). A recent meta-analysis by Tax et al. similarly found a sensitivity of 94%. In addition, when they evaluated those patients with tumors <4 cm in size and no evidence of metastatic disease and who had bilateral sentinel nodes detected, the negative predictive value was 99.92%.

Blue Dye

Echt et al. (1999), from the Moffitt Cancer Center, were first to report an experience in attempting sentinel node identification among cervical cancer patients. In this 1999 series, 13 patients underwent peritumoral injection with Lymphazurin 1% blue dye followed by laparotomy. In 12 of 13 patients, radical hysterectomy was completed; one was aborted following identification of a metastatic para-aortic node (Table 18.3). Collectively, just two (15%) patients were found with blue sentinel nodes. In these two cases, the sentinel nodes were found to contain metastatic disease along with positive undyed, non-sentinel nodes.

Table 18.3 Literature Summary of Cervical Sentinel Node Trials

Author	No of Cases	Dye	Tracer	Lymphoscintigraphy	Success	False Negative
Echt	33	Yes	No	No	15%	0
O'Boyle	20	Yes	No	No	60%	0
Dargent	23	Yes	No	No	86%	0
Levenback	39	Yes	Yes	Yes	1 (3%)[a]	
Rob	65	Yes	Yes	Yes	77%	0
Malur	50	Yes	Yes	Yes[b]	78	
Buist	25	Yes	Yes	Yes	88%	1 (4%)[a]
Bats	71	Yes	Yes	Yes	91%	2 (3%)
Kara	32	Yes	Yes	Yes	100%	0
Fader	38	Yes	Yes	Yes	92%	1 (3%)
Ogawa	82	No	Yes	Yes	88%	0

[a] False negative cases in these trials were parametrial nodes identified within the radical hysterectomy specimens.

[b] Lymphoscintigraphy in first 18 patients only.

The patient with metastatic para-aortic disease (a solitary node) and the remaining 10 patients did not have an identifiable sentinel node. It is not known if the quantity of dye used (2 mL in this series) or the timing for laparotomy contributed to the low rate of identification. The authors concluded that modification of their technique would be required for future study to accurately assess the concept. In a similar report, Medl et al. (2000) reported on three stage IB to IIA patients they identified with metastatic nodal disease using blue dye alone. These patients underwent laparotomy following dye injection, which was delivered into the lateral vaginal fornices, rather than cervical stroma. Although the authors voice support for the adaptation of this technology, it is not stated what the total number of patients being studied was or if there were any false negative determinations. Technical and clinicopathologic features influencing sentinel node mapping success were detailed in a pilot project from O'Boyle et al. (2000). This group, injecting 5 mL of 1% Lymphazurin dye intrastromally, reported sentinel node identification in 12 of 20 (60%) patients undergoing laparotomy for early-stage cervical cancer (stage IB1–IIA). Tumor size (>4 cm) and prior conization were features associated with lack of sentinel node localization. The authors commented that temporal sequence of injection and laparotomy might be important, given the rapidity with which blue dye is cleared from nodal tissues in the vascular pelvic basin. While the interiliac and external iliac nodal chains were the common location of the 23 sentinel nodes identified, four nodes were found in the common iliac basin and four were identified in parametrial tissues. Microscopic nodal metastases were found in four (20%) patients, three of whom had disease in identified sentinel nodes. A fourth patient did not have an identifiable sentinel node. In addition, two of these four patients had bilateral nodal metastases, both of whom had only unilateral sentinel nodes (positive) found. Nonetheless, if patients were identified with a sentinel node, its histopathology reflected the nodal basin in each case. Dargent et al. (2000) argued that this technology would be most important for patients undergoing minimally invasive procedures since its validation would limit the nodal dissection necessary and pave the way for total vaginal resection or even fertility-sparing procedures such as radical trachelectomy. In their report, 35 patients underwent laparoscopic mapping procedures and lymphadenectomy. Defining "success" as identifying a sentinel node on each pelvic sidewall, the authors reported that location (fornices vs. stroma) and volume of dye (4 mL vs. less) were significant factors of a successful study. Overall, they identified sentinel nodes in 59 of 69 (86%) lymphatic dissections (pelvic sidewalls). Of these instances, 51 were associated with a single dyed node. Interestingly, blue dyed nodes were identified a median 52 minutes following injection with a range of 20 to 150 minutes. It is tempting to speculate that intra-abdominal pressure during laparoscopic procedures may reduce the rapid clearance of dye seen in laparotomy studies. Metastatic disease was seen in 11 nodes from six patients—all sentinels. No studies without false negative results have been reported, although one patient had a metastatic node in a basin without a sentinel node identified. Details of sentinel node location in this study confirmed the importance of the lateral lymphatic trunks in cervical drainage. The interiliac, obturator, and external iliac basins (so-called "Leveuf et Godard" area) were the location of 53 sentinel nodes. Rob and colleagues presented their experience of patent blue dye lymphatic mapping in 65 patients undergoing laparoscopy ($n = 12$) and laparotomy ($n = 53$) for early cervical cancer. Unique in this trial was the inclusion of 20 patients undergoing radical hysterectomy following neoadjuvant chemotherapy. Table 18.4 details the findings from this report. Three patients in the laparoscopy cohort were found with metastatic disease, all within identified nodes sent for intraoperative frozen section. There were no false negative studies. The authors concluded that the technique was feasible in smaller tumors by both laparoscopy and laparotomy but limited in patients with larger tumors following neoadjuvant chemotherapy. They further emphasized the importance of timing the dye infusion to follow port placement or laparotomy incision.

Table 18.4 Treatment Cohorts

Cohort	N	Technique	Stage	Detection %
A	12	Laparoscopy	IA2:2 IB1:10	11/12 (92)
B_1	13	Laparotomy	IB_1 (<2 cm)	11/13 (85)
B_2	20	Laparotomy	IB_1 (2–4 cm)	16/20 (80)
B_3	20	NACT/Laparotomy	IB_2	12/20 (60)

Abbreviation: NACT, neoadjuvant chemotherapy.
Source: Adapted from Rob L, Charvat M, Robova H, et al., *Ceska Gynekol* 69:273–7, 2004.

Radiocolloid

In an attempt to bolster the success of finding a sentinel node and to reduce the learning curve for these procedures, many investigators have turned to or added lymphoscintigraphy to their mapping technique. Verheijen et al. (2000) reported their experience with radiocolloid mapping in 10 women with cervical cancer. Focal uptake ("hot") was seen in 6 of 10 patients. Blue dye injection was also used in this study, showing localization in four patients and all within nodes previously identified as hot. A total of 18 sentinel nodes were detected at laparotomy, including the one patient with metastatic disease. Nodal localization was preferentially in the external and interiliac chains but sentinel nodes in the common iliac basin were seen in three cases. Bilateral sentinel nodes were seen in four cases. Lantzsch et al. (2001) detailed their experience of sentinel node identification in 14 stage IB patients using preoperative and intraoperative lymphoscintigraphy alone. This group performed intraoperative localization with a hand-held gamma probe and then completed radical hysterectomy and pelvic lymph node dissection. Focal uptake of filtered radiocolloid was seen in 13 (93%) patients and it identified 26 sentinel nodes (Table 18.4). Five patients were found with bilateral sentinel nodes and eight patients had one or more unilateral sentinels retrieved. One patient was found with histologically positive sentinel nodes. There were no false negative studies. A larger, multi-institutional experience was published by Levenback et al. (2002), in which the combined technique was studied at laparotomy. In this series, 39 patients underwent either preoperative ($n = 23$) or perioperative ($n = 16$) radiocolloid cervical stromal injection. Localized uptake was seen in 33 patients from the lymphoscintigrams. All patients had at least one sentinel node identified and bilateral sentinel nodes were found in 37 of 39 patients. In contrast to other reports, sentinel nodes in this trial retained either or both characteristics of blue and hot. Table 18.5 demonstrates

Table 18.5 Relationship of Dye and Radioactivity in 132 Sentinel Nodes

	Radioactivity		
Dye	**Hot**	**Not Hot**	**Total**
Blue	65	32	100
Not blue	32	0	32
Total	97	35	132

Source: Adapted from Levenback C, Coleman RL, Burke TW, et al. 2002. *J Clin Oncol* **20**:688–93.

Table 18.6 Characteristics and Probability Estimates for 50 Patients Undergoing Lymphatic Mapping

Variable	Blue Dye	Radiocolloid	Combined	Overall
Number of patients	9	21	20	50
Detection rate %	56	76	90	78
Sensitivity %	50	0	100	83
Specificity %	100	100	100	100
Positive predictive value %	100	0	100	100
Negative predictive value %	75	100	100	97
Accuracy %	80	100	100	97
False negative %	50	0	0	17

Source: Malur S, Krause N, Kohler C, et al. 2001. *Gynecol Oncol* **80**:254–7.

the relationship seen in this trial. Further, size and preoperative cervical conization did not negatively affect identification of a sentinel node. Metastatic disease was found in 25 nodes from eight patients. In seven of these patients at least one positive sentinel node was retrieved and in five, the only positive node was the sentinel node. In one patient with negative bilateral sentinel nodes a positive parametrial node was identified in the hysterectomy specimen. The relatively high radioactivity observed near the cervix following injection limits precise localization of nodes in the parametrium (unless blue). The clinical relevance of these nodes to survival has been recently called into question (Winter et al. 2002). Although most investigators agree that the combination of patent blue dyes and radiocolloid significantly improves intraoperative sentinel node detection rate, the necessity of preoperative lymphoscintigraphy is likely unnecessary. Frumovitz et al. (2006) reviewed the correlation of preoperative lymphoscintigraphy and intraoperative detection of sentinel nodes and found that the additional preoperative imaging did little to improve intraoperative identification. In fact, there was very poor concordance between the lymphoscintigraphy and the intraoperative findings, while the imaging added to patient cost, time, and discomfort. Fotiou et al. (2010) reported similar findings when they reviewed their experience of preoperative and intraoperative identification of sentinel lymph nodes in women with cervical cancer. Combined technique and laparoscopy as illustrated by Dargent et al. (2000), laparoscopic sentinel node mapping may provide the greatest measure of benefit for patients with early-stage disease. There has been limited experience reported utilizing the intraoperative gamma probe but the early reports would support its feasibility and importance in sentinel node localization. Kamprath et al. (2000) presented data on 18 patients undergoing laparoscopic lymphadenectomy following preoperative radiocolloid injection. Laparoscopic radical hysterectomy was performed in 15 patients and radical trachelectomy in three patients. Since no blue dye was used in this trial, resected nodes were secondarily scanned ex vivo for activity. "Hot" nodes were labeled sentinel and were found in 16 of 18 (89%) patients. Interestingly, a median 2.1 pelvic sentinel nodes were found, with a median 1.4 para-aortic sentinel nodes found among five patients. Their two nondiagnostic studies included the first two patients given one-fifth and one-half of the radiocolloid dose, respectively. One patient was found with metastatic disease. This patient had one sentinel and three non-sentinel positive nodes. Similarly, Malur et al. (2001), from the same institution, later reported their experience with patent blue dye alone ($n = 9$), radiocolloid alone ($n = 21$), and the combination ($n = 20$) in early-stage cervical cancer patients undergoing pelvic and para-aortic lymphadenectomy via laparoscopy ($n = 45$) or laparotomy ($n = 5$). Table 18.6 outlines the success of sentinel node identification and representation by technique. Detection rate was similar between laparotomy and laparoscopy (about 78%), although six patients in this series had stage IV disease and were undergoing extirpation by pelvic exenteration. Metastatic disease was documented in 10 (20%) patients, six of whom had identifiable sentinel nodes. In all but one of these cases, the sentinel node had metastatic disease. In two, the sentinel node was the only positive node. One patient identified with blue-dyed, histologically negative sentinel nodes was found with a single, positive metastatic non-sentinel node—a false negative study. This patient was evaluated by blue dye alone, prompting the authors to recommend the combined technique for further study. In this latter cohort, 18 of 20 patients were identified with sentinel nodes; four with metastatic disease and all within sentinel nodes (Table 18.5). Barranger et al. (2003) discussed their experience with laparoscopic sentinel node mapping following the combination of patent blue dye and radiocolloid cervical injection. In this limited series of 13 patients, one to three sentinel nodes were identified in 12 patients. No patients were found with metastatic disease on routine H&E staining. However, micrometastatic lesions were found in four sentinel nodes from two patients by immunohistochemical analysis. None of these patients received adjuvant therapy. Interestingly, one patient was found with a sentinel node in the common iliac area. The authors concluded that sentinel node mapping could have a role in minimally invasive surgical procedures for patients with early-stage cervical cancer. Buist et al. (2003) reported on 25 early-stage cervical cancer patients undergoing laparoscopic sentinel node assessment as a triage technique for subsequent abdominal radical hysterectomy. If metastatic disease was detected in the sentinel node, complete lymphadenectomy was performed laparoscopically and the uterus was left in situ.

If no metastatic disease was identified, a laparoscopic pelvic lymphadenectomy was performed followed by an abdominal radical hysterectomy. One or more sentinel nodes were detected in all patients and bilateral sentinel nodes were found in 22 of 25 (88%) patients. Metastatic disease was detected in 40% of

the cohort. One patient with two negative obturator sentinel nodes was later found to have a metastatic parametrial node removed with the primary tumor. This represented the only false negative study. Two additional patients were later identified by immunohistochemistry to have micrometastatic disease. Importantly, six patients underwent only laparoscopic lymphadenectomy and ovarian transposition following sentinel node identification averting exploration for radical hysterectomy. The authors concluded the procedure was feasible, and triage in this manner could avert additional morbidity from transperitoneal exploration.

Future Development

Surgical validity of this technology requires prospective investigation in more diverse cohorts, the multi-institutional environment, and with adaptation of newer and more specific pathologic/molecular techniques of nodal evaluation. Further, validation is required for the development of prospective, randomized trials where individual treatment triage is specified on the basis of the sentinel node. Such trials are currently under development. In this regard, it would seem that patients eligible for laparoscopic dissection would be ideal candidates for this technology, as focused dissection and potentially fertility-sparing operations (such as radical trachelectomy) could be offered (Covens et al. 1999). In addition, sparing of potential antigen-recognizing lymphoid cells could be critical to the successful adaptation of vaccine therapies. The importance of such strategies on the prevention of viral infection has been documented in a randomized double-blind multicenter controlled clinical trial of a HPV-L1 VLP on healthy volunteers (Koutsky et al. 2002). At a median of 17.9 months' follow-up the rate of persistent HPV infection was 3.9/100 woman-years in the control group compared to 0/100 woman-years in those receiving vaccine ($p < 0.001$). All cases of HPV-16-related dysplasia occurred in the placebo cohort. Overall, however, more information of the clinical relationship between the primary tumor and its lymphatic basin is required to gain a deeper understanding of tumor biology and unravel the mysteries of clinical behavior.

Uterine Cancer

Endometrial cancer is a difficult target for the mapping strategy. The primary tumor cannot be seen, imaged, or palpated with standard clinical tools. However, endometrial cancer is an attractive disease site for lymphatic mapping given the complexity of the lymphatic drainage of the uterus. Sentinel nodes could theoretically be found anywhere from the obturator space to the renal vessels (Figure 18.14). In lymphatic mapping studies, Echt et al. (1999) described their attempts at sentinel node identification in patients with endometrial cancer. Patent V blue dye was injected into the uterine fundus at a depth of approximately half the thickness of the myometrium. The authors could not identify any sentinel nodes in eight patients. Burke et al. (1996) described intraoperative injection of isosulfan blue into the subserosal myometrium into three midline sites at the fundus, 2 cm anterior and 2 cm posterior to this site. These sites were chosen to mimic a fundal endometrial cancer. Dye uptake was seen in the lymphatic channels and lymph nodes within 10 minutes (Figure 18.15). Blue-stained nodes were identified

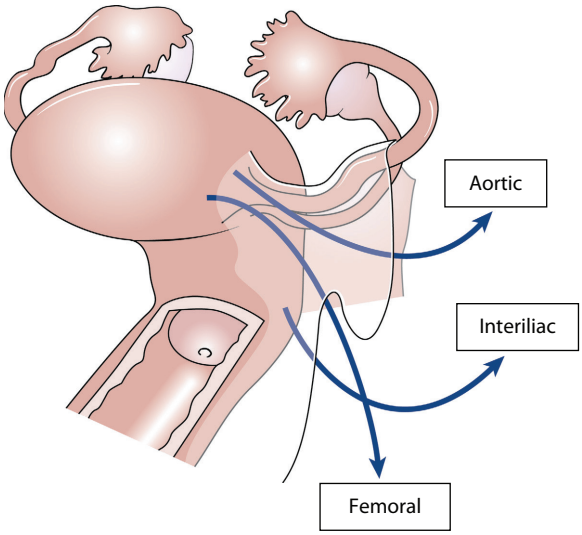

Figure 18.14 Lymphatics from the uterus may follow the vessels leading to the pelvic nodes or through the gonadal vessels to the para-aortic nodes. Rarely, they may follow the round ligament draining in the inguinofemoral basin.

and the location recorded, and the nodes were sent to pathology as separate specimens. A selective pelvic and para-aortic lymphadenectomy was then performed. Blue dye was deposited in lymph nodes in 10 of 15 patients and blue nodes were found in the pelvic and para-aortic areas. No stained nodes were found between the bifurcation of the aorta and the origin of the inferior mesenteric artery. This confirms the observations of many anatomists that the lymphatic drainage of the uterus follows two paths, along the uterine vessels to the pelvis and the gonadal vessels to the para-aortics at the level of the renal vessels. Four patients had positive lymph nodes; two in sentinel nodes. One patient with bulky nodes had no dye uptake and



Figure 18.15 Blue dye in the uterine corpus, injected at the time of laparotomy, is seen traversing the gonadal lymphatics into the low para-aortic region (seen transperitoneally). Although lymphatic mapping in this fashion may not accurately reflect the primary tumor's specific drainage, one can appreciate the vast intrauterine lymphatic anastamotic network.

one patient had a micrometastases to an unstained node in the obturator space. A follow-up study of fundal injection of radionucleotide and patent blue dye by the same group enrolled an additional 18 women. In this second cohort of women, sentinel nodes were identified in only eight (45%) patients (Frumovitz et al. 2007). Furthermore, seven (88%) of the eight women with a sentinel node identified had only unilateral drainage noted. As the uterus is a midline organ with presumably bilateral drainage, the absence of sentinel nodes on both sides of the pelvis is seemingly troublesome and a potential problem with the technique. Holub et al. (2001) described a laparoscopic-assisted technique for lymphatic mapping in patients with endometrial cancer. In this series, eight patients underwent intraoperative injection of blue dye using the same locations as described by Burke et al. using a 5-mm laparoscopic puncture needle. Blue nodes were found in the obturator, internal iliac, and common iliac sites in 11 lymph nodes among five patients. Holub et al. expanded on their experience and reported two techniques for lymphatic mapping in endometrial cancer in 2002. In this study, 13 patients underwent subserosal injection as described in the first report and 12 patients underwent subserosal and cervical injections. The combined injection technique increased the rate of observation of blue-stained lymph nodes from 61.5% in the first group to 83.3% in the current report. The authors suggest that the combined approach is superior.

Other authors have focused on the cervical injections only for sentinel node detection in women with uterine cancer, and cervical injection has emerged as the preferred method at most centers. There are many potential advantages of this approach. First, many investigators are comfortable with this technique, having used it in their patients with primary cervical cancer. Second, the cervix is readily accessible preoperatively for injection of radiocolloid in the nuclear medicine suite. This allows for preoperative imaging of sentinel nodes and better surgical planning. Pandit-Taskar et al. (2010) reported on 40 patients with endometrial cancer who underwent SPECT-CT after cervical injection of technecium-99. In their cohort, a sentinel node was identified preoperatively 100% of the time. This allowed for precise anatomic localization of sentinel nodes, helping the surgeon detect them intraoperatively. The major disadvantage to this technique is that it essentially ignores the fundal route of drainage of the primary lesion. In the Pandit-Taskar report described above, none of the 40 patients had lymphatic drainage outside the pelvis (i.e., to the aortacaval region). Pelosi et al. (2002) was the first to describe this approach using a combination of radioactive tracer and blue dye in 11 patients with early endometrial cancer during laparoscopic-assisted vaginal hysterectomy and bilateral salpingo-oophorectomy. The tracer and blue dye were injected into the cervix. Three sentinel nodes were identified that proved to be positive for micrometastases. Similarly, Gargiulo et al. (2003) reported on 11 patients with stage IB to IIA endometrial cancer who underwent preoperative cervical injection of radiocolloid and intraoperative cervical injection of blue dye prior to planned laparoscopic-assisted vaginal hysterectomy, bilateral salpingo-oophorectomy, and pelvic and para-aortic lymphadenectomy. Seventeen sentinel lymph nodes were identified, predominantly in the external iliac area—three with micrometastases. No para-aortic nodes were identified. More recently, larger series have been published. Bats et al. (2008a,b) performed cervical injection of both blue dye and radiocolloid in 43 patients with clinical stage I uterine cancer. Sentinel nodes were identified in 30 patients (69.8%). Eight patients had metastatic disease to the pelvic nodes and all were found by lymphatic mapping (no false negatives). However, as expected, none of the 30 patients with sentinel nodes detected had drainage to nodes along the aorta or vena cava. Likewise, Ballester et al. (2008) used the cervical injection technique in 46 patients with uterine cancer and were able to detect a sentinel node in 40 of them (87%). In their 10 patients with metastatic disease to lymph nodes, there were also no false negatives with the mapping technique. In their series, only 1 of 101 sentinel nodes detected in the 40 patients was found along the aorta. The remaining 100 sentinel nodes were again limited to the pelvis. However, as disease spread to para-aortic nodes in the absence of pelvic disease is exceedingly rare (<1%), investigators argue that cervical injection will miss very few patients with metastatic disease to the nodes.

Two large prospective studies have attempted to demonstrate the cervical injection as a valid approach for women with endometrial cancer. The FIRES trial (Rossi et al. 2017) performed lymphatic mapping with ICG using the da Vinci robotic platform in 340 patients. All patients had cervical injection with ICG followed by removal of sentinel nodes and then complete pelvic lymphadenectomy. In addition, 58% had a para-aortic node dissection. In this study, 86% had at least one sentinel node identified. The overall sensitivity of the procedure was 97.2% with a negative predictive value of 99.6%. However, as 42% of patients did not have a para-aortic node dissection, it is uncertain as to whether the sensitivity was truly 97.2% or if positive disease was missed (i.e., isolated para-aortic nodes). To overcome this potential confounder in incomplete surgical staging to validate the procedure, Soliman et al. (2017) performed lymphatic mapping via a cervical injection followed by complete pelvic and para-aortic node dissection to the renal vessels in all patients enrolled. In this study, of the 101 evaluable patients, 90 (89%) had at least one sentinel node identified. The overall sensitivity was 95% and negative predictive value was 98.6%. Only one patient (<1%) had disease in isolated para-aortic nodes with no disease found in the pelvis.

In an effort to accurately map the lymphatic drainage of the tumor and not the organ, multiple investigators have attempted to inject the tumor directly using hysteroscopic visualization and injection. Most used office hysteroscopy to inject radiocolloid and/or blue dye prior to going to the operating arena for hysterectomy, salpingo-oophorectomy, and staging. This allowed for nuclear imaging prior to incision. Niikura et al. (2004) injected radiocolloid only into 28 consecutive patients with endometrial cancer. At surgery, they were able to find at least one sentinel node in 23 (82%) patients. As expected and in stark contrast to cervical injection techniques, 81% of patients had at least one sentinel node located above the bifurcation of the aorta including 14% with sentinel nodes only along the aorta (i.e., no pelvic sentinel nodes identified). Maccauro et al. (2005) used combined radiocolloid and blue dye in their hysteroscopic injection of 26 women with uterine cancer. In their study, they were able to identify at least one sentinel node in all 26 women injected. Furthermore, of the 53 sentinel lymph nodes removed surgically, 14 (26%) were found along the aorta

and/or vena cava. Both these two early studies had no false negatives in the combined 49 patients. Delaloye et al. (2007), however, did have one false negative (11%) in the nine women with positive metastatic disease in their cohort of 60 patients. In their study, hysteroscopic injection of both blue dye and radiocolloid led to a sentinel node detection rate of 82% (49 of 60 patients). One-third of patients had at least one sentinel node along the aorta/vena cava. Other authors have had more difficulty identifying sentinel nodes using the hysteroscopic technique. Perrone et al (2008) were only able to identify a sentinel node in 65% of patients who underwent hysteroscopic injection, while Robova et al. (2009) and Clement et al. (2008) were only able to identify a sentinel node in 50% and 40% of patients, respectively. In our experience, the hysteroscopic technique is quite difficult, with good visualization of the entire uterine lesion often impossible. In addition, bleeding at the first puncture sight and leakage of blue dye into the uterine cavity during hysteroscopic injection obscures much of the field. Also, the endometrium is rich in blood supply and much of the radiocolloid and blue dye may be taken up into the vasculature as opposed to the lymphatics. Overall, however, the use of this technique is an improvement over techniques that rely on injection into the uterine fundus or cervix without visualization of the actual tumor, as it more likely approximates the lymphatic drainage of the tumor as opposed to the uterus. In addition, this technique provides a preoperative lymphoscintigram that can help plan the operative procedure. The most cephalad sentinel node can be identified and perhaps a determination made about how long an incision it will take to reach it. Conversely, it requires another procedure and a 2-day sequence. And as it is most often done as an office procedure, the hysteroscopic injection can be quite uncomfortable for patients. In the only study to evaluate patient tolerance of preoperative hysteroscopic injection of mapping substances, Clement et al. (2008) reported very high pain scores (visual analog scale score 8 out of 10) for women undergoing the procedure. It remains to be seen if other groups can replicate these results.

Summary

Endometrial cancer is an excellent disease site for lymphatic mapping and sentinel node identification. Many technical challenges remain, yet most agree that cervical injection is the most feasible approach, with low likelihood for missing disease along the aorta that typically does not map with the cervical injection ("isolated" para-aortic nodes).

FUTURE DIRECTIONS OF LYMPHATIC MAPPING

Continuing work to validate the concept of lymphatic mapping in gynecologic tumors is being conducted through multi-institutional clinical trials within the international community. Departure from "standard-of-care" lymphatic resection paradigms in cancer management requires prudent and propitious decision-making through careful review of clinical outcomes in properly conducted and controlled clinical studies. Many challenges remain, not the least of which lie in the relative rarity of the diseases being studied. However, clear definition of the learning curve and establishment of an acceptable false negative rate will need to accompany equally important advances in our understanding of the tumor physiology of the regional lymphatics. While selective resection of affected tissues remains the holy grail of cancer surgery, treatment success defines the benchmark—a line which the pursuit of minimization cannot compromise. It is anticipated that better tracers and localizing agents, improved pathological processing, and standardized operative techniques will measurably add to this growing body of challenging study.

REFERENCES

Altgassen C, Hertel H, Brandstädt A, et al.; AGO Study Group. 2008. Multicenter validation study of the sentinel lymph node concept in cervical cancer: AGO Study Group. *J Clin Oncol* **26**(18):2943–51.

Ansink AC, Sie-Go DM, van der Velden J, et al. 1999. Identification of sentinel lymph nodes in vulvar carcinoma patients with the aid of a patent blue V injection: A multicenter study. *Cancer* **86**:652–6.

Ballester M, Dubernard G, Rouzier R, et al. 2008. Use of the sentinel node procedure to stage endometrial cancer. *Ann Surg Oncol* **15**:1523–9.

Barranger E, Grahek D, Cortez A, et al. 2003. Laparoscopic sentinel lymph node procedure using a combination of patent blue and radioisotope in women with cervical carcinoma. *Cancer* **97**:3003–9.

Bats AS, Clément D, Larousserie F, et al. 2008a. Does sentinel node biopsy improve the management of endometrial cancer? Data from 43 patients. *J Surg Oncol* **97**:141–5.

Bats AS, Lavoué V, Rouzier R, et al. 2008b. Limits of day-before lymphoscintigraphy to localize sentinel nodes in women with cervical cancer. *Ann Surg Oncol* **15**:2173–9.

Berman ML, Soper JT, Creasman WT, et al. 1989. Conservative surgical management of superficially invasive stage I vulvar carcinoma. *Gynecol Oncol* **35**:352–7.

Bostick PJ, Giuliano AE. 2000. Vital dyes in sentinel node localization. *Semin Nucl Med* **30**:18–24.

Buist MR, Pijpers RJ, van Lingen A, et al. 2003. Laparoscopic detection of sentinel lymph nodes followed by lymph node dissection in patients with early stage cervical cancer. *Gynecol Oncol* **90**:290–6.

Burke TW, Levenback C, Tornos C, et al. 1996. Intraabdominal lymphatic mapping to direct selective pelvic and para-aortic lymphadenectomy in women with high-risk endometrial cancer: Results of a pilot study. *Gynecol Oncol* **62**:169–73.

Cabanas RM. 1977. An approach for the treatment of penile carcinoma. *Cancer* **39**:456–66.

Clement D, Bats AS, Ghazzar-Pierquet N, et al. 2008. Sentinel lymph nodes in endometrial cancer: Is hysteroscopic injection valid? *Eur J Gynaecol Oncol* **29**:239–41.

Coleman RL, Whitten CW, O'Boyle J, et al. 1999. Unexplained decrease in measured oxygen saturation by pulse oximetry following injection of Lymphazurin 1% (isosulfan blue) during a lymphatic mapping procedure. *J Surg Oncol* **70**:126–9.

Covens A, Shaw P, Murphy J, et al. 1999. Is radical trachelectomy a safe alternative to radical hysterectomy for patients with stage IA-B carcinoma of the cervix? *Cancer* **86**:2273–9.

Dargent D, Martin X, Mathevet P. 2000. Laparoscopic assessment of the sentinel lymph node in early stage cervical cancer. *Gynecol Oncol* **79**: 411–5.

Darlin L, Persson J, Bossmar T, et al. 2010. The sentinel node concept in early cervical cancer performs well in tumors smaller than 2 cm. *Gynecol Oncol* **117**(2):266–9.

De Cicco C, Sideri M, Bartolomei M, et al. 2000. Sentinel node biopsy in early vulvar cancer. *Br J Cancer* **82**(2):295–9.

De Cicco C, Cremonesi M, Luini A, et al. 1998. Lymphoscintigraphy and radioguided biopsy of the sentinel axillary node in breast cancer. *J Nucl Med* **39**:2080–4.

de Hullu JA, Doting E, Piers DA, et al. 1998. Sentinel lymph node identification with technetium-99m-labeled nanocolloid in squamous cell cancer of the vulva. *J Nucl Med* **39**:1381–5.

de Hullu JA, Hollema H, Piers DA, et al. 2000. Sentinel lymph node procedure is highly accurate in squamous cell carcinoma of the vulva. *J Clin Oncol* **18**:2811–6.

Delaloye JF, Pampallona S, Chardonnens E, et al. 2007. Intraoperative lymphatic mapping and sentinel node biopsy using hysteroscopy in patients with endometrial cancer. *Gynecol Oncol* **106**:89–93.

DiSaia PJ, Creasman WT, Rich WM. 1979. An alternate approach to early cancer of the vulva. *Am J Obstet Gynecol* **133**:825–32.

Echt ML, Finan MA, Hoffman MS, et al. 1999. Detection of sentinel lymph nodes with lymphazurin in cervical, uterine, and vulvar malignancies. *South Med J* **92**:204–8.

Ege GN. 1976. Internal mammary lymphoscintigraphy. The rationale, technique, interpretation and clinical application: A review based on 848 cases. *Radiology* **118**:101–7.

Eshima D, Fauconnier T, Eshima L, et al. 2000. Radiopharmaceuticals for lymphoscintigraphy: Including dosimetry and radiation considerations. *Semin Nucl Med* **30**:25–32.

Eudy GE, Carlson GW, Murray DR, et al. 2003. Rapid immunohistochemistry of sentinel lymph nodes for metastatic melanoma. *Hum Pathol* **34**: 797–802.

Euscher ED, Malpica A, Atkinson EN, et al. 2008. Ultrastaging improves detection of metastases in sentinel lymph nodes of uterine cervix squamous cell carcinoma. *Am J Surg Pathol* **9**:1336–43.

Fader AN, Edwards RP, Cost M, et al. 2008. Sentinel lymph node biopsy in early-stage cervical cancer: Utility of intraoperative versus postoperative assessment. *Gynecol Oncol* **111**:13–7.

Fotiou S, Zarganis P, Vorgias G, et al. 2010. Clinical value of preoperative lymphoscintigraphy in patients with early cervical cancer considered for intraoperative lymphatic mapping. *Anticancer Res* **30**:183–8.

Frumovitz M, Bodurka DC, Broaddus RR, et al. 2007. Lymphatic mapping and sentinel node biopsy in women with high-risk endometrial cancer. *Gynecol Oncol* **104**:100–3.

Frumovitz M, Coleman RL, Gayed IW, et al. 2006. Usefulness of preoperative lymphoscintigraphy in patients who undergo radical hysterectomy and pelvic lymphadenectomy for cervical cancer. *Am J Obstet Gynecol* **194**:1186–93.

Frumovitz M, Gayed IW, Jhingran A, et al. 2008. Lymphatic mapping and sentinel lymph node detection in women with vaginal cancer. *Gynecol Oncol* **108**:478–81.

Gargiulo T, Giusti M, Bottero A, et al. 2003. Sentinel Lymph Node (SLN) laparoscopic assessment early stage in endometrial cancer. *Minerva Gynecol* **55**:259–62.

Gould EA, Philbin WT, Hyland PH, et al. 1960. Observations on a 'sentinel node' in cancer of the parotid. *Cancer* **13**:77–8.

Halsted W. 1907. The results of radical operations for the cure of carcinoma of the breast. *Ann Surg* **46**:1.

Hampl M, Hantschmann P, Michels W, et al.; German Multicenter Study Group. 2008. Validation of the accuracy of the sentinel lymph node procedure in patients with vulvar cancer: Results of a multicenter study in Germany. *Gynecol Oncol* **111**:282–8.

Henze E, Schelbert HR, Collins JD, et al. 1982. Lymphoscintigraphy with Tc-99m-labeled dextran. *J Nucl Med* **23**:923–9.

Holloway RW, Abu-Rustum NR, Backes FJ, et al. 2017. Sentinel lymph node mapping and staging in endometrial cancer: A Society of Gynecologic Oncology literature review with consensus recommendations. *Gynecol Oncol* **146**(2):405−15.

Holub Z, Jabor A, Kliment L. 2002. Comparison of two procedures for sentinel lymph node detection in patients with endometrial cancer: A pilot study. *Eur J Gynaecol Oncol* **23**:53–7.

Holub Z, Kliment L, Lukac J, et al. 2001. Laparoscopically-assisted intraoperative lymphatic mapping in endometrial cancer: Preliminary results. *Eur J Gynaecol Oncol* **22**:118–21.

Homesley HD, Bundy BN, Sedlis A, et al. 1986. Radiation therapy versus pelvic node resection for carcinoma of the vulva with positive groin nodes. *Obstet Gynecol* **68**:733–40.

International (Ludwig) Breast Cancer Study Group. 1990. Prognostic importance of occult axillary lymph node micrometastases from breast cancers. *Lancet* **335**:1565–8.

Iversen T, Aas M. 1983. Lymph drainage from the vulva. *Gynecol Oncol* **16**:179–89.

Kamprath S, Possover M, Schneider A. 2000. Laparoscopic sentinel lymph node detection in patients with cervical cancer. *Am J Obstet Gynecol* **182**:1648.

Kara PP, Ayhan A, Caner B, et al. 2008. Sentinel lymph node detection in early stage cervical cancer: A prospective study comparing preoperative lymphoscintigraphy, intraoperative gamma probe, and blue dye. *Ann Nucl Med* **22**:487–94.

Koutsky LA, Ault KA, Wheeler CM, et al. 2002. A controlled trial of a human papillomavirus type 16 vaccine. *N Engl J Med* **347**:1645–51.

Lantzsch T, Wolters M, Grimm J, et al. 2001. Sentinel node procedure in Ib cervical cancer: A preliminary series. *Br J Cancer* **85**:791–4.

Lécuru F, Mathevet P, Querleu D, et al. 2011. Bilateral negative sentinel nodes accurately predict absence of lymph node metastasis in early cervical cancer: Results of the SENTICOL study. *J Clin Oncol* **29**(13):1686−91.

Leong SP, Donegan E, Heffernon W, et al. 2000. Adverse reactions to isosulfan blue during selective sentinel lymph node dissection in melanoma. *Ann Surg Oncol* **7**:361–6.

Leveuf J, Godard H. 1923. Les lymphatiques de l'uterus. *Revue de Chirurgie* **61**:219–48.

Levenback C, Burke TW, Gershenson DM, et al. 1994. Intraoperative lymphatic mapping for vulvar cancer. *Obstet Gynecol* **84**:163–7.

Levenback C, Coleman RL, Burke TW, et al. 2001. Intraoperative lymphatic mapping and sentinel node identification with blue dye in patients with vulvar cancer. *Gynecol Oncol* **83**:276–81.

Levenback C, Coleman RL, Burke TW, et al. 2002. Lymphatic mapping and sentinel node identification in patients with cervix cancer undergoing radical hysterectomy and pelvic lymphadenectomy. *J Clin Oncol* **20**:688–93.

Levenback CF, Ali S, Coleman RL, et al. 2012. Lymphatic mapping and sentinel lymph node biopsy in women with squamous cell carcinoma of the vulva: A gynecologic oncology group study. *J Clin Oncol* **30**(31):3786−91.

Maccauro M, Lucignani G, Aliberti G, et al. 2005. Sentinel lymph node detection following the hysteroscopic peritumoural injection of 99mTc-labelled albumin nanocolloid in endometrial cancer. *Eur J Nucl Med Mol Imag* **32**:569–74.

Malur S, Krause N, Kohler C, et al. 2001. Sentinel lymph node detection in patients with cervical cancer. *Gynecol Oncol* **80**:254–7.

Medl M, Peters-Engl C, Schutz P, et al. 2000. First report of lymphatic mapping with isosulfan blue dye and sentinel node biopsy in cervical cancer. *Anticancer Res* **20**:1133–4.

Moore RG, DePasquale SE, Steinhoff MM, et al. 2003. Sentinel node identification and the ability to detect metastatic tumor to inguinal lymph nodes in squamous cell cancer of the vulva. *Gynecol Oncol* **89**:475–9.

Moore RG, Robison K, Brown AK, et al. 2008. Isolated sentinel lymph node dissection with conservative management in patients with squamous cell carcinoma of the vulva: A prospective trial. *Gynecol Oncol* **109**:65–70.

Morton DL, Wen DR, Wong JH, et al. 1992. Technical details of intraoperative lymphatic mapping for early stage melanoma. *Arch Surg* **127**:392–9.

Munakata S, Aihara T, Morino H, et al. 2003. Application of immunofluorescence for intraoperative evaluation of sentinel lymph nodes in patients with breast carcinoma. *Cancer* **98**:1562–8.

Nahrig JM, Richter T, Kuhn W, et al. 2003. Intraoperative examination of sentinel lymph nodes by ultrarapid immunohistochemistry. *Breast J* **9**: 277–81.

Niikura H, Okamura C, Utsunomiya H, et al. 2004. Sentinel lymph node detection in patients with endometrial cancer. *Gynecol Oncol* **92**:669–74.

Nyberg RH, Iivonen M, Parkkinen J, et al. 2007. Sentinel node and vulvar cancer: A series of 47 patients. *Acta Obstet Gynecol Scand* **86**:615–9.

O'Boyle JD, Coleman RL, Bernstein SG, et al. 2000. Intraoperative lymphatic mapping in cervix cancer patients undergoing radical hysterectomy: A pilot study. *Gynecol Oncol* **79**:238–43.

Ogawa S, Kobayashi H, Amada S, et al. 2010. Sentinel node detection with (99m)Tc phytate alone is satisfactory for cervical cancer patients undergoing radical hysterectomy and pelvic lymphadenectomy. *Int J Clin Oncol* **15**:52–8.

Pandit-Taskar N, Gemignani ML, Lyall A, et al. 2010. Single photon emission computed tomography SPECT-CT improves sentinel node detection and localization in cervical and uterine malignancy. *Gynecol Oncol* **117**:59–64.

Parry-Jones E (1963) Lymphatics of the vulva. *J Obstet Gynaecol Br Commonw* **70**:751–65.

Pelosi E, Arena V, Baudino B, et al. 2002. Preliminary study of sentinel node identification with 99mTc colloid and blue dye in patients with endometrial cancer. *Tumori* **88**:S9–S10.

Perrone AM, Casadio P, Formelli G, et al. 2008. Cervical and hysteroscopic injection for identification of sentinel lymph node in endometrial cancer. *Gynecol Oncol* **111**:62–7.

Plentl A, Friedman E. 1971. *Lymphatic System of the Female Genitalia.* Philadelphia: WB Saunders.

Rob L, Charvat M, Robova H, et al. 2004. Sentinel lymph node mapping in early-stage cervical cancer. *Ceska Gynekol* **69**:273–7.

Rob L, Robova H, Pluta M, et al. 2007. Further data on sentinel lymph node mapping in vulvar cancer by blue dye and radiocolloid Tc99. *Int J Gynecol Cancer* **17**:147–53.

Robova H, Charvat M, Strnad P, et al. 2009. Lymphatic mapping in endometrial cancer: Comparison of hysteroscopic and subserosal injection and the distribution of sentinel lymph nodes. *Int J Gynecol Cancer* **19**(3):391–4.

Rossi EC, Kowalski LD, Scalici J, et al. 2017. A comparison of sentinel lymph node biopsy to lymphadenectomy for endometrial cancer staging (FIRES trial): A multicentre, prospective, cohort study. *Lancet Oncol* **18**(3):384–92.

Sadiq TS, Burns WW, 3rd, Taber DJ, et al. 2001. Blue urticaria: A previously unreported adverse event associated with isosulfan blue. *Arch Surg* **136**:1433–5.

Salvo G, Ramirez PT, Levenback CF, et al. 2017. Sensitivity and negative predictive value for sentinel lymph node biopsy in women with early-stage cervical cancer. *Gynecol Oncol* **145**(1):96–101.

Sherman A, Ter-Pogossian M. 1953. Lymph node concentration of radioactive colloidal gold following interstitial injection. *Cancer* **6**:1238–40.

Sideri M, De Cicco C, Maggioni A, et al. 2000. Detection of sentinel nodes by lymphoscintigraphy and gamma probe guided surgery in vulvar neoplasia. *Tumori* **86**:359–63.

Sliutz G, Reinthaller A, Lantzsch T, et al. 2002. Lymphatic mapping of sentinel nodes in early vulvar cancer. *Gynecol Oncol* **84**:449–52.

Soliman PT, Westin SN, Dioun S, et al. 2017. A prospective validation study of sentinel lymph node mapping for high-risk endometrial cancer. *Gynecol Oncol* **146**(2):234–9.

Stehman FB, Bundy BN, Thomas G, et al. 1992. Groin dissection versus groin radiation in carcinoma of the vulva: A Gynecologic Oncology Group study. *Int J Radiat Oncol Biol Phys* **24**:389–96.

Tax C, Rovers MM, de Graaf C, Zusterzeel PL, Bekkers RL. The sentinel node procedure in early stage cervical cancer, taking the next step; a diagnostic review. *Gynecol Oncol* **139**(2015):559–67.

Uren RF, Howman-Giles R 2002. The role of nuclear medicine. In: Cody HS, ed. *Sentinel Lymph Node Biopsy*. London: Martin Dunitz, pp. 19–43.

Van der Zee AG, Oonk MH, De Hullu JA, et al. 2008. Sentinel node dissection is safe in the treatment of early-stage vulvar cancer. *J Clin Oncol* **26**:884–9.

Van Trappen PO, Gyselman VG, Lowe DG, et al. 2001. Molecular quantification and mapping of lymph-node micrometastases in cervical cancer. *Lancet* **357**:15–20.

Verheijen RH, Pijpers R, van Diest PJ, et al. 2000. Sentinel node detection in cervical cancer. *Obstet Gynecol* **96**:135–8.

Vidal-Sicart S, Puig-Tintoré LM, Lejárcegui JA, et al. (2007) Validation and application of the sentinel lymph node concept in malignant vulvar tumours. *Eur J Nucl Med Mol Imag* **34**:384–91.

Way S. 1951. Carcinoma of the vulva. *Malignant Disease of the Female Genital Tract*. Philadelphia: Blakiston.

Wilhelm AJ, Mijnhout GS, Franssen EJ. 1999. Radiopharmaceuticals in sentinel lymph-node detection—An overview. *Eur J Nucl Med* **26**:S36–S42.

Winter R, Haas J, Reich O, et al. 2002. Parametrial spread of cervical cancer in patients with negative pelvic lymph nodes. *Gynecol Oncol* **84**:252–7.

Wong JH, Cagle LA, Morton DL. 1991. Lymphatic drainage of skin to a sentinel lymph node in a feline model. *Ann Surg* **214**:637–41.

19 Ovarian tissue cryopreservation and transplantation

Giuliano Bedoschi and Kutluk Oktay

INTRODUCTION

Early detection and advanced treatment strategies in cancer have improved survival outcomes, leading to an increased interest for fertility preservation. Starting with the first description of the successful restoration of ovarian function after transplantation of previously cryopreserved ovarian cortical pieces (Oktay and Karlikaya 2000), the field of fertility preservation entered into an accelerated phase. Once the cancer community and the patients took notice of the possibility of successfully and safely preserving fertility, fertility preservation became an increasingly important part of cancer care with attention to the improvement of post survival quality of life (Ethics Committee of American Society for Reproductive Medicine 2013, American Society of Clinical Oncology, Fertility Preservation Guidelines Committee, Oktay et al. 2018).

While embryo or oocyte cryopreservation can be offered to those individuals who have sufficient time for ovarian stimulation before chemotherapy, a sufficient time period for ovarian stimulation is not available to all cancer patients. Moreover, especially in prepubertal children, ovarian stimulation is not feasible. When such limitations exist and when there is also the desire for the preservation of endocrine function, ovarian cryopreservation and transplantation stands out among the other techniques.

However, the major limitation of ovarian transplantation is the follicle loss of at least two-thirds due to the initial ischemia while revascularization occurs (Liu et al. 2002). If these losses can be prevented, the ovarian transplant procedure can become the most preferred fertility preservation procedure in many cases. For this reason, we attempted to improve the orthotopic ovarian transplantation technique with the utility of a human decellularized extracellular tissue matrix (ECTM) scaffold, robot-assisted minimally invasive surgery, and perioperative pharmacological support (see "Pelvic Orthotopic Transplantation"). In addition, our research in human ovarian xenograft models suggests that there may be pharmacological approaches to enhance neovascularization in ovarian transplants, but such pharmacological approaches are yet to be tested in clinical cases (Soleimani et al. 2011).

IMPACT OF CANCER TREATMENTS ON FEMALE FERTILITY

Modern methods of cancer treatments have a significant negative impact on ovarian endocrine and reproductive function. In women, the primordial follicles are nonrenewable and their numbers are reduced via apoptotic loss throughout the female life span until near complete depletion prompts menopause. An accelerated and premature depletion of germ cells in the ovaries caused by direct toxic insults to the primordial follicle oocyte is the main mechanism underlying gonadal damage and failure induced by radiotherapy and chemotherapy (Oktem and Oktay 2008). Specifically, gonadotoxic chemotherapy agents such as those belonging to alkylating or topoisomerase inhibitors groups induce double-strand DNA breaks and apoptotic death in human primordial follicles (Soleimani et al. 2011, Li et al. 2014). The age of the patient, the type, dose, and intensity of chemotherapy and/or radiotherapy are the main factors determining the magnitude of the ovarian damage (Green et al. 2009, Thibaud et al. 1998, Wo and Viswanathan 2009). The damage can be further compounded by the delay after cancer treatment to attempt at childbearing.

OVARIAN TISSUE CRYOPRESERVATION

Ovarian tissue cryopreservation is a more recent technique for fertility preservation. Even though it has previously been considered experimental, it is now considered as an established method in numerous countries, and this may soon be the case in the United States. The ovarian tissue harvesting for cryopreservation is typically performed by laparoscopy, except in cases where the patient needs to undergo abdominal surgery for the treatment of cancer, in which case the ovarian tissue can be harvested during the same surgical procedure.

Some advantages of this technique include the lack of a need to significantly delay cancer treatments since it does not require ovarian stimulation, and lack of a need for a partner. Ovarian cryopreservation may be offered to sexually immature girls or postpubertal females, those with urgent need to start cytotoxic treatment, as well as those who are diagnosed with estrogen-sensitive cancer and do not wish to undergo ovarian stimulation (Oktay et al. 2018). Table 19.1 summarizes the indications for ovarian tissue cryopreservation.

Ideally, ovarian tissue harvesting for the purpose of cryopreservation should be carried out before the initiation of cytotoxic treatment since each round of chemotherapy will diminish ovarian reserve in a culminating fashion (Soleimani et al. 2011). However, it may still be feasible to harvest ovarian tissue after initiation of first courses of chemotherapy, especially in younger patients with large ovarian reserve, as there does not appear to be residual damage on surviving primordial follicles (Meirow et al. 2005, Tanbo et al. 2015).

Tissue Harvesting

As long as there is no contraindication, ovarian tissue is collected via laparoscopy. Because of the ischemia encountered after ovarian transplantation, a significant loss of follicles can occur (Liu et al. 2002). As a result, in adult patients we recommend that an entire ovary is removed and cryopreserved until such time that ovarian transplantation techniques are improved. While in the pediatric age group, less than an ovary worth of ovarian tissue may provide same number of follicles from an adult ovary,

Table 19.1 Indications for Ovarian Cryopreservation

Cancer patients
Breast cancer (stage 0–3)
Cervical cancer
Non-genital rhabdomyosarcoma
Childhood cancers
Hodgkin lymphoma
Non-Hodgkin lymphoma (except Burkitt lymphoma)
Osteosarcoma
Ewing sarcoma
Wilms tumor
Bone marrow transplant patients
Aplastic anemia
Sickle cell anemia
Autoimmune and immune-deficiency diseases (e.g., rheumatoid arthritis)
Autoimmune diseases
Collagen vascular diseases (e.g., SLE)
Acute glomerulonephritis
Behcet disease
Adjunctive oopherectomy
Recurrent breast cancer
Endometriosis
Benign ovarian tumors
Recurrent cysts
Endometriosis
Prophylactic oopherectomy
BRCA-1 or -2 mutation carriers

practically, such an approach may be damaging to the remainder of the ovary. In addition, additional tissue may be useful for repeated ovarian transplant attempts since the current mean longevity of ovarian transplants is around 3 years. On average one-third to half of an ovarian tissue is thawed and transplanted back, and this may allow multiple attempts to transplant (Pacheco and Oktay 2017). Hence, in general, we support, removal of an entire ovary when there is high likelihood of damage to ovarian reserve. The ovary is removed by a laparoscopic approach using an 5-mm trocar inserted in the umbilicus and 5 and 12-mm trocars in the lower quadrants. Use of electrocautery is not recommended to minimize damage to ovarian cortex containing the follicles. The ipsilateral fallopian tube is left intact to allow a spontaneous pregnancy to occur in case an orthotopic transplantation is performed in the future. An endoscopic specimen bag is used to remove the ovary through the 12-mm trocar; the trocar is pulled out and the specimen is delivered through the 12-mm incision. In some instances, this incision may need to be widened to extract a large ovary. The same may also be accomplished with robotic assistance (Da Vinci Xi®), in which case 8-mm ports are used in addition to a 12-mm access port.

Processing of the Ovarian Tissue

The sample is transported to the laboratory on ice in a HEPES-buffered medium. The ovary is bivalved through its hilum, and the cortex is separated from the medullary portion using a number 10 blade. This step is undertaken because the primordial follicles are contained in the cortical portion, and the medullary portion may decrease tissue permeation of cryoprotectants (Newton et al. 1998). The aim of the processing of ovarian tissue before cryopreservation is to obtain ovarian pieces small and thin enough for the cryoprotectants to easily permeate, yet the sizes should be manageable for future transplantation. Accordingly, the cortex is divided into approximately 5 × 5 × 1 mm pieces using a number 10 or 11 blade. The preparation is performed under a laminar flow hood, and the tissue is kept in the medium throughout the process.

Cryopreservation

Slow freezing with a relatively long dehydration time is the current method used for cryopreservation of ovarian tissue (Gook et al. 1999, Isachenko et al. 2009a, Isacheckno et al. 2009b). In the 15 years that followed our publication of the first successful case of ovarian transplantation with frozen-thawed issue (Oktay and Karlikaya 2000), the number of livebirths and ongoing pregnancies exceed 90 and are increasing (Pacheco and Oktay 2017). Nearly all live births associated with ovarian transplantation are thus far with slow frozen tissue.

For cryopreservation, the cortical pieces are then put in cryovials containing 1.5 mL of an ovarian freeze solution. The cryovials are kept in ice for 30 minutes for the equilibration of the cryoprotectants. Cryopreservation is performed using a slow freeze protocol in a programmable freezer. The pieces are cooled to −7°C and seeded at this temperature. They are then cooled to −140°C and plunged into liquid nitrogen (Oktay 2001).

OVARIAN TISSUE TRANSPLANTATION

There are two broad approaches to ovarian transplantation: orthotopic and heterotopic. The sites for orthotopic transplantation may include retroperitoneum in the ovarian fossa area or the remaining ovary if there is one remaining. Heterotopic location may include the forearm (Oktay et al. 2001), lower abdominal subcutaneous tissue (Oktay et al. 2004), or retroperitoneal space in abdomen (Stern et al. 2013).

The first signs of ovarian function may take 2 to 6 months after transplantation, as shown by the rise of estrogen levels and decrease of gonadotropin levels as well as follicular activity. Overall, ovarian tissue transplantation is able to restore ovarian function in approximately 64% of patients submitted to the procedure (Pacheco and Oktay 2017). The lifespan of the transplanted ovarian grafts may be limited, mainly owing to massive loss of ovarian reserve during the hypoxic period after transplantation (Liu et al. 2002). A second transplantation can be performed if necessary and if there is sufficient amount of frozen-banked tissue remaining. Mean longevity of ovarian transplants is currently 26 months (Pacheco and Oktay 2017), but this may be improving with newer approaches (Oktay et al. 2015).

Risk of Cancer Cell Seeding

The risk of cancer cell transmission is a concern when implanting ovarian tissue (Meirow et al. 2008). However, the risk of reintroduction of a malignancy is low for most cancer types seen in young females, and its risks depend on the tumor type and stage, the mass of malignant cells transferred, and the time of ovarian tissue harvesting (Bastings et al. 2013). The chance of an ovarian metastasis arising from Hodgkin lymphoma or nonmetastatic breast carcinoma is negligible, whereas there may be a strong theoretical concern in leukemia patients (Kim et al. 2001). However,

Table 19.2 Risk of Metastases to Ovaries in Various Cancers

High risk
Leukemia
Neuroblastoma
Burkitt lymphoma
Genital rhabdomyosarcoma
Moderate risk
Breast cancer stage IV
Infiltrative lobular histological subtype
Adenocarcinoma/adenosquamous carcinoma of the cervix
Colon cancer
Low risk
Breast cancer stage I–III
Infiltrative ductal histological subtype
Squamous cell carcinoma of the cervix
Non-Hodgkin lymphoma
Hodgkin lymphoma
Wilms tumor
Ewing sarcoma
Non-genital rhabdomyosarcoma
Osteogenic sarcoma

the initial induction treatments for leukemia are not gonadotoxic, and by the time hematopoietic stem cell transplantation and preconditioning chemotherapy is needed, the patient is in remission and there are no circulating leukemic cells. In fact, xenograft studies are assuring that ovarian transplantation may be safe under those circumstances (Greve et al. 2012). However, when there is a significant concern about ovarian involvement, ovarian cryopreservation should not be performed for the purpose of autotransplantation. In addition to histological methods, it has been suggested that ovarian tissue screening should be performed using molecular markers to detect malignant cells prior to performing ovarian transplantation, when available (Bastings et al. 2013). Table 19.2 summarizes the risk of ovarian involvement in different cancers. For instance, risk of ovarian involvement is higher in leukemia and neuroblastoma patients, compared to lymphoma or Wilms tumor patients.

Ovarian Transplantation Techniques

Pelvic Orthotopic Transplantation

Our current transplantation utilizes a robot-assisted approach (Oktay et al. 2015), while our earlier laparoscopic approach may still be used (Oktay et al. 2001). The anesthesia induction and the thawing process starts simultaneously, both lasting for approximately 40 minutes. Thawing is done by a rapid thaw protocol in 30°C water bath, followed by washing the tissues in decreasing gradients of cryoprotectant (Oktay 2001). The ovarian pieces are then sutured to an extra-cellular matrix (ECTM) membrane (Alloderm) with 5-0 monocryl (11-mm 3/8C needle) by positioning the cortical pieces with stromal side exposed, then passing the needle through ECTM, stroma, cortex, and then back through ECTM under a microsurgical microscope. We then trim the ECTM to leave a ~5-mm tissue-free rim all around. A 4-0 Vicryl V-lock suture is then tagged to the apex of the ECTM.

Using the robot-assisted Da Vinci Xi® minimally invasive surgery technique, typically five ports are used: an 8-mm port for the camera, a 12-mm (right or left depending on the site of operation) upper quadrant for access, and three 8-mm ports for instrumentation. In patients presenting a remaining ovary, we bivalve it using curved scissors, avoiding cauterization. This exposes the medulla and creates a vascular bed for the graft as well as doubling the surface area available for transplantation. Next, we introduce the graft into the abdominal cavity through the 12-mm assist port. The graft is then juxtaposed on the ovary so that the stromal sides of the cortical pieces oppose the exposed stroma of the bivalved ovary. We then anastomose the edges of the ECTM scaffold to the edges of ovarian cortex by interrupted sutures using 4-0 Vicryl V Lock continuously. Using this technique, return of ovarian function was obtained 2–3 months after the ovarian tissue transplantation procedure in two subjects who underwent grafting. In vitro fertilization treatment cycles were performed followed by embryo cryopreservation, since both subjects had a desire to form a bank of frozen embryos and the duration of the grafts could not be predicted. Frozen embryos transfers were performed resulting in live births in both subjects (Oktay et al. 2015). Additional cases have been performed and results are pending publication since our earlier report.

In patients without a remaining ovary, we create a pocket in the ovarian fossa, posterior to the broad ligament, superior to the ureters, and inferior to iliac vessels in the supine position by using sharp and blunt dissection. The graft is then loaded into the abdominal cavity through the 12-mm assist port. The first suture is then placed in the most dependent portion of the pocket, approximately 1 cm above the ureter, and the needle is passed through the peritoneum into the pelvic cavity. By pulling on this suture, the graft is wedged in the pelvic pocket. Next, the base suture is passed through the upper edge of the peritoneal pocket. The graft is stretched and flattened against the pelvic sidewall by pulling this suture from the intraperitoneal site. With a large number of pieces, a second graft may be prepared and placed superior and caudal to the first one. Then, the peritoneum is approximated with interrupted sutures. The base of the ECTM scaffold is also included into the suture while closing the peritoneum to further secure the graft in place.

Prior to the procedures, patients receive transdermal 0.1 mg estradiol (E_2) (Climara®, Bayer Healthcare Pharmaceuticals Inc., Whippany, NJ, USA) weekly and vaginal progesterone 100 mg (Prometrium®, Schering-Plough, Kenilworth, NJ, USA) nightly with a 2-week-on/2-week-off regimen. This regimen is continued after the transplant until a sign of ovarian function is seen. Hormone replacement is given because of its beneficial effects on graft survival based on the evidence from animal studies (Morales et al. 1995). Patients are also given 81 mg of Aspirin Regimen Bayer® Low Dose (Bayer Corporation, Whippany, NJ, USA) for 7 days, which are discontinued 2 days before the surgery, as it is presumed that this treatment may enhance angiogenesis.

Heterotopic Transplantation

Heterotopic ovarian transplantation in the forearm or lower abdominal wall has been associated with reports of restoration of hormonal function, follicle development, and oocyte retrieval for in vitro fertilization (Oktay et al. 2004, Oktay et al. 2001). A recent report from an Australian group demonstrated

an ongoing pregnancy following heterotopic grafting of cryopreserved ovarian tissue in a woman after a bilateral oophorectomy (Stern et al. 2013). The advantages of this technique are being able to closely monitor the graft if there is a need, its feasibility when the pelvis has been scarred from previous radiation, or the potential to inject agents directly into the ovarian grafts to enhance graft survival (Sonmezer and Oktay 2010). It is also less invasive and can be done under local anesthesia in an office setting, and it lends itself better to repetitive procedures.

Forearm

After thawing and washing as described previously, each strip is tagged with 4-0 Vicryl as described previously (Oktay et al. 2003). The needle is cut off from the suture, and the cortical pieces are left in the medium until the surgical site is ready for transplantation. To create a pocket for the graft under the skin of the forearm, a 1-cm transverse incision is made over the brachioradialis muscle, 5 cm below the antecubital fossa. If there is a cosmetic concern, the incision and the transplantation may be made more medially. A pocket is created between the fascia and the subcutaneous tissues using blunt dissection. Since this area is relatively vascular, attention must be given to avoid major bleeding. As the ovarian tissue will acquire its blood supply from these vessels, extensive cauterization should be avoided.

Following the creation of the pocket, the free end of the suture is threaded onto a reusable needle. A half-circle cutting needle with a chord length of 25 to 38 mm (depending on the size of the strips) is inserted into the subcutaneous pocket as far as possible. It is then passed through the skin, and the cortical piece is wedged into the pocket by pulling on this suture. Care is taken to place the pieces with their cortical side facing up. The needle is removed, and the free end of the suture is held with a Mosquito clamp. The main purpose of this suture pull-through technique is to guide the tissue placement and avoid overlapping the strips, rather than securing them in place. Depending on the patient's forearm size, 5 to 15 cortical pieces can be placed beneath the forearm skin. Following the placement of the last piece, the sutures are cut. Then the skin is closed subcuticularly and a non-pressure dressing is applied in order to not reduce the blood flow to the area.

Seventy-five IU/day of follicle-stimulating hormone are injected directly in the grafts for 7 days starting the day of the surgery, as the exogenous gonadotropin could maximize follicle survival when this tissue is grafted back to the patient (Imthurn et al. 2000). The patient's forearm is splinted for 72 hours to prevent dislodgment of the graft due to muscle movement. In addition, 81 mg aspirin, and hormone replacement are started before the surgery, as in the case of orthotopic transplantation. The latter is stopped with the first sign of graft function. The ovarian function usually returns within 3 months.

Lower Abdominal Subcutaneous Tissue

In recent years, we found the lower abdominal area as a more practical site for heterotopic ovarian transplantation. In addition, in patients for whom the use of the forearms is contraindicated, lower abdominal subcutaneous tissue may be used as the transplantation site. For example, the forearm is not suitable for transplantation for breast cancer patients who have had bilateral axillary dissection, due to risk of lymphedema formation. In general and in cases as such, we prefer to implant the cortical pieces in the subcutaneous tissue of the abdominal wall (Oktay et al. 2004). The preferred location is the lower abdominal wall, above the waistline of the underwear, but depending on previous surgical scars or any other condition of the abdomen, the transplantation site may be adjusted. The technique and post-surgical follow-up are the same as for forearm transplantation. In addition, the tissues can be transplanted retroperitoneally in the lower abdomen, as recently described by an Australian group (Stern et al. 2013).

REFERENCES

Bastings L, Beerendonk CCM, Westphal JR, et al. 2013. Autotransplantation of cryopreserved ovarian tissue in cancer survivors and the risk of reintroducing malignancy: A systematic review. *Hum Reprod Update* **19**(5):483–506.

Ethics Committee of American Society for Reproductive Medicine. 2013. Fertility preservation and reproduction in patients facing gonadotoxic therapies: A committee opinion. *Fertil Steril* **100**(5):1224–31.

Gook DA, Edgar DH, Stern C. 1999. Effect of cooling rate and dehydration regimen on the histological appearance of human ovarian cortex following cryopreservation in 1, 2-propanediol. *Hum Reprod* **14**(8):2061–8.

Green DM, Sklar CA, Boice JD, Jr, et al. 2009. Ovarian failure and reproductive outcomes after childhood cancer treatment: Results from the Childhood Cancer Survivor Study. *J Clin Oncol* May **27**(14):2374–81.

Greve T, Clasen-Linde E, Andersen MT, et al. 2012. Cryopreserved ovarian cortex from patients with leukemia in complete remission contains no apparent viable malignant cells. *Blood* **120**(22):4311–6.

Imthurn B, Cox SL, Jenkin G, et al. 2000. Gonadotrophin administration can benefit ovarian tissue grafted to the body wall: Implications for human ovarian grafting. *Molec Cell Endocrinol* **163**(1–2):141–6.

Isachenko V, Isachenko E, Weiss JM. 2009a. Human ovarian tissue: Vitrification versus conventional freezing. *Hum Reprod* **24**(7):1767–8; author reply 1768–9.

Isachenko V, Lapidus I, Isachenko E, et al. 2009b. Human ovarian tissue vitrification versus conventional freezing: Morphological, endocrinological, and molecular biological evaluation. *Reproduction.* **138**(2):319–27.

Kim SS, Radford J, Harris M, et al. 2001. Ovarian tissue harvested from lymphoma patients to preserve fertility may be safe for autotransplantation. *Hum Reprod* **16**(10):2056–60.

Li F, Turan V, Lierman S, et al. 2014. Sphingosine-1-phosphate prevents chemotherapy-induced human primordial follicle death. *Hum Reprod* **29**(1):107–13.

Liu J, Van der Elst J, Van den Broecke R, et al. 2002. Early massive follicle loss and apoptosis in heterotopically grafted newborn mouse ovaries. *Hum Reprod* **17**(3):605–11.

Loren AW, Mangu PB, Beck LN, et al. 2013. Fertility preservation for patients with cancer: American Society of Clinical Oncology clinical practice guideline update. *J Clin Oncol* **31**(19):2500–10.

Meirow D, Hardan I, Dor J, et al. 2008. Searching for evidence of disease and malignant cell contamination in ovarian tissue stored from hematologic cancer patients. *Hum Reprod* **23**(5):1007–13.

Meirow D, Levron J, Eldar-Geva T, et al. 2005. Pregnancy after transplantation of cryopreserved ovarian tissue in a patient with ovarian failure after chemotherapy. *New Engl J Med* **353**(3):318–21.

Morales DE, McGowan KA, Grant DS, et al. 1995. Estrogen promotes angiogenic activity in human umbilical vein endothelial cells in vitro and in a murine model. *Circulation.* **91**(3):755–63.

Newton H, Fisher J, Arnold JR, et al. 1998. Permeation of human ovarian tissue with cryoprotective agents in preparation for cryopreservation. *Hum Reprod* **13**(2):376–80.

Oktay K. 2001. Ovarian tissue cryopreservation and transplantation: Preliminary findings and implications for cancer patients. *Hum Reprod Update* **7**(6):526–34.

Oktay K, Aydin BA, Karlikaya G. 2001. A technique for laparoscopic transplantation of frozen-banked ovarian tissue. *Fertil Steril* **75**(6):1212–6.

Oktay K, Bedoschi G, Pacheco F, et al. 2015. First pregnancies, live birth, and in vitro fertilization outcomes after transplantation of frozen-banked ovarian tissue with a human extracellular matrix scaffold using robot-assisted minimally invasive surgery. *Am J Obstet Gynecol* **214**(1):94.e1–e9.

Oktay K, Buyuk E, Veeck L, et al. 2004. Embryo development after heterotopic transplantation of cryopreserved ovarian tissue. *Lancet* **363**(9412):837–40.

Oktay K, Buyuk E, Rosenwaks Z, et al. 2003. A technique for transplantation of ovarian cortical strips to the forearm. *Fertil Steril* **80**(1):193–8.

Oktay K, Economos K, Kan M, et al. 2001. Endocrine function and oocyte retrieval after autologous transplantation of ovarian cortical strips to the forearm. *JAMA* **286**(12):1490–3.

Oktay K, Harvey BE, Magdalinski AJ, et al. 2018. Fertility preservation in patients with cancer: American Society of Clinical Oncology Clinical Practice Guideline Update. *J Clin Oncol.* doi: 10.1200/JCO.2018.78.1914. [Epub ahead of print].

Oktay K, Karlikaya G. 2000. Ovarian function after transplantation of frozen, banked autologous ovarian tissue. *New Engl J Med* **342**(25):1919.

Oktem O, Oktay K. 2008. Preservation of menstrual function in adolescent and young females. *Ann N Y Acad Sci* **1135**:237–43.

Pacheco F, Oktay K. 2017. Current success and Efficiency of autologous Ovarian Transplantation: A Meta-Analysis. *Reprod Sci* **24**(8):1111–20.

Soleimani R, Heytens E, Darzynkiewicz Z, et al. 2011. Mechanisms of chemotherapy-induced human ovarian aging: Double strand DNA breaks and microvascular compromise. *Aging* 3(**8**):782–93.

Soleimani R, Heytens E, Oktay K. 2011. Enhancement of neoangiogenesis and follicle survival by shingosine-1-phosphate in human ovarian tissue xenotransplants. *PLoS One* **6**(4):e19475.

Sonmezer M, Oktay K. 2010. Orthotopic and heterotopic ovarian tissue transplantation. *Best Pract Res Clin Obstet Gynaecol* **24**(1):113–26.

Stern CJ, Gook D, Hale LG, et al. 2013. First reported clinical pregnancy following heterotopic grafting of cryopreserved ovarian tissue in a woman after a bilateral oophorectomy. *Hum Reprod* **28**(11):2996–9.

Tanbo T, Greggains G, Storeng R, et al. 2015. Autotransplantation of cryopreserved ovarian tissue after treatment for malignant disease—The first Norwegian results. *Acta Obstet Gynecol Scand* **94**(9):937–41.

Thibaud E, Rodriguez-Macias K, Trivin C, et al. 1998. Ovarian function after bone marrow transplantation during childhood. *Bone Marrow Transpl* **21**(3):287–90.

Wo JY, Viswanathan AN. 2009. Impact of radiotherapy on fertility, pregnancy, and neonatal outcomes in female cancer patients. *International J Radiat Oncol Biol Physics* **73**(5):1304–12.

20 Uterine transplantation and lessons from transplant surgery

Giuseppe Del Priore, Benjamin P. Jones, Srdjan Saso, and J. Richard Smith

INTRODUCTION

Transplant medicine, including surgery and subsequent medical management postoperatively, has improved dramatically over its relatively short existence. There has been recent rapid progress in transplantation in gynecology, particularly in the field of ovarian and uterine transplantation. Ovarian transplantation is described in Chapter 19. These advancements have arisen due to the significant number of women who suffer from absolute uterine factor infertility (AUFI). Such women are considered "unconditionally infertile," due to either an absence of a uterus or the presence of a nonfunctioning uterus. Women with absence of a uterus may have been born without such, as in Mayor-Rokitansky-Kuster-Hauser syndrome, or may have undergone hysterectomy following cancer or excessive hemorrhage. Those with a nonfunctioning uterus may have a uterine malformation, intrauterine adhesions, severe adenomyosis, fibroids, or have suffered radiation damage. Such women have historically had the options of adoption or surrogacy, both of which are associated with moral and ethical complications in addition to legal, cultural, and religious factors that can all interrelate to restrict couples' options. The fact that surrogacy is prohibited in many areas of the world, including Italy, Germany, France, and Spain, signifies the difficulties women experience to have children and the associated heartache, pain, and confusion that it may cause. Uterine transplantation is the first treatment for AUFI that overcomes some of these dilemmas.

ETHICAL CONSIDERATIONS

Uterine transplantation needs careful ethical reflection with due respect for patient autonomy, beneficence, non-maleficence, and justice. The term *primum non nocere*, or *first, do no harm*, is rarely relevant in modern day medicine, as potential harm is possible from almost everything we do as doctors, from prescribing medicines to ultra-radical surgery. The key, in practicing as a doctor, as it is in uterine transplantation, is to provide net benefit with minimal harm. Clearly, the potential benefit from uterine transplantation will vary between individuals determined by personal circumstance, and only a fully informed, autonomous patient can decide whether the potential benefit of such treatment will outweigh the potential risk. When considering the principle of justice, consideration needs to be given to society and whether the introduction of a "quality-of-life–improving" procedure may divert scarce resources away from others potentially needing life-saving treatment. It could be argued that having a good quality of life is a prerequisite for living, so a procedure that may improve quality of life is, from a wellbeing perspective, lifesaving. It could further be debated that withholding such a procedure, if it were to become a suitable treatment for AUFI, could even contravene Human Rights Article 14, preventing people from adverse discrimination. With uterine transplantation still in its infancy, further research in the human model is essential to truly understand the possible benefits and risks, before a balanced ethical discussion can happen.

HISTORICAL CONSIDERATIONS

Research in uterine transplantation has been underway since the 1960s, although progress slowed following the advent and subsequent prioritization of assisted conception techniques, until 1997 when it came back into the limelight during research on abdominal radical trachelectomy (Chapter 12). Soon after, while the Swedish and UK research teams were undertaking preliminary research in animal studies, the first human uterine transplant attempt was made in 2000, using a live donor, resulting in failure of the graft after 99 days. Since then, research by our team has allowed better understanding of the anatomical considerations, including uterine blood supply as well as other important aspects such as the role of immunology and imaging modalities to further enhance the ability to monitor graft response following uterine transplantation. Such work resulted in successful transplantation in rabbits, pigs, and rabbits (Sieunarine et al. 2008) and also resulted in pregnancy in the rabbit model (Saso et al. 2015).

The second human uterine transplantation attempt was made in Turkey in 2011, using a deceased donor. While the transplanted graft has proved successful, unfortunately, after two early miscarriages and despite multiple further IVF attempts, the recipient has yet to bear child. Since then, the Swedish team, led by Professor Brännström, after further success in animal studies, has undertaken nine uterine transplants, using live donors, and reported great success, including the first live birth after uterine transplantation in 2014 (Brännström 2014; we would refer those interested in the surgical technique to the literature cited therein).

FUTURE CONSIDERATIONS

Our team is currently seeking ethics approval to undertake ten uterine transplants, utilizing donation from brain-stem dead, heart-beating deceased donors. A very successful international symposium on uterine transplantation was held in London on June 12, 2015, attended by many world experts, where the psychological, preoperative, postoperative, IVF, and antenatal protocols were validated. The selection criteria and clinical pathway were also established and the surgical procedure described in this chapter was verified.

LESSONS FROM TRANSPLANT SURGERY

Many lessons can be learned from various aspects of transplant surgery that can be extrapolated to a whole range of medical and surgical specialties to improve clinician knowledge and experience. Advances in our own research in uterine transplantation

has aided the development of novel surgical techniques, including the first case of a fertility-sparing procedure for the management of a recurrent adenomatoid tumor (Sieunarine et al. 2005). The patient, who presented with severe menorrhagia and dysmenorrhea, had previously undergone three transcervical resections of the tumor over a 12-month period, the last of which utilized ultrasound guidance and laparoscopic visualization of the uterus. She also failed to respond to medical treatment measures, including GnRH analog administration, and was further deemed unsuitable for vascular embolization. A Strassman procedure was subsequently performed, with successful removal of the adenomatoid tumor. This involved careful dissection of the ureters and pelvic vasculature, selective temporary ligation of uterine arteries, and hemisection of the uterus, followed by excision of the tumor. Frozen sections were undertaken to ensure clear tumor margins before the two uterine halves were sutured back together. Two and a half years on there is no evidence of recurrence. Similar techniques have been utilised in the successful management of placental site trophoblastic tumor (PSTT), described further in Chapter 25, and arteriovenous malformation, using temporary ligation of the uterine and ovarian vessels.

Another example that can be applied across a multitude of surgical specialties incorporates the exciting option of "auto-transplant" for seemingly unresectable tumors. In this procedure, a cancer patient would have an organ removed, perfused, chilled, and preserved for a short intraoperative period to allow for the optimal resection of an adjacent tumor (Figure 20.1). For instance, if a low-grade borderline ovarian cancer recurred around the celiac artery or the hepatobiliary trunk, this tumor could be removed en block and the affected vital vessels or biliary ducts reconstructed using donor or autologous vessels. This method has been successfully performed to remove large fibromatosis and desmoid tumours as well as in liver metastases.

Transplant medicine has a unique opportunity to study surgical and perioperative interventions in two systems, the donor and the recipient. Donors and their families can provide further benefit through additional investigations on the donor. For instance, from a training perspective, it is possible to provide unequalled surgical experience through the retrieval process. It is also possible to randomize donors in ways that are not possible to randomize recipients. For instance, if an intervention is hypothesized to improve perioperative outcomes, donors could be a sensible first group to experience the innovation prior to its introduction into the general surgery population.

Other lessons from transplant research can be applied to seemingly unrelated areas of medicine, such as randomized control trials on immunosuppressive therapy. For instance, organ transplant and immunosuppression therapy have been reported to significantly change a recipient's allergic reaction profile. A recipient who is allergic to certain items, such as peanuts, may no longer be allergic after receiving a transplanted organ and subsequent immunosuppressive medications. Theoretically, a child with a peanut allergy could be treated with a very short course of immunosuppressants, and then over days repeatedly exposed to the allergen. By slowly weaning the immunosuppressant regimen, the allergic patients would become tolerant as they emerge from the induced immunosuppression. This is possible given current encouraging results in solid organ transplant-induced immune tolerance.

From an anesthetic perspective, research in donors and even recipients can help guide intraoperative care. For instance, donors' renal function could be studied in recipients after randomization to liberal versus conservative IV fluid administration. The graft's renal function could be compared in different recipients, and the optimal perioperative care for preserving renal function could be determined. This has been undertaken in a randomized clinical trial by Schnuelle et al. (2009), where 264 brainstem-dead heart-beating donors were randomized to receive low-dose dopamine or placebo. Low-dose dopamine significantly reduced renal failure in recipients' grafts.

Hemorrhage is often encountered in surgical oncology, and equally, if not more so, in liver transplantation. From these patients, traditional replacement guidelines appear to be questionable. For instance, liberal fluid replacement may further dilute consumed coagulation factors. For example, in a 100-kg patient undergoing a procedure, their approximate whole blood may be estimated around 5 L. If this volume of distribution (Vd) is used to represent 100% of circulating coagulation factors, it can be obvious when a coagulopathy can be anticipated and worsened by IV fluids. In this example, a patient who had estimated blood loss of 2L (a not unreasonable amount in a pelvic exenteration procedure), the Vd would only contain about

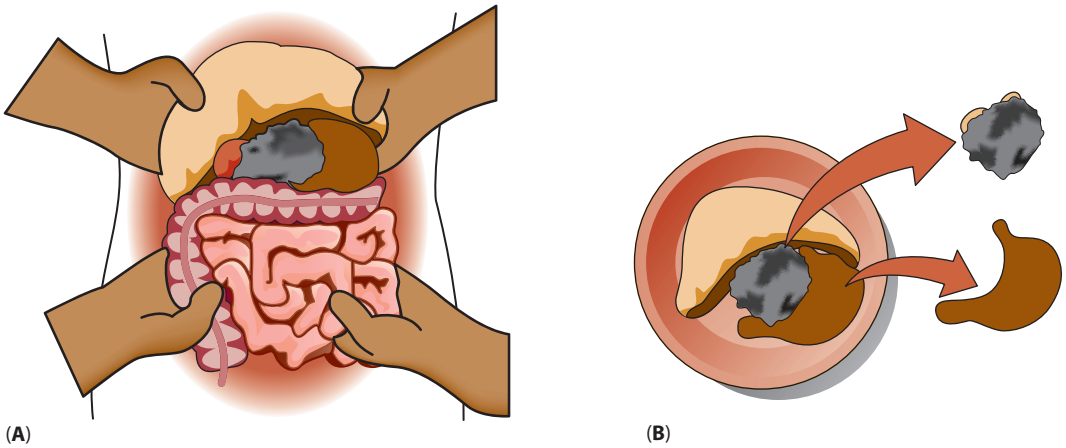

Figure 20.1 (**A**) Tumor and organs affected are removed from body. Alternatively, if the organs are removed giving access to the tumor, the tumor can be resected in vivo. (**B**) Tumor is resected from removed organs. The organs are chilled and perfused with transplant solution that minimizes warm ischemia time and tissue damage. The removed organs are re-implanted, "auto-transplanted" back into the patient.

60% of the presurgical coagulation factors (2L/5L). If this blood loss was replaced 1:1 with crystalloid, one would expect a measured reduction in existing coagulation factors approaching a dilution where a coagulopathy might be seen. However, if the replacement were greater, for example 3:1 (a ratio commonly used but based on unsubstantiated tradition), the coagulopathy would be far greater. Further, the rate of the crystalloid replacement will factor in transiently and is important as the volume.

In liver transplantation, less crystalloid and more fresh frozen plasma is replaced compared to general surgery situations (Mangus et al. 2007). Conservative crystalloid replacement has been associated with better outcomes compared with traditional replacement strategies (Fischer et al. 2010). In this latter randomized controlled trial, patients received over 2 L more fluid intraoperatively compared with standard patients. Patients receiving more crystalloids showed a trend toward more grade 3 complications, and complications related to the anastomosis (leak/fistula/abscess) were significantly higher in the excess fluid group (21.5% vs. 7.7%, $p = 0.045$). The intraoperative fluid volume was higher for all patients with anastomotic complications, regardless of randomization arm ($p < 0.042$). The authors concluded that complications were likely related to greater intraoperative fluid administration.

From a training perspective, we have previously described the educational value of participation in the organ donor network for residents and fellows in a preliminary report (Del Priore et al. 2007). The gynecologic oncology team enrolled as members of the local organ donor network for an Independent Review Board (IRB)-approved research project. We included residents and fellows as part of the organ procurement team whenever possible. We coordinated lectures and animal surgery with the organ procurement experience. Residents and fellows received lectures on surgical anatomy focused on the pelvis but included urologic, hepatobiliary, vascular, thoracic, and gastrointestinal systems. Animal labs were used to demonstrate related practical skills. During a representative 6-month period, 1800 potential donors were identified. Organ procurement surgery eventually took place in 150 of these; that is, 20 to 30 laparatomies per month. Most were multi-organ, including every possible combination of heart, lung, liver, kidney, pancreas, and intestines. Uterus procurements were performed as part of the surgery without interference with the retrieval of the other organs. Surgery teams participated in preoperative critical care of donors. Gynecologic oncology members were able to participate in approximately 10 of these surgeries based on our schedule limitations but not duty hour restrictions. Each retrieval process consisted of approximately 18 hours of surgery, although the range was 6 to 24 hours depending on the acceptability of the donor organs. Gynecologic oncology team members typically participated in 8 to 12 hours of multivisceral surgery, including cardiac and thoracic areas. Participation in an organ donor network can provide valuable surgical and critical care experience for trainees.

Transplant services are similar to gynecologic oncology services in a number of important parameters. Both provide comprehensive and coordinated surgical and medical interventions. Both specialties form lifelong relationships with critically ill patients, resulting in a demanding yet extremely rewarding training and lifestyle.

Transplant medicine has much to offer cancer patients through direct application of surgical, medical, and laboratory advances. Previous research, as described in this chapter, can be extrapolated and used to optimize the medical, anesthetic, and of course surgical management of such patients. The training needs of both surgical and gynecological trainees can also be optimized with close collaboration with their local transplant community on a variety of shared interests.

REFERENCES

Brännström, M, Johannesson, L, Bokström, H, et al. 2014. Livebirth after uterus transplantation. *Lancet* **385**:607–16

Del Priore G, Fernandez IM, Smith JR, et al. 2007. Educational value of organ retrieval network participation in an integrated comprehensive surgical training curriculum. *Gynecol Oncol* **104**(3)S:52.

Fischer M, Matsuo K, Gonen M, et al. 2010. Relationship between intraoperative fluid administration and perioperative outcome after pancreaticoduodenectomy: Results of a prospective randomized trial of acute normovolemic hemodilution compared with standard intraoperative management. *Ann Surg* **252**(6):952–8.

Mangus RS, Kinsella SB, Nobari MM, et al. 2007. Predictors of blood product use in orthotopic liver transplantation using the piggyback hepatectomy technique. *Transplant Proc* **39**(10):3207–13.

Saso S, Petts G, David AL, et al. 2015. Achieving an early pregnancy following allogeneic uterine transplantion in a rabbit model *Eur J Obstet Gynecol Reprod Biol* **185**:164–9.

Schnuelle P, Gottmann U, Hoeger S, et al. 2009. Effects of donor pretreatment with dopamine on graft function after kidney transplantation: A randomized controlled trial. *JAMA* **302**(10):1067–75.

Sieunarine K, Cowie AS, Bartlett JD, et al. 2005. A novel approach in the management of a recurrent adenomatoid tumor of the uterus utilizing a Strassman technique. *Int J Gynecol Cancer* **15**:671–5.

Sieunarine K, Doumplis D, Kuzmin E, et al. 2008. Uterine allotranspiantation in the rabbit model using a macrovascular patch technique. *Int Surg* **93**:288–94.

21 Epithelial ovarian cancer

Jane Bridges and David Oram

PREOPERATIVE ASSESSMENT

Ovarian cancer continues to be a major therapeutic challenge. Clinicians are disadvantaged by the cancer's intrinsic characteristics of unreliable, inconsistent symptomatology, accounting for late presentation and poor survival figures. Even when the patient does present early, the preoperative diagnosis of ovarian cancer is frequently a difficult one to make. This is borne out by the fact that 50% of patients with this disease are initially referred to general physicians or general surgeons for investigation of symptomatology or ascites. The development by Jacobs et al. (1990) of a scoring system, the risk of malignancy index (RMI), which incorporates the use of the serum CA125 level, pelvic ultrasound features, and the menopausal status of the patient, has greatly eased this preoperative diagnosing difficulty. The details of the calculation are shown in Figure 21.1, and the RMI has now been validated in clinical practice. Using this calculation to assess the nature of an abdominopelvic mass helps to confirm the diagnosis of malignancy with >95% accuracy. This in turn allows for an appropriate referral to a cancer center, or at least prevents the initial surgery being inappropriately performed by an inexperienced surgeon. The importance of this has been demonstrated in data from the west of Scotland, which confirm improved survival of patients with ovarian cancer if they are managed in a cancer center using a multidisciplinary team approach. Furthermore, accurate preoperative diagnosis enables appropriate counseling to be given to the patient and her family. Appropriate investigation and management planning can be embarked upon in a proactive manner, and by no means the least important consideration is that the patient's initial surgery and exploration can be performed through the correct surgical incision.

PREOPERATIVE INVESTIGATIONS

Investigations should include an assessment of the patient, including her performance and nutritional status; if necessary, parenteral feeding through central lines can be instituted preoperatively. This should not, however, delay the initial surgery. A thorough hematological and biochemical assessment should be undertaken. A chest x-ray or thoracic CT scan is required. If a pleural effusion is present, this should be aspirated and the fluid examined cytologically for malignant cells. Pelvic ultrasonography is usually performed as part of the initial assessment and is complemented by specialist imaging such as computed tomography (CT) and magnetic resonance imaging (MRI) in assessing the extent of the disease spread, including intra- and extra-abdominal metastatic deposits (Figure 21.2). Preoperatively the patient requires a bowel preparatory agent, and in selected more advanced cases stoma counseling may be instituted.

The majority of patients will undergo primary laparotomy. However, a small proportion will be deemed unlikely to achieve optimal debulking (<1 cm nodules of residual disease) and may have a radiologically-guided biopsy of the omentum or other sites of disease. If confirmed as primary ovarian cancer, the patient may have three cycles of chemotherapy followed by interval debulking surgery. Gynecological oncologists are usually very good at achieving optimal debulking in the pelvis. Results are less good in the presence of pleural and extensive diaphragmatic disease (see Chapter 22) but improvements can be made by extensive primary surgery so long as residuals of less than 1 cm in diameter can be achieved. Much work has been done to try to determine methods of predicting the patient in whom an inadequate debulking procedure (>1 cm deposits) will result. Inadequate primary debulking is currently regarded as a prognosticator of poorer outcome than interval debulking. Prognostic CA125 levels have been used in many studies but have low sensitivity and specificity. Clearly, surgical ability will also be variable and so the extent and frequency of adequate debulking will vary by center.

PRIMARY LAPAROTOMY

The correct staging of ovarian cancer is of paramount importance because it has implications for adjuvant therapy and also for appropriate counseling concerning prognosis. It is unfortunate that understaging is commonplace in this disease, in spite of attention being drawn to this problem by various authors since the 1970s (McGowan et al. 1985, Piver and Barlow 1976, Young et al. 1983). The surgical procedure should be performed through a midline incision extending from the symphysis pubis to above the umbilicus if necessary. Any ascites present on opening the peritoneal cavity should be aspirated and sent for cytological assessment; otherwise, the pelvis and paracolic gutters should be thoroughly irrigated with saline and the washings aspirated and sent for cytological assessment. Diaphragmatic swabs for cytology may also be taken. Thereafter thorough exploration and assessment of the extent of disease spread are crucial. Particular note should be taken of the tumor deposits in the upper abdomen: the hemidiaphragm should be palpated and inspected; the surface and parenchyma of the liver, the omentum, appendix, and small and large bowel should be assessed, and thereafter all peritoneal surfaces including the paracolic gutters and the pelvic peritoneum. Attention is then turned to the extent of disease in the pelvis: The pelvic and para-aortic lymph nodes should, in the first instance, be palpated. In selected cases adherent tissue and adhesions should be sampled for biopsy and if it is felt to be helpful by the operating surgeon, frozen section of suspicious areas can be utilized. Where no obvious peritoneal disease is present, random biopsies can be taken from areas at high risk. Biopsy of the subdiaphragmatic peritoneum may be facilitated by the use of long-handled punch biopsy forceps.

Depending on the stage of the disease, the surgical problems differ. In advanced disease, the stage is usually obvious and the surgical challenge centers on cytoreductive surgery. In apparent

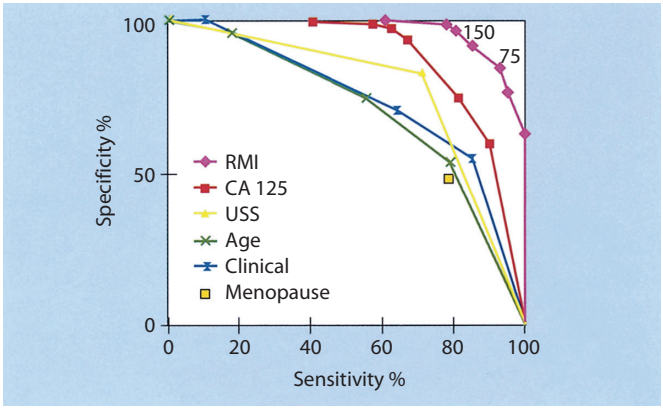

(a)

RMI = $U \times M \times$ serum CA125

where U and M are the ultrasound and menopausal scores.

Ultrasound was assessed for the following features suggestive of malignancy:

- Multiloculated cysts
- Evidence of solid areas
- Evidence of metastases
- Presence of ascites
- Bilateral lesions.

A score of 0 was given where none of these was present; 1 if one was present; and a score of 3 for two or more.

A score of 1 or 3 was given to pre- or postmenopausal patients, respectively.

An RMI of 200 had a sensitivity of 85% and a specificity of 97% for diagnosing ovarian cancer.

(b)

Figure 21.1 Risk of malignancy index (RMI).

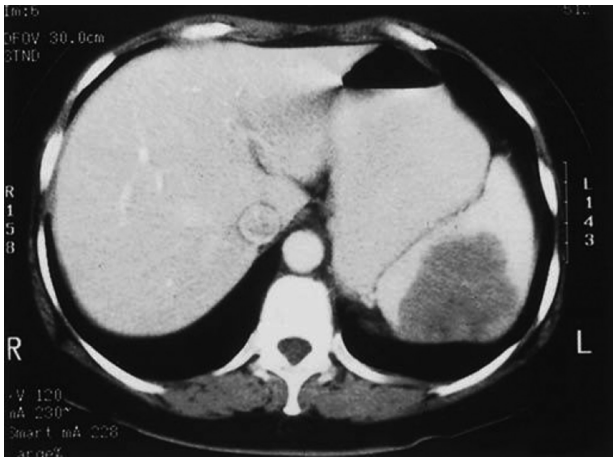

Figure 21.2 Magnetic resonance imaging (MRI) demonstrating solitary splenic metastasis.

early-stage disease, however, tumor resection is usually easy, but accurate surgical staging is a major consideration. In such cases pelvic and para-aortic lymph node assessment is indicated.

SURGICAL TECHNIQUES FOR ADVANCED DISEASE

Following the completion of the staging procedure, optimal cytoreduction becomes the goal. The surgical approach in ovarian cancer differs from that for other solid tumors where the aim is to remove the tumor with a wide area of normal tissue clearance. In epithelial ovarian cancer, the priority is to remove as much of the bulk disease as possible, but if complete tumor clearance is not achievable then reduction of the tumor burden to minimal residual disease becomes the goal. Tumor debulking was advocated initially in the early part of the twentieth century by Meigs (1934) and Berkeley and Bonney (1913) and further developed by Brunschwig (1961). Munnell in the 1950s coined the phrase "maximum surgical effort" and Griffiths quantified this in the 1970s in his seminal paper, which has dictated subsequent surgical practice (Griffiths 1975, Munnell 1952). Griffiths demonstrated an improved survival in patients who had their disease reduced to residual nodules of <1.5 cm. The surgery for advanced-stage disease is often difficult and, unlike other forms of cancer surgery, there are no set moves. It often requires persistence and a flexible approach by the operating surgeon, depending on available tissue planes. At the very least, the procedure should incorporate total or subtotal hysterectomy, bilateral salpingo-oophorectomy, omentectomy, and removal of all bulk tumor deposits where possible. In most circumstances the retroperitoneal en bloc approach as described below should be used to clear all pelvic disease. Other surgical procedures that occasionally require to be undertaken include biopsy and excision of parenchymal liver deposits. If the spleen is involved in the omental cake of tumor. a splenectomy can be undertaken. Bowel resection (Chapter 28) is only indicated in two clinical situations: The first is if there is bowel tumor causing impending obstruction, and the second is if resecting a segment of bowel will help to achieve complete tumor clearance. Prior to concluding the initial surgical procedure it is worth considering whether the patient might be suitable for intraperitoneal adjuvant chemotherapy. If so, an intraperitoneal catheter can then be inserted.

En Bloc Resection of Advanced Pelvic Disease

The technique of en bloc resection was first described by Hudson (1968) in the management of patients with advanced pelvic disease where spread to the pelvic peritoneum, rectosigmoid, and/or bladder had occurred. It facilitates resection of locally advanced tumors in one contiguous sample. First the round and infundibulopelvic ligaments are divided and ligated. The pelvic peritoneum is then opened circumferentially from the symphysis pubis anteriorly to the rectosigmoid posteriorly. The peritoneum is dissected free in a lateral-to-medial direction, including that covering the dome of the bladder and the pelvic sidewalls. The uterine arteries are then divided and ligated in a lateral position close to their origin at the internal iliac artery, allowing the ureters to be mobilized laterally (Figure 21.3). The anterior vaginal fornix is exposed by further dissection of the bladder anteriorly and opened transversely. The hysterectomy can then be performed in a retrograde fashion, dividing and ligating the uterosacral and cardinal ligaments. Development of the retrorectal space at this stage will allow elevation of the rectum, uterus, and tumor from the sacral hollow, and an assessment of the need for rectosigmoid resection—depending on the tumor mobility and invasion—can be made (Figure 21.4). Where superficial invasion of the sigmoid serosa only has occurred, the tumor may be dissected free by stripping the outer muscular layer from the underlying circular muscular layer and the mucosa. In patients with a small area of deep invasion, local

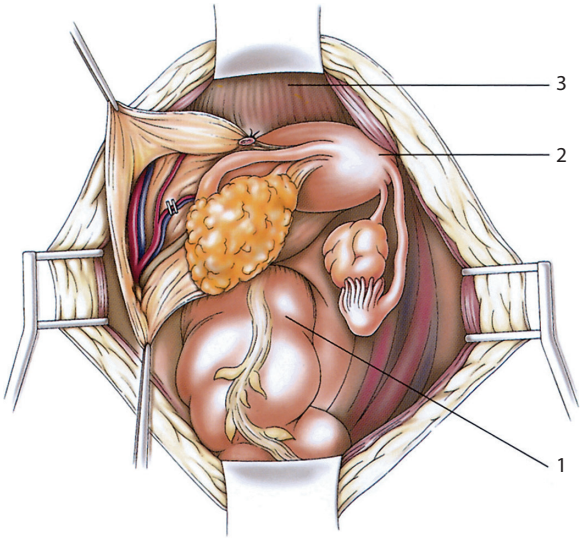

Figure 21.3 Extraperitoneal dissection. 1: Rectum; 2: uterus; 3: bladder.

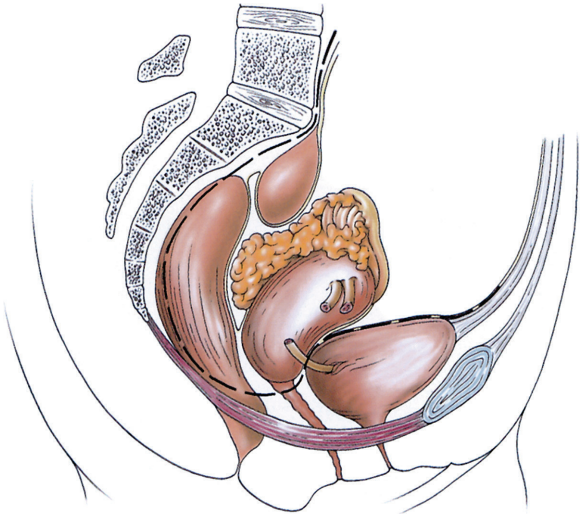

Figure 21.5 Resection outline.

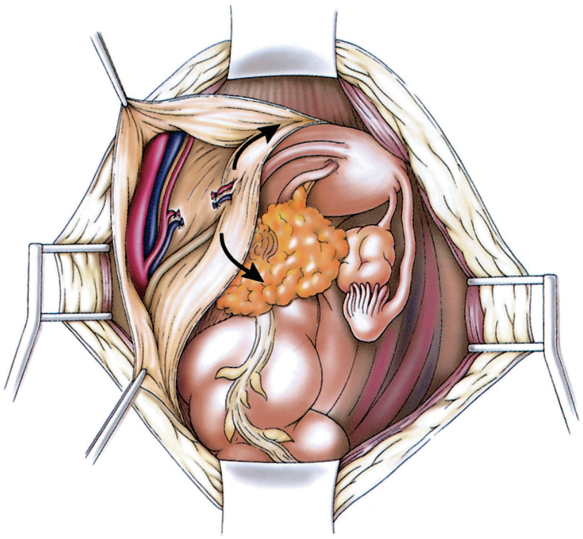

Figure 21.4 Development of the retrorectal space.

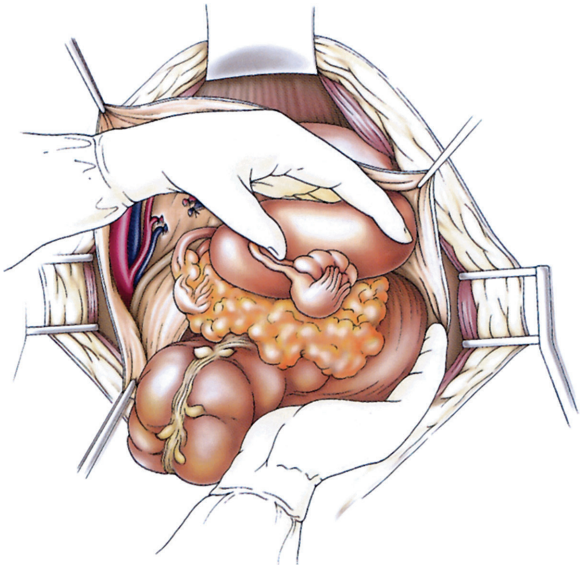

Figure 21.6 Resection.

resection of the anterior wall of the sigmoid may be performed and the bowel defect closed in the anterior plane. Resection will include the lateral pelvic and sigmoid peritoneum within the specimen (Figures 21.5 and 21.6). Where there is more extensive rectosigmoid involvement, resection of this segment of the colon can be performed with a primary anastomosis. Initially the superior hemorrhoidal vessels are identified and ligated at the level of the sacral promontory. The sigmoid mesentery is then divided allowing margins for adequate tumor clearance, facilitated by division of the peritoneum and mobilization of the descending colon if necessary. The sigmoid is then divided, generally with a stapling device, and the proximal end of the sigmoid is placed in the left paracolic gutter while the final dissection of the tumor specimen is performed. Blunt dissection and traction on the distal rectosigmoid portion are used to mobilize the bowel, allowing the specimen to be drawn out of the pelvis and the resection margin of the rectum to be identified. At this stage the posterior anastomosis of the sigmoid to the rectal stump may be performed prior to the final division of the tumor en bloc specimen just above the anastomosis. The anastomosis can then be completed by hand or by a stapling device inserted through the anus. The anastomosis may be covered by a loop colostomy, but as the majority of women will not have received preoperative radiotherapy and will have had adequate bowel preparation, this may not always be necessary. Adequate drainage at the site of the anastomosis should be allowed at the end of the laparotomy, however, in the form of a large-bore tube drain.

The laparotomy should be completed with an omentectomy, with or without appendectomy and assessment of the paraaortic nodes. If these are bulky they should ideally be removed as part of the optimal debulk. If normal in size there is dispute as whether to leave or remove them.

Appendectomy

The appendix is a common site for metastatic disease but should only be removed when clearly involved by tumor (Fawzi et al.

1997) or in the case of mucinous ovarian tumors. The appendix can be easily delivered through the midline incision. The mesoappendix is divided either following a single transfix suture if it is minimal, or by serial clipping section by section (Figure 21.7). A clip is then used to crush the base of the appendix, first close to the cecal wall and then immediately above it (Figure 21.8). A polyglactin tie is used to ligate the crushed area, and the suture ends are cut short. A purse-string suture is next inserted approximately 1 cm from the appendix, picking up only the seromuscular coat. The appendix is divided close to the clamp (Figure 21.9), the stump is invaginated, and the purse-string suture tied (Figure 21.10).

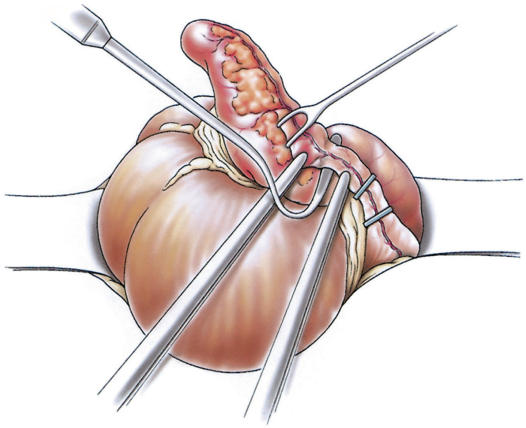

Figure 21.7 The mesoappendix is clipped.

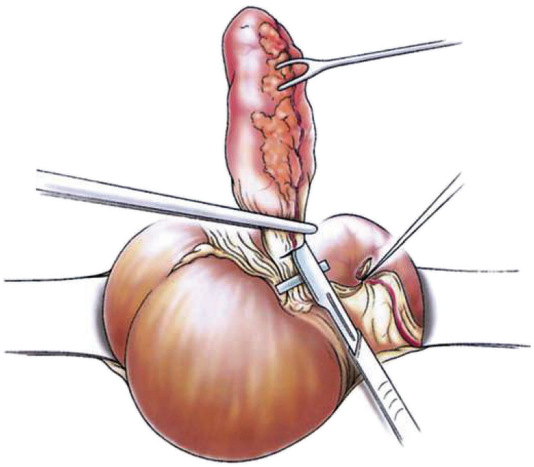

Figure 21.8 The base of the appendix is crushed.

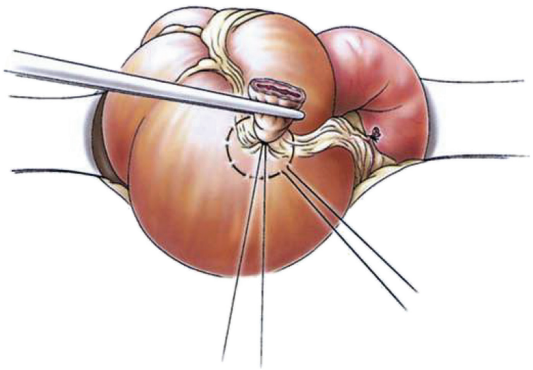

Figure 21.9 The appendix is divided.

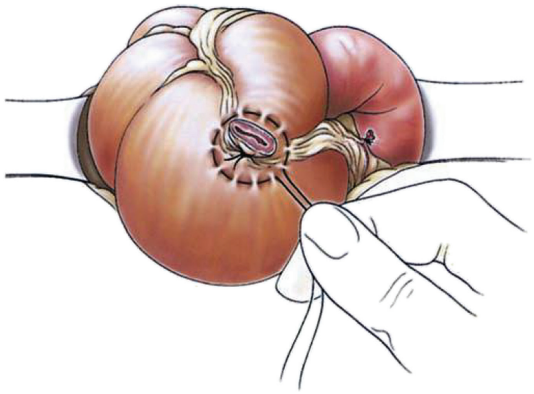

Figure 21.10 Purse-string suture.

Splenectomy

Splenectomy is rarely necessary or indicated. However, at the time of surgical staging, disease spread to the spleen may be apparent as an extension of the omental plaque or as implants of more focal disease on the capsule and/or hilum. Occasionally it may appear as an isolated site of recurrence.

First the spleen should be mobilized to allow exposure and division of its ligamentous attachments. Traction in an inferior and medial direction will expose the filamentous attachments to the diaphragm (splenophrenic) and colon (splenocolic), and these may then be divided and ligated. Entry into the lesser sac then allows exposure of the pancreas and the gastrosplenic ligament, which contains the short gastric arteries (Figure 21.11). Division of the short gastric vessels leaves only the splenorenal ligament intact, containing the splenic vessels and the tail of the pancreas. Holding the splenic hilum between the fingers, the operator identifies and protects the tail of the pancreas while the peritoneum over the ligament is taken and the splenic artery identified and divided (Figure 21.12). Finally the large splenic vein is identified, ligated, and divided, and the spleen is delivered. Occasionally the tail of the pancreas is sacrificed and requires sutures in two layers to prevent leakage. A drain is mandatory.

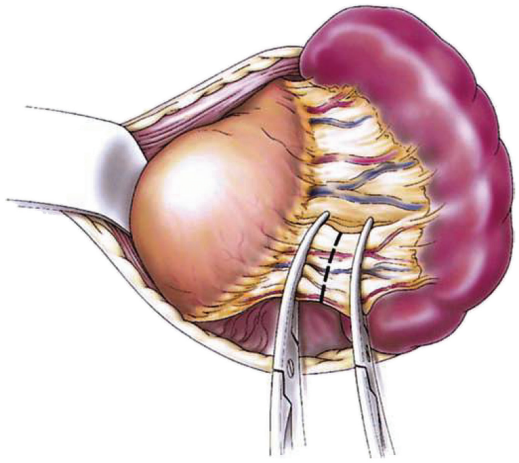

Figure 21.11 Exposure of the pancreas and gastrosplenic ligament.

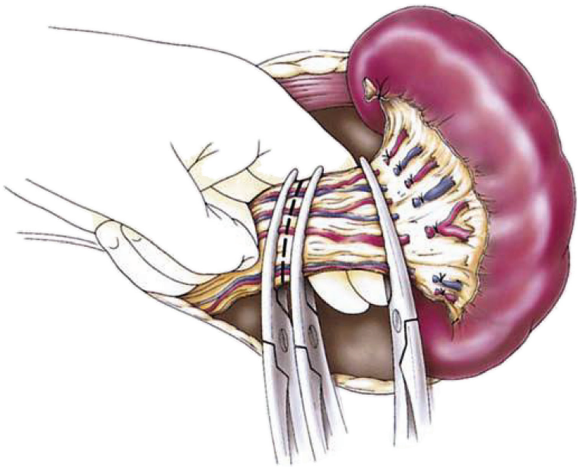

Figure 21.12 Division of the splenic artery.

Omentectomy

The omentum is frequently the site of massive metastatic deposits of disease and may cause the presenting symptoms at the time of diagnosis. An omental "cake," as it is commonly referred to, may be found at the junction of the greater omentum and the transverse colon. Although initial assessment may give the appearance of gross involvement of the transverse colon, this is usually not the case, and the tumor mass can be carefully mobilized and resected without the need for a transverse colectomy. Care should be taken to assess whether the omentum is adherent to the anterior abdominal wall peritoneum, as this peritoneal layer can be stripped in continuity with the omentum if necessary.

Initially the omentum should be elevated to expose the transverse colon. The posterior leaf of the omentum is then divided, beginning to the left of the hepatic flexure. Gradual mobilization

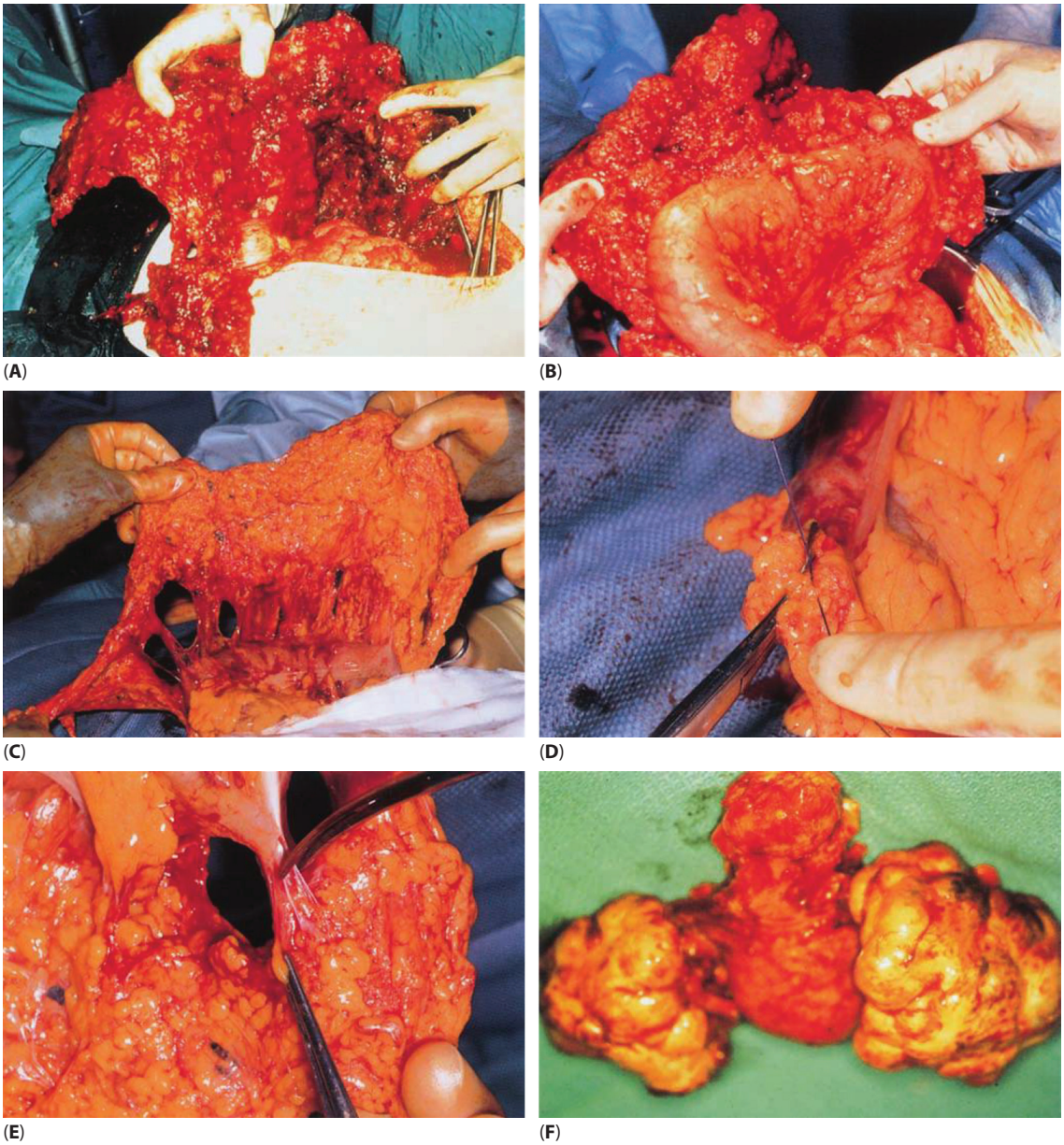

Figure 21.13 Omentectomy: (**A**) delivery of omentum with gross disease; (**B**) division of posterior leaf; (**C**) dissection of omentum; (**D**) ligature of vessels; (**E**) removal of omentum from bowel; and (**F**) bilateral primary tumor.

of this layer allows the transverse colon to be rolled in a caudal direction to expose the gastrocolic ligament. Care must be taken to avoid damage to the spleen when dissecting free the left lateral section of the omentum at the level of the splenic flexure. The vessels in the gastrocolic ligament can then be ligated with a series of clips (Figure 21.13).

Excision of Liver Nodules

Attempts at resection of large-volume disease are sometimes appropriate as part of the tumor reductive surgical process if optimal debulking may be achieved. The deposits may be shelled out digitally after incising the liver capsule. Alternatively, they may be aspirated using a Cavitron ultrasonic aspirator (Cavitron Corporation, USA). Following resection, hemostasis may be achieved using diathermy with a rollerball handpiece (Figure 21.14).

SURGERY FOR APPARENT EARLY-STAGE DISEASE

At the time of initial laparotomy a proportion of women will have apparent early-stage disease. It is imperative that a meticulous surgical staging procedure is performed to allow counseling regarding prognosis, the place of adjuvant therapy, and where appropriate, fertility options. In women who have completed their family, a total or subtotal abdominal hysterectomy, bilateral salpingo-oophorectomy, together with omentectomy, para-aortic node sampling, and peritoneal biopsies should be performed. More conservative surgery should only be considered in women desiring to maintain fertility options with stage IA disease and well-differentiated or borderline tumors; in these cases, the uterus may be conserved and a simple oophorectomy with inspection and biopsy of the contralateral ovary are performed (Figure 21.15). The remainder of the staging laparotomy should then be undertaken. Full counseling about risks, completion surgery after childbirth, and the concept of cryopreservation of ova, embryos, or ovarian tissue should be undertaken.

INTERVAL DEBULKING SURGERY

The concept of interval debulking has been assessed in two centers. Initially a Birmingham (UK) study failed to demonstrate a survival benefit (Lawton et al. 1990), but a later European Organisation for Research and Treatment of Cancer (EORTC) study, despite its critics, has suggested that interval debulking of tumor following three courses of initial chemotherapy did confer survival benefits of the order of 6 months if the patient underwent resection of visible disease (van der Burg et al. 1995). Further validation of this work is in progress, but it remains perhaps the first convincing evidence that interval surgery does have a significant role in management.

SECOND-LOOK SURGERY

Second-look procedures, either laparoscopy or laparotomy following the completion of chemotherapy, in order to test tumor response and establish the need for secondary debulking procedures, have not proved to be helpful in treatment decisions, nor in terms of patient benefit and improved survival. It is now broadly agreed that these should be only undertaken as part of defined research protocols.

PALLIATIVE SURGERY

Palliative procedures often have an important part to play in the management of the pre-terminal stages of this disease and are usually concerned with relieving the effects of intestinal obstruction. The most common of these procedures is the bypass of obstructive loops of small bowel, in which circumstance an ileocolic bypass anastomosis is to be favored over heroic attempts at mass resection (see Chapter 28).

The use of such palliative surgery can provide a great degree of symptomatic relief for patients with bowel obstruction, but it is to be stressed that fine judgment needs to be exercised to ensure that the patient will benefit in her final weeks from such a surgical approach rather than merely have her discomfort increased by the pain of a laparotomy.

GERM CELL AND STROMAL TUMORS OF THE OVARY

Germ cell and stromal tumors occur predominantly in younger women and adolescents. Preoperative diagnosis of these tumors may be facilitated by the use of tumor markers, and conservative surgery should be considered in all cases where fertility preservation is desired. Unilateral adnexectomy with biopsy of the contralateral ovary is sufficient as the pelvic surgical component in the majority of young women since the advent of successful adjuvant chemotherapy (Gershenson 1988).

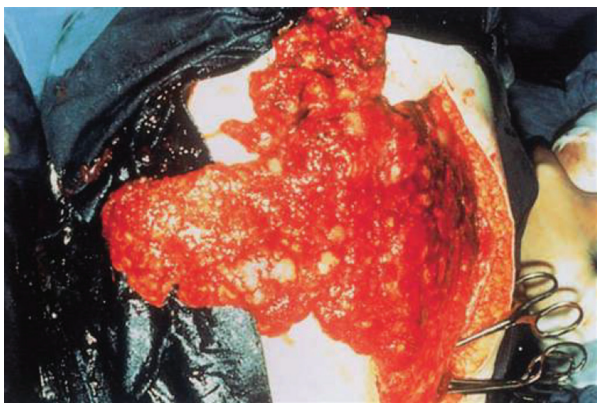

Figure 21.14 Excision of liver nodules.

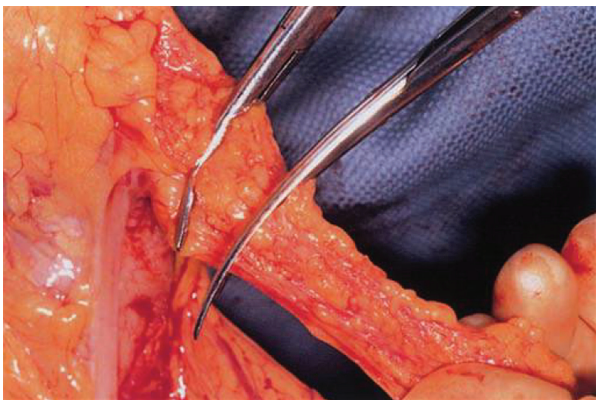

Figure 21.15 Oophorectomy.

REFERENCES

Berkeley C and Bonney V. 1913. A text-book of gynaecological surgery. In: Choice CC, editor. *A System of Surgery*. Vol. 2. New York: Funk & Wagnalls.

Brunschwig A. 1961. Attempted palliation by radical surgery for pelvic and abdominal carcinomatosis primary in the ovaries. *Cancer* **14**:384–8.

Fawzi HW, Robertshaw JK, Bolger BS, et al. 1997. Role of appendicectomy in the surgical management of ovarian cancer. *Eur J Gynaec Oncol* **18**:34–5.

Gershenson DM. 1988. Menstrual and reproductive function after treatment with combination chemotherapy for malignant ovarian germ cell tumours. *J Clin Oncol* **6**:270–5.

Griffiths CT. 1975. Surgical resection of tumour bulk in the primary treatment of ovarian carcinoma. Symposium on ovarian cancer. *Nat Cancer Inst Monog* **42**:101–4.

Hudson CN. 1968. A radical operation for fixed ovarian tumours. *J Obstet Gynaecol Br Commonw* **75**:1155–60.

Jacobs I, Oram D, Fairbanks J, et al. 1990. A risk of malignancy index incorporating CA125, ultrasound and menopausal status for the accurate preoperative diagnosis of ovarian cancer. *Br J Obstet Gynecol* **97**:922–9.

Lawton F, Luesley D, Redman C, et al. 1990. Feasibility and outcome of complete tumor resection in patients with advanced ovarian cancer. *J Surg Oncol* **45**:14–9.

McGowan L, Lesher LP, Norris HJ, et al. 1985. Misstaging of ovarian cancer. *Obstet Gynec* **65**:568–72.

Meigs JV. 1934. *Tumours of the Female Pelvic Organs*. New York: Macmillan.

Munnell EW. 1952. Ovarian carcinoma. Predisposing factors, diagnosis and management. *Cancer* **5**:1128–33.

Piver MS, Barlow JJ. 1976. Preoperative and intraoperative evaluation in ovarian malignancy. *Obstet Gynec* **48**:312–15.

van der Burg ME, van Lent M, Buyse M, et al. 1995. The effect of debulking surgery after induction chemotherapy on the prognosis in advanced epithelial ovarian cancer. *N Engl J Med* **332**:629–34.

Young RC, Decker DG, Wharton JT, et al. 1983. Staging laparotomy in early ovarian cancer. *JAMA* **250**:3072–6.

22 Upper abdominal cytoreduction for advanced ovarian cancers

Scott M. Eisenkop, Christina L. Kushnir, and Nick M. Spirtos

INTRODUCTION

Cytoreduction of all visible disease for patients with advanced stage epithelial ovarian cancer before adjuvant chemotherapy is associated with maximum survival and is well documented to increase 5-year and even 10-year survival when compared to patients left with visible disease measuring 5 mm to 1 cm, and even more so, those left with residual disease measuring more than 1 cm. Those patients in this last group benefit little from surgery, except for palliative relief of specific symptoms. However, until recently there was controversy about the relative influences of tumor biology and surgical effort on survival, and there may still remain some controversy. In a series from 1990 to 2002 we used a ranking system of 0–3 to prospectively quantify the extent of disease involved in anatomic sections of the abdomen and compare ranks at each section and sum of ranks with completeness of cytoreduction on survival to reflect biologic aggressiveness versus completeness of surgery. Survival was independently (stepwise Cox model) influenced by the sum of rankings ($p = 0.05$), but far more by completeness of cytoreduction ($p = 0.001$), indicating that a visibly disease-free outcome has a more significant influence on survival than the extent of disease before surgery (Bacalbasa et al. 2015c, Benedetti et al. 2015, Chang et al. 2015, Eisenkop et al. 2003). Shih et al. (2010) define optimal cytoreductive surgery as <1 cm of residual disease, but to include maximal surgical effort and no gross residual disease. Maximal surgical effort includes low anterior resection, diaphragm resection, liver resection, and thoracoscopy. Maximal surgical effort applies to both primary and recurrent ovarian cancer patients. In their review of the literature, patients with no gross residual disease had the longest survival compared with residual disease <1 cm, and residual disease >1 cm. In a series from 1994 to 1998, Aletti et al. (2006) analyzed whether survival was influenced by need for specific operations to accomplish optimal cytoreduction for 194 patients with stage IIIC epithelial ovarian cancer before chemotherapy. Optimal cytoreduction was accomplished for 67.5% of the patients, and no specific procedure impacted survival. In a series from 1998 to 2003, Eisenhauer et al. (2006) defined optimal as <1 cm of residual disease and stratified 262 stage IIIC/IV epithelial ovarian cancer patients based on the extent of upper abdominal surgery (group 1) such as diaphragm resection, liver resection, porta hepatis, spleen ± distal pancreas, standard surgery (group 2) which included TAH/BS0, omentectomy, bowel resection, etc., and suboptimal surgeries (group 3). The median survival was not reached for group 1 by 68 months, was 84 months for group 2, and 38 months for group 3, indicating patients requiring maximal upper abdominal cytoreduction benefited significantly.

As it is much more difficult to define the benefit to the patient of maximal effort cytoreduction when more than one centimeter of disease is left behind, it is incumbent upon the surgeon to identify disease that is unresectable as early in the procedure as possible, as this determination should result in the termination of surgery, saving the patient unnecessary morbidity and possible mortality. Undertaking surgical procedures while leaving residual disease of more than 1 cm should only be done to relieve specific symptoms such as bowel obstruction. It is only in this context that such a maximal surgical effort should be pursued.

As virtually all pelvic disease is resectable if the surgeon is willing to approach the disease from a retroperitoneal approach and remove the disease en bloc, exploration of the upper abdomen, and under specific settings the thoracic cavity, is most critical in determining if there is unresectable disease. Additionally, removing the upper abdominal disease often provides exposure, opens retroperitoneal spaces which facilitates access to structures that must be dissected during the pelvic phase of surgery, and prevents ongoing production of ascites, etc., all of which makes the pelvic resection more feasible and timely. Hence a midline incision extending from the symphysis pubis to the xyphoid process is used for exposure. Upon entering the peritoneal cavity, exploration should be done immediately to identify the extent of disease. Once this is accomplished, a complete supra- and infracolic omentectomy should be performed by transecting the short gastric vessels across the greater curvature of the stomach. This can be accomplished with traditional clamps and ties; alternatively, the LDS stapling device, endo-GIA stapling devices with vascular loads (30-mm staples), or various bipolar energy devices may be used to decrease anesthesia time. The advantage of removing the omentum first in this fashion is that its removal decreases fluid losses, provides exposure to the remainder of the upper abdomen, and, importantly, allows for exploration of the lesser sac and the pancreas, both to remove small amounts of metastatic disease and identify a primary pancreatic lesion if present. If a primary pancreatic cancer is identified, no further debulking efforts are indicated and surgery should be aborted. Primary pancreatic lesions are distinct in that the disease typically either encases and replaces the pancreas or there is a solitary intraparenchymal lesion. In contrast, metastatic disease from an ovarian, tubal, or primary peritoneal cancer is typically confluent with the tail and splenic hilum. In order to facilitate complete resection of the omentum, and recognizing that 15% to 20% of patients will require splenectomy to achieve optimal cytoreduction, the left colon and splenic flexure should be mobilized. This is best accomplished by incising the left parietal peritoneum from the pelvic brim to the splenic flexure where the phrenicolic ligament can be transected. Hydro-dissection in this plane can be used to facilitate the elevation of the parietal peritoneum and descending colon anterior to the left kidney. The distal pancreas and spleen can

easily be elevated into the operative field, permitting en-bloc resection of the omentum, spleen, and distal pancreas if necessary. Distal pancreatectomy can be performed safely as part of a maximal cytoreductive effort, and is associated with improved survival in advanced ovarian cancer (Bacalbasa et al. 2015a).

SPLEEN

As maximal surgical efforts have increased to remove all evidence of disease, splenectomy has played a central role in complete cytoreductive surgery. McCann et al. (2011) evaluated how splenectomy as part of the initial cytoreductive effort affected patient postoperative course and survival. Forty-four patients had splenectomy as part of their primary cytoreductive surgery. Thirty-four of 44 (84%) were optimally cytoreduced. Splenectomy was performed in 82% of the patients for optimal cytoreduction. The median overall survival for patients optimally cytoreduced with and without splenectomy was 30 and 45 months ($p < 0.045$), respectively. McCann concluded that splenectomy was safe and feasible, but survival was shortened secondary to depressed immune function. Pant et al. (2010) reviewed patients with advanced ovarian cancer undergoing optimal cytoreduction including splenectomy, and their ability to subsequently tolerate IP chemotherapy. Forty-one patients were eligible for the study, whom either underwent primary or secondary optimal cytoreductive surgery. Thirteen of 41 underwent splenectomy, and 69% of patients who had a splenectomy were able to complete six cycles of intra peritoneal (IP) chemotherapy. Seventy-one percent of patients who did not undergo splenectomy were able to complete six cycles of IP chemotherapy ($p = 0.33$). The median progression free survival (PFS) for patients who underwent splenectomy was 9 months versus 16 months for patients who did not ($p = 0.14$). The authors concluded that there is no difference in progression-free survival between the two groups, and those patients who have a splenectomy are able to tolerate IP chemotherapy as well as those who did not have a splenectomy.

Hanprasertpong et al. (2010) analyzed six patients who underwent splenectomy during secondary cytoreductive surgery for epithelial ovarian cancer. Of the six, three patients had a splenectomy as part of their interval debulking surgery and the other three had a splenectomy during secondary cytoreductive surgery. In these six patients, the splenectomies were well tolerated. No serious morbidity or mortality was incurred. One patient did have a transient elevation in platelet count. Bacalbasa et al. (2015b) retrospectively reviewed the impact of survival of splenectomy as part of cytoreductive surgery in recurrent ovarian cancer. A total of 28 patients were identified: 21 in the secondary setting, 6 in the tertiary setting, and 1 in the quaternary setting. It was concluded that splenectomy as part of a secondary debulking can be performed safely, and contributes to maximal survival benefit.

By mobilizing the splenic flexure and mobilizing the mesocolon and descending colon medially, the renal vein at the point the ovarian vein drains into it can be easily identified and the lymph nodes in this area can be fully accessed. To access the lymph nodes involving the celiac plexus, all one must do at this point is to transect the lieno-splenic and gastrosplenic ligaments and sweep both the spleen and the pancreas over the midline providing excellent access to this area. By starting the dissection in this manner, not only is the omentum and possibly the spleen easily removed but two areas that might harbor unresectable disease (the para renal and celiac lymph nodes) can be evaluated and if so determined, minimize the need of further debulking. In the event that the spleen must be removed, any remaining attachments of gastrocolic ligament and stomach should be transected with bipolar instruments and the splenic vessels palpated. The amount of exposure as well as adjacent adipose tissue, inflammation, and proximity to the pancreas determines whether the vessels are clamped, cut, and tied or whether they are transected with an endoscopic-GIA and then clipped as well. In the event that confluent disease involves the pancreatic tail adjacent to the spleen, the already mobilized pancreas is further mobilized with bipolar cautery and/or the endo-GIA and then stapled across using a GIA stapler with white vascular loads. The superior aspect of the pancreas is inspected under magnification, and if a duct is seen it is clipped with a small hemoclip, after which the pancreas is reinforced with continuous 2-0 Prolene. Postoperatively, patients who undergo distal pancreatectomy are treated with intravenous Sandostatin (50 μg IVPB q8h d#1, 75 μg IVPB d#2-3, 100 μg IVBP d#4-10, taper d#11-12) with total parental nutrition.

DIAPHRAGM

Assuming this portion of the procedure is completed and virtually all disease is determined to be resected, diaphragmatic disease should be evaluated and removed. In almost all cases the disease involving the diaphragm can be surgically removed or ablated with the argon beam coagulator if the disease is small volume and not scattered. Cliby et al. (2004) reviewed 41 patients at the Mayo Clinic who underwent diaphragm resection (DR) to achieve optimal cytoreductive surgery in ovarian carcinoma. The majority of diaphragmatic resection (DR) occurred in patients undergoing surgery for recurrent disease (35/41; 85%), and in 13 of these 35 patients, there had been at least one prior recurrence. Lesions were predominately right-sided (80%), but bilateral resection was necessary in two (5%) patients. Pathologic evaluation of resected areas revealed 35 cases (85%) were full-thickness disease. Pleural surface was involved in a minority of cases (10/35). Forty of forty-one women underwent additional procedures for debulking, including splenectomy, liver resection, small bowel resection, and intra-abdominal tumor debulking. At the conclusion of the operations, 33 of 41 (80.1%) had no gross residual disease, 4 of 41 (9.8%) had less than 1 cm of residual disease, 1 of 41 (2.4%) had residual disease of 1 to 2 cm, and 3 of 41 (7.3%) patients had greater than 2 cm of residual disease. Overall, DR allowed for 90% of patients to achieve optimal debulking (no single lesion larger than 1 cm). Ten of the 41 patients had chest tubes placed at the time of surgery. Of the remaining 31 patients, 3 (9.7%) subsequently required a chest tube. Complications that could possibly be attributed to DR were symptomatic pneumothorax requiring chest tube placement (2/41; 4.9%) and the accumulation of pleural effusions contributing to respiratory compromise requiring percutaneous thoracentesis (4/41, 9.8%). One of 41 developed a subphrenic abscess that required percutaneous drainage and antibiotic therapy. One of 41 who underwent left DR as well as splenectomy developed a gastro-pleural fistula late in her hospital course, and eventually died from sepsis. This study was not designed to evaluate diaphragmatic resection and

survival, but was designed to address potential complications from DR, and has shown that DR risks are comparable to other debulking procedures.

Devolder et al. (2008) looked at the role of diaphragmatic surgery in a series of patients from 1993 to 2001. A total of 137 patients underwent cytoreductive surgery. Of these, 69 patients underwent diaphragmatic surgery as part of cytoreduction surgery for advanced epithelial ovarian cancer (EOC). The remaining 68 patients did not have DR either due to being free of visible diaphragm involvement, or they were judged to be poor candidates medically for complete mobilization of the liver, due to other bulky disease or unstated reasons. For DR or coagulation, mobilization of the liver was needed in order to have adequate visualization. A Rochard retractor was used to retract the ribs for additional exposure. Seventeen of 69 patients underwent stripping, 22 of 69 underwent coagulation, and 30 of 69 underwent stripping and coagulation. Stripping was preferred when lesions were >5 mm, or extensive spread was appreciated. Coagulation was used in the presence of a small number of lesions (<20), small solitary lesions (<5 mm), and thin lesions (<5 mm). In five cases, the diaphragmatic muscle with the outer pleural layer was removed as well. In three of these five cases, the external pleural layer and the diaphragmatic muscle were closed with an interrupted layer of Polyglactin 910. The authors did not use prophylactic thoracic drains. In the remaining two of the five cases, the diaphragmatic defect was too large to be closed primarily, and was left open without the use of a thoracic drain. These two patients did not subsequently need thoracic drainage in their postoperative period. Complications attributed to diaphragmatic resection were pleural effusion (59%), elevation of the diaphragm (48%), and pneumothorax (5%). Only five patients needed a chest drain, and only seven needed pleural puncture. Stripping of the diaphragm caused a slightly higher morbidity than coagulation, but was also performed in cases of larger and thicker lesions. The authors compared the median overall survival of patients who underwent stripping ($n = 13$) with the median overall survival of patients who underwent coagulation ($n = 12$) in stage IIIC ovarian cancer and found that the median overall survival (OS) in the stripping group was 66 months versus 49 months in the coagulation group. This was not found to be statistically significant. They concluded that debulking to no residual disease resulted in the best survival in advanced ovarian cancer, diaphragmatic surgery to be feasible, and to have an acceptable morbidity.

Chereau et al. (2011) conducted a multicenter retrospective study that included 148 patients with advanced ovarian cancer. Complete cytoreduction was achieved in 84% of the patients. Risk factors for pulmonary complications were the addition of extensive upper surgery to the diaphragmatic surgery ($p = 0.014$) and the size of the diaphragmatic resection ($p = 0.012$). The pulmonary complications were pleural effusion (37%), pulmonary embolism (5%), pneumothorax (4%), and pulmonary infection (2%). Postoperative mortality was 3%. The authors concluded that diaphragmatic surgery achieved complete removal of the tumor but resulted in pulmonary complications.

Bashir et al. (2010) evaluated full-thickness resection of the diaphragm in 45 patients with advanced epithelial ovarian cancer undergoing either primary or secondary cytoreductive surgery. Of these patients, 73.3% had a full-thickness resection (FTR) of the diaphragm; 75.6% of the cases were performed for primary cytoreduction of stage IIIC (27/45) or stage IV disease (18/45). Transdiaphragmatic decompression of pneumothorax (TDDP) was performed in 41 of 45 patients undergoing diaphragm FTR, while 4 of 45 had thoracostomy tubes placed introperatively. Radiographic imaging on postoperative days 3 to 4 revealed 9.8% had a residual pneumonthorax. Two patients (4.9%) required postoperative thoracostomy tube placement or thoracentesis. Therefore, TDDP potentially eliminates the need for intraoperative and postoperative thoracostomy tube placement or thoracentesis.

LIVER

It is our practice to transect the falciform, right, and left triangular ligaments using a LigaSure device (Covidien Inc., USA), Gyrus bipolar cutting forceps (Gyrus Inc., USA), or an argon beam coagulator (Conmed Inc., USA). Similarly, the upper and lower layers of the coronary ligaments are incised using argon beam coagulation, and as the dissection proceeds posteriorly significant care is required to ensure the inferior vena cava is not injured as it penetrates the diaphragm. The liver can now be elevated and mobilized toward the midline, allowing for complete visualization and resection of all diaphragmatic disease, or resection of the diaphragm as needed. Special care is also required in mobilizing the liver in this manner as the bare area of the liver is easily fractured, resulting in significant blood loss. The use of a surgical sponge soaked in saline and epinephrine 1/100,000 dilution can minimize this problem. The surgeon must be prepared to address bleeding caused by this dissection. Techniques used most frequently by the authors include the use of topical hemostatic agents with the application of direct pressure. These agents include Arista (Medafor Inc., USA), Gelfoam (Baxter Inc., USA), and Surgicel (Johnson & Johnson, Inc., USA) soaked in thrombin, or Tisseel (Baxter Inc., USA) applied to the liver surface. In extreme cases, liver sutures are needed to compress large vessels deep to the surface. In the event that there is oozing from disease that infiltrates a raw surface, or a significant tear that must be sutured, and bleeding is significant, the loss can be reduced by first digitally entering the portal area, palpating the portal triad, and placing an atraumatic clamp or Penrose drain (our preference; i.e., Pringle maneuver) for a brief time. If the liver must be sutured, large atraumatic needles with 0-chromic are specifically made for use on liver. Of note, during the process the portal area is palpated for any nodal disease which is either resected after hemostasis, ablated with the argon beam coagulator if small, or aspirated with a cavitron ultrasonic surgical aspirator (CUSA) if it has high water content. An alternative approach to suturing is using radiofrequency ablation. The Habib probe (varying lengths) can be inserted into the bleeding site and energy applied until hemostasis is achieved. Pekmezci et al. (2010) reviewed eight patients who underwent liver resection for metastatic ovarian cancer. All eight patients had had prior tumor debulking surgery. The mean disease-free interval was 5.38 years from the time of initial surgery to surgery for metastatic liver lesions, and 39 months after liver resection to secondary metastases. Four patients had no evidence of disease after liver surgery. Liver surgery for EOC is feasible and effective.

Roh et al. (2011) evaluated hepatic resection as part of secondary cytoreductive surgery for recurrent ovarian cancer. Eighteen patients were identified as having had wedge resection

(4/18), unisegmentectomy (13/18), and bisegmentectomy (1/18). There were no surgical-related deaths. The overall median survival after hepatic resection was 38 months (range 3–78 months). The authors concluded that liver resection is safe, and liver lesions should not preclude optimal secondary cytoreductive surgery.

Bacalbasa et al. (2015d) evaluated whether optimal debulking of ovarian cancer including hepatectomy in their institution led to improved survival and was safe. Upon review of their cases, 31 debulkings included liver resection: 11 in the primary setting, 15 at secondary cytoreduction, 3 at tertiary cytoreduction, and 2 at the time of quaternary cytoreduction. They found that not only was survival longer in the patients who were optimally cytoreduced, which included liver resection, but that it is a safe and effective procedure.

THORAX

A more controversial issue is the appropriateness of addressing disease above the diaphragm. Recent reports suggest approximately 35% to 40% of patients with apparent stage IIIC ovarian cancer have subclinical stage IV disease, although in only a few cases was suboptimal disease (greater than 1 cm) found in the thoracic cavity. Diaz et al. (2010) reviewed the records of 42 patients with advanced ovarian cancer and right-sided pleural effusions who underwent video-assisted thoracic surgery (VATS). VATS was performed for pleural effusion in 30 of 42 patients (71%). Macroscopic disease was found in 29 of 42 patients (69%). Intrathoracic cytoreductive surgery was attempted in 6 of 18 patients (33%) with pleural disease >1 cm. After VATS, 29 of 42 (69%) patients underwent primary abdominal cytoreductive surgery. Thirteen of 42 (31%) patients received adjuvant chemotherapy after VATS, and 12 underwent interval cytoreductive surgery. Patients who received neoadjuvant chemotherapy after VATS versus primary cytoreductive surgery had a 2-year PFS of 22% versus 42% ($p = 0.36$). Lim et al. (2009) had 12 patients with ovarian cancer who underwent VATS from June 2007 to November 2008. Of the 12 patients, 7 had primary ovarian cancer and 5 had recurrent ovarian cancer. Intrathoracic disease ranged from 0.3 to 4.9 cm. Nine of 12 patients had pleural disease greater than 1 cm in size. Complete cytoreduction was achieved in all 12 patients. Based on the outcome of the VATS, 10 patients were scheduled to undergo intraabdominal cytoreductive surgery that same day. Two patients did not undergo cytoreductive surgery. One patient had recurrent cardiophrenic lymph node disease. The second patient had three cycles of chemotherapy, was in poor condition, and therefore intraabdominal surgery was delayed. Optimal intraabdominal cytoreduction was achieved in 10 of 10 patients (100%). No evidence of metastasis was identified in abdomen and thorax in all 12 patients, with a median follow-up of 10 months (2–14 months). Terauchi et al. (2009) performed a prospective study evaluating transdiaphragmatic thoracoscopic-assisted pleural biopsy and intrathoracic washings for advanced ovarian cancer with diaphragmatic metastases. Ten patients with stage IIIC ovarian cancer with prominent diaphragmatic lesions were eligible for transdiaphragmatic thoracoscopy, then biopsy of pleural lesions thought to be metastases, and pleural washings. Ten patients were enrolled. Three of 10 patients (30%) had metastatic lesions and positive cytology in the thoracic cavity. Two patients had positive biopsy results (20%). Two additional patients had positive cytology. A total of seven out of ten (70%) patients were upstaged to stage IV. Spirtos et al. (2007) reported at the European Society of Gynecologic Oncology in 2007 on 57 patients undergoing transdiaphragmatic thoracoscopy during surgery for apparent stage IIIC EOC with negative chest radiographs or CT scans. Twenty-three (40%) were found to have disease involving either the parietal or visceral pleurae. All with pleural disease had involvement of the diaphragm peritoneum and over 90% of the patients had positive retroperitoneal lymph nodes. Most of the disease (88%) found above the diaphragm was of small caliber (<1 cm) and could be ablated or resected. Yin et al. (2015) evaluated the role of transdiaphragmatic thoracic exploration (TDTE) in bulky stage IIIC ovarian cancer in patients who underwent diaphragmatic surgery. Twenty-two patients met criteria for evaluation; 14 of 22 (63.6%) had pleural metastases and were diagnosed with stage IVB disease due to TDTE. They concluded that TDTE is feasible, safe, and should be considered in a patient with an untapped pleural effusion and full-thickness diaphragm invasion. If by identifying this disease a surgeon's decision to continue with debulking efforts was to be influenced, or perhaps the decision made as to whether an intraperitoneal port should be placed for the administration of chemotherapy, then there is potential value in opening the diaphragm and placing a 5-mm laparoscope into the right thoracic cavity while the anesthesiologist halts ventilation so the parietal and visceral pleurae can be adequately visualized. Small-volume disease can be ablated using argon beam coagulation. If disease involves the lung parenchyma and is readily accessible, a TA-60 stapling device can be used to resect disease on the edges of the lung. Tisseel (Baxter Inc., USA) can be applied after stapling and resecting the involved portion of lung. A chest tube can easily be inserted transdiaphragmatically, although it is not universally agreed that it is necessary. If a chest tube is not inserted, a purse-string suture using monofilament suture (0-Monocryl or Prolene) should be placed to close the defect in the diaphragm, and a large caliber red Robinson catheter placed into the thoracic cavity. As the anesthesiologist hyperinflates the lungs, the catheter with suction applied is withdrawn and the purse-string suture secured. If the defect in the diaphragm cannot be closed primarily, a Gore-Tex graft can be sutured into place using 0-Prolene suture.

PERINEPHRIC REGION, INTESTINE, MESENTERY, AND LYMPH NODES

After completing the diaphragm and pleural resection, the right perinephric area is always thoroughly inspected since this is commonly an area beneath the liver in which it is easy to overlook residual disease. Disease in this area is usually either excised or ablated with the argon beam coagulator.

After completing the left upper quadrant cytoreduction (omentum + spleen + pancreas) and right upper quadrant cytoreduction (diaphragm + chest + liver + perinephric), the central abdomen is addressed, since exposure is now optimized. The intestine and its mesentery are now systematically inspected. Implants that are not immediately adjacent to intestinal serosa are most expeditiously ablated with the argon beam coagulator. Implants that are immediately adjacent to the serosa or on serosa are aspirated with the CUSA

if the water content of the tumor is high; alternatively, the implants are excised and seromuscular defects are oversewn with interrupted 3-0 silk. Unfortunately, this is the setting that most often prevents complete cytoreduction and requires the coalescence of the surgeons' judgment and technical ability to fully assess the feasibility of achieving complete cytoreduction in the context of the risk/benefit ratio to the patient. If need be, bulky, confluent disease can be resected with bowel resection and anastomosis.

In order to complete the resection of all upper abdominal disease, the left and right aortic lymph nodes should be resected. Of note, the lymph nodes are usually removed after the pelvic phase of surgery to facilitate exposure. Extensive bulky nodes, unlike those associated with metastatic squamous cell cervical cancers and some gastrointestinal malignancies, can be safely removed, since the surgical planes between nodes and adjacent vessels can be developed digitally, thus facilitating their resection. First, using an endo-GIA, the left gonadal vessels can be transected and resected along with the lymph nodes overlying the anterior and lateral aspect of the aorta down to the level of the bifurcation of the aorta. The dissection should continue across the midline, removing the lymph nodes in the interspace between the aorta and vena cava. If macroscopically involved lymph nodes are encountered posterior to these vessels, the lumbar vessels must be ligated and divided in order to safely resect lymph nodes in this area.

After completing the pelvic phase of surgery and the lymph node dissection, the full thickness of the abdomen is typically closed using a running monofilament suture.

CONCLUSIONS

1. Explore through a midline incision that permits access to the entire abdomen.
2. First address the left upper quadrant:
   a. This provides exposure.
   b. This prevents ongoing fluid loss.
   c. This helps to rule out pancreatic or gastric primary.
3. If the omental disease is severe, be open-minded about taking the omentum en bloc with a section of transverse colon or spleen or spleen with pancreas.
4. In the process of mobilizing the omentum and spleen and colon, use the opportunity to mobilize the bowel for the anticipated lymph node dissection.
5. After finishing the left upper quadrant, address the right upper quadrant.
6. When addressing the right upper quadrant, quantify the disease as a few scattered implants versus many scattered implants/confluent disease:
   a. If a few scattered implants, ablate with an argon beam coagulator.
   b. If many scattered implants or confluent disease, strip the diaphragm.
7. When stripping or resecting the diaphragm, first mobilize the liver as described; if there is an effusion or you enter the pleural cavity while undertaking resection of the disease, perform transdiaphragmatic thoracoscopy and be prepared to ablate the disease with an argon beam coagulator.
8. Be familiar with techniques for hemostasis of the liver (Pringle, argon beam coagulator, Habib, topical agents).
9. After the right upper quadrant, address the central disease. Never be in the position of deciding between the argon beam coagulator, CUSA, and excision. Ideally use all three:
   a. Argon beam coagulator for rapid ablation remote from serosa, although it is acceptable to use very briefly at 40 watts on serosa.
   b. CUSA for high water content on serosa and for other sensitive areas briefly.
   c. Excision.
10. Pelvic resection is usually completed after upper abdominal disease, as exposure is optimized.
11. Lymph node dissection is usually completed after pelvic resection, as exposure is further optimized.

REFERENCES

Aletti GD, Dowdy SC, Gostout BS, et al. 2006. Aggressive surgical effort and improved survival in advanced-stage ovarian cancer. *Obstet Gynecol* **107**:77–85.

Bacalbasa N, Balescu I, Dima S, et al. 2015a. Pancreatic resection as part of cytoreductive surgery in advanced-stage and recurrent epithelial ovarian cancer—A single-center experience. *Anticancer Res* **35**(7):4125–9.

Bacalbasa N, Balescu I, Dima S, et al. 2015b. Splenectomy as part of cytoreductive surgery in recurrent epithelial ovarian cancer. *Anticancer Res* **35**(9):5097–101.

Bacalbasa N, Dima S, Balescu L, et al. 2015c. Results of primary cytoreductive surgery in advanced-stage epithelial ovarian cancer: A single-center experience. *Anticancer Res* **35**(7):4099–104.

Bacalbasa N, Dima S, Brasoveanu V, et al. 2015d. Liver resection for ovarian cancer liver metastasis as part of cytoreductive surgery is safe and may bring survival benefit. *World J Surg Oncol* **13**(1):235.

Bashir S, Gerardi MA, Giuntoli RL, et al. 2010. Surgical technique of diaphragm full-thickness resection and trans-diaphragmatic decompression of pneumonthorax during cytoreductive surgery for ovarian cancer. *Gynecol Oncol* **119**(2):255–8.

Benedetti Panici P, Di Donato V, Dischetti M, et al. 2015. Predictors of postoperative morbidity after cytoreduction for advanced ovarian cancer: Analysis and management of complications in upper abdominal surgery. *Gynecol Oncol* **137**(3):406–11.

Chang SJ, Bristow RE, Chi DS, et al. 2015. Role of aggressive surgical cytoreduction in advanced ovarian cancer. *J Gyncol Oncol* [Epub ahead of print].

Chereau E, Rouzier R, Gouy S, et al. 2011. Morbidity of diaphragmatic surgery for advanced ovarian cancer: Retrospective study of 148 cases. *Eur J Surg Oncol* **37**(2):175–80.

Cliby W, Dowdy S, Feitoza SS, et al. 2004. Diaphragm resection for ovarian cancer: Technique and short-term complications *Gynecol Oncol* **94**:655–60.

Devolder K, Amant F, Neven P, et al. 2008. Role of diaphragmatic surgery in 69 patients with ovarian carcinoma. *Int J Gynecol Cancer* **18**:363–8.

Diaz JP, Abu-Rustum NR, Sonoda Y, et al. 2010. Video-assisted thoracic surgery (VATS) evaluation of pleural effusions in patients with newly diagnosed advanced ovarian carcinoma can influence the primary management choice for these patients. *Gynecol Oncol* **116**:483–8.

Eisenhauer EL, Abu-Rustum NR, Sonoda Y, et al. 2006. The addition of extensive upper abdominal surgery to achieve optimal cytoreduction improves survival in patients with stages IIIC-IV epithelial ovarian cancer. *Gynecol Oncol* **103**:1083–90.

Eisenkop SM, Spirtos NM, Friedman RL, et al. 2003. Relative influence of tumor volume before surgery and the cytoreductive outcome on survival for patients with advanced ovarian cancer: A prospective study. *Gynecol Oncol* **90**:390–6.

Hanprasertpong J, Ohishi R, Iwasa N, et al. 2010. Splenectomy during secondary cytoreductive surgery for epithelial ovarian cancer. *Asian Pacific J Cancer Prev* **11**:413–16.

Lim MC, Lee HS, Jung DC, et al. 2009. Pathological diagnosis and cytoreduction of cardiophrenic lymph node and pleural metastasis in ovarian cancer patients using video-assisted thoracic surgery. *Ann Surg Oncol* **16**:1990–6.

McCann CK, Growdon WB, Munro EG, et al. 2011. Prognostic significance of splenectomy of part of initial cytoreductive surgery in ovarian cancer. *Ann Surg Oncol* **18**(10):2912–8.

Pant AC, Santillian A, Montes TD, et al. 2010. Splenectomy in cytoreductive surgery for advanced ovarian cancer and subsequent intraperitoneal chemotherapy. *J Gynecol Oncol* **26**:179–82.

Pekmezci S, Saribeyoglu K, Aytac E, et al. 2010. Surgery for isolated liver metastasis of ovarian cancer. *Asian J Surg* **33**(2):83–8.

Roh HJ, Kim DY, Joo WD, et al. 2011. Hepatic resection as part of secondary cytoreductive surgery for recurrent ovarian cancer involving the liver. *Arch Gynecol Obstet* **284**(5):1223–9.

Shih KK, Chi DS. 2010. Maximal cytoreductive effort in epithelial ovarian cancer surgery. *J Gynecol Oncol* **21**:75–80.

Spirtos NM, Eisenkop SM, Fleury AC, et al. 2007. *Transdiaphragmatic thoracoscopy: Impact in patients with Stage IIIC epithelial ovarian cancer*. Berlin, Germany: European Society of Gynecologic Oncology. October 2007.

Terauchi F, Kobayashi Y, Nagashima T, et al. 2009. Pilot study on transdiaphragmatic thoracoscopic-assisted pleural biopsy and intrathoracic washing cytology for stage IIIc ovarian cancer with diaphragmatic metastases. *Int J Gynecol Cancer* **19**:300–3.

Yin S, Jiang R, Wang P, et al. 2015. Role of transdiaphragmatic thoracic exploration in bulky stage IIIC ovarian cancer patients who underwent diaphragmatic surgery. *Int J Gynecol Cancer* [Epub ahead of print].

23 Extraperitoneal approach to infrarenal, inframesenteric, and pelvic lymphadenectomies

Katherine A. O'Hanlan

INTRODUCTION

Pelvic and aortic lymphadenectomy is an essential step in the staging of pelvic malignancies. It is often used to determine primary therapy, to help remove all grossly or occult positive disease, and to enable stratification of malignancies for valid comparisons of treatments, all with the purpose of optimizing survival. A transabdominal laparoscopic approach for pelvic (Querleu et al. 1991) and infrarenal aortic (Querleu et al. 1993) lymphadenectomy was first described by Querleu and colleagues for staging cervical, endometrial, and ovarian malignancies. Urologists (Ferzli et al. 1992) and later gynecologic oncologists (Vasilev and McGonigle 1995) subsequently developed an extraperitoneal approach for pelvic, infrarenal aortic (Vasilev and McGonigle 1996), and suprarenal aortic (Possover et al. 1998) artery lymphadenectomy. Because the predominant drainage of malignancies of the cervix is to pelvic nodes, and of the endometrium and ovaries is to pelvic and aortic nodes (Matsumoto et al. 2002), this chapter focuses on use of a direct extraperitoneal approach for staging or restaging cervical, uterine, and ovarian carcinomas.

INDICATIONS

Cervical Carcinoma

Resection of bulky nodes prior to combination chemotherapy and radiotherapy has been shown to result in improved overall survival (Cosin et al. 1998). When PET or CT scans show enlarged pelvic nodes, lymphadenectomy and then radiation of the nodal beds and at least one nodal segment higher is indicated. In addition, it is useful to rule out aortic adenopathy when there are bulky nodes in the pelvis, prior to initiating radiotherapy to the pelvis alone (Tillmanns and Lowe 2007). The extraperitoneal approach can avoid the adhesions that can develop during transperitoneal surgery that can complicate radiation therapy.

Endometrial Carcinoma

The ability to laparoscopically remove pelvic and inframesenteric aortic nodes implicated in endometrial carcinoma was established by the Gynecology Oncology Group (Childers et al. 1993). However, it has been demonstrated that endometrial carcinoma can metastasize directly along the infundibulopelvic vessels to the infrarenal aortic lymph nodes in as many as two-thirds of the 77% of women with aortic metastases, especially if they have grade 2 or 3 disease, or a deeply invasive grade 1 endometrial carcinoma (Dowdy et al. 2008). A thorough lymphadenectomy may have a therapeutic benefit, because pathologically negative nodes can be found to harbor occult disease when specially stained or step-sectioned (Amezcua et al. 2006).

Ovarian Carcinoma

Staging of ovarian carcinoma included the right and left inframesenteric nodes and pelvic nodes until it was shown, not surprisingly, that lymphatic metastases could follow the ovarian vascular supply to the infrarenal aortics where the infundibulopelvic vessels originated (Onda et al. 1996). Now it is standard to resect bilateral infrarenal aortic nodes in staging ovarian (Morice et al. 2003, Takeshime et al. 2005) and primary peritoneal (Aletti et al. 2009) epithelial malignancies because there is decussation of lymphatics above the inferior mesenteric artery, even though the left side is slightly favored (Morice et al. 2003, Roger et al. 2008). In these instances, an extraperitoneal lymphadenectomy can be performed first in the surgical care plan with greatest facility.

METHODS

Preparation

Patients should always be consented for a laparoscopic lymphadenectomy with the knowledge that laparotomy may be necessary. Any node dissection around a major artery indicates typing and screening for antibodies, but reserving two units of packed red blood cells has not been useful because the blood loss is usually minimal. While bowel preparation is not indicated if extraperitoneal lymphadenectomy is the sole procedure, it can facilitate the rest of the staging procedure if hysterectomy, omentectomy, etc., are to be performed.

All patients with cancer should receive at least 30 to 40 mg of low-molecular weight heparin to prophylax against deep vein thrombus formation. The procedure is performed typically in a supine position if it is the sole procedure. If hysterectomy and other abdominal procedures will be performed later, then the modified lithotomy position is preferred. Arms are tucked by the patient's side, and shoulder bolsters are carefully positioned. The hips should be positioned so that they can be extended 180°, so that the left thigh does not limit the dissection. The surgeon is on the patient's left side with monitors on the right, one at the level of the feet, and the other at the level of the diaphragm.

Technique

Because success of an extraperitoneal approach depends on creating and maintaining a pneumoretroperitoneum, this procedure is always performed first. Any leak of carbon dioxide into the peritoneum will preferentially collapse the retroperitoneum due to the weight of the bowel.

There are two methods of entering the retroperitoneum by extraperitoneal approach: laparoscopic guidance or direct incision. When a laparoscopic survey of the abdomen is indicated first, then a single direct transumbilical puncture is made

(O'Hanlan et al. 2007). Abdominal survey is performed. If a washing is needed, a secondary 5-mm trocar can be inserted near the right anterior superior iliac crest.

Next, a 3-cm incision is made at the left McBurney site; that is, 2 cm medial and up to 4 cm superior to the anterior superior iliac crest (Figure 23.1). Use a Kelly clamp to open and spread each of the two paper-thin layers of oblique fascia that comprise the abdominal wall to access the subperitoneal fat with a finger. Visual guidance laparoscopically is useful to show proximity of the Kelly tips to the peritoneal lining so the surgeon is careful to not perforate this thin layer. Entry into the retroperitoneum is heralded by palpating the absence of either fascial layer attached to the iliac crest, allowing the finger to sweep toward the interior of the iliac fossa, over to the psoas (Figure 23.2).

If no intraperitoneal inspection is desired first, then it is possible to make a McBurney incision without peritoneal insufflation, and using opening of the hemostat before an advancing finger, again identifying that two fascial layers have been penetrated, and that the underside of the iliac crest has been accessed.

After either entry technique, the surgeon's finger is then used to separate the peritoneum off of the muscular wall as far as possible, sweeping far cephalad, posterior, and caudal directions, and posteromedially to palpate the left common iliac artery. A blunt-tip 5-mm trocar is inserted directly through a separate 5-mm incision in the axillary line about 4 to 6 cm above the level of the first (Figure 23.2), directly onto the surgeon's fingertip to protect the peritoneum from puncture, also under laparoscopic guidance. The carbon dioxide insufflator is now attached to the new 5-mm port, allowing insufflation of the retroperitoneum to about 10- to 12-mmHg pressure, and then collapse of the intraperitoneal compartment is facilitated by leaving the umbilical trocar open. A 12-mm blunt-tip hernia trocar is then inserted through the McBurney incision and secured by the inflated balloon, to maintain the pneumoretroperitoneum.



(**A**)

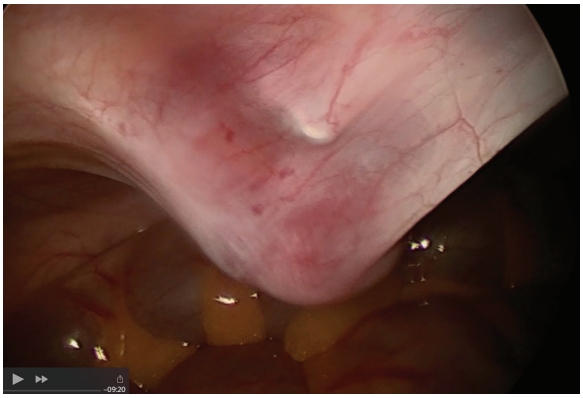

(**B**)

Figure 23.1 (**A**) Palpating the two fascial layers while opening with hemostats. (**B**) View from inside abdomen.

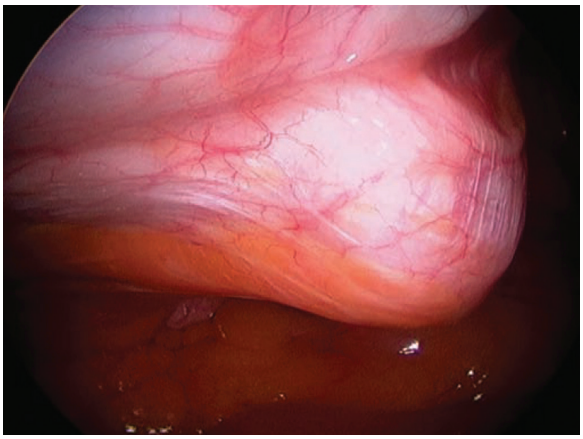

Figure 23.2 Laparoscopic guidance during dissection through the two abdominal wall fascial layers, being careful not to perforate the peritoneum. Using the finger, the peritoneum is swept off of the abdominal wall and the parietal pelvis.

Opening the Space

At this point, usually only adventitia is seen, with hints of the muscular red of the psoas muscle on the dorsal aspect (the "floor"), but more careful inspection will reveal the ureter vermiculating anteriorly medially or on the peritoneal "ceiling," and allow for gentle sweeping of the adventitia up and off of the dorsal "floor" until the major vessels are seen, if they are not seen immediately (Figure 23.3). The peritoneum is swept off of the muscular abdominal wall laterally with broad strokes, and more superiorly along the anterior axillary line so that a third 5-mm blunt-tip trocar can be inserted under direct visualization, careful not to inadvertently puncture the peritoneum (Figure 23.4). Now the surgeon can use a 5-mm vessel-sealing

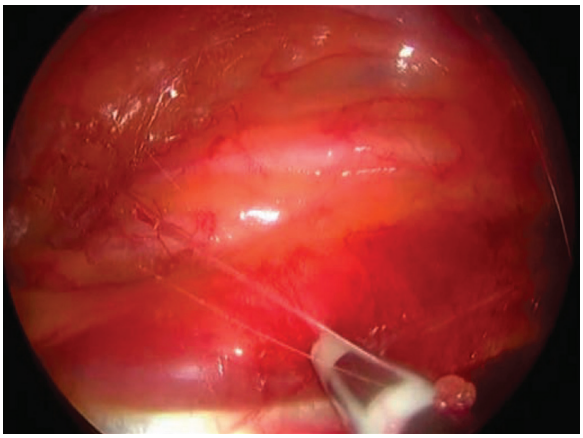

Figure 23.3 The newly opened adventitial space seen upon insertion of the scope, with the ureter seen crossing the common ileac artery, anterior to the psoas muscle.

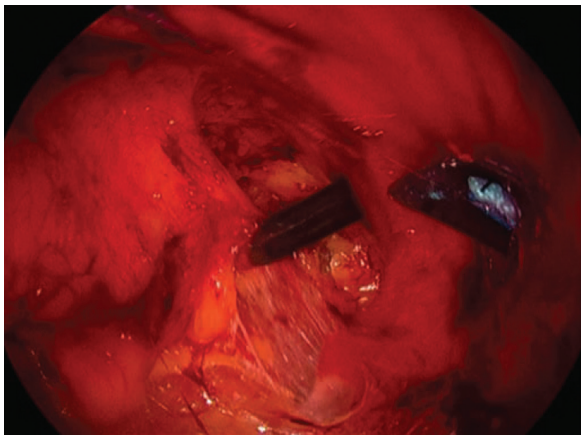

Figure 23.4 Sweeping the peritoneum away from the abdominal wall to allow for additional trocars to be inserted under direct vision.

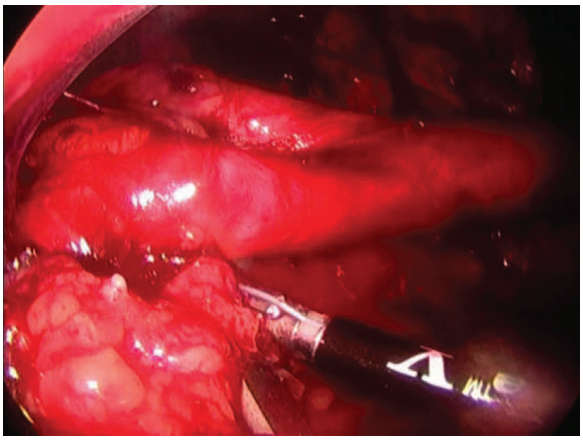

Figure 23.5 After exposing the length of the left side of the aorta, the nodal bundle is resected from the inferior mesenteric artery downward to the crossing of the ureter.

device and a blunt dolphin-tip grasper to lift the peritoneum off the left common iliac artery from the level of the ureter crossing at the bifurcation, cephalad to the renal artery. The ureter is left attached to the "ceiling," having been identified along its entire length. The ovarian artery and vein are seen lateral to the ureter below the level of the inferior mesenteric artery (IMA), but these vessels cross the ureter medially and find their origins on the anterolateral aspect of the aorta and the left renal vein. They can be ligated above the ureteral crossing and later tracked up to expose the left renal vein. The aorta is exposed along its left side to reveal the origin of the IMA. Above the IMA, the duodenum is identified and lifted up off the aorta to the level of the left renal vein, typically found crossing anterior to the aorta, often with an azygous branch extending posteriorly and behind the aorta. The tortuous left renal artery is *usually* posterior and slightly superior to the left renal vein. With broad strokes, the renal capsule can be swept superiorly up off the psoas to allow broad access to the left renal vessels. Frequent identification of the vermiculations of the ureter reassure the surgeon of the essential landmarks: the ureter is lateral to the ovarian vein superiorly.

Challenges Establishing Pneumoretroperitoneum

When the peritoneum is perforated, the retroperitoneal space will collapse due to the weight of the visceral bowel. Small leaks can sometimes be managed by the open umbilical trocar allowing the peritoneal compartment to vent. Closure of the leak is sometimes possible using hemoclips, suture, or Endoloop, and possibly sealing it with a sprayed fibrinogen/thrombin glue (Tisseel; Baxter). It is preferable to simply insert an additional 5-mm trocar to employ a flexible 5-mm liver retractor (CareFusion), or a 12-mm trocar for use of an Endopaddle (Ethicon) (Figure 23.3) to simply elevate the anterior peritoneal "ceiling" in each area that is being operated on. The liver retractor facilitates most of our cases and prevents the anterior peritoneum from limiting access to the nodal beds, especially in obese patients.

Harvesting the Left Inframesenteric Aortic Nodes

Nodes are harvested in order of easiest access. First the nodes from the IMA down to the crossing of the ureter are resected in a caudal direction (Figure 23.5). There is no need to strip the IMA of its own nodal investment, needlessly increasing the risk of chyloretroperitoneum. Remove the fibrofatty tissue at the base of the IMA for only 1 cm, and then all the left lateral nodal tissue above the left common iliac artery, using bipolar vessel-sealing confidently along the posterior and medial base of the nodal specimen down to the bifurcation of the common iliac (Lamberton et al. 2008). Remove these nodes using a 10-mm spoon forceps through the 12-mm port.

Next, remove the infrarenal (IR) nodes starting at the IMA, dissecting in a cephalad direction; after confident identification of the ureter laterally and the ovarian vein medially, the renal vein is exposed (Figure 23.6). There can be significant variability of the left renal vasculature, warranting a cautious technique of spreading, opening, and identifying until all of the major vessels and minor variations, including the unusual azygous vein, are exposed (Figure 23.7). Use bipolar sealing along the medial base of the aortic specimens to coagulate lumbar vertebral arterial branches and the origins of the left ovarian artery and vein (Figure 23.8). The IR nodes should be harvested from the anterior aspect of the aorta over to the left margin of the vena cava, and from the anterior aspect of the renal vein, so that nodes

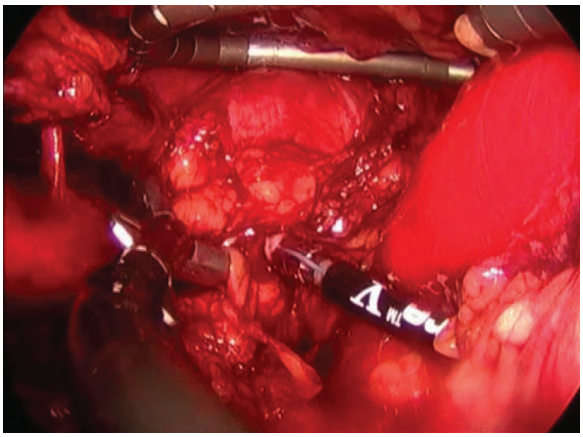

Figure 23.6 The duodenum is swept up off the nodal bundle above the inferior mesenteric artery using the 5-mm liver retractor. A real hand articulating bullet grasper is used to help resect the nodal bundle, working up from the inferior mesenteric artery.

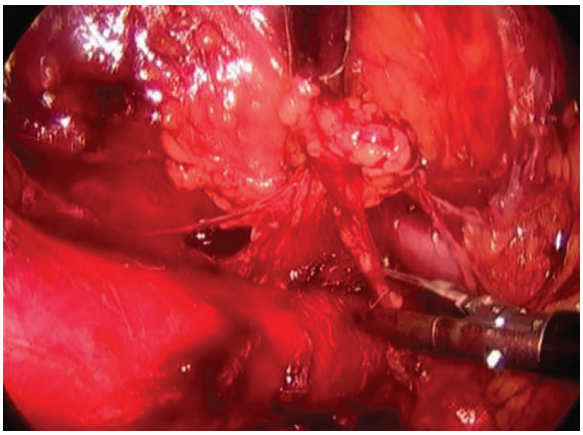

Figure 23.7 The left renal artery and vein have been identified and the left ovarian artery transected.

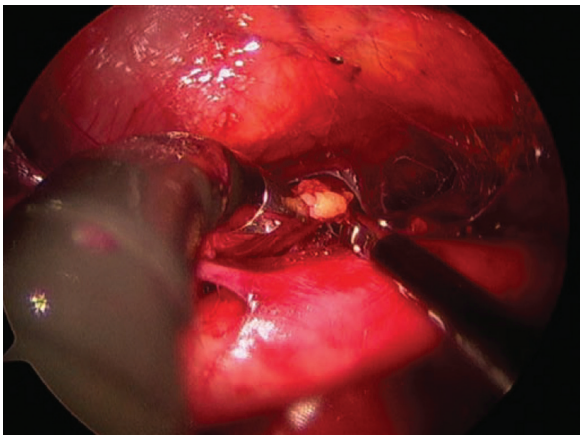

Figure 23.8 The articulating grasper elevates and facilitates resection of the right infrarenal nodal bundle.

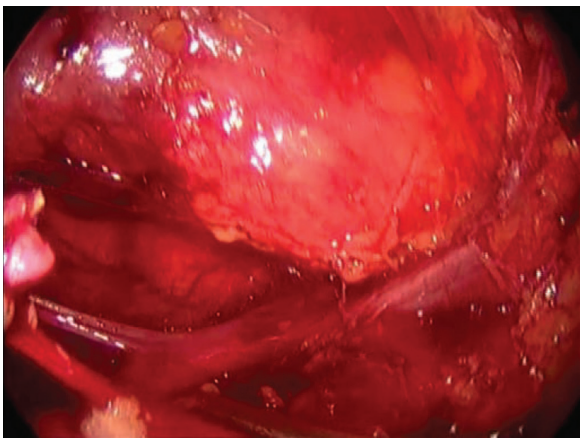

Figure 23.9 The completed right infrarenal node dissection revealing the right ovarian vein, the left renal vein, and the root of the inferior mesenteric artery.

clearly above the ovarian artery origin are thoroughly removed (Figure 23.9).

Resecting the Right Aortic Nodes

Next, to obtain the right inframesenteric nodal specimen, cross the bifurcation of the aorta, carefully lifting the peritoneum over the right common iliac artery, anticipating the right ureter as the lateral-most border (Figure 23.10). Then broadly open the psoas space, tracing the path of the ureter superiorly, recognizing the crossing of the ovarian vessels as they course medially to their origins on the right side of the vena cava and aorta, exposing up to the origin of the right renal vein. Be careful not to lift the nodes off the vena cava, but to rather elevate the duodenum off of the nodal bundle.

With the IMA stripped of its most proximal 1 cm, gently open underneath the precaval nodal bundle to expose the blueish vena cava. It is then possible to remove the nodal bundle anterior to the vena cava, starting just above the vessel, transecting confidently with bipolar, sealing all the "fellow" veins that arise in this region, stripping all fibrofatty lymph-bearing tissue off of the right common iliac artery and vein down to the ureter and remove the specimen (Figure 23.11). Recall that the rightmost lateral margin of the vena cava and common iliac node dissection is just a filmy avascular web that can be bluntly removed off of the psoas muscle (Figure 23.12).

To remove the right IR nodes, consider a 30° scope, and recall that the lateral margin of the upper nodal bundle is also avascular and can be stripped off the vena cava while watching out for the rare additional "fellow" veins, there still being a few above

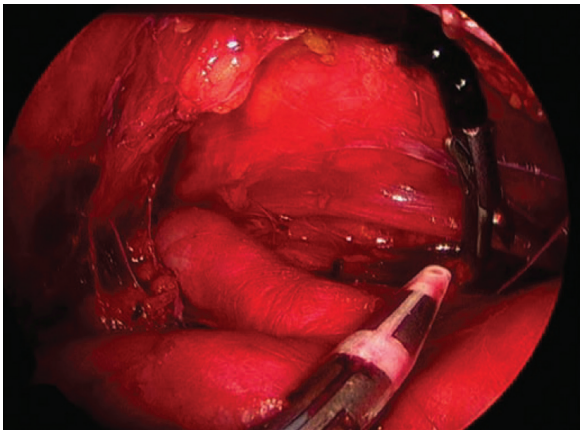

Figure 23.10 The right common ileac artery has been exposed and the nodal bundle anterior is being resected. Note the ureter, the lateral border of the dissection.

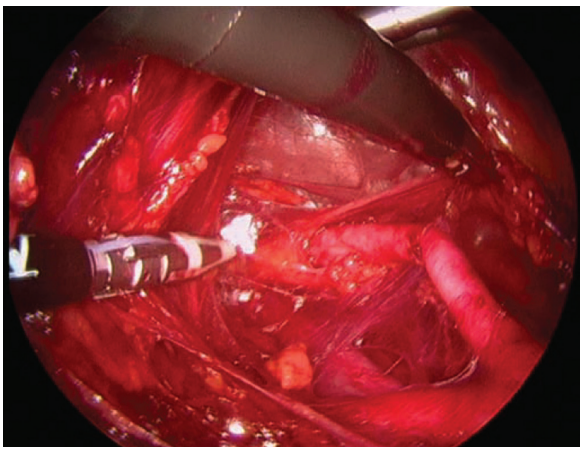

Figure 23.11 Preparing the right pelvic nodal filed for dissection, the peritoneum is being swept off of the sacrum using the Ligasure.

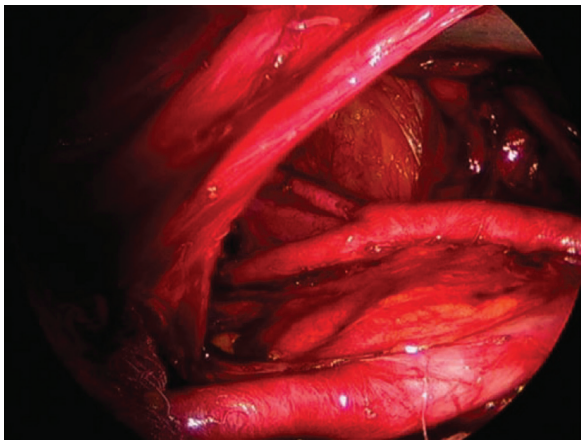

Figure 23.12 The completed right external ileac node dissection, with presacral nodes exposed.

the IMA. It is easiest to start at the right renal vein and work caudally to the IMA.

Harvesting the Pelvic Nodes

To access the pelvic nodes on the right side, sweep the peritoneum off of the anterior sacrum very gently with broad strokes, using blunt instruments so as not to puncture. Expose the external iliac artery down to the level of the crossing of the deep circumflex iliac vein over the external iliac artery going laterally. Strip the superior vesical artery, the medial margin of the nodal bundle, of its lateral attachments and open the paravesical space. Open the pararectal space posteriomedially to the internal iliac artery. Identify the genitofemoral nerve and begin to peel the nodal bundle *en masse* medially off the external iliac artery, then off of the vein, then under the vein off of the sidewall, posteriorly. Identify and expose the length of the obturator nerve as the posterior margin of resection, and remove the large unitary bundle off of the internal iliac artery (Figure 23.13).

It is harder to remove the nodes from the left side, but entirely possible, using the same technique. All instruments are torqued inferiorly, and excellent visibility is possible with the 30° scope with the same technique as used for the right side.

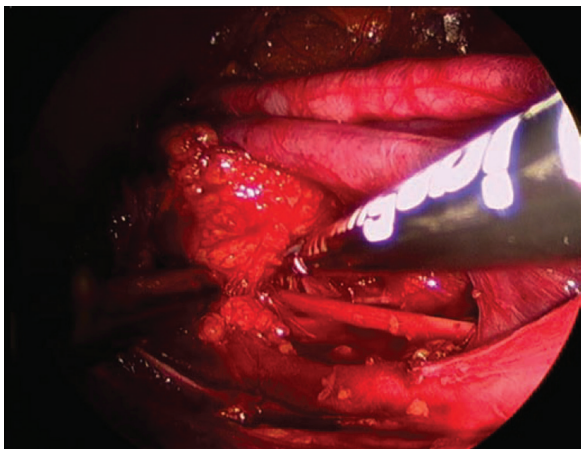

Figure 23.13 Freeing the obturator nodes from the obturator nerve. These nodes are bulky and solid in this patient with metastatic cervical cancer.

After this procedure, a drain is placed if the plan is to keep the retroperitoneum closed, as with cervical cancer. But for ovarian and endometrial, the pneumoretroperitoneum is broadly opened on each side to avoid lymphocyst development, and no drains are placed. Only the McBurney site requires closure with suture at the fascial level. Skin incisions can be closed with an inverted, vertical subcuticular suture of 4-0 monocryl. All incisions are sealed with skin glue.

Postoperative Management

Before transferring the patient to a gurney, a stretch binder is placed around the abdomen centered on the incisions, to compress them and reduce likelihood of leakage of lymphatic fluid. Discharge is planned for the same or next day, unless hysterectomy and other procedures are performed.

Surgical outcomes

Recent comparison of the extraperitoneal approach with a transperitoneal approach confirmed that the extraperitoneal approach may offer higher aortic nodal yields, even in patients with BMIs of 45 (O'Hanlan et al. 2015). In this report, both groups had similar age, 58 years, BMI of 26, blood loss of 150 cm, and hospital stay of 1 day. The extraperitoneal surgery took about 240 min and yielded an average of 50 nodes.

In this report, 25% of cervical, 19% of endometrial and 14% of ovarian cancer patients had metastases in radiographically negative infrarenal nodes, while 50% of cervical, 33% of endometrial, and 17% of ovarian cancer patients had therapy altered by aortic lymphadenectomy. When the inframesenteric nodes were positive, 63% of endometrial and 80% of ovarian cancer patients had infrarenal metastases. It was confirmed that more metastases were identified with increasing aortic node count. Higher BMI patients had lower aortic node yields by transperitoneal but not extraperitoneal approach. Among the 14 patients whose BMI was 35–41, mean extraperitoneal total aortic nodal yield was 30.

After 120 extraperitoneal comprehensive lymphadenectomies from the crossing of the deep circumflex iliac vein up to the renal veins, patients were surveyed for post-operative quality of life. They did not report lymphedema unless radiation was prescribed afterward (O'Hanlan et al. 2017).

Complications

These included two conversions to laparotomy for high blood loss and failure to complete, one transection of the left renal artery with saphenous vein interposition by laparotomy, and one obturator transection with repair. The retroperitoneal approach showed no learning curve, with nodal yields even in patients with a BMI as high as 39.

Patients are warned preoperatively that they may experience copious wine-colored fluid leak through the vaginal incision or any of their abdominal incisions for a few days. If a leak develops, they are instructed to place a bundled-up bulky non-sterile washcloth or paper towels in their binder to enhance compression of the leaking port site. It is not clear if this speeds up resolution or only helps manage the significant leakage that some develop, but the leakage always resolves in a few days. Nearly all patients are discharged from the hospital the next day.

Infectious complications are rare. Chylous retroperitoneum or ascites has been described, with most cases resolving after dietary modification. Vascular complications, while potentially serious, are rare (Querleu et al. 2006). Some surgeons insert a 4×4 gauze pad into the retroperitoneum to facilitate visualization and for compression in case of vascular injury. Compression of any vascular injury for 5 minutes (by the clock) can facilitate laparoscopic suture repair. It is wise to have a 5-mm clip applier available in the room for any emergency. Avulsion or transection of the IMA is not serious, but must be reliably sealed with a clip. Injury to the vena cava or left renal vein by avulsion of the ovarian vein may require multiple clips or application of an equine cartilage patch covered with desiccated thrombin and fibrinogen (Tachosyl; Baxter). Arterial injury such as avulsion of the ovarian artery can be treated with a clip or application of bovine cartilage granules covered with thrombin (Floseal; Baxter). Ureteral injury should be very rare, due to repeated re-identification, and following the "identify twice, cut once" rule. While obese patients benefit most from this procedure, obesity is also a common cause of converting to laparotomy.

CONCLUSIONS

Comprehensive laparoscopic retroperitoneal pelvic to infrarenal aortic lymphadenectomy for early pelvic carcinoma is safe and readily feasible, and may impact staging and treatment decisions in one-third of patients. An extraperitoneal approach may be easier to learn and be more effective for larger patients than a transperitoneal approach.

REFERENCES

Aletti GD, Powless C, Bakkum-Gamez J, et al. 2009. Pattern of retroperitoneal dissemination of primary peritoneum cancer: Basis for rational use of lymphadenectomy. *Gynecol Oncol* **114**(1):32–6.

Amezcua CA, MacDonald HR, Lum CA, et al. 2006. Endometrial cancer patients have a significant risk of harboring isolated tumor cells in histologically negative lymph nodes. *Int J Gynecol Cancer* **16**(3):1336–41.

Childers JM, Brzechffa PR, Hatch KD, et al. 1993. Laparoscopically assisted surgical staging (LASS) of endometrial cancer. *Gynecol Oncol* **51**(1):33–8.

Cosin JA, Fowler JM, Chen MD, et al. 1998. Pretreatment surgical staging of patients with cervical carcinoma: The case for lymph node debulking. *Cancer* **82**(11):2241–8.

Dowdy SC, Aletti G, Cliby WA, et al. 2008. Extra-peritoneal laparoscopic paraaortic lymphadenectomy—A prospective cohort study of 293 patients with endometrial cancer. *Gynecol Oncol* **111**(3):418–24.

Ferzli G, Raboy A, Kleinerman D, et al. 1992. Extraperitoneal endoscopic pelvic lymph node dissection vs. laparoscopic lymph node dissection in the staging of prostatic and bladder carcinoma. *J Laparoendosc Surg* 2(5):219–22.

Lamberton GR, Hsi RS, Jin DH, et al. 2008. Prospective comparison of four laparoscopic vessel ligation devices. *J Endourol* **22**(10):2307–12.

Matsumoto K, Yoshikawa H, Yasugi T, et al. 2002. Distinct lymphatic spread of endometrial carcinoma in comparison with cervical and ovarian carcinomas. *Cancer Lett* **180**(1):83–9.

Morice P, Joulie F, Camatte S, et al. 2003. Lymph node involvement in epithelial ovarian cancer: Analysis of 276 pelvic and paraaortic lymphadenectomies and surgical implications. *J Am Coll Surg* **197**(2):198–205.

O'Hanlan KA, Dibble SL, Garnier AC, et al. 2007. Total laparoscopic hysterectomy: Technique and complications of 830 cases. *JSLS* **11**(3):45–53.

O'Hanlan KA, Sten MS, O'Holleran MS, Ford NN, Struck DM, McCutcheon SP. 2015. Infrarenal lymphadenectomy for gynecological malignancies: Two laparoscopic approaches. *Gynecol Oncol* **139**(2):330–7.

O'Hanlan KA, Sten MS, Halliday DM, Sastry RB, Struck DM, Uthman KF. 2017. Comprehensive laparoscopic lymphadenectomy from the deep circumflex iliac vein to the renal veins: Impact on quality of life. *Gynecol Oncol* 144(3):592–7.

Onda T, Yoshikawa H, Yokota H, et al. 1996. Assessment of metastases to aortic and pelvic lymph nodes in epithelial ovarian carcinoma. A proposal for essential sites for lymph node biopsy. *Cancer* **78**(4):803–8.

Possover M, Krause N, Drahonovsky J, et al. 1998. Left-sided suprarenal retrocrural para-aortic lymphadenectomy in advanced cervical cancer by laparoscopy. *Gynecol Oncol* **71**(2):219–22.

Roger N, Zafrani Y, Uzan C, et al. 2008. Should pelvic and para-aortic lymphadenectomy be different depending on histological subtype in epithelial ovarian cancer? *Ann Surg Oncol* **15**(1):333–8.

Takeshima N, Hirai Y, Umayahara K, et al. 2005. Lymph node metastasis in ovarian cancer: Difference between serous and non-serous primary tumors. *Gynecol Oncol* **99**(2):427–31.

Tillmanns T, Lowe MP. 2007. Safety, feasibility, and costs of outpatient laparoscopic extraperitoneal aortic nodal dissection for locally advanced cervical carcinoma. *Gynecol Oncol* **106**(2):370–4.

Querleu D, Leblanc E, Cartron G, et al. 2006. Audit of preoperative and early complications of laparoscopic lymph node dissection in 1000 gynecologic cancer patients. *Am J Obstet Gynecol* **195**(5):1287–92.

Querleu D, Leblanc E, Castelain B. 1991. Laparoscopic pelvic lymphadenectomy in the staging of early carcinoma of the cervix. *Am J Obstet Gynecol* **164**(2):579–81.

Querleu D, Leblanc E, Castelain B, et al. 1993. Celioscopic pelvic and paraaortic lymphadenectomy. *Chirurgie; memoires de l'Academie de chirurgie* **119**(4):208–11.

Vasilev SA, McGonigle KF. 1995. Extraperitoneal laparoscopic paraaortic lymph node dissection: Development of a technique. *J Laparoendosc Surg* **5**(2):85–90.

Vasilev SA, McGonigle KF. 1996. Extraperitoneal laparoscopic para-aortic lymph node dissection. *Gynecol Oncol* **61**(3):315–20.

24 Vascular access and implantable vascular and peritoneal access devices

Paniti Sukumvanich and Gary L. Goldberg

INTRODUCTION

Most patients with cancer will undergo multiple courses of chemotherapy and other intravenous infusions as a part of their management. Venous access can become compromised by the intravenous cytotoxic chemotherapies, transfusions, hyperalimentation, and other fluids. In 1972, Cole and colleagues reported on the first surgically implanted vascular access device based on a modification of an arteriovenous fistula catheter for renal dialysis (Cole et al. 1972). This was later modified and made popular by Broviac and Hickman (Broviac et al. 1973, Hickman et al. 1979). A decade later, a completely implanted device known as the Port-a-Cath (PAC) was introduced (Ecoff et al. 1983). Newer devices (PowerPort®) now allow for powered injection of contrast media and can be used for CT pulmonary angiogram. These devices have become more popular as a greater variety of chemotherapeutic options have become available to patients. The advantage of venous access ports includes fewer access failures with less access-related anxiety and pain (Bow et al. 1999). With the advent of intraperitoneal chemotherapy, PAC devices became a means of obtaining intraperitoneal access. This chapter discusses the indications, techniques of insertion, complications, and management of complications for these venous access devices.

INDICATIONS

The main indication for central venous access devices includes the need for venous access in patients undergoing prolonged chemotherapy, especially in patients with poor venous access. The need for access may be determined by patient's preference to avoid multiple attempts of phlebotomy or the need to assure safe intravascular access. PAC devices for use as intraperitoneal access devices are indicated in patients who are expected to undergo intraperitoneal chemotherapy.

CONTRAINDICATIONS

Patients should not undergo elective venous access catheter placement in the presence of a current infection, such as bacteremia, septicemia, or fungemia. Patients with clinically significant thrombocytopenia or coagulopathy should also not undergo the procedure without special consideration and preparations.

ANATOMIC CONSIDERATIONS

Central venous lines can be accessed through a number of routes. The routes most commonly utilized are the internal jugular vein or the subclavian vein. The internal jugular vein is located within the supraclavicular fossa. The borders of the fossa are the clavicle inferiorly, and the sternal and clavicular heads of the sternocleidomastoid muscle anteriorly and posteriorly, respectively. The internal jugular vein empties into the brachiocephalic vein, which is anterior and lateral to the common carotid artery, and posterior to the artery is the apex of the lung. The subclavian vein is a continuation of the axillary vein which runs along the superior border of the pectoralis minor muscle to the level of the first rib. The lateral border of the first rib can be approximated by finding the area on the clavicle where it changes from a convex to a concave curvature (about two-thirds of the distance from the head of the clavicle). It is important to note that there is no major vessel directly posterior to the clavicle lateral to the first rib. Thus, attempts at venous access lateral to this area will usually fail. At the lateral border of the first rib the subclavian vein begins and runs parallel to the first rib, posterior to the clavicle, and ends at the medial border of the scalenus anterior muscle. The subclavian vein then merges with the internal jugular vein and forms the brachiocephalic vein. The subclavian artery, though it runs parallel with the vein, is separated by the scalenus anterior muscle.

TYPES OF PORTS

Venous access catheters can be divided into two types. The first type consists of an externalized Hickman-type catheter. This type of catheter is similar to a central line catheter except that a portion of the catheter is tunneled subcutaneously and has an externalized access site. The second type of venous access catheter is a completely implanted device. The most common example is the PAC. This device has a silicone and titanium reservoir site that is accessed through the skin.

SURGICAL PROCEDURE

Both types of access devices, the externalized Hickman-type and the internalized PAC type, are potential options for central venous access. However, internalized ports are recommended since they are easier to maintain than the externalized devices and they are more "patient-friendly." It was assumed that the Hickman-type catheters had a higher rate of catheter-related infections, but a randomized prospective trial did not bear this out (Mueller et al. 1992).

Preoperative Evaluation and Testing

1. Complete blood count, platelet count, and coagulation profile.
2. Prophylactic antibiotics are not required. There are limited data regarding the use of antibiotics in central venous catheters. Although possible reductions (Bock et al. 1990, Henrickson et al. 2000, Raad et al. 1998) in infection rates have been reported, the emergence of resistant organisms is of concern (HICPAC 1995, van de Wetering and van Woensel 2007). Alcohol-based skin preparations are preferred over alternative agents.

Surgery

1. Prepare both sides of the neck and chest to the level of the xyphoid process should the attempt on the right side fail.
2. Have the arms tucked on the side of the insertion.
3. In obese patients, a roll of towel can also be placed between the shoulders to allow for easier access in the subclavian approach (Figure 24.1).
4. Place the patient in Trendelenburg to distend the target vessels.

Venous Access

Venous access can be obtained via either the internal jugular vein or the subclavian vein. The right subclavian vein is usually accessed as the initial choice, as it is more convenient for a right-handed surgeon. Access can be obtained either through a percutaneous or cutdown technique. Cutdown technique has been associated with a lower risk of pneumothorax. However, cutdown technique has the disadvantage of being unsuccessful in 6% of cases, requiring a percutaneous approach in order to successfully complete the procedure (Knebel et al. 2011).

The anatomic landmarks described below will indicate the general starting area. Real-time intraoperative sonography can often confirm the target and its safe access. The internal jugular is more reliably identified by sonography than is the subclavian vein. Easy compression of the vein parallel to the pulsating accompanying artery helps distinguish the two vascular structures. Doppler can do the same by detecting the opposite blood flow.

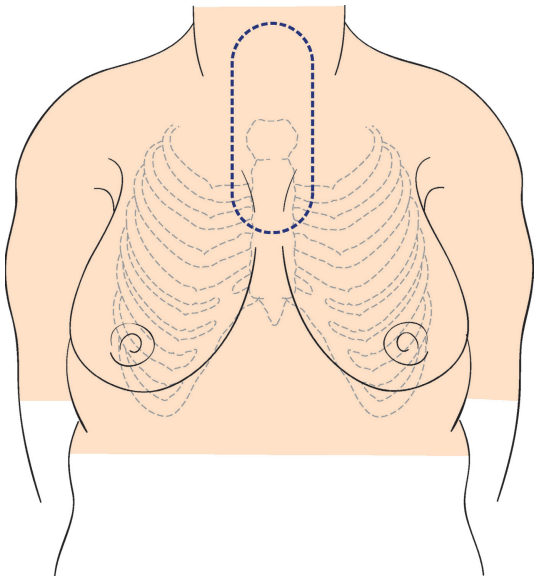

Figure 24.1 Positioning of patient with towel roll in place. The dotted area indicates where a roll of towel can be placed between the patient's shoulder blades. This can help facilitate access to the subclavian vein in an obese patient.

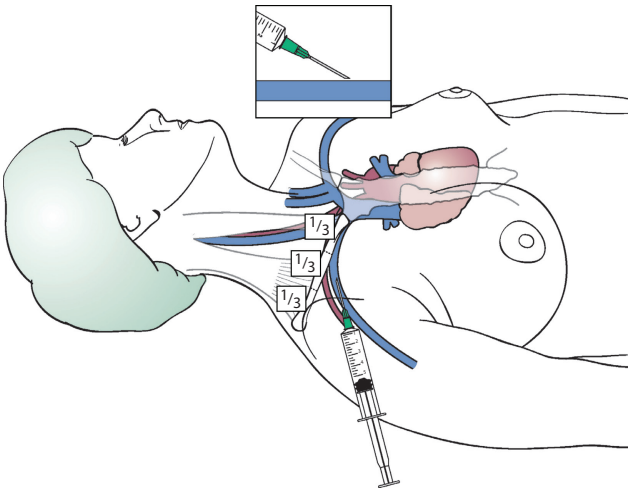

Figure 24.2 Subclavian venous access with the Seldinger technique. The 16-gauge needle should be inserted in an area that is two-thirds distal to the head of the clavicle, with the bevel of the needle pointing down.

Percutaneous (Seldinger) Technique

Needle Insertion

1. Local anesthesia using 1% lidocaine (lignocaine) at the site of either the internal jugular vein or the subclavian vein.
2. Set up the 16-gauge needle by lining the bevel of the needle with the numbers on the syringe. This will allow the surgeon to be aware of the direction of the bevel once the needle has been inserted.
3. Insertion into the vein should be done with the bevel pointing inferiorly (Figure 24.2).

Subclavian Vein Access

Traditional Method of Insertion

1. Insert the needle directly perpendicular to the skin about 0.5 cm from the inferior edge of the clavicle two-thirds from the head of the clavicle.
2. Once you have gone through the skin, angle the needle toward the subclavian vein underneath the clavicle by aiming for the sternal notch. The needle/syringe should be parallel to the chest wall as negative pressure is applied until there is venous blood return. If there is no blood return on initial insertion, slowly withdraw the syringe.

Alternative Technique

1. Squeeze the clavicle (two-thirds from the head of the clavicle) with the index finger and thumb. Be sure you are grasping the entire clavicle.
2. Insert the needle at the lower edge of the thumb with bevel down. Once through the skin, aim the needle toward the sternal notch while pushing down on the needle with the left thumb. Negative pressure should be applied until there is venous blood return.

Sonogram identification of the subclavian vein is often obtained from a supraclavicular approach. Therefore the needle insertion approach must follow that for real-time continuous sonogram guidance.

Internal Jugular Access

There are two approaches for accessing the internal jugular vein—the anterior and posterior approaches. The anterior or posterior portion of the name refers to whether the needle is inserted anterior or posterior to the sternocleidomastoid muscle. Sonogram guidance can be used with either approach.

1. *Anterior approach.* Locate the triangle that is formed by two heads of the sternocleidomastoid muscle and clavicle. First, apply 1% lidocaine (lignocaine) to the apex of the triangle in order to anesthetize the skin. Insert the needle at the apex of the triangle, anterior to the muscle, aiming the needle toward the ipsilateral nipple at a 45° to 60° angle until the vein has been accessed. Be careful to not aim too medially, as there is a potential for puncturing the carotid artery.
2. *Posterior approach.* Local anesthesia with 1% lidocaine (lignocaine). Locate the sternocleidomastoid muscle and insert the needle three finger-breadths above the clavicle and posterior to the sternocleidomastoid muscle. Aim the needle toward the suprasternal notch at a 45° angle to the horizontal plane (Figure 24.3).

Passing the Guide Wire

1. Once the subclavian vein has been accessed, rotate the bevel of the needle toward the heart (i.e., the numbers on the syringe should be facing the patient's heart). If the internal jugular vein is used, then no rotation of the needle is necessary.
2. Remove the syringe from the needle and gently thread the guide wire through the needle. Before removing the syringe, reconfirm that the patient is still in Trendelenburg to minimize the risk of air embolism. Remove needle once the guide wire has passed into the vein without resistance. Minimal force should be used, as injury to the vein or the heart can occur if undue force is applied. Care should also be taken not to leave the needle hub exposed for a long time, as inspiration by the patient can lead to an air embolism.
3. If premature ventricular contractions (PVCs) are seen on the electrocardiogram (EKG), withdraw the wire until PVCs are no longer seen.
4. Fluoroscopy should be performed at this point to confirm the location of the wire to the right of the vertebral column.
5. Estimate the length of the catheter and cut with a pair of mayo scissors. The catheter should be long enough to go from the port site to the superior vena cava (Figure 24.4). The length of the catheter can be estimated by cutaneous landmarks or after insertion by using fluoroscopy while the wire is still in the catheter.

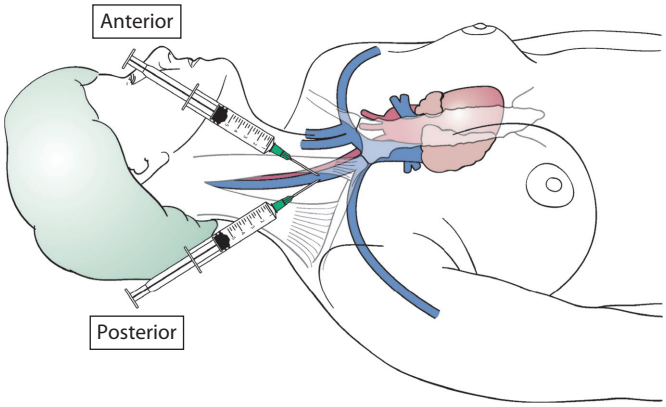

Figure 24.3 Internal jugular access with the Seldinger technique. The anterior approach involves insertion of a 16-gauge needle at the apex of the triangle that is formed by the two heads of the sternocleidomastoid muscle and the clavicle. In an obese patient where the apex of the triangle is hard to appreciate, the apex is approximately halfway between the sternal notch and the mastoid process.

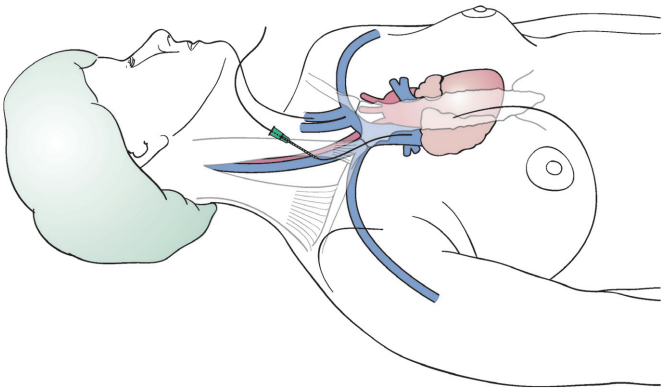

Figure 24.4 Passing the guide wire. It is important to perform this maneuver with very little force, as there should be minimal resistance if the wire is going in the correct direction.

Dilating the Skin Incision/Passing the Catheter

1. Extend the skin incision with a no. 11 blade on either side of the guide wire. The incision should allow insertion of the port sheath without resistance.
2. Pass the inner dilator sheath over the guide wire. Pull back on the wire at this time to ensure the sheath is patent. Fluoroscopy at this point can also assist in determining the eventual length of the catheter and positioning of its tip.

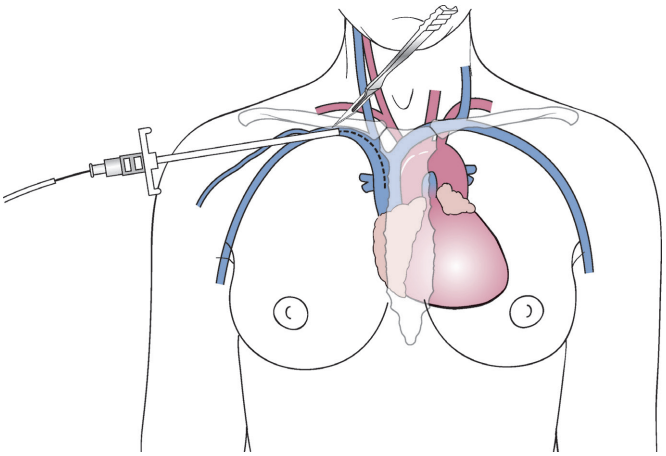

Figure 24.5 Dilating the skin incision and passing the catheter.

3. Remove the inner dilator sheath, leaving the guide wire in place. Connect the inner and outer dilator sheaths and pass this over the guide wire. Again, pull back on the guide wire as the sheath is being inserted. Be sure to not completely pull out the guide wire.
4. Pull out the inner sheath with the guide wire in place.
5. Pass the premeasured catheter over the guide wire and then remove the guide wire.
6. Peel the sheath in half and slowly withdraw the outer sheath, stabilizing the catheter in place at the skin incision with a pair of atraumatic forceps.
7. Access and flush the catheter with a weak heparinized saline via a blunt Huber needle to confirm venous access (Figure 24.5). (See "Making the Pocket for the Port" below for the final steps).

Cutdown Technique

Venous Access via the Cephalic Vein

A transverse skin incision is made at the acromial end of the clavicle. Dissect the fascia over the pectoralis muscle and identify the separation between the deltoid muscle and the pectoralis major. Within this groove is the cephalic vein. Retract the vein with a 2-0 silk and make a venotomy on the anterior surface of the vein. Cannulate with the catheter (or wire if the vein is too small) using the vein pick typically supplied in the kit. The dilator supplied with the kit can be used over the wire if necessary. Check the placement of the catheter by fluoroscopy. Once the position of the catheter tip is confirmed in the superior vena cava, tie the 2-0 silk to secure the position of the catheter and to maintain hemostasis (Figure 24.6A).

Internal Jugular Cutdown

A transverse skin incision is made 2 cm above the clavicle overlying the supraclavicular triangle. The dissection is performed to the level of the sternocleidomastoid muscle. Separate the muscle to expose the internal jugular vein. A 2-0 silk purse-string suture is placed in the internal jugular vein if the diameter allows, followed by a venotomy. If the vein is too small for a purse-string, proximal and distal control can be achieved using vessel loops. Once the vein is cannulated with a catheter and the tip is in the correct position, tie the suture to secure the position of the catheter and to maintain hemostasis (Figure 24.6B).

Making the Pocket for the Port

Regardless of how venous access is obtained, the following can be used to attach the reservoir to the proximal catheter end.

1. The site of the pocket should be lateral enough to prevent kinking of the catheter by the clavicle after the port reservoir and catheter are connected. The site should not be too caudal, as the port pocket should be on the anterior chest wall and not the breast tissue.
2. Incise the skin with a knife and dissect posteriorly toward the pectoralis major fascia.
3. Once the fascia has been located, dissect out the pocket for the port inferior to the skin incision. Make the pocket large enough to accommodate the port

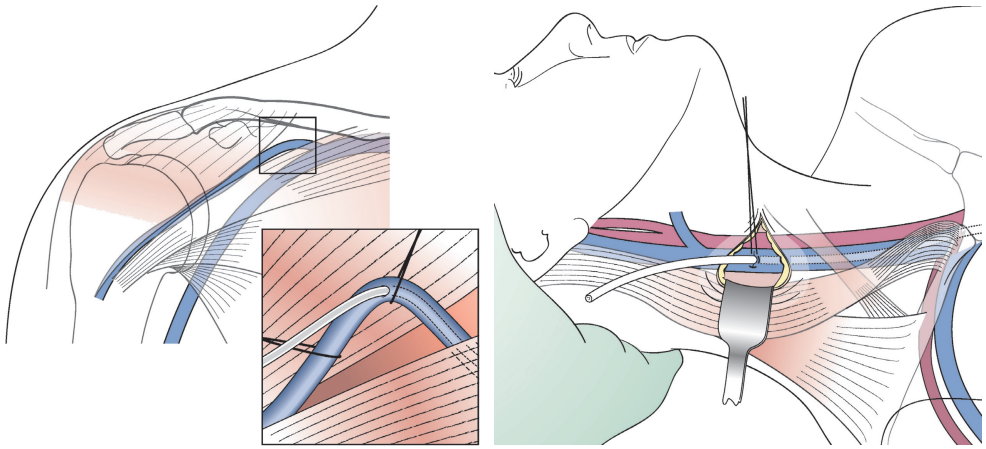

Figure 24.6 (**A**) Venous access via the cephalic vein using the cutdown technique. (**B**) Venous access via the internal jugular using the cutdown technique.

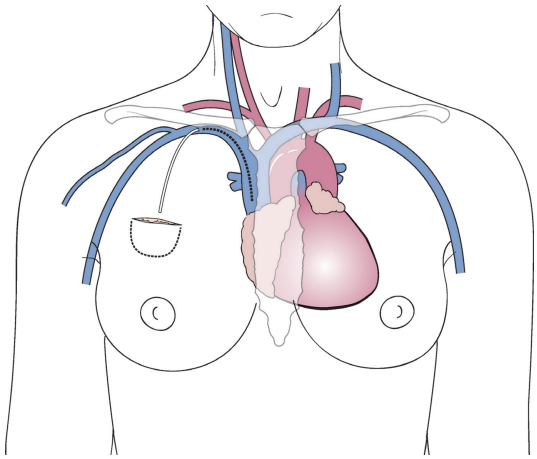

Figure 24.7 Making a pocket for the port.

reservoir without difficulty. Ensure hemostasis in the pocket prior to fixation of the reservoir (Figure 24.7).

Creating a Tunnel for the Catheter

1. Tunnel subcutaneously toward the cephalad incision. The tunnel should be under the fat and not directly under the skin. Tunneling too close to the skin will not properly conceal the catheter. The kit may contain a malleable tunneling device to facilitate this.
2. Gently pull the catheter through the tunnel, taking care not to twist or kink the catheter at the insertion site.
3. Flush the catheter with weak heparinized saline using a blunt Huber needle to confirm venous return (Figure 24.8).

Connecting the Port to the Catheter

1. Make sure the catheter is the appropriate length, and trim as necessary.

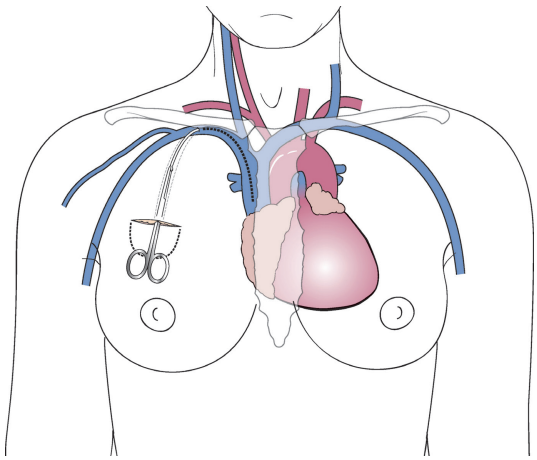

Figure 24.8 Creating a tunnel for the catheter.

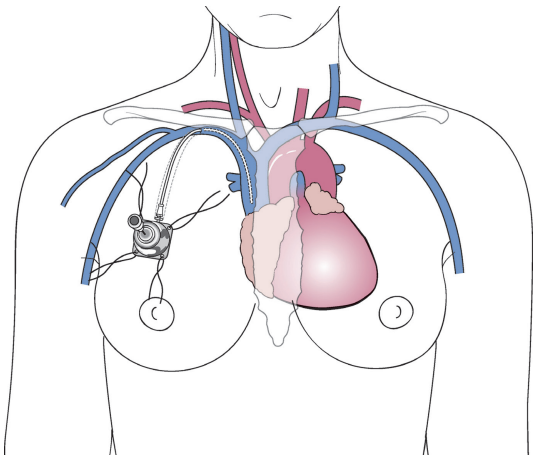

Figure 24.9 Connecting the port to the catheter.

2. Thread the locking device over the catheter.
3. Connect the catheter to the reservoir and place in the pocket. Care should be taken not to puncture the catheter.
4. Check the placement of the catheter tip by fluoroscopy. The tip of the catheter should be in the superior vena cava and outside of the heart.
5. Deploy the locking device.
6. Access the port through the skin with a sharp Huber needle. After accessing, flush with 10 cm^3 of heparinized saline. Leave the needle in place and suture the port in the pocket (Figure 24.9).

An alternative approach is to attach the proximal end of the full-length catheter to the reservoir. The catheter is then tunneled to the cutaneous exit site of the wire. The dilator is then placed over the wire and the wire removed. The catheter length is determined and cut. The dilator inner obturator is removed. The catheter is then fed into the peel-away sheath. While the catheter is held in place, the peel-away is split and removed with the help of an assistant.

Checking Placement of Catheter

A chest x-ray should be obtained after the procedure to confirm the position of the catheter and rule out potential complications associated with the placement. Pneumothorax or hemothorax may occur on the same or the contralateral side. The catheter tip should ideally be just outside the heart and parallel with the long-axis of the vein. A good radiologic marker is the carina (Schuster et al. 2000). Alternative tip placements, e.g., superior vena cava (SVC) are acceptable.

Peritoneal Access Device without Concurrent Laparoscopy or Laparotomy

1. Select the site for the peritoneal access device by the ninth to tenth rib, generally about 2 cm cephalad to the costal margin (Figure 24.10).

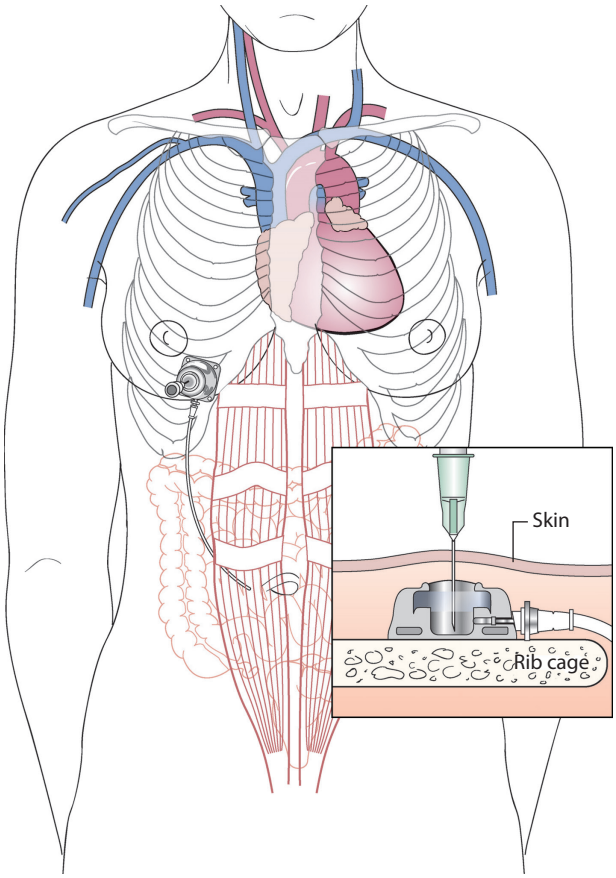

Figure 24.10 Placement of the peritoneal access device. The reservoir can be rolled up on the rib cage to provide a trim base while trying to access the device.

2. Once the site has been selected, make a diagonal skin incision 1 cm caudal to the costal margin and enter the peritoneal cavity.
3. Create a subcutaneous pocket above the rectus fascia and on the rib cage about 3 to 4 cm in size and about 3 to 4 cm away from the incision site.
4. Trim catheter to about 20 to 25 cm and insert into peritoneal cavity. Connect non-fenestrated end to the reservoir.
5. Suture reservoir to the fascia overlying the inferior border of the rib cage.
6. Close fascial incision around the catheter, with care to make the closure as tight as possible without kinking the catheter.

Maintenance and Access of Catheters

The purpose of routine maintenance of implanted catheters is to ensure venous access return and to prevent infection and thrombotic complications. Upper extremity deep vein thrombosis (DVT) in patients with central venous catheters is associated with pulmonary emboli in about 10% to 15% of cases (Monreal et al. 1994). The risk of upper extremity DVT in patients with implantable venous access devices is quite variable, as most are thought to be asymptomatic (De Cicco et al. 1997, Monreal et al. 1996). In a prospective randomized trial, a coumadin dose of 1 mg/day has been shown to decrease the incidence of thrombosis from 37% to 10% without increasing hemorrhagic complications (Bern et al. 1990). Subsequent trials as well as several meta-analyses have not found low-dose Coumadin to be effective and it is currently not recommended (Debourdeau et al. 2013). Catheter tip occlusion is another frequent complication. One strategy to reduce this complication is to flush the catheter regularly. In general, Hickman catheters are flushed once a day with heparinized saline (100 U heparin/1 cm^3 saline). Although PAC devices have usually been flushed once a month with heparinized saline, more recent data have shown that flushing once every 3 months is a viable option with a low rate of catheter tip thrombosis (Goldberg, pers. comm.). Routine flushing with heparinized saline has been shown to decrease thrombus formation at the catheter tip as well as catheter-related infection (Rackoff et al. 1995, Randolph et al. 1998). This may be related to the role that thrombus formation plays in facilitating catheter colonization and subsequent infection (Gilon et al. 1998).

Meticulous sterile technique should always be used when ports are accessed. Access of PAC devices should only be done with a non-coring needle, such as a Huber needle. After accessing the port and confirming venous access, the port should be flushed with 10 cm^3 of normal saline followed by 5 cm^3 of heparinized saline (100 U heparin/1 cm^3 saline). There is no universally accepted flushing regimen. Replacing heparin with saline can reduce the incidence of heparin-induced thrombocytopenia without apparent increase in catheter issues.

COMPLICATIONS

Complications secondary to central venous access can be divided into intraoperative complications and postoperative (long-term) complications. Intraoperative complications include pulmonary complications, such as pneumothorax, hemothorax, and air embolism. Intraoperative cardiovascular complications include cardiac arrhythmia, cardiac tamponade, trauma to a major vessel or the right atrium, and hemorrhage. Postoperative complications include infections of the exit site, tunnel infection, and bacteremia. Mechanical complications, such as catheter breakage, catheter migration, and catheter tip occlusions, may occur. Upper extremity venous thrombosis occurs in about 5% of cases, though rates of asymptomatic thromboses can be as high as 62% (Hsueh et al. 2003).

The most common complications of peritoneal ports are infection of the port site and inability to flush or infuse the catheter. Table 24.1 outlines the more common complications of central venous catheters as well as their management strategies.

Table 24.1 Common Complications and Management of Central Venous Catheters

Complications	Incidence	Signs and Symptoms	Management
Pneumothorax	0.5%–5%	Shortness of breath, hypoxia, chest pain, decreased breath sound on side with pneumothorax	If ≤30% pneumothorax seen on initial CXR and patient is relatively asymptomatic, repeat CXR in 4 hr, if no progression of pneumothorax and patient without symptoms, then observe. Repeat CXR in 12–24 hr. If pneumothorax enlarges or if the patient develops symptoms, then place a small pigtail catheter; see protocol below (Laronga et al. 2000). If ≤30% pneumothorax with or without hypoxia, then place a small pigtail catheter with a Heimlich valve. Patient may be discharged home after insertion of pigtail. Have patient return in 24–48 hr for a repeat inspiration/expiration CXR with the pigtail clamped. If no pneumothorax seen then pigtail can be removed. Placement of large chest tube is indicated for persistent or worsening pneumothorax.
Hemothorax	Rare	Shortness of breath, decreased breath sounds, chest pain, shoulder pain	If a hemothorax is visible on a CXR, a chest tube must be inserted to prevent a clotted hemothorax and associated restrictive pulmonary function.
Air embolism	Rare	Unstable vital signs, cardiac arrest	Air embolism is fatal only if more than 50–100 mL of air is aspirated. This is less of a risk in intubated patients since there is no negative pressure with inspiration.
Cardiac arrythmia	Common, rarely occurs postop	Palpitations, changes seen on EKG (PVCs, PACs, or right bundle branch block)	If seen during procedure, this is secondary to catheter or guide wire presence in right atrium or ventricle. Right bundle branch blocks are seen with contact of the catheter with the right side of the ventricular septum. Treatment is to pull back on wire or catheter until EKG is normal. If present postop, then catheter should be pulled back and correctly placed and positioned.
Exit site infection	3%–20%	Tenderness, erythema, and swelling at port site. Incidence of infection was thought to be higher in Hickman-type catheters; however, this was not seen in a randomized trial (Mueller et al. 1992: 11)	The most common cause of infection is Gram-positive organisms such as *Staphylococcus aureus*, *S. epidermidis*, or streptococcal species. Occasionally, Gram-negative organisms, such as *Escherichia coli*, *Pseudomonal* species, and *Klebsiella* species, may be the pathogen. Polymicrobial infections with staphylococcal and pseudomonal species can also occur. Fungal infections may occur, especially the candidal species. Rarer pathogens, such as *Rhodotorula glutinis* (a fungal species), *Chryseobacterium indologenes*, and *Pseudallescheria boydii*, have also been reported (Hsueh et al. 2003: 16, Nulens et al. 2001: 15, Perez et al. 1988: 13). Blood cultures should be obtained from the port site and a peripheral site (about 50% of infections will yield a positive culture) (Mueller et al. 1992: 11). It is important to distinguish potentially complicated from uncomplicated patients when treating port infections. Complicated patients are considered to be any patient with endocarditis, artificial heart valves, osteomyelitis, suppurative thrombophlebitis, or presence of *S. aureus* in a patient who is immunocompromised or has active malignancy. In complicated patients, the port should be removed as part of the treatment; otherwise port removal is not necessary as initial treatment (Hiemenz et al. 1986: 37, Mermel et al. 2009: 49, Olson et al. 1987: 381). Complete blood count should be obtained to ascertain the patient's granulocyte count. Initial treatment is aimed at Gram-positive species. Non-neutropenic patients should receive vancomycin (40 mg/kg/day) given through the port. Empirical coverage for Gram-negative bacilli should be based on severity of disease (4th generation cephalosporin gentamicin).

(*Continued*)

Table 24.1 (Continued) Common Complications and Management of Central Venous Catheters

Complications	Incidence	Signs and Symptoms	Management
			Neutropenic patients should receive zosyn/gent/vancomycin given through the port. Empirical therapy for suspected catheter-related candidemia should be considered in patients with the following risk factors: total parenteral nutrition, prolonged use of antibiotics, or receipt of bone marrow or solid organ transplant. Treatment with the appropriate antibiotics should be given until WBC is normal, patient is afebrile, and surveillance cultures are negative. Indications for PAC removal include (1) unresolved or worsening symptoms despite adequate antibiotic treatment; (2) persistent bacteremia after 72 hr of appropriate antibiotic therapy; (3) recurrence or persistence of positive blood culture after 14 days of appropriate antibiotic therapy and persistent fungemia.
Tunnel infection	Not distinguished from above	Induration, erythema, and tenderness over tunneled catheter	See "Treatment of exit site infection" above.
Bacteremia	Same as above	Fever, positive blood	See "Treatment of exit site infection" above.
Catheter tip occlusion	1%–22%	Inability to draw back blood or infuse chemotherapeutic agent	Initial strategies include (1) changing the patient's arm or head position; (2) having patient perform a Valsalva maneuver (in case the tip occlusion is secondary to the tip being up against the wall of the vein); (3) flushing with agent 5–10 mL normal saline; (4) flushing with 3 mL heparinized saline (300 U); (5) repeated attempts to aspirate blood. If all the above maneuvers fail, then consider thrombolytic therapy. Urokinase can be used in the following manner: 1. 5000 U of reconstituted urokinase can be given through the port. After the urokinase instillation, inject the port with 1–2 mL of heparinized saline. 2. Wait 15 min and re-attempt aspiration. 3. If this fails, then repeat the above steps twice for a total of the 15,000 U of urokinase instillation. 4. If this fails, then instill 40,000 U of urokinase into the port. 5. After 12 hr, another aspiration attempt can be performed.
Catheter fracture	Rare	Fairly rare event; most are asymptomatic and seen only on CXR obtained for inability to flush or draw from catheter (36%), pain/swelling by supraclavicular region (29%), shoulder pain (12%), palpitations (7%), pectoral swelling (5%), chest pain (5%), "swishing sound" during fluid infusion (2%)	Catheter fracture is thought to occur to secondary pinch-off syndrome fracture where the catheter has been inserted too medially and is trapped (pinched) between the clavicle and the first rib. If the catheter fractures and embolus is suspected, CXR should be obtained. Prompt removal of catheter is necessary. This can be done through a transcutaneous approach via the femoral vein.
Venous thrombosis	1.5%–62%	Progressive swelling of the arm or face Most venous thromboses are asymptomatic, incidence of venous randomized studies where venograms were routinely performed whether patient has symptoms reveal an incidence of 38%–62% Overall incidence of symptomatic thrombosis is about 5%	Overview of randomized trials recommended low-molecular-weight heparin for a minimum of 3 months. PAC may be left in place while the patient is on anticoagulation therapy as long as (1) catheter tip is in correct position, (2) catheter is functional, (3) catheter is mandatory for the patient, and (4) there are no signs of infection.

Abbreviations: CXR, chest x-ray; EKG, electrocardiogram; PAC, Port-a-Cath; PVC, premature ventricular contractions; WBC, white blood cell count.

REFERENCES

Bern MM, Lokich JJ, Wallach SR, et al. 1990. Very low doses of warfarin can prevent thrombosis in central venous catheters. A randomized prospective trial. *Ann Intern Med* **112**(6):423–8.

Bock SN, Lee RE, Fisher B, et al. 1990. A prospective randomized trial evaluating prophylactic antibiotics to prevent triple-lumen catheter-related sepsis in patients treated with immunotherapy. *J Clin Oncol* **8**(1):161–9.

Bow EJ, Kilpatrick MG, Clinch JJ. 1999. Totally implantable venous access port systems for patients receiving chemotherapy for solid tissue malignancies: A randomized controlled clinical trial examining the safety, efficacy, costs, and impact on quality of life. *J Clin Oncol* **17**(4):1267.

Broviac JW, Cole JJ, Scribner BH. 1973. A silicone rubber atrial catheter for prolonged parenteral alimentation. *Surg Gynecol Obstet* **136**(4):602–6.

Cole JJ, Dennis MB, Hickman RO, et al. 1972. Preliminary studies with the fistula catheter—A new vascular access prosthesis. *Trans Am Soc Artif Intern Organs* **18**:448–51.

Debourdeau P, Farge D, Beckers M, et al. 2013. International clinical practice guidelines for the treatment and prophylaxis of thrombosis associated with central venous catheters in patients with cancer. *J Thromb Haemost* **11**:71–80.

De Cicco M, Matovic M, Balestreri, et al. 1997. Central venous thrombosis: An early and frequent complication in cancer patients bearing long-term silastic catheter. A prospective study. *Thromb Res* **86**(2):101–13.

Ecoff L, Barone RM, Simons RM. 1983. Implantable infusion port (Port-A-Cath). *NITA* **6**:406–8.

Gilon D, Schectes D, Rein AJ, et al. 1998. Right atrial thrombi are related to indwelling central venous catheter position: Insights into time course and possible mechanism of formation. *Am Heart J* **135**(3):457–62.

Henrickson KJ, Axtell RA, Hoover SM, et al. 2000. Prevention of central venous catheter-related infections and thrombotic events in immunocompromised children by the use of vancomycin/ciprofloxacin/heparin flush solution: A randomized, multicenter, double-blind trial. *J Clin Oncol* **18**(6):1269–78.

Hickman RO, Buckner CD, Clift RA, et al. 1979. A modified right atrial catheter for access to the venous system in marrow transplant recipients. *Surg Gynecol Obstet* **148**:871–5.

HICPAC (Hospital Infection Control Practices Advisory Committee). 1995. Recommendations for preventing the spread of vancomycin resistance. *Infect Control Hosp Epidemiol* **16**:105–13.

Hiemenz J, Skelton J, Pizzo PA. 1986. Perspective on the management of catheter-related infections in cancer patients. *Pediatr Infect Dis* **5**:6–11.

Hsueh PR, Teng LJ, Ho SW, et al. 2003. Catheter-related sepsis due to *Rhodotorula glutinis*. *J Clin Microbiol* **41**(2):857–9.

Knebel P, Lopez-Benitez R, Fischer L, et al. 2011. Insertion of totally implantable venous access devices: An expertise-based, randomized, controlled trial (NCT00600444). *Ann Surg* **253**:1111–17.

Laronga C, Meric F, Truong MT, et al. 2000. A treatment algorithm for pneumothoraces complicating central venous catheter insertion. *Am J Surg* **180**(6):523–6 [discussion 526–7].

Mermel LA, Allon M, Bouza E, et al. 2009. Clinical practice guidelines for the diagnosis and management of intravascular catheter-related infection: 2009 Update by the Infectious Diseases Society of America. *Clin Infect Dis* **49**(1):1–45.

Monreal M, Alastrue A, Rull M, et al. 1996. Upper extremity deep venous thrombosis in cancer patients with venous access devices—Prophylaxis with a low molecular weight heparin (Fragmin). *Thromb Haemost* **75**(2):251–3.

Monreal M, Raventos A, Lerma R, et al. 1994. Pulmonary embolism in patients with upper extremity DVT associated to venous central lines—A prospective study. *Thromb Haemost* **72**(4):548–50.

Mueller BU, Skelton J, Callender DP, et al. 1992. A prospective randomized trial comparing the infectious and noninfectious complications of an externalized catheter versus a subcutaneously implanted device in cancer patients. *J Clin Oncol* **10**(12):1943–8.

Nulens E, Bussels B, Bols A, et al. 2001. Recurrent bacteremia by *Chryseobacterium indologenes* in an oncology patient with a totally implanted intravascular device. *Clin Microbiol Infect* **7**(7):391–3.

Olson TA, Fisher GW, Lupo MC, et al. 1987. Antimicrobial therapy of Broviac catheter infections in pediatric hematology oncology patients. *J Pediatr Surg* **22**(9):839–42.

Perez RE, Smith M, McClendon J, et al. 1988. *Pseudallescheria boydii* brain abscess. Complication of an intravenous catheter. *Am J Med* **84**(2):359–62.

Raad II, Hachem RY, Abi-Said D, et al. 1998. A prospective crossover randomized trial of novobiocin and rifampin prophylaxis for the prevention of intravascular catheter infections in cancer patients treated with interleukin-2. *Cancer* **82**(2):403–11.

Rackoff WR, Weiman M, Jakobowski D, et al. 1995. A randomized, controlled trial of the efficacy of a heparin and vancomycin solution in preventing central venous catheter infections in children. *J Pediatr* **127**(1):147–51.

Randolph AG, Cook DJ, Gonzales CA, et al. 1998. Benefit of heparin in central venous and pulmonary artery catheters: A meta-analysis of randomized controlled trials. *Chest* **113**(1):165–71.

Schuster M, Nave H, Piepenbrock S, et al. 2000. The carina as a landmark in central venous catheter placement. *Br J Anaesth* **85**:192–4.

van de Wetering MD, van Woensel JBM. 2007. Prophylactic antibiotics for preventing early central venous catheter Gram positive infections in oncology patients. *Cochrane Database Sys Rev* **1**: CD003295. DOI: 10.1002/14651858.CD003295.pub2.

25 Surgical management of trophoblastic disease

Srdjan Saso, Krishen Sieunarine, Benjamin P. Jones, Joseph Yazbek, Michael J. Seckl, and J. Richard Smith

MANAGEMENT OF TROPHOBLASTIC DISEASE: THE BASICS

Gestational trophoblastic disease (GTD) is a general term used to describe a spectrum of disease ranging from the premalignant complete, partial hydatidiform moles through to the malignant invasive moles, choriocarcinomas and placental-site trophoblastic tumors (PSTTs)/epithelioid trophoblastic tumors (ETTs) (Seckl et al. 2010). The latter malignant conditions are also collectively known as gestational trophoblastic tumors or neoplasia (GTN). Management of trophoblastic disease in the first instance involves evacuation of the uterus. This should always be done using a suction curette and preferably with the help of ultrasound guidance. In the presence of persistently elevated human chorionic gonadotrophin (hCG) levels or continuing problems with hemorrhage, further evacuation may be necessary. This should normally be discussed with a GTD center because of the high risk of perforation, hemorrhage, or infection. Thereafter, if the hCG levels remain elevated, chemotherapy should be instituted. The vast majority of patients will respond to these measures due to the inherent chemosensitivity of GTD. Chemotherapy produces high cure rates while maintaining fertility, allowing women to have further pregnancies.

For the small minority whose hCG levels remain elevated following chemotherapy, more definitive surgical management may be required in the form of a total abdominal hysterectomy. Elevated hCG levels predispose to ovarian cyst formation, but this should not encourage bilateral oophorectomy at the time of the hysterectomy unless there is another pre-existing reason. Total abdominal hysterectomy in the presence of choriocarcinoma can prove very taxing. Uterine vascularity may be massively increased, presumably owing to the action of vasoactive peptides, and the uterine arteries may be up to 1 cm in diameter. More troublesome still is the massive enlargement of the uterine venous plexus. This can lead to hemorrhage during ureteric dissection, particularly in cases where the tumor has spread beyond the uterus into the parametrium.

Preoperative assessment should include Doppler flow ultrasonography of the pelvis, CT and/or MRI scans of the chest, abdomen, and pelvis, and an MRI of the head, together with hCG, full blood count, and blood biochemistry measurements. GTD always produce hCG which allows screening and monitors treatment and follow-up. Four to six units of blood should be cross-matched. The authors have sometimes found it useful in the presence of extrauterine spread to perform ureteric stenting (see Chapter 6). The laparotomy is performed, generally via a Pfannenstiel incision, but may require Cherney muscle cutting or a midline incision, depending on the surgeon's preference and the size of the uterus. In the presence of huge vessels, the authors have found it helpful to commence the procedure by opening the broad ligament, identifying the ureter and dissecting it in a cephalad direction as far as the bifurcation of the common iliac artery. Vascular elastic slings can be placed around the internal iliac vessels (Figure 25.1). These vessels can be temporarily ligated prophylactically using bulldog surgical clips or the slings left loose until the need arises.

These slings have proved useful to the authors in the face of the torrential hemorrhage which may arise. Dissection of the internal iliac arteries then takes place inferiorly until the origins of the uterine arteries are identified, skeletonized, and ligated using either polyglactin ties or surgical clips. The ureter is identified running under the uterine artery. The multiple uterine vessels are ligated by applying three surgical clips to each vessel and transecting the vessel between them, leaving two proximally (inset in Figure 25.1). In general, the ureteric canal does not need to be opened; however, if the need arises, this should be done as described in Chapter 18. If PSTT is suspected, removal of pelvic lymph nodes and para-aortic lymph nodes is advisable for gross lymph node disease involvement.

Excessive uterine manipulation should be avoided during the surgery when possible so as to reduce any possible risk of embolization of trophoblastic tissue. Because these patients may be hemodynamically unstable, it is recommended that these procedures be carried out by an experienced surgical team at a specialized center providing full medical support, including intensive care.

PLACENTAL SITE TROPHOBLASTIC TUMORS

PSTT is a very rare form of GTD. Previously termed "trophoblastic pseudotumor," PSTT was first recognized as a separate entity to other GTDs in 1976. This atypical variant of GTD is associated with a 20% mortality rate, and was renamed as PSTT in 1981. The revised nomenclature was due to the disease's apparent late-onset aggressive nature, its unpredictable malignant potential, and its relative resistance to standard trophoblastic disease chemotherapy (Lathrop et al. 1988). PSTT is further set apart from other forms of GTD because of its characteristically low β-hCG levels caused by the neoplastic proliferation of intermediate trophoblastic cells (Kim 2003).

PSTT can occur following a full-term delivery or miscarriage, and less commonly arises following a hydatidiform molar pregnancy. The time from the index pregnancy to diagnosis is variable and can be up to several years. PSTT is a malignant tumor derived from fetal tissue and histologically comprised of intermediate trophoblasts, cells which usually play a vital role in implantation by migrating to the basal plate and invading the spiral arteries. The risk factors for PSTT are not well understood, with limited data currently available on the genetics of PSTT (Seckl et al. 2010).

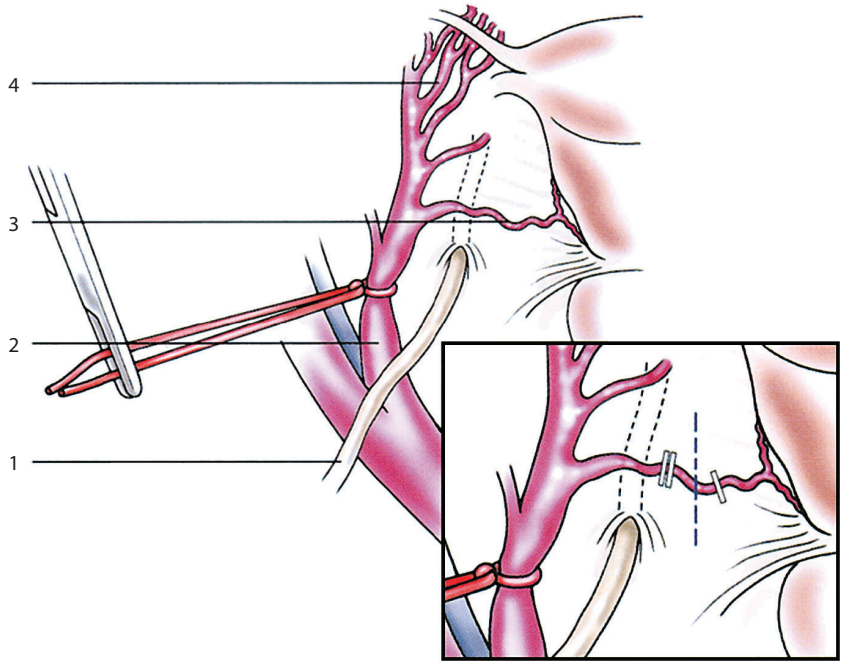

Figure 25.1 Vascular elastic slings are placed around the internal iliac vessels in the case of hemorrhage. (Inset) Ligation of the uterine artery (incision marked by dotted line): 1: Ureter; 2: internal iliac vessels; 3: uterine artery; 4: superior vesical arteries.

The gross pathology presents as a well localized, ill-defined, slowly-growing myometrial mass, with a late-onset invasive/metastatic tendency to penetrate deeper into the uterine wall. PSTT is commonly confined to the uterus. However, it does have a potential to infiltrate adjacent organs, the most common sites of metastases being the pelvis, lymph nodes, and lungs. With regard to outcomes, various prognostic factors have been proposed to be important including stage, number of mitosis, depth of myometrial invasion, size of primary, hCG level, and duration from the antecedent pregnancy. A recent analysis of the UK PSTT series has shown that the most important and only factor to remain significant on multivariate analysis is the duration to clinical presentation from the antecedent pregnancy. Thus 98% of women were cured if they presented within 4 years, while all 13 women presenting beyond this time eventually succumbed from their disease regardless of disease stage or hCG levels (Schmid et al. 2009).

The information available on the frequency of PSTT, optimal management, long-term outcome, and prognostic parameters is very sparse. In the United Kingdom, patients with GTD are registered and treated centrally. Between 1976 and 2006, 35,550 patients with GTD were diagnosed and registered, of which 62 were diagnosed with PSTT, accounting for approximately 0.2% of all GTD. Despite this, estimated data is not available to accurately determine the true frequency of PSTT as a proportion of GTD (Ngan et al. 2003). In previous years, there would undoubtedly have been underdiagnosis of PSTT.

MANAGEMENT

The rarity of PSTT along with its unpredictable biological behavior and reduced chemosensitivity means that optimum management is difficult to plan. Preservation of fertility is paramount, as the disease affects women of childbearing age primarily. In trophoblastic disease, total abdominal hysterectomy (TAH) is rarely required. However, in the management of relatively chemoresistant disease such as PSTT, standard management of choice is pelvic lymphadenectomy and TAH/radical hysterectomy, depending upon the position of the tumor—those with cervical involvement requiring a more radical approach.

In the 13-year period from 1993 to 2006, 25 cases were referred to the Chelsea and Westminster Hospital and the West London Gynaecological Cancer Centre from Charing Cross Hospital (London center for GTD) for some form of hysterectomy for GTD (Sieunarine et al. 2003). These 25 cases who underwent hysterectomy were drawn from 11,213 women who were registered at Charing Cross Centre for Trophoblastic Disease over that period of time. However, in addition to the cases referred to the authors, other cases will have been referred back to referring surgeons, and it is therefore not possible to give the percentage of overall patients who have required surgery. Many centers have published their experience in the management of GTD by hysterectomy, with an incidence ranging from 1.5% to 35%.

In our group of 25 cases, 9 (36%) were choriocarcinomas, 6 (24%) were PSTT, and 10 (40%) were hydatidiform moles. The two main reasons for referral for surgical management were chemoresistance of the tumor during the initial treatment episode and relapse after treatment. Of the 25, 9 (36%) women had lymph node sampling. Of the 25, 11 (44%) had bilateral salpingo-oophorectomy concurrently. A radical hysterectomy ± unilateral parametrectomy were required in 3 of 25 (12%) women.

Despite having a hysterectomy followed by chemotherapy, 3 of 25 (12%) of these women failed to survive. All were in the high-risk metastatic group. Their poor outcome was unrelated to the surgery but because of chemoresistant metastatic disease outside the pelvis. The review concluded that surgical management of primary drug resistant and relapse cases of GTD in the

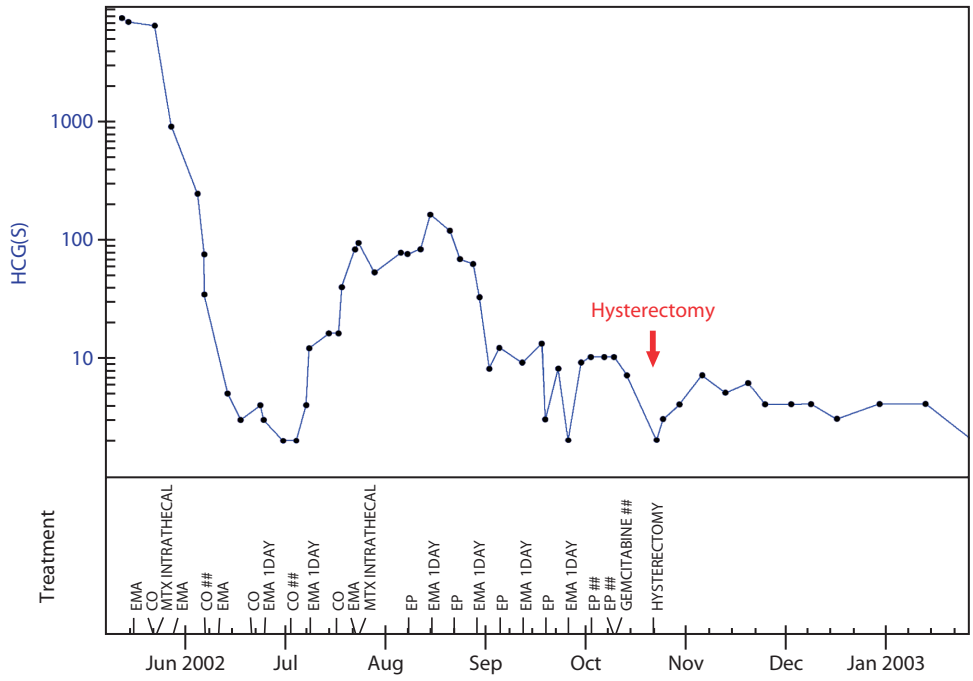

Figure 25.2 Therapeutic benefits of a hysterectomy in the management of chemoresistant GTD localized to the uterus.

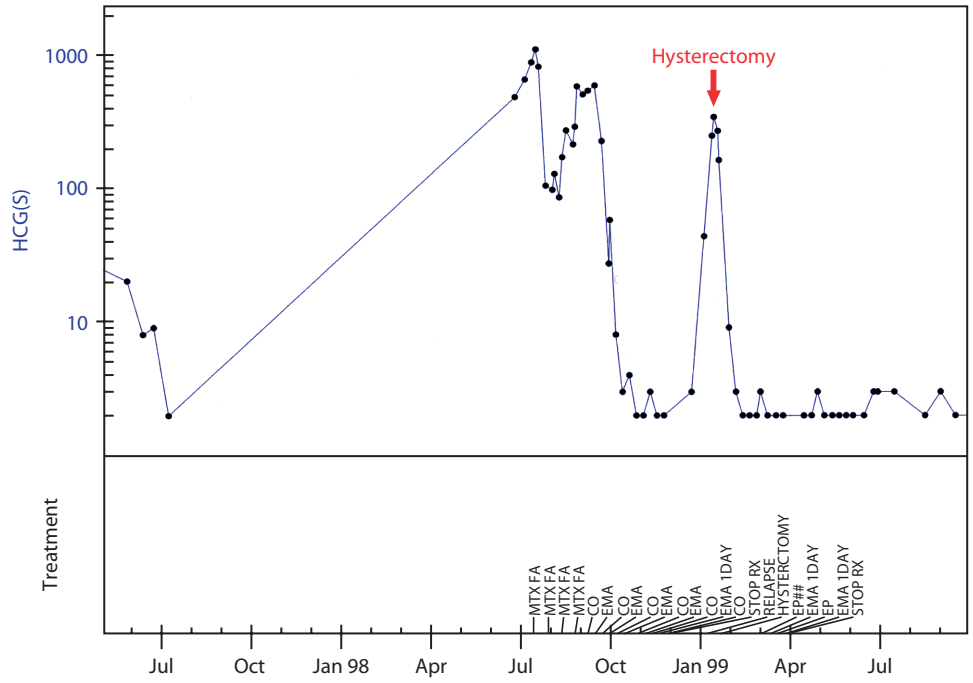

Figure 25.3 Therapeutic benefit of a hysterectomy during relapse of a GTT.

form of a hysterectomy is a useful and safe adjunct to chemotherapy and has a satisfactory long-term outcome.

Figure 25.2 illustrates the therapeutic benefit of a hysterectomy using serum ßhCG levels in the management of chemoresistant GTD which is localized to the uterus. Figure 25.3 illustrates the therapeutic benefit of a hysterectomy during relapse of a gestational trophoblastic tumor.

FERTILITY PRESERVATION

Conservative therapy by combination chemotherapy without hysterectomy is a possible alternative for patients with metastatic disease desiring future fertility, as chemotherapeutic regimes have improved. However, because PSTT is typically less sensitive to chemotherapy despite intensive multimodal therapy, local uterine resection could be considered if a patient wanted to preserve her fertility (Kim 2003). This is known as fertility-sparing surgery and takes the form of a modified Strausmann procedure (MSP). The hoped-for benefit of MSP is to remove the tumor while preserving the woman's fertility, and thus allow for childbearing in future. The patient should be aware that no alternative fertility-sparing approach exists. MSP is thus tried as an alternative to a hysterectomy.

MSP is partly based on ideas relating to pelvic vasculature obtained from another fertility-sparing technique, abdominal radical trachelectomy (ART). The temporary occlusion of the uterine arterial supply allows the isolation of the uterus. The uterine arteries are temporarily ligated either with vascular slings round the uterine artery, close to the anterior division of the internal iliac artery, or by bulldog clipping. To achieve this, the broad ligament requires to be opened. This can be done by dividing the round ligaments, incising the posterior peritoneal leaf of the broad ligament, and identifying the ureter, internal iliac, and uterine vessel at its origin. This can then be ligated temporarily with a vascular sling. At the end of the procedure, the sling can be removed, round ligament re-sutured, and broad ligament closed to prevent herniation of the bowel. Alternatively, one can preserve the round ligament and open the broad ligament, including the paravesical and pararectal spaces. A bulldog clip can then be placed on the ascending branch of the uterine artery. In addition, bulldog clips can be placed across the ovarian ligament, or if this proves difficult to isolate, across the arteries and veins. The former is preferable since the ovary is not isolated from its blood supply and is therefore less likely to suffer ischemic damage. Note should be taken of the length of time that the uterus is isolated from its blood supply. The authors have not experienced any problems with this technique utilized for up to 1 hour. The third method is via placement of a Foley catheter, incorporating the uterine arteries ± ovarian vessels. This involves feeding a catheter under the round ligament through perforations created in the peritoneum. Diathermy and transillumination allows avoidance of vessels.

The abnormality is subsequently identified and using cutting diathermy, an incision is made at a distance of 1 cm from the lesion. This incision is generally full thickness through to the uterine cavity and may even involve hemisection of the uterus. This then allows excision with a margin around the nodule. The uterus is reconstructed, using a number of different suture materials for the respective uterine layers: vicryl 3-0 to the endometrium, vicryl 2-0 to the myometrium, and PDS 3-0 to the serosa. TAH is carried out 2 weeks post-procedure in the event of unclear margins or positive lymph nodes.

Over the last 3 years, the authors have attempted this on five occasions (Saso et al. 2012a). All five patients were referred to the Trophoblastic Tumor Screening and Treatment Centre (Charing Cross Hospital, London) between 2007 and 2010. The two main reasons for referral were a solitary uterine focus (presumed to be a type of GTD) on ultrasound scan (USS) and a persistently elevated β-hCG.

To date, there has been one long-term success. The other four patients have all had completion hysterectomy. Three of the four patients who had completion hysterectomy had it within a fortnight; one had no residual disease in the uterus and the other three did. The 20% success rate provides some indication that the procedure, with further focused development, may give the patient a prospect of future fertility, particularly when relating to our final successful case where we utilized frozen section analysis intraoperatively with a highly experienced gestational trophoblastic disease pathologist. Although fertility-sparing surgery is not appropriate in all cases, it is recognized as standard management for other gynecological malignancies. An example of this is performing a large loop excision of the transformation zone to treat stage IA squamous cell cervical carcinoma and ART for stage IB cervical cancers.

Our one successful case demonstrated regular menses postoperatively, allowing us to assume that the patient's reproductive function had returned to normal. This was confirmed by subsequent pregnancies. The patient miscarried twice (at gestational age of 7 weeks), followed by a termination of pregnancy at 17 weeks secondary to trisomy 21. However, the fourth pregnancy post-MSP resulted in a symmetrically well-grown, healthy, term baby, weighing 3.2 kg and delivered via caesarean section at 38 weeks. The placenta was not adherent to the MSP scar. Conception was natural. The gestational and interpartum periods were uneventful (Saso et al. 2012b).

If MSP is offered to a patient, the limitations must be included when discussing management options. First, our success rate is low (20%) with the rest all undergoing TAH within 2 weeks of MSP. Second, the surgical process may be viewed as unnecessary, creating a sense of false hope and prolonging the acceptance of permanent infertility. Third, theoretically the opening of the uterus can result in tumor seeding. Finally, with regard to achieving competency at performing a MSP, the relative novelty of the technique along with the low success rate may lead to poor uptake among gynecologists in considering this approach.

Several factors may explain the high failure rate. First, MSP is limited when dealing with the occult and multifocal nature of the disease because of its limited resection approach. Second, histopathology of the focal uterine resection is fraught with difficulty: (a) diffuse disease may be missed, and (b) the fact that two patients had complete excisions demonstrates the difficulties of performing histopathology on electrodiathermied biopsies. In addition, it may not be possible to define a "safe" distance free margin in terms of single cells. Such a distance would depend on whether a knife or cutting diathermy (with consequent cautery damage) is applied. A cold knife may be used in future with intraoperative frozen section analysis (as with the last case) and a ≥5-mm safe distance to perhaps avoid the pathological concerns of residual disease. Finally, imaging modalities (Doppler USS, MRI, CT) may be excellent at detecting the main uterine lesion but not all the other metastatic disease sites within the uterus (Saso et al. 2012a).

The reliability of frozen section assessment of margins at centers with non-expert GTD pathologists has often been queried. PSTT should not be removed at centers with non-expert GTD pathologists, unless by accident; i.e., where the diagnosis was not known at the time of surgery. In paraffin-embedded sections, the distinction between PSTT cells and myometrial cells is fairly straightforward, but even with the highest quality of frozen section it may not be possible to decide. Experiments with other stains such as Toluidine blue have been tried, but with no diagnostic advantage. The involvement by PSTT on frozen section has only been confirmed in our cases because of a sheet-like growth pattern rather than the single cells. ETTs are far easier in that respect, since their growth pattern is pseudoacinar and involvement of myometrium and extrauterine involvement on frozen sections can be concluded upon with confidence.

CONCLUSION

TAH for trophoblastic disease is rarely required. It may be required for the management of excessive uterine bleeding either at presentation or after the onset of chemotherapy and in the management of chemoresistant disease localized to the pelvis. It is the treatment of choice in the management of PSTTs confined to the uterus. When it is being performed, problems with hemorrhage should be anticipated and the suggested prophylactic measures should make uncontrollable hemorrhage less likely. Management of metastatic choriocarcinoma outside the area of gynecological competence—for example, in the thorax or brain—is beyond the scope of this book, but such tumors may well be amenable to management by the appropriate surgeon.

Fertility preservation may be offered in the form of MSP. It consists of temporary arterial occlusion to isolate the uterus, allowing resection of the primary PSTT lesion, followed by uterine manipulation and reconstruction, and therefore ultimately fertility preservation. Because of the high failure rate of MSP as a fertility-sparing procedure, the management of patients with localized PSTT wishing to retain their fertility is open to debate (Sieunarine et al. 2003). These patients need extensive counseling, with attention paid to issues related to PSTT, its potential to be multifocal in nature, and low success rates of MSP. If the patient understands and accepts the concerns raised, then it should be acceptable to proceed. The patient should also be aware of other "fertility" options available to her in case of hysterectomy—mainly surrogacy and adoption.

Therefore, fertility-preserving surgery could be a necessary addition when counseling a PSTT patient regarding her treatment options in the case of presumed unifocal disease. This unique form of GTD primarily presents in women of reproductive age and therefore the importance of considering fertility must be emphasized. The decision to preserve fertility is ultimately based on the patient's wishes, and her decision should be made independently following appropriate counseling and consultation with her family.

REFERENCES

Kim SJ. 2003. Placental site trophoblastic tumour. *Best Pract Res Clin Obstet Gynaecol* **17**:969–84.

Lathrop JC, Lauchlan S, Nayak R, Ambler M. 1988. Clinical characteristics of placental site trophoblastic tumor. *Gynecol Oncol* **31**:32–42.

Ngan HYS, Odicino F, Maisonneuve P, et al. 2003. Gestational trophoblastic diseases. *J Epidemiol Biostat* **6**:175–84.

Saso S, Haddad J, Ellis P, et al. 2012a. Placental site trophoblastic tumours and the concept of fertility preservation. *BJOG* **119**:369–74.

Saso S, Chatterjee J, Yazbek J, et al. 2012b. A case of pregnancy following a modified Strassman procedure applied to treat a placental site trophoblastic tumour. *BJOG* **119**(13):1665–7.

Schmid P, Nagai Y, Agarwal R, et al. 2009. Prognostic markers and long-term outcome of placental-site trophoblastic tumours: A retrospective observational study. *Lancet* **374**:48–55.

Seckl MJ, Sebire NJ, Berkowitz RS. 2010. Gestational trophoblastic disease. *Lancet* **376**:717–29.

Sieunarine K, Rees H, Seckl M, et al. 2003. A review of the surgical management of gestational trophoblastic tumours from March 1993 to October 2003. 2003. *British Gynaecological Cancer Society Annual Meeting*, UK, vol. 22, pp. 45–61.

26 Laparoscopy

Farr Nezhat, Carmel Cohen, and Nimesh P. Nagarsheth

INTRODUCTION

The spectrum of surgical procedures being adapted to a laparoscopic approach continues to expand and encompass traditional operations used for cancer staging. This chapter describes the procedures of appendectomy, hysterectomy (both standard and radical), omentectomy, palliative end colostomy, and lymphadenectomy (encompassing both para-aortic and pelvic lymph nodes).

APPENDECTOMY

Since the first use of laparoscopy for appendectomy by Kurt Semms in Germany and Nezhat and others in the United States in the 1980s and early 1990s, this procedure has become widely accepted.

Two different techniques have been utilized for laparoscopic appendectomy: one uses sutures, harmonic shears, or bipolar electrodessication for severing the appendiceal blood vessels; the other uses a linear stapling device across the mesoappendix and appendix simultaneously.

Indications

Appendectomy is frequently performed incidentally in association with other pelvic surgical procedures, or whenever pathological changes are identified, as in patients with infection, endometriosis, or benign or malignant tumors. In the staging and evaluation of certain ovarian tumors (such as mucinous borderline tumor or mucinous cystadenocarcinoma), the appendix is removed due to the high association of mucinous appendiceal tumors.

Anatomic Considerations

The appendix is an elongated vestigial diverticulum of the cecum, which is richly endowed with lymphoid tissue. It is normally 7 to 10 cm in length but lengths up to 30 cm have been recorded. It receives blood supply from the appendicular artery, which is a branch of the lower division of the ileocecal artery. An accessory appendicular artery may be present in almost 50% of patients. The major vessels enter the mesoappendix a short distance from the base of the appendix. The location of the appendix is variable; up to 70% will be retrocecal and the remainder present primarily in front of the large bowel. Although it is usually found in the right iliac fossa, in maldescent of the cecum or advanced pregnancy the appendix may be seated in the right hypochondrium. In rare conditions, such as situs inversus, the appendix is in the left iliac fossa.

Surgical Procedure

1. Trocar and cannula placement: the primary trocar is placed infraumbilically for introduction of the video laparoscope. Two 5-mm secondary punctures are made lateral to the inferior epigastric vessels, one on the right and one on the left at the level of the iliac crest, and a 10-mm (or 12 mm if a linear stapling device is being used) puncture is made suprapubically 5 cm above the symphysis pubis.
2. After thorough evaluation of the abdominopelvic cavity, any periappendiceal adhesions or attachments are lysed and the appendix is mobilized.
3. While the appendix is being elevated and put on traction, bipolar electrodesiccation is applied to the base of the mesoappendix for hemostasis of the appendiceal vessels (Figure 26.1). After adequate desiccation, the mesoappendix is cut using sharp or electrosurgical scissors until the base of the appendix is reached. Caution should be exercised to avoid thermal injury to the cecum or the ileum.
4. Next, the base of the appendix is ligated by applying two polydioxal or chromic Endoloop sutures (Ethicon Endosurgery, Somerville, New Jersey, USA). The third Endoloop suture is applied 5 mm distal to the first two sutures. The appendix is cut between the two sets of sutures (Figure 26.2). Alternatively, suturing is used for ligation of the appendiceal artery. An opening is made in the mesentery near the base of the appendix and a ligature of polyglactin is introduced into the opening. One ligature is tied around the base of the mesosalpinx and another is tied on the base of the appendix. Similar sutures are placed on the specimen side, and the appendix and mesoappendix are subsequently cut using sharp scissors (Figures 26.3 and 26.4). A linear stapling device can be directly applied across the mesoappendix and the appendix, speeding up the procedure (Figure 26.5).
5. After removal of the appendix, the abdominoperitoneal cavity is thoroughly irrigated. The appendix is removed through the 10- or 12-mm suprapubic trocar sleeve using Babcock forceps or by putting the appendix in a laparoscopic bag.

HYSTERECTOMY

Hysterectomy is one of the most frequently performed major surgical procedures in women. Approximately two-thirds of hysterectomies are performed abdominally and one-third vaginally. The purpose of laparoscopic surgery for hysterectomy is to avoid the adverse effects of laparotomy, maintain the principles of oncologic surgery, and offer the advantages of a vaginal approach. Since its introduction in the late 1980s, numerous variants have been developed, described by terms such as "laparoscopically assisted vaginal hysterectomy," "laparoscopic hysterectomy," or "total laparoscopic hysterectomy." While there

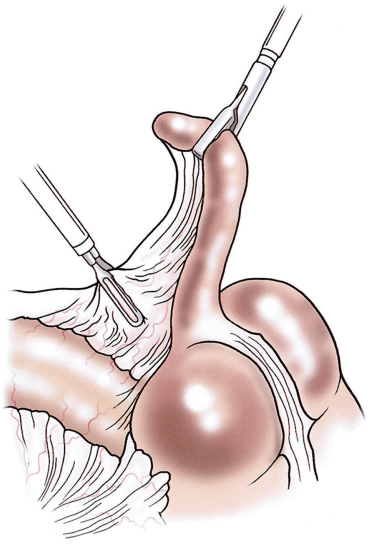

Figure 26.1 Bipolar electrodesiccation is applied to the base of the mesoappendix.

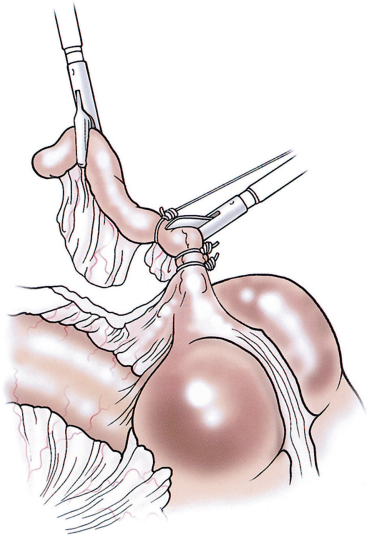

Figure 26.2 The appendix is cut between the sutures.

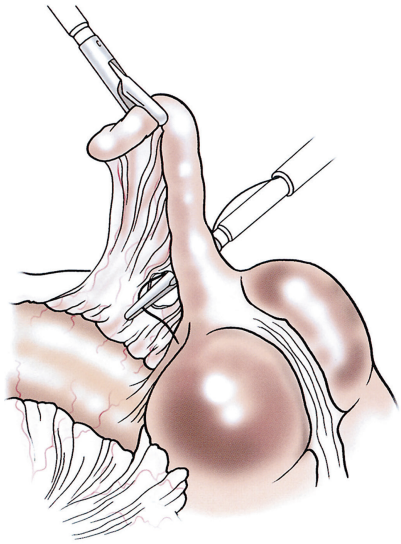

Figure 26.3 Ligatures are tied around the base of the appendix.



Figure 26.4 The appendix and mesoappendix are cut.

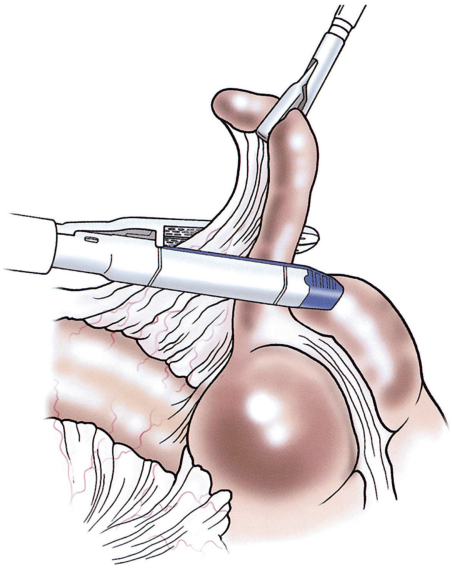

Figure 26.5 Linear stapling device.

may be technical differences and different skill requirements between the various laparoscopic procedures, there is no significant difference in postoperative pain, recovery, complications, or cost. In this chapter, total simple laparoscopic hysterectomy and radical hysterectomy are described.

In gynecologic oncology, hysterectomy has been performed either as part of the treatment and staging of endometrial, ovarian, or fallopian tube carcinoma, in the form of intra- or extrafascial hysterectomy, or as radical hysterectomy for treatment of cervical and occasionally vaginal cancer.

Anatomic Considerations

The blood supply of the uterus is from the uterine artery, which anastomoses with the ovarian and vaginal arteries. The nerve supply is from the urogenital plexus.

Surgical Procedure

1. Trocar placement: as well as the primary intraumbilical trocar sleeve which is used for introduction of the video laparoscope, three other low abdominal trocar sleeves are introduced for the passage of the ancillary instruments. For hemostasis, bipolar electrodesiccation with a vessel sealing device is currently favored; suturing or the ultrasonic harmonic scalpel may also be used. For cutting, sharp or electrosurgical scissors or lasers are commonly used.
2. After the anatomy of the pelvis is evaluated and any associated procedures (such as treatment of pelvic adhesions or endometriosis, or peritoneal biopsy) are performed, hysterectomy and salpingo-oophorectomy proceed as follows. If oophorectomy is planned, first the infundibulopelvic ligament blood supply is severed using bipolar electrodesiccation or a stapling device. The direction of the ureter crossing the pelvic brim over the bifurcation of the common iliac artery should be identified. In these patients, the ureter can often be visualized, observed for peristalsis, and avoided without mobilization. In obese patients, specific dissection may be required to identify and thus avoid injury to the ureter. Retroperitoneal or intraperitoneal ureteral dissection should be performed when there are severe adhesions or tumor involvement between the ovary and the pelvic sidewall. The adnexa should be grasped with the forceps and retracted medially and caudally to stretch and outline the infundibulopelvic ligaments before application of the bipolar vessel sealing device (Figure 26.6).
3. The round ligament is transected (Figure 26.7) or electrodesiccated approximately 4 to 5 cm lateral to the uterus, and the anterior leaf of the broad ligament is dissected using blunt, sharp, or hydrodissection. The bladder is separated from the lower uterine segment and cervix (Figures 26.8 and 26.9). These steps are accomplished bilaterally. When ovarian preservation is desired, we routinely remove the fallopian tubes during hysterectomy.

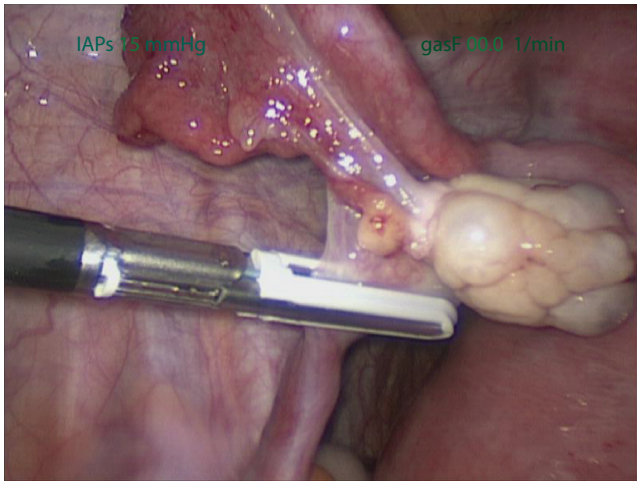

Figure 26.6 The bipolar vessel sealing device is applied to the infundibulopelvic ligaments.



(**A**)

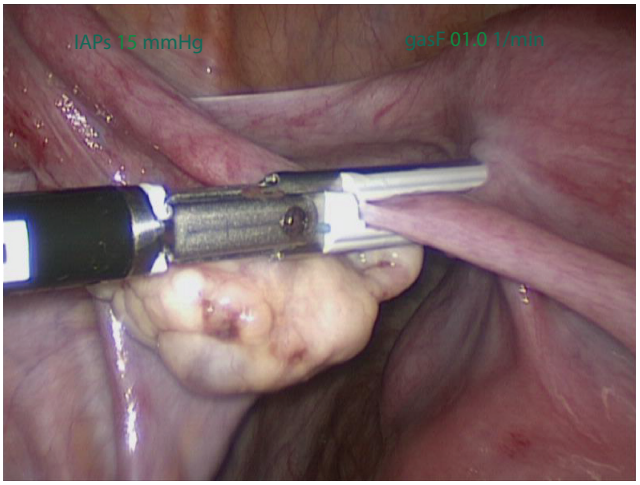

(**B**)

Figure 26.7 (**A**) The bipolar vessel sealing device is used to ligate and divide the mesosalpinx and utero-ovarian ligament. The ovary is preserved. (**B**) For patients that may desire preservation of the fallopian tube and ovary, the bipolar vessel sealing device is used to ligate and divide the proximal portion of fallopian tube and utero-ovarian ligament. The fallopian tube and ovary are preserved.

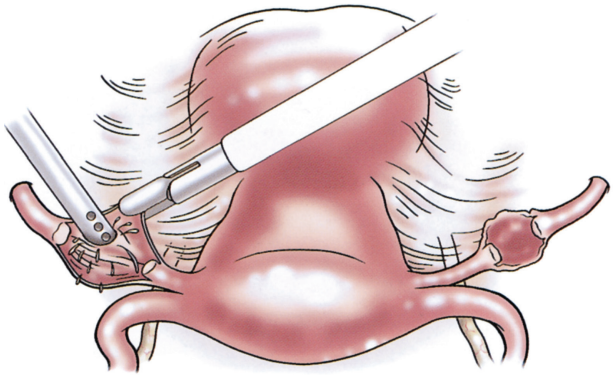

Figure 26.8 The anterior leaf of the broad ligament is dissected.

4. While the assistant retracts the uterus to one side using an intrauterine manipulator, the uterine blood supply is skeletonized and severed, using bipolar electrodesiccation or a linear stapling device (Figure 26.10).

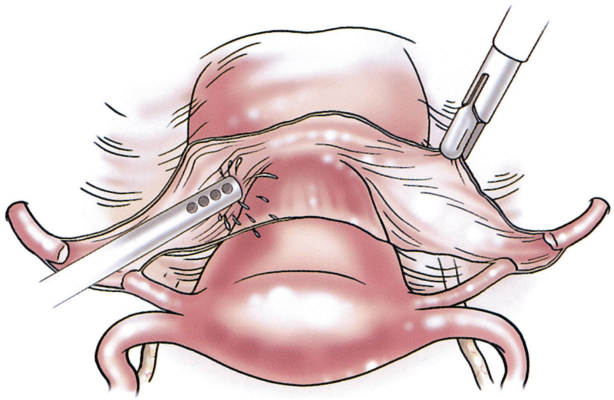

Figure 26.9 Hydrodessication of the bladder.

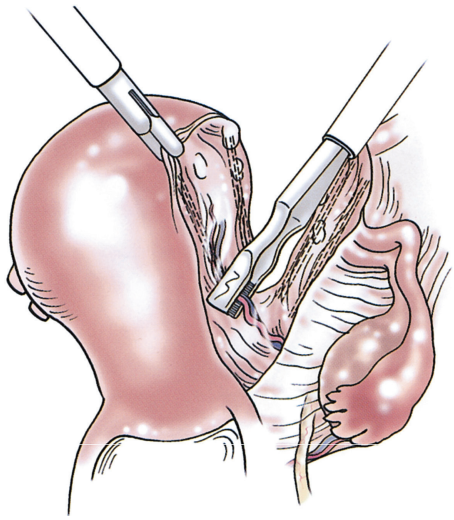

Figure 26.10 Uterine vessel dessication.

5. The direction of the ureters should be further identified and dissected laterally, especially for an extrafascial hysterectomy. The bladder is dissected away completely from the cervix and slightly from the upper vagina. The cardinal and uterosacral ligaments are electrodesiccated and cut or stapled (Figure 26.11). For the culdotomy, a colpotomy cup (typically

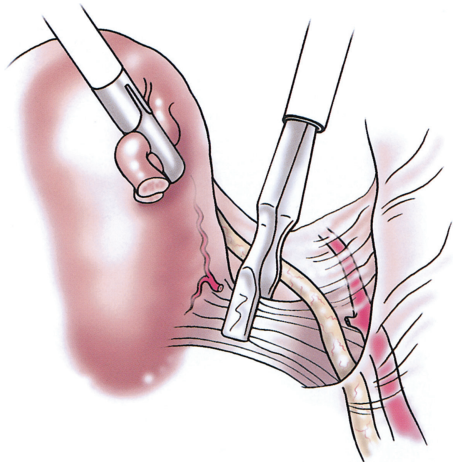

Figure 26.11 The cardinal and uterosacral ligaments are electrodessicated.

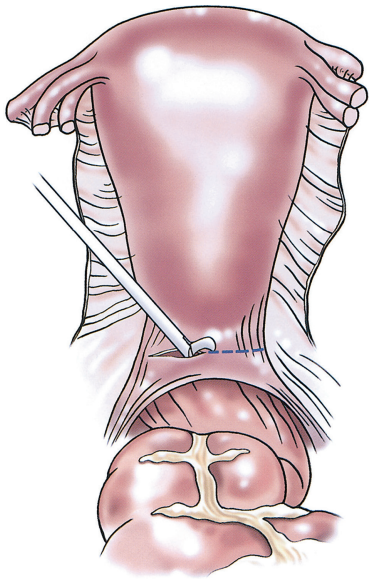

Figure 26.12 Marking the posterior vaginal cuff and performing posterior culdotomy.

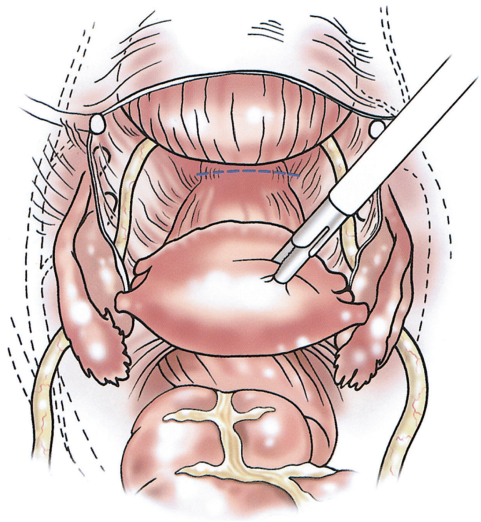

Figure 26.13 Anterior culdotomy. Anterior vagina is distended by placing sponge forceps attached to a 10 cm × 10 cm gauze transvaginally.

part of the uterine manipulator) or moistened gauze on a sponge stick is used to mark the vagina cuff (Figure 26.12). The vaginal wall is thus clearly demonstrated, allowing horizontal transection with the cutting instrument. The uterus should be positioned anteriorly for a posterior culdotomy and posteriorly for anterior culdotomy (Figures 26.13 and 26.14). The remaining attachment of the uterus laterally is circumferentially dissected, and after the uterus is completely freed it is removed vaginally by introducing a tenaculum through the vaginal vault to grasp the cervix, or to pull the uterus out with the previously attached elevator (Figure 26.15).

6. Vaginal vault closure and support: the vaginal vault can be closed either laparoscopically or transvaginally. In a laparoscopic approach to prevent loss of pneumoperitoneum, either the uterus or a partially

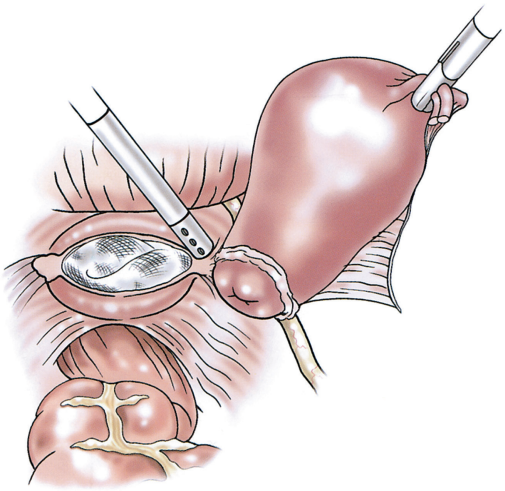

Figure 26.14 Detachment of uterus from vaginal cuff.

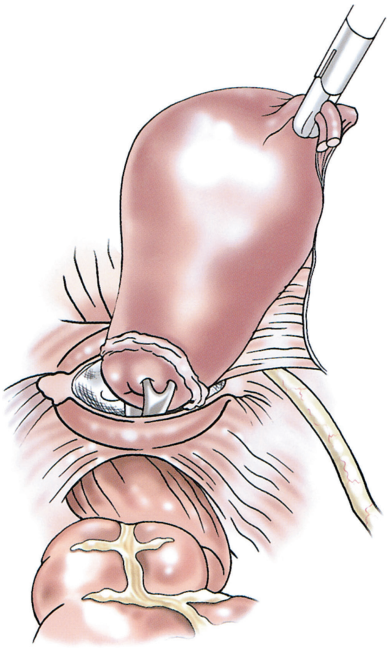

Figure 26.15 The uterus is removed transvaginally.

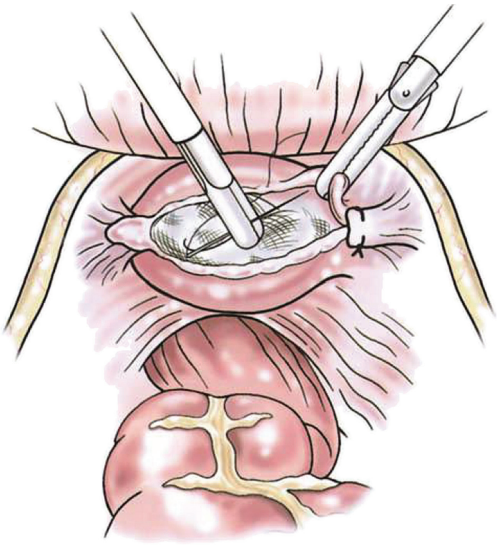

Figure 26.16 The vaginal cuff is closed in the middle.

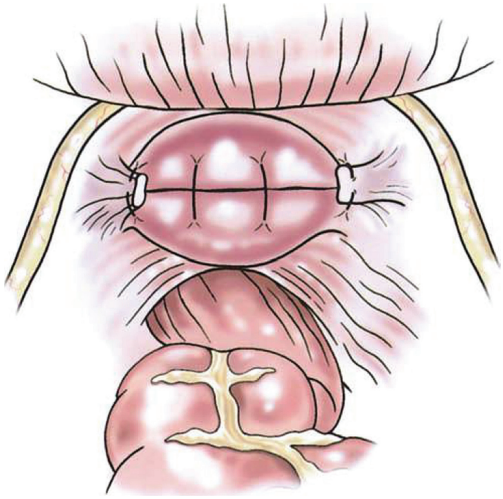

Figure 26.17 Final appearance.

inflated surgical glove containing a folded wet gauze is left in the vagina. The uterosacral ligament is elevated with a grasping forceps and sutured to the vaginal angle on each side; the knot tying may be extra- or intracorporeal. The vaginal cuff is closed in the middle using several interrupted sutures or a single or continuous suture (Figures 26.16 and 26.17).

RADICAL HYSTERECTOMY

The most common indications for the radical procedure are stage IA2, IB, and IIA carcinoma of the cervix. Less common indications include small centrally recurrent postradiation cervical cancers, adenocarcinoma of the endometrium with clinical involvement of the cervix, and stage I to II carcinoma of the vagina.

Surgical Procedure

1. Development of the rectovaginal space: an assistant elevates the uterus with a uterine manipulator, and with the other hand performs a rectovaginal examination, delineating the rectum and the vagina. The cul-de-sac peritoneum between the attachment to the rectum and to the vagina is incised laparoscopically and the rectum is separated from the posterior vaginal wall using sharp and blunt dissection to a level of 3 to 4 cm below the cervix (Figure 26.18). The pneumoperitoneum will help identify the correct plane.
2. Development of the vesicovaginal space: round ligaments are electrodesiccated and cut close to the pelvic sidewall. The peritoneum is incised lateral and parallel to the ovarian vessels. Anterior leaves of broad ligament are incised toward the vesicouterine peritoneal reflexion. Using hydrodissection or sharp and blunt dissection, the vesicouterine ligament is divided and the bladder is pushed off the cervix and the upper third of the vagina (Figure 26.19).
3. Development of the paravesical spaces: the obliterated hypogastric artery is identified and is retracted medially with a suction irrigator probe or a grasping

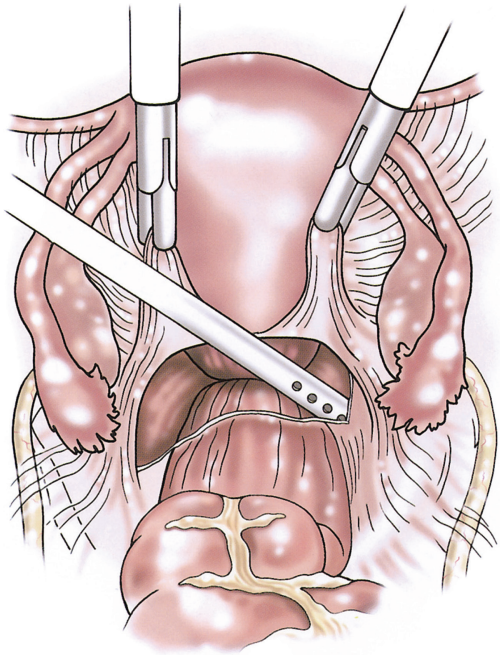

Figure 26.18 The cul-de-sac peritoneum is incised laparoscopically and the rectovaginal septum is developed.

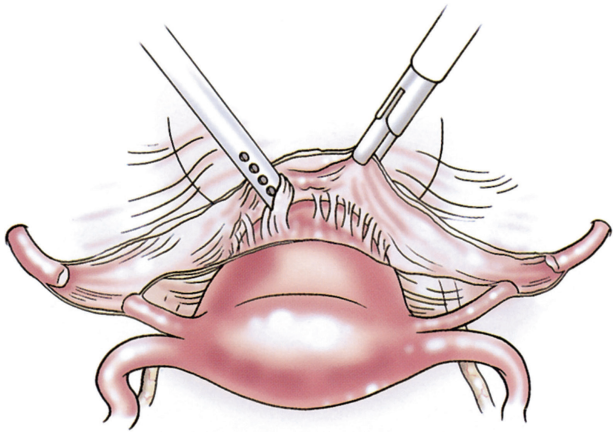

Figure 26.19 The vesicovaginal space is developed and the vesicocervical uterine ligament is dissected.

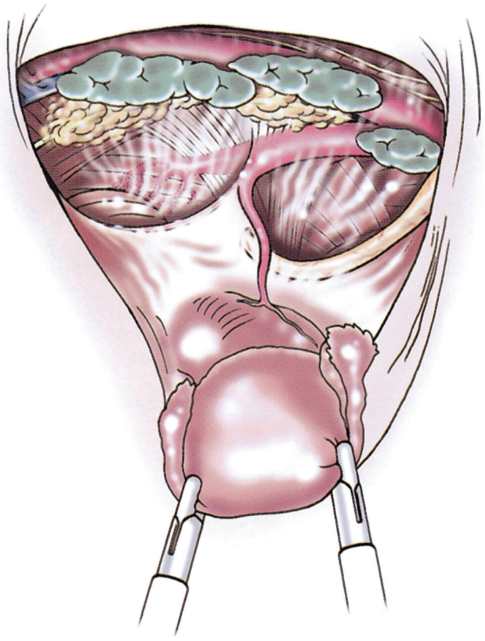

Figure 26.20 The paravesical and pararectal space is developed.

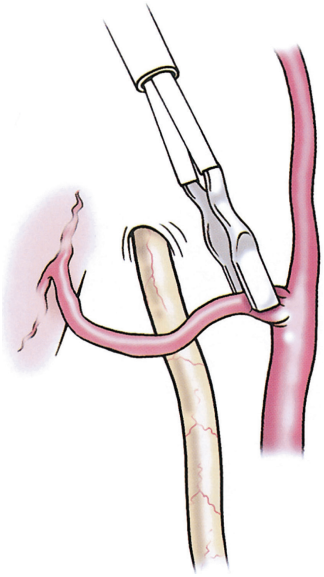

Figure 26.21 The uterine artery is electrodessicated or clipped at its origin from the hypogastric artery.

forceps. The paravesical space is developed between the obliterated hypogastric artery and the external iliac vein (Figure 26.20).

4. Development of the pararectal space: while the infundibulopelvic ligament and adnexa are retracted medially, the obliterated hypogastric artery is traced down until the ureter is identified retroperitoneally and traced from the pelvic brim toward the bladder. While the ureter is retracted medially, the pararectal space is entered using blunt dissection between the hypogastric artery laterally and the ureter medially and posterior to the uterine artery. Ureteral dissection is performed and the uterine artery is identified at its origin from the hypogastric artery (Figure 26.21).
5. Ligation of the uterine artery and unroofing the ureter: the uterine artery is electrodesiccated or clipped just medial to its origin, transected, and rotated anterior to the ureter (Figure 26.22). An angled tip clamp or the tip of the suction irrigator probe is used to widen the ureteral canal; an incision is made anteriorly; it is opened completely and the ureter mobilized. The ureter is unroofed from the ureteral canal and the parametrium is freed. Bipolar electrodesiccation, staples, or surgical clips can be used for achieving hemostasis of the hypogastric venous plexus (Figure 26.23). The uterosacral ligaments and the parametrium are stapled or electrodesiccated with a bipolar vessel sealing device and sequentially transected approximately 1.5 to 3 cm lateral to the cervix, based on the type of radical hysterectomy being performed. The dissection is taken to 2 to 3 cm below the cervix (Figure 26.24).

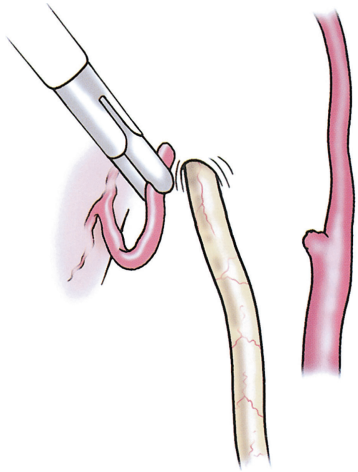

Figure 26.22 The uterine artery rotated over the ureter.

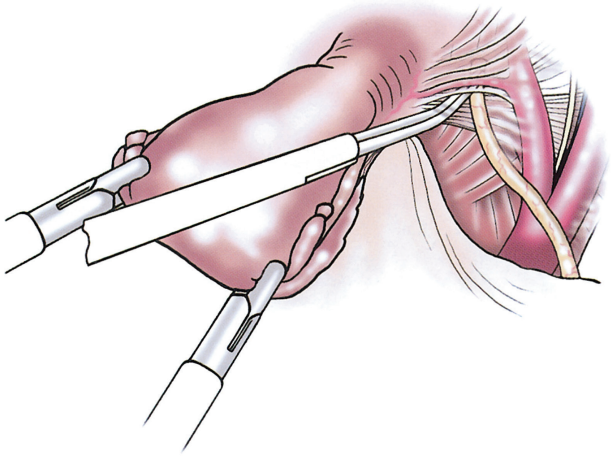

Figure 26.23 The parametrium is freed.

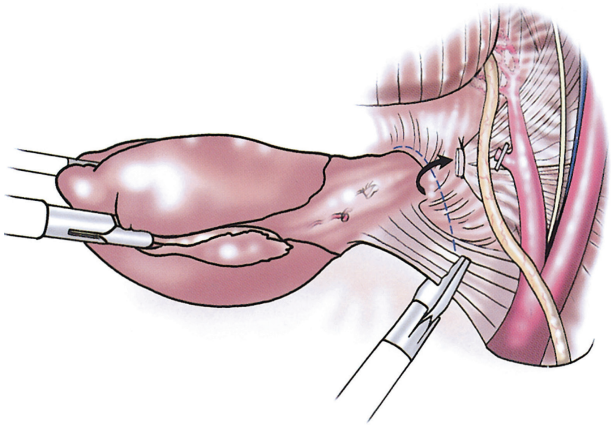

Figure 26.24 The dissection is taken to 2 to 3 cm below the cervix.

Anterior and posterior culdotomy are performed as described above. After removal of the uterus, the vaginal cuff is closed either laparoscopically or vaginally.

OMENTECTOMY

Omentum frequently is involved with metastatic lesions whenever there is intra-abdominal spread of cancer. Omentectomy is part of the staging of ovarian cancer and is often performed in treating or staging other gynecologic cancers, such as uterine papillary serous adenocarcinoma.

Anatomic Considerations

The greater omentum is a fatty apron attached to the transverse colon and draped over coils of the small intestine. It is attached along the first part of the duodenum; its left border is continuous with the gastrolienal ligament. If it is lifted and turned back over the stomach and liver, it can be seen to adhere to the transverse colon along the latter's whole length across the abdomen.

The omentum receives its blood supply from the gastro-omental arcade, which is formed by the anastomosis of the left (a branch of the splenic artery) and right (a branch of the gastroduodenal artery) gastro-omental arteries.

Surgical Procedure

1. Patient position and trocar placement: the patient should be lying flat or in a slightly reversed Trendelenburg position for better access to the omentum. Primary and secondary trocar placement is similar to that described for appendectomy. Although stapling or bipolar electrodesiccation can be used for hemostasis of the omental vasculature, the harmonic scalpel is preferred by some because of its unique advantages of reducing both tissue damage and smoke plume production.
2. The omentum is elevated using two atraumatic grasping forceps introduced through the 5-mm trocar sleeves. After exposure of the omentum and assessment of its relation to the transverse colon, a harmonic scalpel is introduced through the midline trocar and the omentectomy is started from the middle or the hepatic flexure, proceeding toward the splenic flexure at the line of reflection onto the transverse colon. Attention should be paid to avoiding injury to the colon and its mesentery and the short gastric vascular cascades (Figures 26.25–26.27), especially if the anatomy has been distorted by the tumor deposit or adhesions.

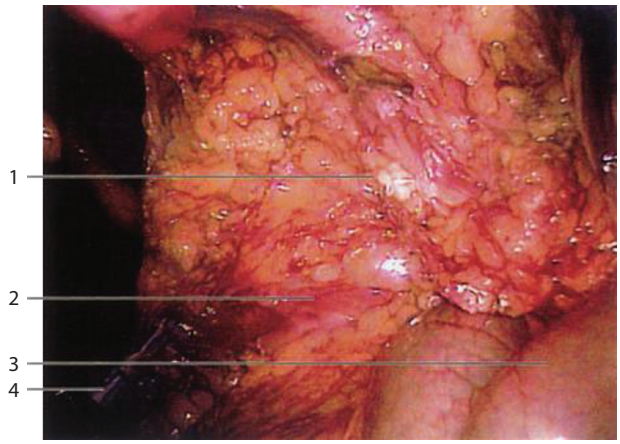

Figure 26.25 1: Omentum is under the stretch; 2: transverse colon; 3: small bowel; 4: omentectomy is started from the hepatic flexure.

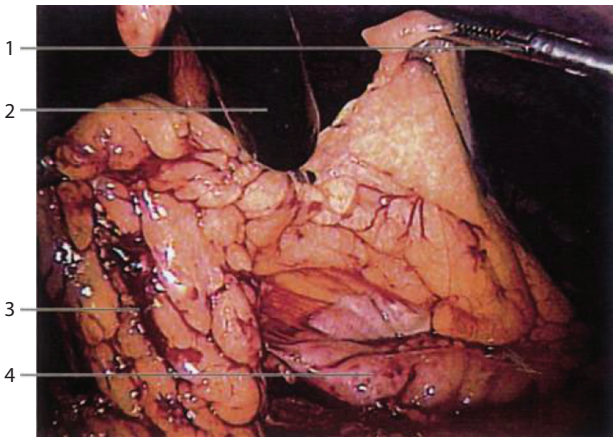

Figure 26.26 1: Grasping forceps elevate the omentum; 2: harmonic scalpel; 3: segment of detached omentum; 4: transverse colon.

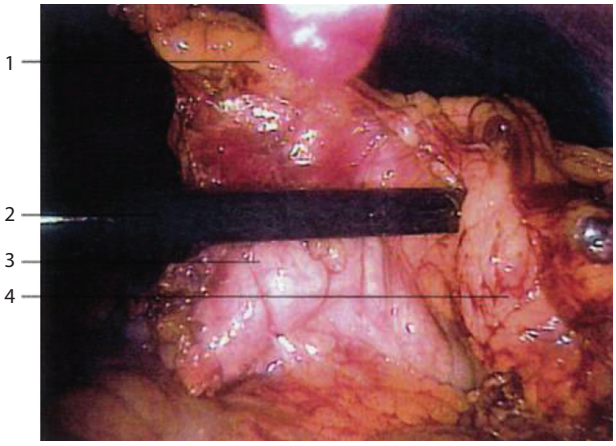

Figure 26.27 1: Omentum being elevated for exposure of transverse colon; 2: harmonic scalpel; 3: transverse colon; 4: splenic flexure and part of omentum.

3. After the omentum has been detached it can be extracted from the abdominal cavity in different ways. Following laparoscopic or laparoscopically-assisted vaginal hysterectomy, it can be extracted through the vagina either directly or after placing it in a bag. Alternatively, the omentum can be removed through a 12-mm trocar sleeve or an enlarged anterior abdominal trocar site after enclosure in an endoscopic bag. Before termination of the procedure, hemostasis should be assured by decreasing the pneumoperitoneum pressure and evaluating the site of the resection. Individual bleeding sites can be treated with bipolar electrocoagulation, application of clips, or suture techniques.

LAPAROSCOPIC BOWEL SURGERY

Laparoscopic bowel surgery is becoming more and more common in the field of gynecologic oncology. When performing laparoscopic bowel surgery, some helpful caveats to keep in mind include the following concepts:

1. In most colon resections, the colon becomes a midline structure and can be removed through a small periumbilical or infraumbilical midline incision.
2. A small bowel resection often does not require extensive mobilization of the bowel. Once the area of disease is identified, the loop of intestine to be resected can be brought out through an expanded port incision. The bowel resection and anastomosis can then be accomplished using traditional extracorporeal techniques. Because in most instances the bowel must be removed through an abdominal incision thereby allowing for the extracorporeal anastomosis, there is often no clear advantage to performing the technically more in-depth procedure of intracorporeal anastomosis.

SMALL OR LARGE BOWEL BYPASS

Indications

In general, indications for laparoscopic bowel bypass are the same as indications for bowel bypass in traditional open surgery in the gynecologic oncology patient. In this context, the most common indication is management of malignant bowel obstruction.

Anatomic Considerations

When performing bypass surgery for bowel obstruction, the surgeon must preoperatively assess the patency of the bowel distal to the planned bypass location to assure that another more distal obstruction is not present. Contrast radiologic studies and/or endoscopic procedures are the most commonly used methods to preoperatively study the bowel in preparation for surgery.

A thorough understanding of the bowel blood supply is imperative when performing laparoscopic bowel surgery. One must be cognizant of the "watershed" areas where blood supply to the bowel can be easily compromised, especially when performing bowel resections and/or anastomosis procedures. As a general rule, if mesentery ligation is required during the procedure, it is best to ligate the bowel mesentery prior to dividing segments of bowel to allow for visualization of demarcation areas (bluish discoloration of the bowel marking areas of compromised blood supply). As always, care must be taken to avoid inadvertent ligation of the bowel mesentery when performing anastomosis procedures. This can generally be accomplished by following the classic antimesenteric-to-antimesenteric anastomosis techniques.

Surgical Procedure

Because laparoscopic bowel resections are often performed in conjunction with other procedures related to cancer staging and/or cytoreduction, we prefer a standard approach regarding setup and positioning for our patients. First, patients are positioned in the dorsal lithotomy position with adjustable stirrups.

The operating room is arranged with a standard setup of one or two video monitors placed at the foot of the bed. Monitors may be rotated to the patient's right or left side as different quadrants of the abdomen are explored.

In addition to standard laparoscopic equipment, there are three general categories of surgical stapling devices that are particularly useful when performing laparoscopic bowel surgery. These include the thoracoabdominal linear stapling instruments (extracorporeal stapling), gastrointestinal anastomosis stapling

instruments (both intracorporeal and extracorporeal stapling), and the end-to-end anastomosis (EEA) stapling instruments. Although we prefer the use of endoscopic stapling devices when performing intracorporeal bowel division and anastomosis, traditional suture techniques of bowel closure and anastomosis in one or two layers using polyglactin 910 (Vicryl) suture (or other appropriate suture materials) are also appropriate for the skilled laparoscopic surgeon.

1. Trocar placement: after abdominal insufflation via a traditional intraumbilical port, additional working ports are placed. Ports should be placed about a hands-breadth apart to allow for adequate range of motion without interfering with other instruments. In most instances we use two lower abdominal ports placed two fingerbreadths medial and superior from the anterior superior iliac spine. Additional ports are placed in the upper abdomen either in the left or right upper quadrant to help triangulate in our operating field. For example, if performing a right lower quadrant bypass, we will use a 10- to 12-mm port in the left lower quadrant to allow access for bipolar vessel sealing devices and/or endostapling devices. Similarly, if performing a bypass in the left lower quadrant bypass, we will use a 10- to 12-mm port in the right lower quadrant. Alternatively, a 10- to 12-mm midline suprapubic port (instead of in the lateral position) can perform a similar function while allowing access to the deeper pelvis.
2. After careful inspection of the bowel, the two loops of intestine that will be joined during the anastomosis are identified, mobilized, and lined up side by side. If division of a bowel segment is required, it can be performed using the endoscopic gastrointestinal stapling device (Figure 26.28), and division of the bowel mesentery can be performed using the ultrasonic shears and/or bipolar vessel sealing device. A stay suture (the "crotch stitch") of 3-0 Vicryl is placed via intra- or extracorporeal knot-tying techniques, allowing for stabilization of these two bowel loops.



Figure 26.28 Although small bowel resection is not routinely performed during small bowel bypass, the technique of intracorporeal division is demonstrated here using the endoscopic gastrointestinal stapling device.



Figure 26.29 Intracorporeal side to side anastomosis of small bowel is performed using the endoscopic gastrointestinal stapling device. Two fires of the stapling device are performed (one in a proximal direction and one in a distal direction) to ensure an adequate lumen.

3. A small antimesenteric enterotomy is made in each bowel loop using the electrocautery or ultrasonic shears device. With the bowel loops stabilized securely in place, an intracorporeal anastomosis is accomplished by firing the endoscopic gastrointestinal stapler one or two times depending on the desired length of the anastomosis, creating a classic antimesenteric side-to-side (functional end-to-end) anastomosis (Figure 26.29). As outlined in the anatomic considerations section above, extreme care must be taken to assure that the bowel mesentery is rotated out of the line of fire of the stapling device to avoid inadvertent ligation of blood supply to the anastomosis. The combined enterotomy is then closed using a running two-layer technique via a laparoscopic suturing technique, or closed by using the endoscopic stapling device.

LOOP ILEOSTOMY

Indications

The most common indications for a laparoscopic loop ileostomy are to create a proximal diversion in the setting of a distal malignant bowel obstruction or bowel perforation, to protect a distal anastomosis, and to manage radiation-related bowel toxicity.

Anatomic Considerations

When performing a loop ileostomy, the surgeon must preoperatively assess the patency of the bowel proximal to the planned ostomy location to ensure that a proximal bowel obstruction is not present. Contrast radiologic studies and/or endoscopic procedures are the most commonly used methods to preoperatively study the bowel in this regard.

As with all bowel procedures, a thorough understanding of the bowel blood supply is imperative. Please refer to the anatomic considerations section above on bowel bypass for more detailed information in this regard. For planned ostomy procedures, patients must be counseled and consented preoperatively about the possibility of requiring a temporary or permanent

ostomy. An ostomy nurse or other qualified individual should carefully examine the patient in a variety of positions (lying, sitting, and standing) to determine the optimal location for the ostomy. In general, a loop ileostomy will be brought up in the right mid-abdomen or right lower quadrant. The ostomy location should be anticipated when considering trocar placement, keeping in mind that a trocar site can easily be enlarged into an ostomy site. As a general rule, the ostomy site should be overlying the rectus muscle, be accessible to the patient (both visually and manually), and not fall within the waistline or skin crease (which would make securing of an appliance difficult). Ideally, a patient may wear an appliance preoperatively as a "dry run" to determine the adequacy of the proposed site.

Surgical Procedure

1. Trocar placement: laparoscopic loop ileostomy is performed via three or four ports using a standard placement similar to that as described above for laparoscopic bowel bypass procedures. Ideally, the right mid or lower abdominal port site will also serve as the ostomy site.
2. To facilitate mobilizing the distal ileum, which is often the segment of bowel of interest in this procedure, the small bowel is mobilized by division of peritoneal attachments in the region of the ileocolic junction using a combination of both blunt and sharp dissection using the harmonic shears, bipolar vessel sealing device, or unipolar electrocautery device.
3. At the location of the planned ostomy site, a disc of skin is removed using the unipolar cautery. The dissection is carried down to the fascial layer and a cruciate incision is made approximately two finger-breadths in diameter. The rectus muscles are separated bluntly and the posterior sheath and peritoneum are entered sharply (Figure 26.30). After creation of the abdominal defect, the small bowel (typically distal ileum) is brought up through the stoma site and a window is made in the bowel mesentery just underneath the bowel wall (between vasa recta). A glass or plastic rod is placed through the window and rested on the skin.
4. The bowel wall is incised via a transverse incision closer to the distal limb and the lumen is entered.

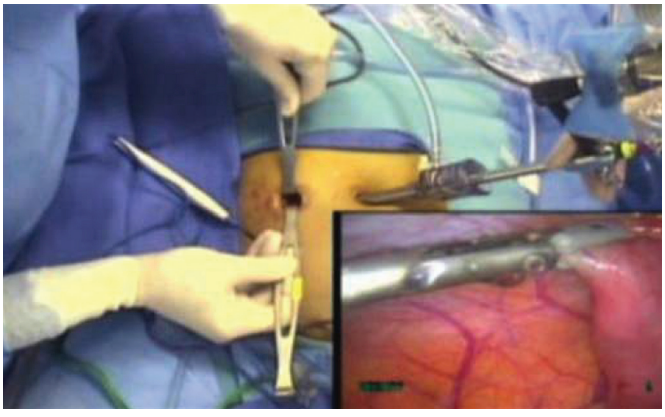

Figure 26.30 Creation of the abdominal wall defect (stoma site).



Figure 26.31 The mucosal edges are everted using a series of 3-0 absorbable sutures in a rosebud type fashion.



Figure 26.32 A mature loop ileostomy.

The mucosal edges are everted using a series of 3-0 absorbable sutures in a rosebud type fashion (Figure 26.31) and the ostomy is matured (Figure 26.32).

RIGHT HEMICOLECTOMY

Indications

In the gynecologic oncology patient, the most common indications for right hemicolectomy are as part of a tumor cytoreduction procedure and/or management of malignant bowel obstruction.

Anatomic Considerations

The right (ascending) colon lies in close proximity to the duodenum, liver, right kidney, and right ureter. The surgeon must be fully aware of the location of the surrounding organs as well as the main blood supply to the right colon, including the ileocolic and right colic arteries, which originate from the superior mesenteric artery. The anastomosis between the main arterial supply from the superior mesenteric artery (right and middle colic arteries) and inferior mesenteric artery (IMA) (left colic artery) marks an important watershed area in the region of the splenic flexure. Whenever possible, resection of the right colon should be performed with preservation of the middle colic artery.

Surgical Procedure

When performing a laparoscopic right hemicolectomy, we follow the standardized techniques as described by Senagore et al. (2004) with slight modifications appropriate for the gynecologic oncology patient.

1. Trocar placement: a standard four port placement is utilized including an intraumbilical 5-mm port, right and left accessory ports (5 to 10 mm), and suprapubic port (12 mm).
2. Elevation of the right colic pedicle and transection of the vessels at an appropriate distance to allow for adequate surgical tumor margins.
3. Elevation of right colon and transverse colon off the retroperitoneum.
4. Entrance of the lesser sac with division of the gastrocolic ligament.
5. Division of the lateral peritoneal reflection.
6. Exteriorization of the specimen through a wound protector.
7. Extracorporeal division and anastomosis.

Following the "medial-to-lateral" approach, the vascular pedicles are identified early in the procedure and are separated from vital structures such as the duodenum before division of the lateral peritoneal attachments. The vessels are transected with margins allowing for complete cytoreduction of tumor involving the bowel and mesentery (Figure 26.33). Keeping the bowel attached to the lateral abdominal wall during this part of the procedure allows for counter traction and easier mobilization. Once the vessels have been transected, the lesser sac is entered by dividing the gastrocolic ligament and the hepatocolic ligament (Figure 26.34). The lateral attachments are divided with sharp dissection using the unipolar cautery device, and the bowel is easily mobilized and exteriorized. It is important to note that a lateral-to-medial approach is equally as effective, and preference is based on surgeon expertise and preference. Although no large prospective randomized controlled studies have compared laparoscopic bowel resection versus open bowel resection in the management of gynecologic cancers, extrapolating from the colorectal surgery literature suggests that outcomes would be equivalent.



Figure 26.33 The right-colic and ileocolic vessels are identified and transected using the bipolar vessel sealing device.

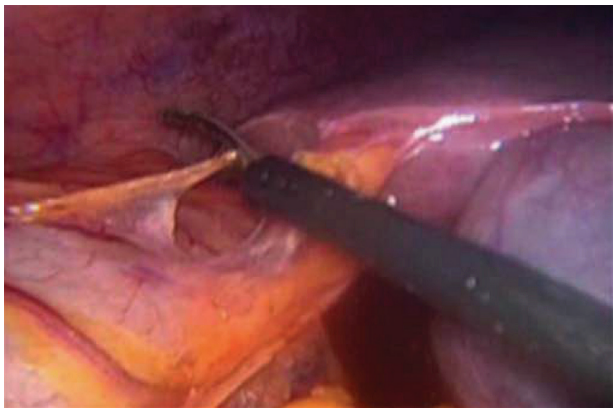

Figure 26.34 The hepatocolic ligament is divided using either unipolar or bipolar cautery.

LEFT HEMICOLECTOMY

Indications

In the gynecologic oncology patient, the most common indications for left hemicolectomy are as part of a tumor cytoreduction procedure and/or management of malignant bowel obstruction.

Anatomic Considerations

The left (descending) colon lies in close proximity to the spleen and pancreas, left kidney, and left ureter. The surgeon must be fully aware of the surrounding organs as well as the main blood supply to the left colon from the IMA (left colic artery, sigmoid arteries, and superior rectal artery). The anastomosis between the main arterial supply from the superior mesenteric artery (right and middle colic arteries) and IMA (left colic artery) marks an important watershed area in the region of the splenic flexure of the colon. Whenever possible, left colon resection should be performed with preservation of the middle colic artery.

Surgical Procedure

1. Trocar placement: as a modification of the standard four-port placement as described above, a hand-assist device is placed as a suprapubic port through a lower midline incision or "mini" Pfannenstiel incision. The incision is made slightly smaller (measured in centimeters) in size than the individual's glove size (Figure 26.35).
2. Using a medial-to-lateral technique, manual retraction of the bowel facilitates mobilization and dissection. Because this procedure is typically performed in conjunction with other gynecologic oncology-related procedures, both the left and right pelvic sidewalls are typically opened and the pararectal spaces are developed, allowing for identification of both ureters prior to proceeding with rectosigmoid colon resection. At a minimum, identification of the left ureter is mandatory prior to transection of the sigmoid arteries and superior rectal vessels. For routine rectosigmoid colon resections, it is not our preference to place ureteral stents.
3. Lateral peritoneal attachments to the colon can be divided using the unipolar electrocautery device after

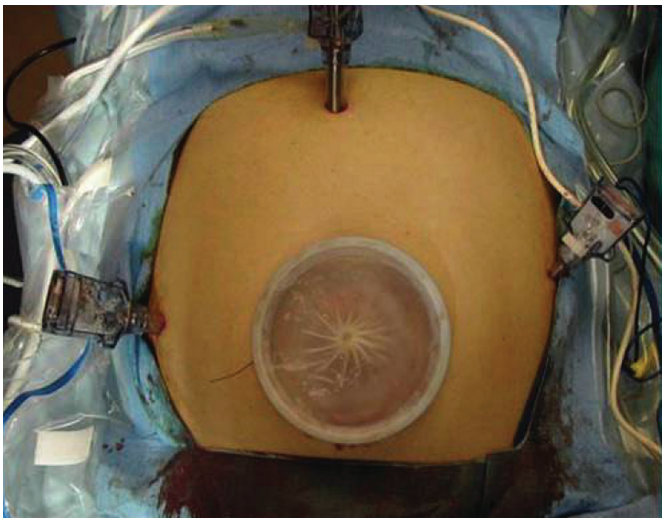

Figure 26.35 The use of a hand-port can facilitate laparoscopic bowel surgery.

mobilization by finger dissection. The dissection is carried proximally with mobilization of the splenic flexure (this includes division of the gastrocolic, phrenocolic, and splenocolic ligaments).

4. Unlike the extracorporeal anastomosis in the right hemicolectomy procedure, the colorectal anastomosis during a rectosigmoid colon resection is routinely performed intracorporeally. After complete mobilization and division of the vessels, the bowel is divided intracorporeally at the distal margin of the specimen with the endostapling device (Figure 26.36). The proximal bowel is externalized through the hand port or with a wound protector, and the proximal margin stapled (or divided) extracorporeally. The rectosigmoid colon specimen is sent to pathology and an EEA anvil is placed in the proximal limb and secured down using a purse-string suture (Figure 26.37). The EEA stapling device is then placed into the anus and advanced into the rectosigmoid colon and the spike is deployed through the rectal stump.
5. The anvil is attached to the EEA stapling device and the bowel limbs are fixed in position by tightening the stapling device. An anastomosis is then performed by firing the EEA stapling device.
6. The anastomosis line is visualized using a sigmoidoscope, and is tested for leaks by injecting air (a bubble test) and/or diluted betadine in the rectum. The "donuts" in the EEA stapling device are inspected and any defect found should alert the surgeon about the possibility of a corresponding defect at the anastomosis site.

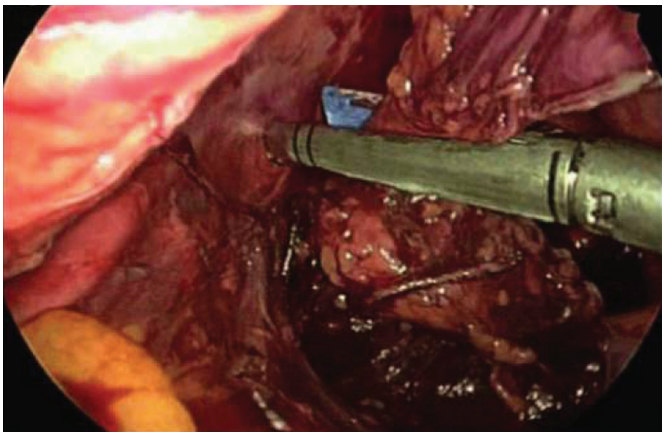

Figure 26.36 The sigmoid colon is divided using the endoscopic gastrointestinal stapling device.

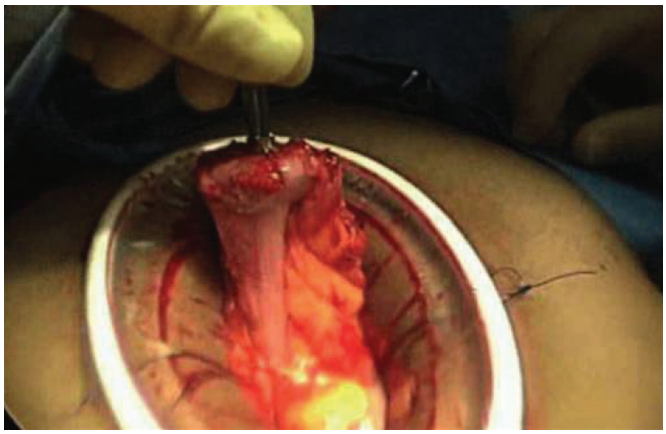

Figure 26.37 The anvil from the appropriately sized EEA stapling device is placed into the proximal colon and secured in place with a purse-string suture.

PALLIATIVE END COLOSTOMY

In palliative end colostomy, the fecal stream is diverted above the rectum. End sigmoid colostomy with a Hartmann pouch or distal exteriorization of the distal portion of the sigmoid colon as a fistula in lieu of the Hartmann pouch may be utilized. Palliative end sigmoid colostomy with the Hartmann pouch is most frequently employed in gynecologic oncology when permanent diversion is required.

Indications

Palliative end colostomy in gynecologic oncology is required when the distal bowel has been removed or is permanently unusable, as in the case of nonresectable pelvic tumor causing sigmoid colon obstruction or irreparable fistula caused by tumor or radiation necrosis.

Anatomic Considerations

The blood supply of the entire large intestine comes from the superior and inferior mesenteric arteries, with the former mainly supplying the midgut-derived right and transverse colon, whereas the latter supplies the hindgut-derived left colon. The marginal artery of Drummond serves to connect the vascular territories of the two arteries.

The IMA arises from the dorsal side of the aorta often to the left at the level of L3, about 3 to 4 cm proximal to the bifurcation of the aorta. After veering to the left, it gives off the left colic artery which divides into ascending and descending branches. The sigmoid colon is supplied by two to four arteries. The first one, which is the largest, comes from the left colic artery (30% of cases) or the IMA. From this first sigmoid vessel, second or third vessels may originate, or may arise directly from the IMA.

As the IMA enters the pelvis, it becomes the superior rectal (hemorrhoidal) artery.

Venous and lymphatic drainage of the large intestine follows the general pattern of the arterial supply.

Surgical Procedure

1. Patient position and trocar placement: the patient is placed in a supine position or slightly turned toward the right side. A principal intraumbilical trocar for video laparoscopy is inserted with three or four other trocars for introduction of the ancillary instruments (Figure 26.38). Two trocars are placed on the left side: one 12-mm trocar between the umbilicus and iliac crest for introduction of a Babcock clamp or linear stapling device, and one 5-mm trocar at the level of the iliac crest for introduction of a grasping forceps. One 12-mm midline trocar is placed 5 cm above the symphysis pubis for introduction of the stapler, clip applier, scissors, or harmonic scalpel, and one 5-mm trocar on the right side at the level of the iliac crest for introduction of a grasping forceps (Figure 26.38).
2. After thorough evaluation of the abdominal and pelvic cavity, the sigmoid colon is identified and

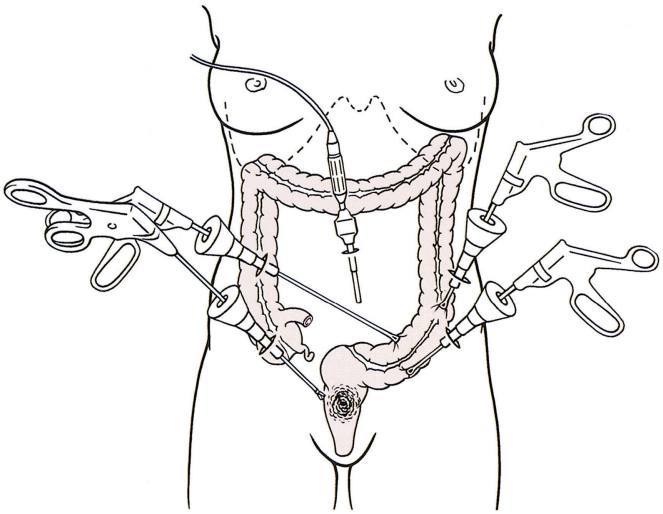

Figure 26.38 Port sites placement for end colostomy.

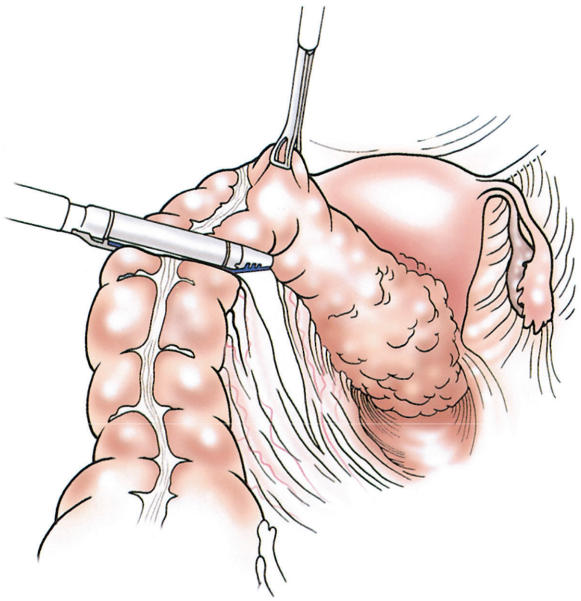

Figure 26.39 A linear stapling cutter is used to divide the bowel.

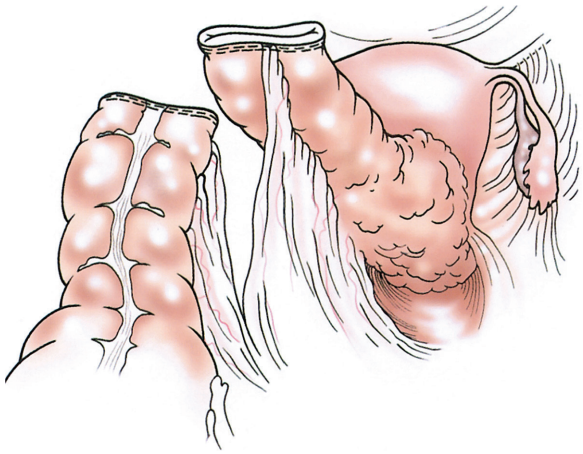

Figure 26.40 Division of the bowel.

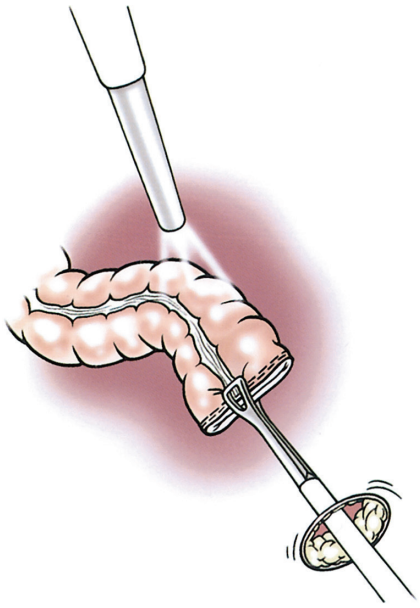

Figure 26.41 The proximal portion of the sigmoid colon is brought out through the incision.

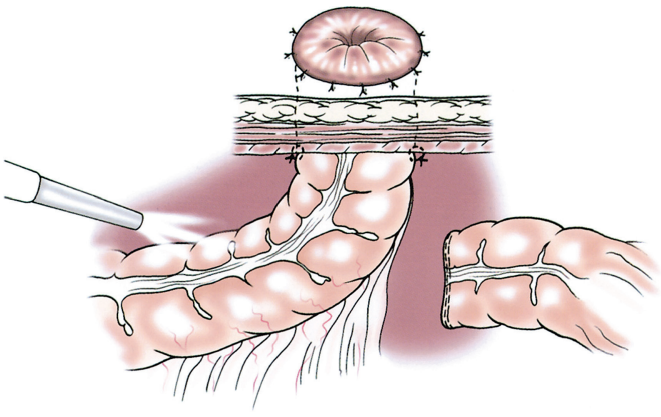

Figure 26.42 The serosa of the sigmoid colon is sutured to the peritoneum.

mobilized from its attachment to the pelvic sidewall. By means of a Babcock grasping forceps introduced through the left trocar incision, the sigmoid colon is elevated. Electrosurgery, a harmonic scalpel, or a stapling device is used to divide the mesentery of the sigmoid colon and a "window" is made. Vascularity of the proximal end of the bowel should not be compromised. While the bowel is elevated with the Babcock clamp, a laparoscopic linear stapling cutter introduced through the left lower quadrant trocar is passed across the bowel, which is then divided (Figures 26.39 and 26.40).

3. After removal of the left lower quadrant trocar cannula, a disk of the subcutaneous fat at this site is incised and removed in preparation for location of the stoma. The fascia is incised and is enlarged using two fingers. Under direct laparoscopic visualization, a Babcock clamp is introduced through the left quadrant incision and the proximal portion of the sigmoid colon is grabbed and brought out through the incision (Figure 26.41).
4. The stapled end of the proximal colon is removed and a "rosebud" stitch is used to evert the colon onto the skin, creating the stoma (Figure 26.42). Laparoscopically the serosa of the sigmoid colon is sutured to the peritoneum for prevention of internal hernia, using 2-0 polyglactin.

LYMPHADENECTOMY

Since the initial descriptions of laparoscopic pelvic and para-aortic lymphadenectomy in the late 1980s and early 1990s, numerous reports have verified the feasibility and safety of this technique. Its advocates point to the better magnification, fewer complications, and superior visualization of the anatomy of blood vessels and lymph nodes provided by the video laparoscope in comparison with conventional techniques. In the hands of the experienced laparoscopist, the efficacy of laparoscopic lymphadenectomy is equal to—if not better than—that achieved during laparotomy, with fewer complications.

Indications

Laparoscopic lymph node resection is performed as part of the treatment of cervical cancer, and node sampling is performed as part of the staging for endometrial or ovarian cancer.

Anatomic Considerations

Para-Aortic Nodes

The landmarks which should be kept in mind for para-aortic lymphadenectomies (Figure 26.43) are as follows, from right to left:

- Psoas muscle
- Right ureter (which is medial to the psoas muscle, lateral to the inferior vena cava and crosses the bifurcation of the common iliac artery)
- Vena cava (which is lateral to the aorta)
- Aorta and both common iliac arteries
- Below the bifurcation of the aorta superficially is the superior hypogastric nerve plexus and beneath it is the left common iliac vein crossing from the left to the right
- On the left side of the aorta are the IMA, the ureter, sigmoid colon, and its mesentery; the lumbar veins and artery are deep and can be seen after left lymphadenectomy
- On the far left is the left psoas muscle

Pelvic Nodes

The important landmarks for pelvic lymphadenectomy (Figure 26.44) are as follows:

- Laterally, the psoas muscle, the genitofemoral nerve, and the external iliac artery and vein
- Distally, the deep circumflex vein, superior pubic ramus, and obturator internus fascia
- Proximally, the common iliac bifurcation, and bowel
- Anteriorly, paravesical space, obturator nerve, and superior vesical artery
- Medially, the anterior division of the hypogastric artery and the ureter, and paravesical space
- Inferiorly, the sacral plexus, hypogastric vein, and pararectal space

Surgical Procedure

Para-Aortic Lymphadenectomy

The operating room setup, the patient's position, and the equipment may require minor variations. These include additional 5- or 10-mm trocars and positioning the video monitor at the head of the operating table, or using two monitors, one on each side of the patient: one for the surgeon's view and the other for the assistants. The surgeon can stand on the right or left side of the patient, although some prefer to stand between the patient's legs. As well as the umbilical port, three to four additional ports are necessary for introduction of the grasping forceps, scissors, and clip applier or bipolar electrocoagulator. The location of the ancillary trocars is adjusted according to the surgeon's preference. The patient is rotated to the left side for better exposure of the para-aortic area.

After insertion of the ancillary instruments and evaluation of the para-aortic area, the aorta is identified under the peritoneum up to the level of the mesenteric root. An incision is made over the posterior peritoneum at the level of the aortic bifurcation and extended toward the right iliac artery. The peritoneal incision is extended to the root of the mesenteric artery and, in the case of ovarian cancer, to the root of the left renal vein. Using two atraumatic grasping forceps, the peritoneum on each side is lifted and retracted laterally. Using blunt and occasionally sharp dissection with the tip of the suction irrigator or scissors, the retroperitoneal fatty tissue is dissected and the retroperitoneal vessels are identified (Figure 26.45).

For left para-aortic lymphadenectomy, the rectosigmoid colon is retracted laterally and, after identification of the IMA and ureter, the nodal packet lateral to the aorta and above the left common iliac artery is resected using blunt and occasionally sharp dissection. Careful attention should be paid to avoid injury to lumbar vessels, the left common iliac vein, left ureter, and IMA.

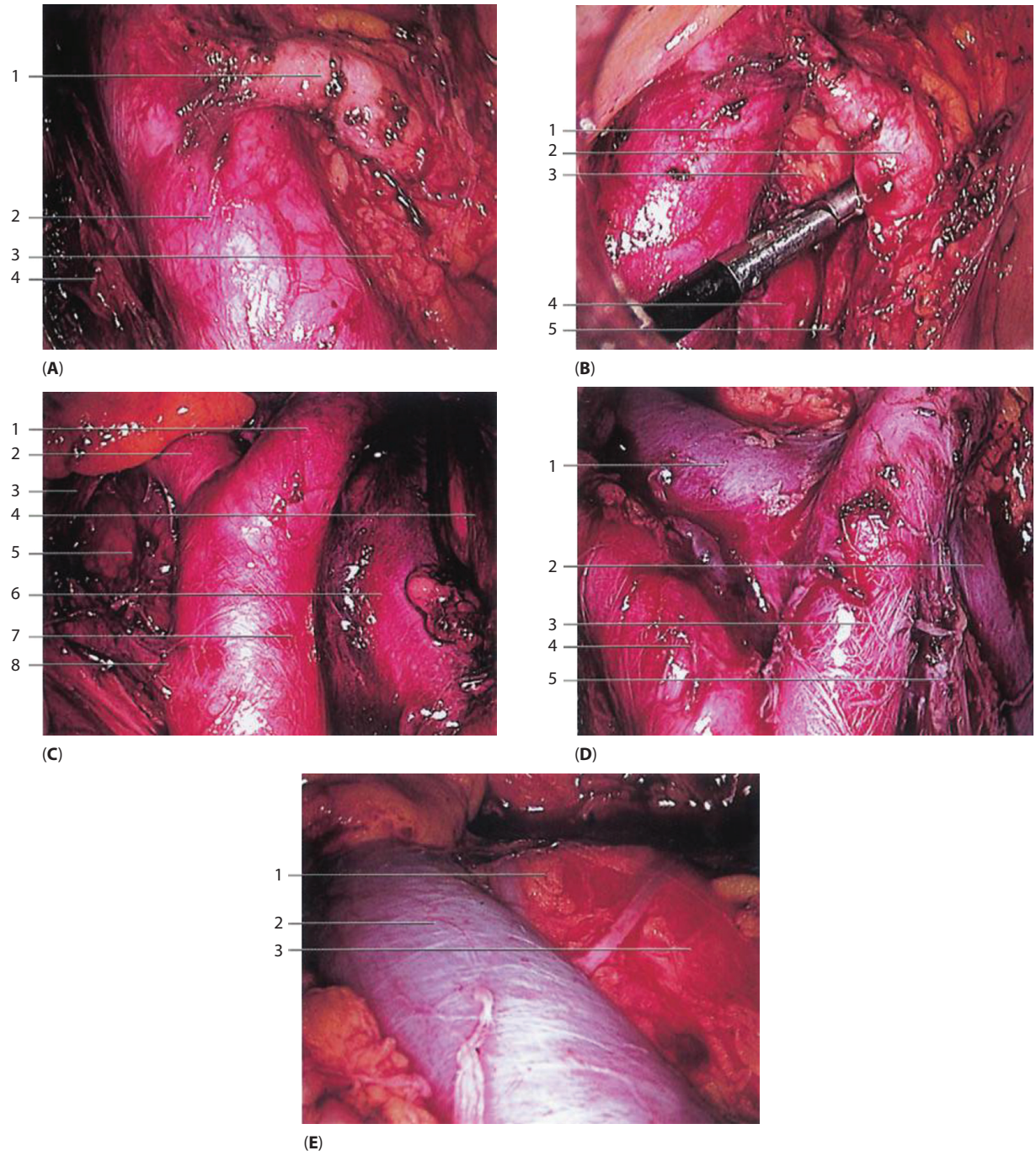

Figure 26.43 Retroperitoneal anatomy during para-aortic lymphadenectomy. (**A**) 1: Inferior mesenteric artery; 2: aorta; 3: left para-aortic nodes; 4: paracaval nodes. (**B**) Grasping forceps is used to retract inferior mesenteric artery for identification of left ureter. 1: Aorta; 2: inferior mesenteric artery; 3: remaining left para-aortic nodes under the inferior mesenteric artery; 4: left para-aortic area after lymphadenectomy; 5: left ureter. (**C**) 1: Right common iliac artery; 2: left common iliac artery; 3: left ureter; 4: right ureter; 5: left para-aortic area after lymphadenectomy; 6: vena cava; 7: aorta; 8: inferior mesenteric artery. (**D**) 1: Left common iliac vein; 2: vena cava; 3: right common iliac artery; 4: left common iliac artery; 5: remaining vena caval nodes. (**E**) 1: Midsacral vessels; 2: left common iliac vein after lymphadenectomy; 3: sacral promontory.

For ovarian cancer staging, the lymphadenectomy can be extended to the level of the left renal vein (Figures 26.46 and 26.47).

For resection of the paracaval nodes, the right ureter is identified and, while gentle traction is applied using atraumatic grasping forceps, the peritoneum and the ureter are retracted laterally over the psoas muscle. The nodal packet attached to the right common iliac artery is dissected off the vessels using blunt and occasionally sharp dissection. Using a laparoscopic Babcock clamp, the nodal packet is elevated and, using blunt and sharp dissection, the nodal packet is removed from the inferior vena cava. Care must be taken to avoid injury to the perforator veins. Clips or bipolar electrodesiccation can be used for achieving hemostasis. The level of the paracaval lymphadenectomy can be extended to the level of the right ovarian vein and, at times, the ovarian vein can be clipped and dissected for a better approach to the nodal packet in this area (Figure 26.47).

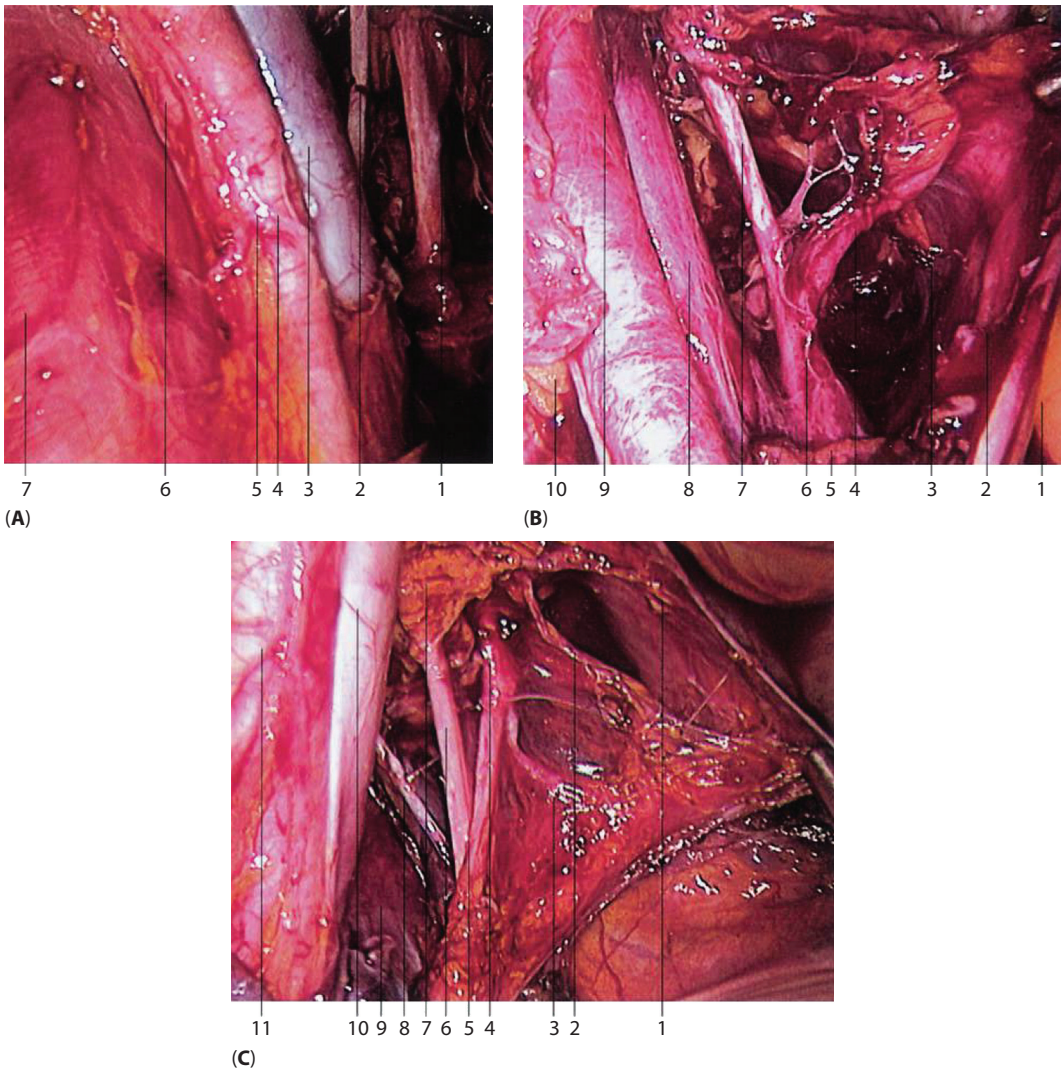

Figure 26.44 Retroperitoneal pelvic sidewall anatomy dissection during pelvic lymphadenectomy. (**A**) 1: Obliterated hypogastric artery (superior vesical); 2: obturator nerve; 3: external iliac vein; 4: left external iliac artery; 5: genitofemoral nerve; 6: left external iliac nodes; 7: left psoas muscle. (**B**) Grasping forceps retracts peritoneum medially. 1: Peritoneum; 2: left ureter; 3: pararectal space; 4: uterine artery branching from hypogastric artery; 5: remaining hypogastric nodes; 6: hypogastric artery; 7: superior vesical artery; 8: external iliac vein; 9: external iliac artery; 10: external iliac nodes. (**C**) Grasping forceps retracts peritoneum medially. 1: Right ureter, 2: superior vesicle artery; 3: uterine artery; 4: obliterated hypogastric artery; 5: hypogastric artery; 6: remaining obturator nodes; 7: obturator nerve; 8: obturator artery and vein; 9: right obturator internus muscle; 10: right external iliac vein; 11: right external iliac artery.

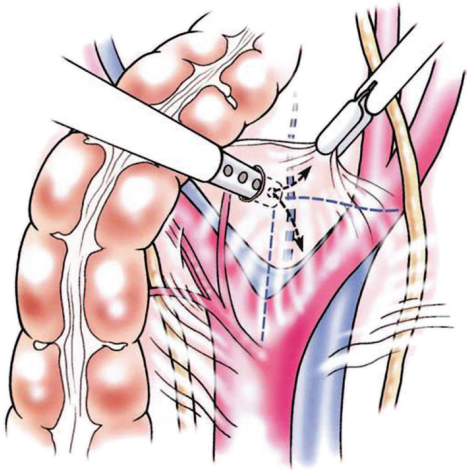

Figure 26.45 Exposure of aortic caval bifurcation.

Pelvic Lymphadenectomy

In addition to the primary intraumbilical trocar which is used for introduction of the video laparoscope, two ancillary 5-mm ports in the right and the left lower quadrants lateral to the inferior epigastric vessels at the level of the iliac crest and an additional 10-mm port in the midline 5 cm above the symphysis pubis are required. The lymphadenectomy may be performed either before or after hysterectomy. The procedure begins with an incision of the peritoneum between the round and infundibulopelvic ligaments, parallel to the axis of the external iliac vessels (Figure 26.48). The round ligament is electrodesiccated and cut, the broad ligament between the round and the infundibulopelvic ligament is opened, and the psoas muscle, genitofemoral nerve, iliac vessels, and ureter are identified. Next, the paravesical space is entered and widened by blunt dissection between the umbilical artery medially and external iliac vessels laterally. Caution should be exercised to avoid injuries to the

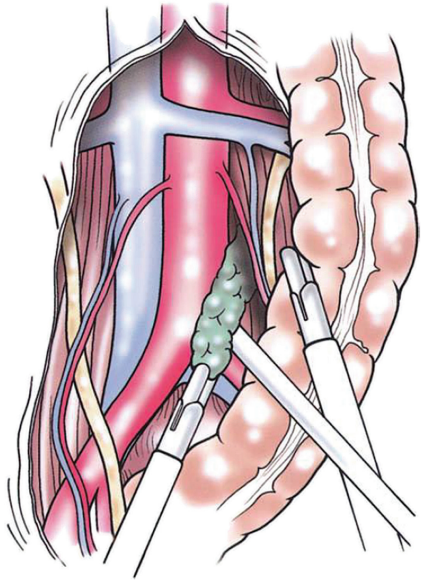

Figure 26.46 Renal vessel exposure.

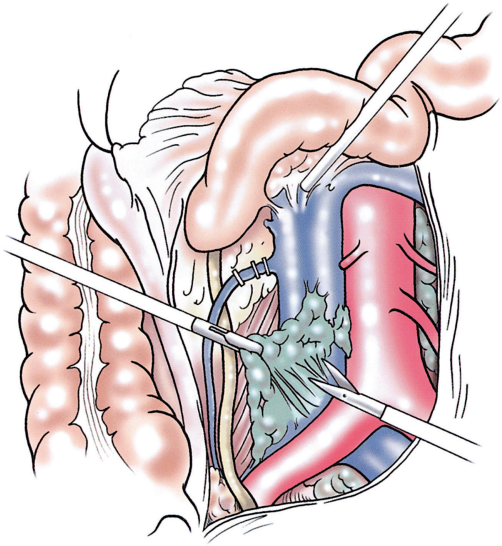

Figure 26.47 Caval exposure.

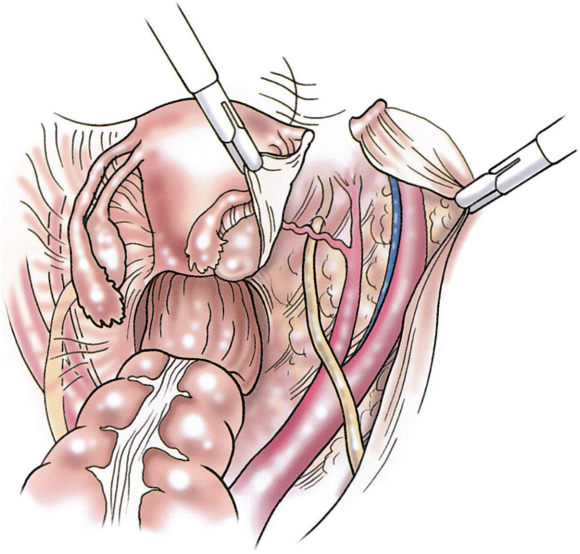

Figure 26.48 Pelvic sidewall exposure.

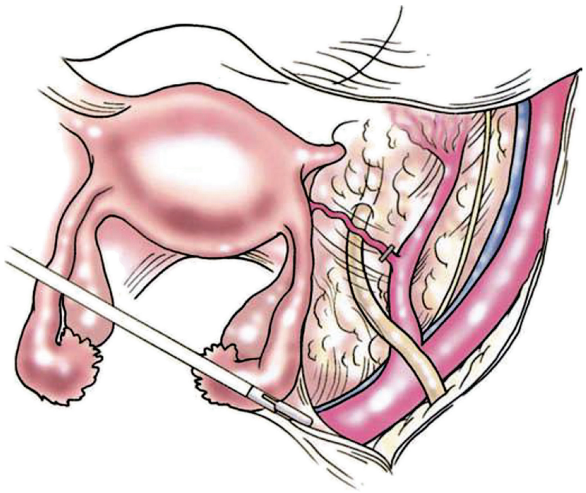

Figure 26.49 Obturator fossa exposure.

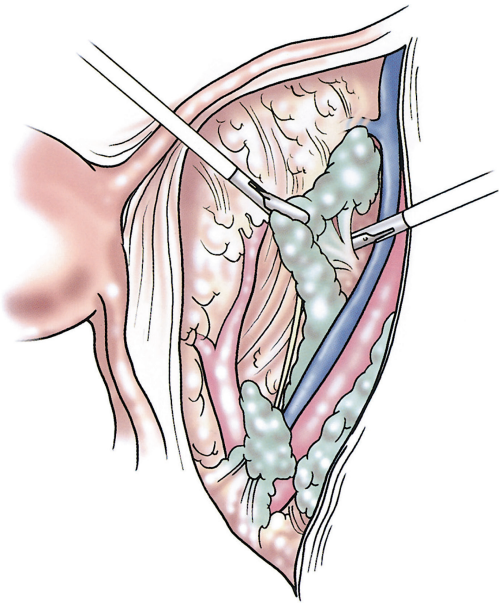

Figure 26.50 Obturator node removal.

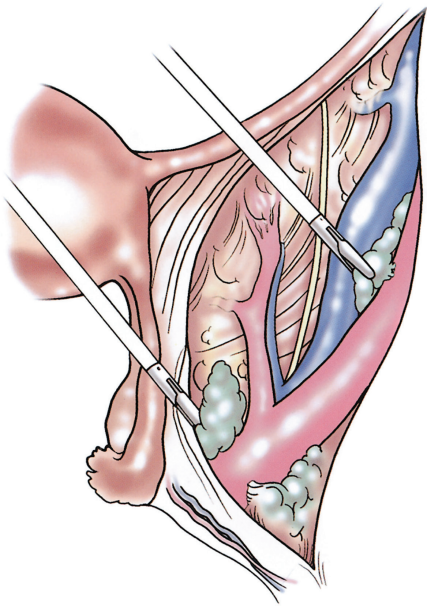

Figure 26.51 Interiliac-external iliac node removal.

external iliac vein and aberrant obturator veins (Figures 26.49 and 26.50).

The fat and the lymphatic pad between the psoas muscle and external iliac artery are elevated, dissected, and removed distally and proximally toward the circumflex vein and common iliac artery, respectively. The nodal packet below the external iliac vein is grasped medially and, using blunt dissection, separated from the vein. While gentle traction is applied on the nodal packet medially, the obturator nerve is identified inferiorly and the obturator nodal packet is dissected and removed from the obturator nerve up to the level of the bifurcation of the external iliac artery; care is taken to avoid the hypogastric vein, which often comes directly up from the pelvic floor. Inferiorly, the nodal packet is removed at the level where the obturator nerve exits from the pelvis. The fatty and nodal tissue between the obturator nerve and the external iliac vein is grasped and thoroughly separated from the pelvic wall by blunt dissection using the suction irrigator or the closed tip of the grasping forceps. Clips can be applied before removal of the nodal tissue. After removal, the pelvic bone and internal obturator muscle can be seen.

The lymphatic nodal package of the hypogastric artery is grasped and gently separated using blunt dissection from the external and internal iliac artery to the level of the division of the common iliac artery. Interiliac nodes between the external iliac artery and vein are removed (Figure 26.51).

At the end of the procedure, the nodal package is removed through the trocar using a Babcock clamp or after placement inside the laparoscopic bag, and the area is thoroughly irrigated. Pneumoperitoneal pressure is decreased for evaluation of hemostasis; the peritoneum is not closed, and no retroperitoneal drain is applied.

BIBLIOGRAPHY

Abu-Rustum NR, Rhee Eh, Chi DS, et al. 2004. Subcutaneous tumor implantation after laparoscopic procedures in women with malignant disease. *Obstet Gynecol* **103**:480–7.

Awtrey CS, Cadungog MG, Leitao MM, et al. 2006. Surgical resection of recurrent endometrial carcinoma. *Gynecol Oncol* **102**:480–8.

Barakat RR, Goldman NA, Patel DA, et al. 1999. Pelvic exenteration for recurrent endometrial cancer. *Gynecol Oncol* **75**:99–102.

Basse L, Hjort Jakobsen D, Billesbolle P, et al. 2000. A clinical pathway to accelerate recovery after colonic resection. *Ann Surg* **232**:51–7.

Bradshaw BG, Liu SS, Thirlby RC. 1998. Standardized perioperative care protocols and reduced length of stay after colon surgery. *J Am Coll Surg* **186**:501–6.

Bristow RE, del Carmen MG, Kaufman HS, et al. 2003. Radical oophorectomy with primary stapled colorectal anastomosis for resection of locally advanced epithelial ovarian cancer. *J Am Coll Surg* **197**:565–74.

Bristow RE, Santillan A, Zahurak ML, et al. 2006. Salvage cytoreductive surgery for recurrent endometrial cancer. *Gynecol Oncol* **103**:281–7.

Bucher P, Gervas P, Soravia C, et al. 2005. Randomized clinical trial of mechanical bowel preparation versus no preparation before elective left-sided colorectal surgery. *Br J Surg* **48**:1509–16.

Bucher P, Mermillod B, Gervas P, et al. 2004. Mechanical bowel preparation for elective colorectal surgery: A meta-analysis. *Arch Surg* **139**:1359–64.

Ceraldi CM, Rypins EB, Monahan M, et al. 1993. Comparison of continuous single layer polypropylene anastomosis with double layer and stapled anastomoses in elective colon resections. *Am Surg* **59**:168–71.

Chi DS, McCaughty K, Diaz JP, et al. 2006. Guidelines and selection criteria for secondary cytoreductive surgery in patients with recurrent, platinum-sensitive epithelial ovarian carcinoma. *Cancer* **106**:1933–9.

Childers J, Surwit E, Tran A, et al. 1993. Laparoscopic para-aortic lymphadenectomy in gynecologic malignancies. *Obstet Gynecol* **82**:741–7.

Clarke-Pearson DL, Dodge RK, Synan I, et al. 2003. Venous thromboembolism prophylaxis: Patients at high risk to fail intermittent pneumatic compression. *Obstet Gynecol* **101**:157–63.

Clinical Outcomes of Surgical Therapy Study Group. 2004. A comparison of laparoscopically assisted and open colectomy for colon cancer. *N Engl J Med* **350**:2050–9.

Conrad JK, Ferry KM, Foreman ML, et al. 2000. Changing management trends in penetrating colon trauma. *Dis Colon Rectum* **43**:466–71.

Curran TJ, Borzotta AP. 1999. Complications of primary repair of colon injury: Literature review of 2964 cases. *Am J Surg* **177**:42–7.

Dargent D, Mathevet P. 1992. Hystérectomie élargie laparoscopico-vaginale. *J Gynecol Obstet Biol Reprod* **21**:709–10.

Duepree HJ, Senagore AJ, Delaney CP, et al. 2002. Laparoscopic resection of deep pelvic endometriosis with rectosigmoid involvement. *J Am Coll Surg* **195**:754–8.

Estes JM, Leath CA, Staughn JM, et al. 2006. Bowel resection at the time of primary debulking for epithelial ovarian carcinoma: Outcomes in patients treated with platinum and taxane-based chemotherapy. *J Am Coll Surg* **203**:527–32.

Ferron G, Querleu D, Martel P, et al. 2006. Laparoscopy-assisted vaginal pelvic exenteration. *Gynecol Oncol* **100**:551–5.

Gillette-Cloven N, Burger RA, Monk BJ, et al. 2001. Bowel resection at the time of primary cytoreduction for epithelial ovarian cancer. *J Am Coll Surg* **193**:626–32.

Giuntoli RL, Garrett-Mayer E, Bristow RE, et al. 2007. Secondary cytoreduction in the management of recurrent leiomyosarcoma. *Gynecol Oncol* **106**: 82–8.

Goldberg GL, Sukumvanich P, Einstein MH, et al. 2006. Total pelvic exenteration: The Albert Einstein College of Medicine/Montifiore Medical Center Experience (1987 to 2003). *Gynecol Oncol* **101**:261–8.

Guillou PJ, Quirke P, Thorpe H, et al. 2005. Short-term endpoints of conventional versus laparoscopic-assisted surgery in patients with colorectal cancer (MRC CLASICC trial): Multicenter, randomised controlled trial. *Lancet* **365**:1718–26.

Hatch KD, Shingleton HM, Potter ME, et al. 1988. Low rectal resection and anastomosis at the time of pelvic exenteration. *Gynecol Oncol* **32**:262–7.

Hoffman MS, Lynch CM, Gleeson NC, et al. 1994. Colorectal anastomosis on a gynecologic oncology service. *Gynecol Oncol* **55**:60–5.

Irvin W, Andersen W, Taylor P, et al. 2004. Minimizing the risk of neurologic injury in gynecologic surgery. *Obstet Gynecol* **103**:374–82.

Jackson TD, Kaplan GG, Arena G, et al. 2007. Laparoscopic versus open resection for colorectal cancer: A meta-analysis of oncologic outcomes. *J Am Coll Surg* **204**:439–46.

Lacy AM, Garcia-Valdecasas JC, Delgado S, et al. 2002. Laparoscopy-assisted colectomy versus open colectomy for treatment of non-metastatic colon cancer: A randomised trial. *Lancet* **359**:2224–9.

Leahy PF. 1989. Technique of laparoscopic appendectomy. *Br J Surg* **76**:616.

Lewis LA, Nezhat C. 2007. Laparoscopic treatment of bowel endometriosis. *Surg Technol Int* **16**:137–41.

Maxwell GL, Synan I, Dodge R, et al. 2001. Pneumatic compression versus low molecular weight heparin in gynecologic oncology surgery: A randomized trial. *Obstet Gynecol* **98**:989–95.

Morrow CP, Curtin JP. 1996. Surgical anatomy. In: Morrow CP, Curtin JP, Osa EL, eds. *Gynecologic Cancer Surgery.* Edinburgh: Churchill Livingstone, pp. 67–139; 181–268.

Muzii L, Bellati F, Zullo MA, et al. 2006. Mechanical bowel preparation before gynecologic laparoscopy: A randomized, single-blind, controlled trial. *Fertil Steril* **85**:689–93.

Nagarsheth NP, Bub DS, Nezhat F. 2009. Laparoscopic bowel resection anastomosis, and ileostomy/colostomy. In: Covens Al, Kupet R, eds. *Laparoscopic Surgery for Gynecologic Oncology*. New York: McGraw-Hill, pp. 83–112.

Nagarsheth NP, Rahaman J, Cohen CJ, et al. 2004. The incidence of port-site metastases in gynecologic cancers. *JSLS* **8**:133–9.

Nelson R, Edwards S, Tse B. 2007. Prophylactic nasogastric decompression after abdominal surgery (review). *Cochrane Rev* **2**:1–31.

Nezhat C, Nezhat F, Ambroze W, et al. 1993. Laparoscopic repair of small bowel and colon. *Surg Endoscopy* **7**:88–9.

Nezhat C, Nezhat F, Gordon S, et al. 1992. Laparoscopic versus abdominal hysterectomy. *J Reprod Med* **37**:247–50.

Nezhat C, Nezhat F, Pennington E. 1992. Laparoscopic proctectomy for infiltrating endometriosis of the rectum. *Fertil Steril* **57**:1129–32.

Nezhat C, Nezhat F, Pennington E. 1992. Laparoscopic treatment of infiltrative rectosigmoid colon and rectovaginal septum endometriosis by the technique of videolaserlaparoscopy and the CO2 laser. *Br J Obstet Gynaecol* **99**:664–7.

Nezhat C, Nezhat F, Silfen SL. 1990. Laparoscopic hysterectomy and bilateral salpingo-oophorectomy using multifire GIA surgical stapler. *J Gynecol Surg* **6**:287.

Nezhat C, Nezhat F. 1991. Incidental appendectomy during videolaseroscopy. *Am J Obstet Gynecol* **165**:559–64.

Nezhat C, Siegler A, Nezhat F, et al. 2000. The role of laparoscopy in the management of gynecologic malignancy. In: Nezhat C, Nezhat F, Luciano A, eds. *Operative Gynaecologic Laparoscopy Principles and Techniques*. 2nd ed. New York: McGraw-Hill, pp. 301–27.

Noel JK, Fahrback K, Estok R, et al. 2007. Minimally invasive colorectal resection outcomes: Short-term comparison with open procedures. *J Am Coll Surg* **204**:291–307.

Piver MA, Rutledge FN, Smith JP. 1974. Five classes of extended hysterectomy for women with cervical cancer. *Obstet Gynecol* **44**:265–70.

Querleu D, Leblanc E. 1991. Laparoscopic pelvic lymphadenectomy in the staging of early carcinoma of the cervix. *Am J Obstet Gynecol* **164**:579–81.

Sakorafas GH, Zouros E, Peros G. 2006. Applied vascular anatomy of the colon and rectum: Clinical implications for the surgical oncologist. *Surg Oncol* **15**:243–55.

Salani R, Santillan A, Zahurak ML, et al. 2007. Secondary cytoreductive surgery for localized recurrent epithelial ovarian cancer. *Cancer* **109**: 685–91.

Semm K. 1983. Endoscopic appendectomy. *Endoscopy* **15**:59–64.

Senagore AJ, Delaney CP, Brady KM, et al. 2004. Standardized approach to laparoscopic right colectomy: Outcomes in 70 consecutive cases. *J Am Coll Surg* **199**:675–9.

The Colon Cancer Laparoscopic or Open Resection Study Group. 2005. Laparoscopic surgery versus open surgery for colon cancer: Short-term outcomes of a randomised trial. *Lancet Oncol* **6**:477–84.

Transatlantic Laparoscopically Assisted vs Open Colectomy Trials Study Group. 2007. Laparoscopically assisted vs open colectomy for colon cancer. A meta-analysis. *Arch Surg* **142**:298–303.

27 Humidification during surgery: Benefits of using humidified gas during laparoscopic and open surgery

Maria Mercedes Binda

BASICS OF THE PHYSIOLOGY OF THE PERITONEUM

The peritoneum is the serous membrane that forms the lining of the abdominal cavity, and it covers most of the intra-abdominal organs. It is composed of a single layer of mesothelium, generally 2.5 to 3 μm thick, supported by a thin layer of connective tissue (Slater et al. 1989). With a surface area of some 14,000 cm^2 in adults (Albanese et al. 2009), almost equal to that of the skin, this membrane may be the largest organ in humans. Its primary function is to diminish the friction among abdominal viscera, enabling their free movement. It also serves as a barrier to infection and is a reservoir of fat, especially in the omentum. The membrane comprises very large amounts of mucopolysaccharides or glycosaminoglycans, and just beneath its surface there is an elastin layer that gives the peritoneum mobility. The surface lining of the peritoneum consists of highly differentiated mesothelial cells (diZerega 1997).

Mesothelial cells are predominantly flattened, squamous-like, approximately 25 μm in diameter, with the cytoplasm raised over a central round or oval nucleus (Mutsaers 2004) (Figure 27.1). Long microvilli are projected from the apical surface of the mesothelial cells (Slater et al. 1989). They have well-developed cell-to-cell junctional complexes including tight junctions, adherent junctions, gap junctions, and desmosomes. Tight junctions in particular are crucial for the development of cell surface polarity and the establishment and maintenance of a semipermeable diffusion barrier (Mutsaers 2004). They secrete glycosaminoglycans, proteoglycans, and phospholipids to provide a slippery, nonadhesive glycocalyx that protects the serosal surface from abrasion, infection, and tumor dissemination. Mesothelial cells rest on a basement membrane with submesothelial stroma cells embedded within extracellular matrix (Mutsaers et al. 2015) and with abundant vascular channels that deliver oxygen and other nutrients to them.

LAPAROSCOPIC SURGERY

During laparoscopic surgery the abdominopelvic cavity is inflated with carbon dioxide (CO_2). Currently, dry CO_2 gas at room temperature is used for insufflation. However, the peritoneum is not designed to cope with variable conditions such as the introduction of dry and cold gas. Significant evidence suggests that the use of humidified and warmed gas may reduce at least two of the major morbidities associated with laparoscopic surgery: postoperative pain and hypothermia (Sajid et al. 2008, Sammour et al. 2008). Humidifying insufflation gas provides a more physiologically normal pneumoperitoneum. These principles can also be extended to other types of endoscopic surgery where other cavities are inflated to enable surgery, i.e., gastrointestinal endoscopy (Dellon et al. 2009), thoracoscopic (Mouton et al. 2001), colonoscopic (Yamano et al. 2010), and hysteroscopic (Brusco et al. 2003) procedures, and open surgery (Corona 2011, Frey et al. 2010, Frey et al. 2012a, Frey et al. 2012b, Persson and van der Linden 2009). In all of these situations the tissue desiccation is of equal consequence.

Impact of the Dry Insufflation Gas on Body Temperature: Hypothermia

When standard dry and cold gas is insufflated into the warm abdomen, the gas is humidified and warmed up by the body in order to reach an equilibrium of humidity and temperature within the peritoneum. This means that the gas is warmed up until its temperature is equal to that of the peritoneum and it is humidified until it is as humid as the peritoneum. Both processes affect the patient's thermal condition, and more specifically, that of the peritoneum. As a consequence, the peritoneum will lose temperature and liquid to reach this equilibrium with the dry and cold gas, and this process consumes energy and consequently induces hypothermia (Bessell et al. 1999). This hypothermia is mainly due to the energy spent to humidify the dry gas (577 cal to vaporize 1 g of water) rather than to the energy required to warm the cold gas (0.00003 cal to heat 1 mL of CO_2 by 1°C) (Binda et al. 2006). Therefore, the pneumoperitoneum will systematically induce hypothermia (Bessell et al. 1999, Hazebroek et al. 2002, Ott 1991) that is to a large extent caused locally by the pneumoperitoneum-induced desiccation (Gray et al. 1999).

Since there are adverse clinical effects due to core temperature cooling, hypothermia should be carefully monitored. Hypothermia can cause complications such as postoperative shivering, increased duration of post-anesthetic recovery and of hospitalization, myocardial complications, increased surgical wound infection, intraoperative blood loss, impaired platelet and immune functions, including T-cell-mediated antibody production and nonspecific oxidative bacterial killing by neutrophils (Sessler 2001).

Numerous studies have compared the effects of different gas conditions upon body temperature. Research into the effect of heating the dry gas (with no humidification) to body temperature has led to mixed results. Heating the insufflation gas has been shown to reduce hypothermia (Backlund et al. 1998, Ott 1991, Puttick et al. 1999), to provide no thermal benefit (Bessell et al. 1995, Saad et al. 2000, Slim et al. 1999), and conversely, to actually produce hypothermia (Nelskyla et al. 1999). When the effect of four kinds of gas (dry and cold, dry and warm, humidified and cold, humidified and warm) upon body temperature was analyzed in the same study, insufflation with warm, dry gas did not prevent hypothermia; in addition, when cold CO_2 was humidified, the decrease in core temperature was smaller than when cold, dry gas was used (Hazebroek et al. 2002). This can

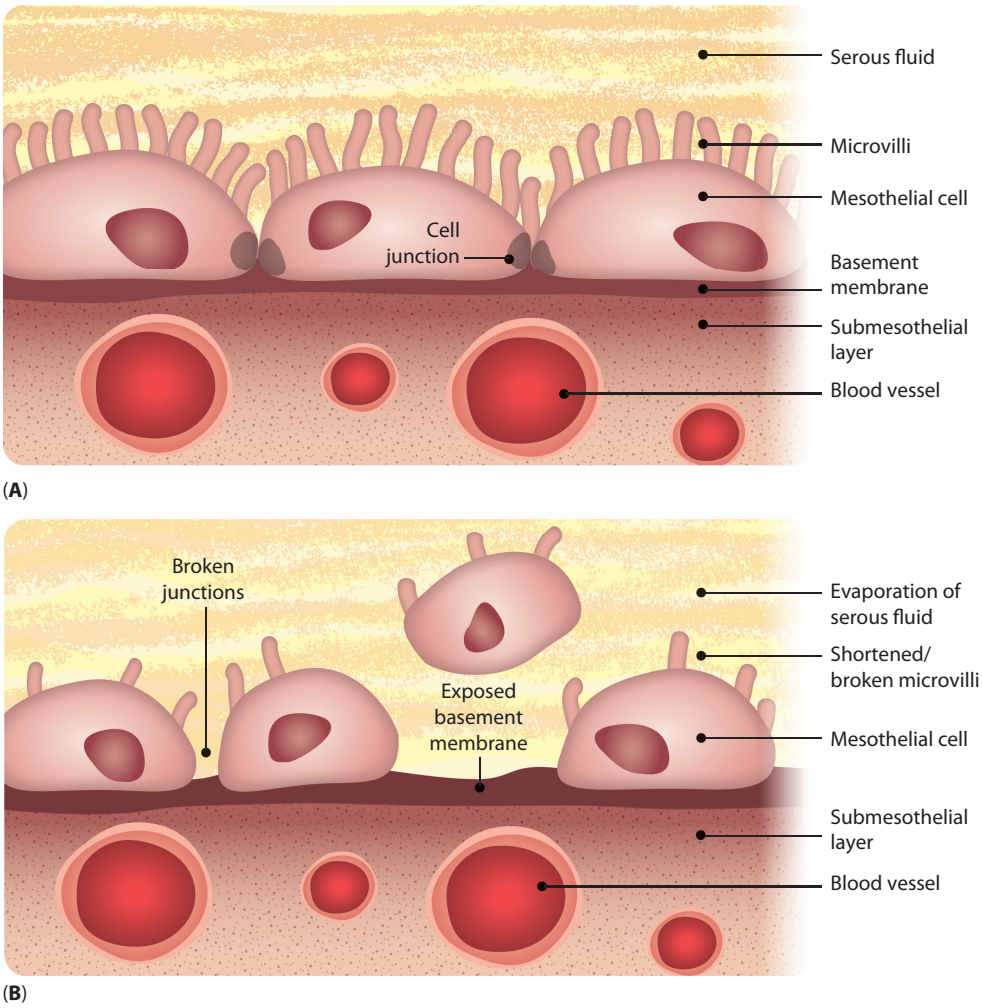

Figure 27.1 (**A**) Normal peritoneum consists of a monolayer of mesothelial cells with long microvilli and tight junctions resting on a basement membrane. (**B**) When the peritoneum is exposed to a dry environment, such as dry CO_2 or dry air, during laparoscopic or open surgery, respectively, mesothelial cells are bulged-up, the microvilli are destroyed, the junctions are broken, and the basement membrane is exposed.

be explained by the fact that the capacity of a gas to hold water vapor increases with its temperature.

Some studies have shown that cold humidification of insufflating CO_2 prevents heat loss associated with pneumoperitoneal insufflation as efficaciously as warmed humidification of the gas (Noll et al. 2012), and this is consistent with the observation that much more energy is used to humidify the gas than is needed to heat it. However, for procedures greater than 60 minutes, the use of warm and humidified gas is superior for preventing heat loss (Noll et al. 2012). Hypothermia can be fully prevented using humidified and warm gas, as shown in animal models (Bessell et al. 1999, Binda et al. 2006, Hazebroek et al. 2002, Noll et al. 2012, Peng et al. 2009), in clinical trials (Mouton et al. 1999b), and as confirmed in a meta-analysis in humans (Sajid et al. 2008).

Impact of the Dry Insufflation Gas on the Peritoneum Integrity: Tissue Damage

Several animal studies have shown that dry and cold gas is deleterious to the peritoneum, i.e., it destroys the microvilli, causes the mesothelial cells to retract and bulge, and exposes the basal lamina (Erikoglu et al. 2005, Hazebroek et al. 2002, Mouton et al. 1999b, Peng et al. 2009, Rosario et al. 2006, Suematsu et al. 2001, Volz et al. 1999). When humidified and heated CO_2 was used, fewer changes to the peritoneal layer were observed in comparison to using dry and cold gas (Erikoglu et al. 2005, Mouton et al. 1999b, Peng et al. 2009).

Following the peritoneal trauma due to the desiccating nature of the dry gas, an inflammatory reaction is produced. Two hours after a laparoscopy was performed with dry and cold CO_2, an inflammatory cell infiltration in the parietal and visceral peritoneum was observed (Papparella et al. 2007). Volz et al. (1999) showed that 12 hours after the laparoscopy, peritoneal macrophages and lymphocytes filled all gaps, recovering the basal lamina where it had been exposed. These results in animal models were confirmed in humans by Liu and Hou (2006), demonstrating that 2 hours after dry CO_2 insufflation a small amount of lymphocytes and macrophages were found in the intercellular clefts. Humidified and heated gas reduces the inflammatory response as seen in the reduction of tumor necrosis factor alpha (TNF-α) (Glew et al. 2004) and increased lymphocytes during laparoscopy (Erikoglu et al. 2005). This shows that less trauma occurs in the peritoneum with humidified gas.

Impact of the Temperature and Humidification of the Insufflation Gas on Pain

The effect of the insufflation gas temperature on postoperative pain is controversial (Kissler et al. 2004, Korell et al. 1996, Slim et al. 1999, Wills and Hunt 2000). Korell et al. (1996) demonstrated that the use of dry and warm gas reduced pain levels in a prospective randomized study. In another clinical trial, the effect of three gas conditions (humidified and heated, dry and heated, standard dry and cold gas) on postoperative pain was investigated and no significant difference in intraoperative and postoperative analgesic requirements or postoperative pain score were found (Kissler et al. 2004). However, a further, prospective, controlled, randomized, double-blinded study demonstrated that using humidified-warm gas for laparoscopic gastric banding reduces shoulder pain and decreases pain medication requirements for up to 10 days postoperatively in comparison with gas conditions used for the other groups. In addition, dry-heated gas may cause further complications since this increases pain medication use and pain intensity (Benavides et al. 2009). In another study, it was demonstrated that patients receiving heated dry gas had more early postoperative pain than those in the control group using room-temperature gas, suggesting that heated gas has no benefit in terms of pain reduction (Wills et al. 2001). The authors suggested that the drying effect of the gas could be the cause. Consistent with this, the shoulder tip and subcostal pains were more intense after using warm gas during laparoscopy (Slim et al. 1999). A possible explanation to the results obtained by the last three studies can be due to the characteristics of a dry gas. It is known that the capacity of a gas to retain water depends on its temperature: the higher the temperature, the more water a gas can hold. Therefore, when a dry gas enters the abdominal cavity, desiccation will inevitably occur (Gray et al. 1999), and it will be increased at higher temperatures. In addition, the peritoneum has a large surface with a thin serous fluid layer which facilitates humidification of the pneumoperitoneum gas. As a result, a heated gas will produce more desiccation in the abdominal cavity than does a room-temperature gas, and this peritoneal damage may cause more pain.

In regard to the use of humidified gas, many clinical studies have demonstrated that patients receiving humidified and heated insufflation gas experienced less postoperative pain. This can be seen in a variety of procedures: laparoscopic cholecystectomy (Mouton et al. 1999a), gynecological procedures (Almeida 2002, Demco 2001, Ott et al. 1998), thoracoscopic procedures (Mouton et al. 2001), and gastric bypass (Champion and Williams 2006). Moreover, two meta-analyses have been published showing that patients in the humidified and warm insufflation gas group experienced a significant reduction in pain score after surgery and in their analgesic requirements than did those in the control group which had standard cold and dry CO_2 gas (Sajid et al. 2008, Sammour et al. 2008).

Impact of the Insufflation Gas on Postoperative Adhesions

Adhesions are abnormal fibrous connections between surfaces within body cavities. Many different insults, such as infections, surgery, chemical irritation, endometriosis, and dry gas, can disrupt the peritoneum, produce inflammation, and cause adhesions to develop (Diamond and Freeman 2001). Abdominal surgery is the most common cause of adhesions with an incidence that ranges from 63% to 97% (Ellis 1997, Menzies and Ellis 1990, Weibel and Majno 1973). They are the major cause of intestinal obstruction (Ellis 1998, Menzies 1993), of female infertility (Drake and Grunert 1980, Hirschelmann et al. 2012), chronic pain, and difficulties at the time of reoperation.

It has been claimed that the desiccation caused by the standard dry and cold CO_2 pneumoperitoneum will favor the development of postoperative adhesions. The desiccation-induced adhesion formation was demonstrated to be reduced by using warm and humidified gas in animal models (Binda et al. 2006, Peng et al. 2009). Therefore, the key role of desiccation in the pathogenesis of the adhesion formation is evident. The hypothesis of desiccation as a driving mechanism in adhesion formation is supported by the data demonstrating that the dry and cold CO_2-induced pneumoperitoneum alters the morphology of the mesothelium as explained in detail previously, which can favor the development of postoperative adhesions.

The effect of using humidified insufflation gas to reduce adhesions is clear. The effect of using humidified gas at different temperatures has also been studied, showing that reducing a few degrees the temperature of the humidified gas produced less adhesion formation in mice (Binda et al. 2004, Binda et al. 2006). Consistent with these results, animal data demonstrated that peritoneal infusion with cold saline at 4°C decreased postoperative adhesions (Fang et al. 2010), whereas irrigation with saline at warmer than body temperature increased postoperative adhesions (Kappas et al. 1988). Recent experiments confirmed that peritoneal infusion with cold saline at 4°C decreased postoperative adhesions, and the same results were obtained using saline at a temperature of 10°C and 15°C (Lin et al. 2014). Several mechanisms might be involved in this beneficial effect of hypothermia. Adhesion formation might be reduced by hypothermia through protecting tissues and cells from the pneumoperitoneum-induced hypoxia, since cell oxygen consumption decreases with temperature. Indeed, hypothermia decreases the global cerebral metabolic rate during ischemia, slowing the breakdown of glucose, phosphocreatine, and adenosine triphosphate and the formation of lactate and inorganic phosphate (Erecinska et al. 2003). In addition, hypothermia reduces the production of reactive oxygen species during reperfusion (Horiguchi et al. 2003), improves the recovery of energetic parameters during reperfusion (Erecinska et al. 2003), and suppresses the inflammatory response thus decreasing the infiltration of polymorphonuclear cells and the production of TNF-α, interleukin 1β, and macrophage inflammatory protein-2 (Kato et al. 2002). In the article of Lin et al. (2014), intraperitoneal cold infusion at 4, 10, and 15°C has showed a decrease of postoperative adhesions together with a decrease of the levels of TNF-α and interleukin 6 compared with those in the group without saline infusion.

These results were further translated to clinical trials showing that it is possible to insufflate humidified gas at 32°C, reducing the abdominal temperature locally but without affecting the core body temperature (Corona et al. 2011). In a randomized controlled trial in deep endometriosis surgery (Koninckx et al. 2013), postoperative adhesions were completely prevented in 12 out of 16 women using full-conditioning (86% CO_2 + 10% N_2O + 4% O_2 for the pneumoperitoneum, humidification and

cooling of the peritoneal cavity to 32°C), heparinized rinsing solution, and 5 mg of dexamethasone together with a barrier, whereas in the control group with humidified CO_2 at 37°C (n = 211) all women had severe adhesions. In the full-conditioning group, CO_2 resorption, postoperative pain, and C-reactive protein concentrations were lower, while clinical recovery was faster and time to first flatus shorter. More clinical trials should be performed to confirm these results.

Impact of the Insufflation Gas on the Recovery Time

The time taken for a patient to recover from surgery is an important issue. Any time saved at each point of recovery also contributes to a reduction in the cost of treatment and the quality of life of the patient. Although it is clear that humidified and warm gas prevents hypothermia and pain after surgery, results related to patient recovery (Benavides et al. 2009, Davis et al. 2006, Hamza et al. 2005, Manwaring et al. 2008, Ott et al. 1998), length of hospitalization (Davis et al. 2006, Farley et al. 2004, Hamza et al. 2005, Mouton et al. 2001, Nguyen et al. 2002, Sajid et al. 2008, Savel et al. 2005), and return to normal activities are still controversial. Recovery time depends on several factors, including patient characteristics, surgeon skills, and type and duration of the surgery, and therefore makes this topic difficult to fully evaluate.

OPEN SURGERY

During open surgery, the peritoneum is exposed to dry and cold ambient air in the operating room. Taking into account the composition of air (20.9% oxygen, 78% nitrogen, 0.03% CO_2 and other gases) and that the physiologic intracellular partial pressure of oxygen and at the intercellular space is around 3% to 4% (5–40 mmHg) (Guyton and Hall 2000), this dry and hyperoxic environment will also be traumatic for the peritoneum. The effect of desiccation upon the peritoneum during open surgery will be of equal importance to that observed during laparoscopic surgery.

The idea of flooding the operative field during open surgery might sound difficult; however, it is feasible as has been demonstrated in an in vitro model (Persson et al. 2004), in animal models (Corona 2011, Marshall et al. 2015), and in humans (Frey et al. 2012a, Frey et al. 2012b). In an in vitro model, insufflation of humidified CO_2 was demonstrated to keep the open wound warm during open surgery (Persson et al. 2004). In animal models, insufflation of humidified CO_2 was demonstrated to increase intraoperative tissue oxygen tension (Marshall et al. 2015) and to reduce postoperative adhesions (Corona 2011). In patients undergoing open colon surgery, insufflation of warm and humidified CO_2 in an open surgical wound cavity via a gas diffuser was shown to increase surgical wound and core temperatures and to help to maintain normothermia (Frey et al. 2012a, Frey et al. 2012b).

CONCLUSION

The peritoneum, one of the largest organs in humans, has a very important function in the abdominal cavity: it diminishes the friction, serves as a barrier to infections, and enables the secretion of cytokines. It is a delicate layer highly susceptible to damage. Of course, it is not designed to cope with variable conditions such as being in contact with dry and cold CO_2 during laparoscopic surgery or dry and cold air during open surgery. Insufflating dry and cold CO_2 into the abdominal cavity causes peritoneal damage, postoperative pain, hypothermia, and postoperative adhesions. Humidified and warm gas reduces the inflammatory response, demonstrating that less trauma is incurred to the peritoneum. In addition, it has been clearly confirmed by meta-analysis that warm and humidified gas prevents pain after laparoscopic surgery (Sajid et al. 2008, Sammour et al. 2008). In regard to hypothermia due to desiccation, it can be fully prevented using humidified and warm gas (Sajid et al. 2008).

Using humidified and warm insufflation gas now offers a significant clinical benefit to the patient, creating a more physiologic peritoneal environment and reducing postoperative pain and hypothermia.

REFERENCES

Albanese AM, Albanese EF, Mino JH, et al. 2009. Peritoneal surface area: Measurements of 40 structures covered by peritoneum: Correlation between total peritoneal surface area and the surface calculated by formulas. *Surg Radiol Anat* **31**(5):369–77. Available from: PMID:19142561.

Almeida OD, Jr. 2002. Awake microlaparoscopy with the Insuflow device. *JSLS* 6(3):199–201. Available from: PMID:12166755.

Backlund M, Kellokumpu I, Scheinin T, et al. 1998. Effect of temperature of insufflated CO2 during and after prolonged laparoscopic surgery. *Surg Endosc* **12**(9):1126–30. Available from: PMID:9716765.

Benavides R, Wong A, Nguyen H. 2009. Improved outcomes for lap-banding using the Insuflow device compared with heated-only gas. *JSLS* **13**(3): 302–5. Available from: PMID:19793466.

Bessell JR, Karatassas A, Patterson JR, et al. 1995. Hypothermia induced by laparoscopic insufflation. A randomized study in a pig model. *Surg Endosc* **9**(7):791–6. Available from: PMID:7482186.

Bessell JR, Ludbrook G, Millard SH, et al. 1999. Humidified gas prevents hypothermia induced by laparoscopic insufflation: A randomized controlled study in a pig model. *Surg Endosc* **13**(2):101–5. Available from: PMID:9918606.

Binda MM, Molinas CR, Hansen P, et al. 2006. Effect of desiccation and temperature during laparoscopy on adhesion formation in mice. *Fertil Steril* **86**(1):166–75. Available from: PMID:16730008.

Binda MM, Molinas CR, Mailova K, et al. 2004. Effect of temperature upon adhesion formation in a laparoscopic mouse model. *Hum Reprod* **19**(11):2626–32. Available from: PMID:15333592.

Brusco GF, Arena S, Angelini A. 2003. Use of carbon dioxide versus normal saline for diagnostic hysteroscopy. *Fertil Steril* **79**(4):993–7. Available from: PMID:12749443.

Champion JK, Williams M. 2006. Prospective randomized trial of heated humidified versus cold dry carbon dioxide insufflation during laparoscopic gastric bypass. *Surg Obes Relat Dis* **2**(4):445–9. Available from: PMID:16925377.

Corona R. 2011. The role of the entire peritoneal cavity in post-operative adhesion formation: From the laboratory to the operating theatre. PhD Dissertation, Catholic University of Leuven, Leuven, Belgium. https://lirias.kuleuven.be/bitstream/123456789/314777/1/THESIS_total.pdf.

Corona R, Verguts J, Koninckx R, et al. 2011. Intraperitoneal temperature and desiccation during endoscopic surgery. Intraoperative humidification and cooling of the peritoneal cavity can reduce adhesions. *Am J Obstet Gynecol* **205**(4):392–7. Available from: PMID:21872199.

Davis SS, Mikami DJ, Newlin M, et al. 2006. Heating and humidifying of carbon dioxide during pneumoperitoneum is not indicated: A prospective randomized trial. *Surg Endosc* **20**(1):153–8. Available from: PMID:16333546.

Dellon ES, Hawk JS, Grimm IS, et al. 2009. The use of carbon dioxide for insufflation during GI endoscopy: A systematic review. *Gastrointest Endosc* **69**(4):843–9. Available from: PMID:19152906.

Demco L. 2001. Effect of heating and humidifying gas on patients undergoing awake laparoscopy. *J Am Assoc Gynecol Laparosc* **8**(2):247–51. Available from: PMID:11342732.

Diamond MP, Freeman ML. 2001. Clinical implications of postsurgical adhesions. *Hum Reprod Update* **7**(6):567–76. Available from: PM:11727865.

diZerega GS. 1997. Biochemical events in peritoneal tissue repair. *Eur J Surg Suppl* **577**:10–6. Available from: PMID:9076447.

Drake TS, Grunert GM. 1980. The unsuspected pelvic factor in the infertility investigation. *Fertil Steril* **34**(1):27–31. Available from: PMID:6447079.

Ellis H. 1997. The clinical significance of adhesions: Focus on intestinal obstruction. *Eur J Surg Suppl* **577**:5–9. Available from: PMID:9076446.

Ellis H. 1998. The magnitude of adhesion related problems. *Ann Chir Gynaecol* **87**(1):9–11. Available from: PMID:9598223.

Erecinska M, Thoresen M, Silver IA. 2003. Effects of hypothermia on energy metabolism in Mammalian central nervous system. *J Cereb Blood Flow Metab* **23**(5):513–30. Available from: PMID:12771566.

Erikoglu M, Yol S, Avunduk MC, et al. 2005. Electron-microscopic alterations of the peritoneum after both cold and heated carbon dioxide pneumoperitoneum. *J Surg Res* **125**(1):73–7. Available from: PMID:15836853.

Fang CC, Chou TH, Lin GS, et al. 2010. Peritoneal infusion with cold saline decreased postoperative intra-abdominal adhesion formation. *World J Surg* **34**(4):721–7. Available from: PMID:20049434.

Farley DR, Greenlee SM, Larson DR, et al. 2004. Double-blind, prospective, randomized study of warmed, humidified carbon dioxide insufflation vs standard carbon dioxide for patients undergoing laparoscopic cholecystectomy. *Arch Surg* **139**(7):739–43. Available from: PMID:15249406.

Frey JM, Janson M, Svanfeldt M, et al. 2012a. Intraoperative local insufflation of warmed humidified CO(2) increases open wound and core temperatures: A randomized clinical trial. *World J Surg* **36**(11):2567–75. Available from: PMID:22868970.

Frey JM, Janson M, Svanfeldt M, et al. 2012b. Local insufflation of warm humidified CO(2) increases open wound and core temperature during open colon surgery: A randomized clinical trial. *Anesth Analg* **115**(5):1204–11. Available from: PMID:22886839.

Frey JM, Svegby HK, Svenarud PK, et al. 2010. CO2 insufflation influences the temperature of the open surgical wound. *Wound Repair Regen* **18**(4):378–82. Available from: PMID:20636552.

Glew PA, Campher MJ, Pearson K, et al. 2004. The effect of warm humidified CO2 on the dissipation of residual gas following laparoscopy in piglets. *J Am Assoc Gynecol Laparosc* **11**(2):204–10. Available from: PMID:15200776.

Gray RI, Ott DE, Henderson AC, et al. 1999. Severe local hypothermia from laparoscopic gas evaporative jet cooling: A mechanism to explain clinical observations. *JSLS* **3**(3):171–7. Available from: PMID:10527326.

Guyton AC, Hall JE. 2000. Transport of oxygen and carbon dioxide in the blood and body fluids. In: Guyton AC, Hall JE, eds. *Textbook of Medical Physiology*. 10th ed. Philadelphia: WB Saunders, pp. 463–73.

Hamza MA, Schneider BE, White PF, et al. 2005. Heated and humidified insufflation during laparoscopic gastric bypass surgery: Effect on temperature, postoperative pain, and recovery outcomes. *J Laparoendosc Adv Surg Tech A* **15**(1):6–12. Available from: PMID:15772469.

Hazebroek EJ, Schreve MA, Visser P, et al. 2002. Impact of temperature and humidity of carbon dioxide pneumoperitoneum on body temperature and peritoneal morphology. *J Laparoendosc Adv Surg Tech A* **12**(5):355–64. Available from: PMID:12470410.

Hirschelmann A, Tchartchian G, Wallwiener M, et al. 2012. A review of the problematic adhesion prophylaxis in gynaecological surgery. *Arch Gynecol Obstet* **285**(4):1089–97. Available from: PMID:22037682.

Horiguchi T, Shimizu K, Ogino M, et al. 2003. Postischemic hypothermia inhibits the generation of hydroxyl radical following transient forebrain ischemia in rats. *J Neurotrauma* **20**(5):511–20. Available from: PMID:12803982.

Kappas AM, Fatouros M, Papadimitriou K, et al. 1988. Effect of intraperitoneal saline irrigation at different temperatures on adhesion formation. *Br J Surg* **75**(9):854–6. Available from: PMID:3179657.

Kato A, Singh S, McLeish KR, et al. 2002. Mechanisms of hypothermic protection against ischemic liver injury in mice. *Am J Physiol Gastrointest Liver Physiol* **282**(4):G608–16. Available from: PMID:11897619.

Kissler S, Haas M, Strohmeier R, et al. 2004. Effect of humidified and heated CO2 during gynecologic laparoscopic surgery on analgesic requirements and postoperative pain. *J Am Assoc Gynecol Laparosc* **11**(4):473–7. Available from: PMID:15701188.

Koninckx PR, Corona R, Timmerman D, et al. 2013. Peritoneal full-conditioning reduces postoperative adhesions and pain: A randomised controlled trial in deep endometriosis surgery. *J Ovarian Res* **6**(1):90. Available from: PMID:24326155.

Korell M, Schmaus F, Strowitzki T, et al. 1996. Pain intensity following laparoscopy. *Surg Laparosc Endosc* **6**(5):375–9. Available from: PMID:8890423.

Lin HF, Wu CY, Wu MC, et al. 2014. Hypothermia decreases postoperative intra-abdominal adhesion formation. *Am J Surg*. Available from: PMID:24581996.

Liu Y, Hou QX. 2006. [Effect of carbon dioxide pneumoperitoneum during laparoscopic surgery on morphology of peritoneum]. *Zhonghua Yi Xue Za Zhi* **86**(3):164–6. Available from: PMID:16638321.

Manwaring JM, Readman E, Maher PJ. 2008. The effect of heated humidified carbon dioxide on postoperative pain, core temperature, and recovery times in patients having laparoscopic surgery: A randomized controlled trial. *J Minim Invasive Gynecol* **15**(2):161–5. Available from: PMID:18312984.

Marshall JK, Lindner P, Tait N, et al. 2015. Intra-operative tissue oxygen tension is increased by local insufflation of humidified-warm CO2 during open abdominal surgery in a rat model. *PLoS One* **10**(4):e0122838. Available from: PMID:25835954.

Menzies D. 1993. Postoperative adhesions: Their treatment and relevance in clinical practice. *Ann R Coll Surg Engl* **75**(3):147–53. Available from: PMID:8323205

Menzies D, Ellis H. 1990. Intestinal obstruction from adhesions—How big is the problem? *Ann R Coll Surg Engl* **72**(1):60–3. Available from: PMID:2301905.

Mouton WG, Bessell JR, Millard SH, et al. 1999a. A randomized controlled trial assessing the benefit of humidified insufflation gas during laparoscopic surgery. *Surg Endosc* **13**(2):106–8. Available from: PMID:9918607.

Mouton WG, Bessell JR, Pfitzner J, et al. 1999b. A randomized controlled trial to determine the effects of humidified carbon dioxide insufflation during thoracoscopy. *Surg Endosc* **13**(4):382–5. Available from: PMID:10094752.

Mouton WG, Naef M, Bessell JR, et al. 2001. A randomized controlled trial to determine the effect of humidified carbon dioxide (CO2) insufflation on postoperative pain following thoracoscopic procedures. *Surg Endosc* **15**(6):579–81. Available from: PMID:11591944.

Mutsaers SE. 2004. The mesothelial cell. *Int J BiochemCell Biol* **36**(1):9–16. Available from: PMID:14592528.

Mutsaers SE, Birnie K, Lansley S, et al. 2015. Mesothelial cells in tissue repair and fibrosis. *Front Pharmacol* **6**:113. Available from: PMID:26106328.

Nelskyla K, Yli-Hankala A, Sjoberg J, et al. 1999. Warming of insufflation gas during laparoscopic hysterectomy: Effect on body temperature and the autonomic nervous system. *Acta Anaesthesiol Scand* **43**(10):974–8. Available from: PMID:10593458.

Nguyen NT, Furdui G, Fleming NW, et al. 2002. Effect of heated and humidified carbon dioxide gas on core temperature and postoperative pain: A randomized trial. *Surg Endosc* **16**(7):1050–4. Available from: PMID:12165821.

Noll E, Schaeffer R, Joshi G, et al. 2012. Heat loss during carbon dioxide insufflation: Comparison of a nebulization based humidification device with a humidification and heating system. *Surg Endosc* **26**(12):3622–5. Available from: PMID:22722768.

Ott DE. 1991. Correction of laparoscopic insufflation hypothermia. *J Laparoendosc Surg* **1**(4):183–6. Available from: PMID:1834266.

Ott DE, Reich H, Love B, et al. 1998. Reduction of laparoscopic-induced hypothermia, postoperative pain and recovery room length of stay by preconditioning gas with the Insuflow device: A prospective randomized controlled multi-center study. *JSLS* **2**(4):321–9. Available from: PMID:10036122.

Papparella A, Noviello C, Romano M, et al. 2007. Local and systemic impact of pneumoperitoneum on prepuberal rats. *Pediatr Surg Int* **23**(5):453–7. Available from: PMID:17333216.

Peng Y, Zheng M, Ye Q, et al. 2009. Heated and humidified CO2 prevents hypothermia, peritoneal injury, and intra-abdominal adhesions during prolonged laparoscopic insufflations. *J Surg Res* **151**(1):40–7. Available from: PMID:18639246.

Persson M, Elmqvist H, van der Linden J. 2004. Topical humidified carbon dioxide to keep the open surgical wound warm: The greenhouse effect revisited. *Anesthesiology* **101**(4):945–9. Available from: PMID:15448528.

Persson M, van der Linden J. 2009. Intraoperative field flooding with warm humidified CO2 may help to prevent adhesion formation after open surgery. *Med Hypotheses* **73**(4):521–3. Available from: PMID:19589645.

Puttick MI, Scott-Coombes DM, Dye J, et al. 1999. Comparison of immunologic and physiologic effects of CO2 pneumoperitoneum at room and body temperatures. *Surg Endosc* **13**(6):572–5. Available from: PMID:10347293.

Rosario MT, Ribeiro U, Jr, Corbett CE, et al. 2006. Does CO2 pneumoperitoneum alter the ultra-structuture of the mesothelium? *J Surg Res* **133**(2): 84–8. Available from: PMID:16360175.

Saad S, Minor I, Mohri T, et al. 2000. The clinical impact of warmed insufflation carbon dioxide gas for laparoscopic cholecystectomy. *Surg Endosc* **14**(9):787–90. Available from: PMID:11000355.

Sajid MS, Mallick AS, Rimpel J, et al. 2008. Effect of heated and humidified carbon dioxide on patients after laparoscopic procedures: A meta-analysis. *Surg Laparosc Endosc Percutan Tech* **18**(6):539–46. Available from: PMID:19098656.

Sammour T, Kahokehr A, Hill AG. 2008. Meta-analysis of the effect of warm humidified insufflation on pain after laparoscopy. *Br J Surg* **95**(8):950–6. Available from: PMID:18618870.

Savel RH, Balasubramanya S, Lasheen S, et al. 2005. Beneficial effects of humidified, warmed carbon dioxide insufflation during laparoscopic bariatric surgery: A randomized clinical trial. *Obes Surg* **15**(1):64–9. Available from: PMID:15760500.

Sessler DI. 2001. Complications and treatment of mild hypothermia. *Anesthesiology* **95**(2):531–43. Available from: PMID:11506130.

Slater NJ, Raftery AT, Cope GH. 1989. The ultrastructure of human abdominal mesothelium. *J Anat* **167**:47–56. Available from: PMID:2630540.

Slim K, Bousquet J, Kwiatkowski F, et al. 1999. Effect of CO(2) gas warming on pain after laparoscopic surgery: A randomized double-blind controlled trial. *Surg Endosc* **13**(11):1110–4. Available from: PMID:10556449.

Suematsu T, Hirabayashi Y, Shiraishi N, et al. 2001. Morphology of the murine peritoneum after pneumoperitoneum vs laparotomy. *Surg Endosc* **15**(9):954–8. Available from: PMID:11443469.

Volz J, Koster S, Spacek Z, et al. 1999. Characteristic alterations of the peritoneum after carbon dioxide pneumoperitoneum. *Surg Endosc* **13**(6):611–4. Available from: PMID:10347302.

Weibel MA, Majno G. 1973. Peritoneal adhesions and their relation to abdominal surgery. A postmortem study. *Am J Surg* **126**(3):345–53. Available from: PMID:4580750.

Wills VL, Hunt DR. 2000. Pain after laparoscopic cholecystectomy. *Br J Surg* **87**(3):273–84. Available from: PMID:10718794.

Wills VL, Hunt DR, Armstrong A. 2001. A randomized controlled trial assessing the effect of heated carbon dioxide for insufflation on pain and recovery after laparoscopic fundoplication. *Surg Endosc* **15**(2):166–70. Available from: PMID:11285961.

Yamano HO, Yoshikawa K, Kimura T, et al. 2010. Carbon dioxide insufflation for colonoscopy: Evaluation of gas volume, abdominal pain, examination time and transcutaneous partial CO(2) pressure. *J Gastroenterol. Available* from: PMID:20635100.

28 Robotic surgery

Rabbie K. Hanna and John F. Boggess

INTRODUCTION

The robotic platform has enhanced the role of minimal invasive surgery, especially in complex pelvic surgical procedures. In addition to the significant reduction in perioperative morbidity, mortality, and length of hospital stay, as has been proven with conventional laparoscopy, this platform has allowed for less conversions to laparotomy along with better surgical maneuverability while operating in the complex pelvis (Boggess et al. 2008a,b, 2009). The robotic platform, manifested currently as the da Vinci system (Intuitive Surgical, Inc., Sunnyvale, California, USA), has found its path into many of our complex gynecologic oncology procedures.

A description of the operative room setup and anesthesia challenges in addition to patient preparation and positioning are discussed in this chapter. A brief description of key points of the operative procedures performed with the robotic platform are presented.

ADVANTAGES AND DISADVANTAGES

The da Vinci robotic system offers the following:

1. A better and stable 3D operative visualization enhanced by the ability of digital zooming.
2. Seven degrees of freedom of articulation offering improved dexterity coupled with elimination of the fulcrum effect.
3. Computer filtration of physiologic tremor.
4. Better ergonomics for the surgeon with the added benefit of increasing his/her longevity.
5. The learning curve is significantly enhanced as compared to conventional laparoscopy.

The disadvantages are summarized in the bulkiness of the robotic system, necessitating dedicated operating rooms. To that note, advances in robotics technology are producing systems that diminish the operating room footprint. The ongoing debate of cost has not been settled, as more in-depth analyses of hospital finances are needed to settle this issue. The cost-effectiveness dialog is complex and strongly contested, as both cost (easy to measure) and effectiveness (difficult to quantify) are endpoints with non-uniform definitions.

OPERATIVE ROOM SETUP

The current size of the robotic platform necessitates a larger operating room than that of a conventional laparoscopy setting. A well thought out operating room setup will optimize the surgical care provided to the patient. The setup should allow for easy communication among all members of the operative team in addition to easy patient accessibility. Thus, an ergonomic layout of the various components plays a significant role in a smooth perioperative flow of events. We will discuss the setup we currently use for our gynecologic procedures. With this setup, both types of docking (centrally between the lower limbs and side docking) are applicable.

The robotic platform (Figure 28.1) is composed of a surgeon console, a patient side cart that is composed of the surgical cart and the robotic arms, and the vision system that is composed of the video cart that harbors two video control boxes, light sources, and a synchronizer. The imaging unit is placed in a pivotal point of the surgical theater with the surgical console in the corner as shown in Figure 28.1. (The surgeon's console and the imaging unit are stationary.) The patient's bed is placed in front of the imaging unit, with the anesthesia team and the surgical cart cephalad and caudad to the patient, respectively.

The console is placed in a corner, allowing the surgeon to have visual communication with the primary assistant and the anesthesia team (Figure 28.1). Audio communication is enhanced by built-in speakers through the console.

An accessory tower is placed to the side of the video cart. This contains the cautery sources, the light source, and laparoscopy monitor for conventional laparoscopic equipment, and an insufflator machine. As shown in Figure 28.1, our operating room is supplemented with two additional monitors allowing both assistants to visualize the procedure from any angle.

PATIENT POSITIONING AND RELATED ANESTHESIA REQUIREMENTS

From an anesthetic standpoint, it is well known that most of our patients are advanced in age with multiple comorbidities such as hypertension, diabetes, etc. These pose an anesthetic challenge and are managed according to pre-existing guidelines perioperatively which are not within the scope of this chapter. In addition to the preoperative visit and the necessary physical examination performed, all of our patients have their appropriate laboratory data reviewed by the primary surgical team and the anesthesia team. In addition, they are interviewed and examined by the anesthesia team members.

All intravenous (or arterial) lines are to be placed prior to patient positioning. The patient is placed in a lithotomy position with the arms tucked to her sides after wrapping the elbows with a gel pads (to protect the bony prominences). Sponge padding at the level of the hands avoids pressure injury to the stirrup joints. The patient is placed in a dorsal lithotomy position on a torso-length gel pad. Shoulder blocks are placed above the acromioclavicular joints after the arms are tucked at the patient's side (Shafer and Boggess 2008). Insufflation of the peritoneal cavity with CO_2 is performed prior to placing her in the desired Trendelenburg position.

Due to this positioning, intravenous accesses need to be secured without kinks and compression. As the patient's accessibility by the anesthesiologists is limited, more than one intravenous access is necessary in addition to a lower threshold

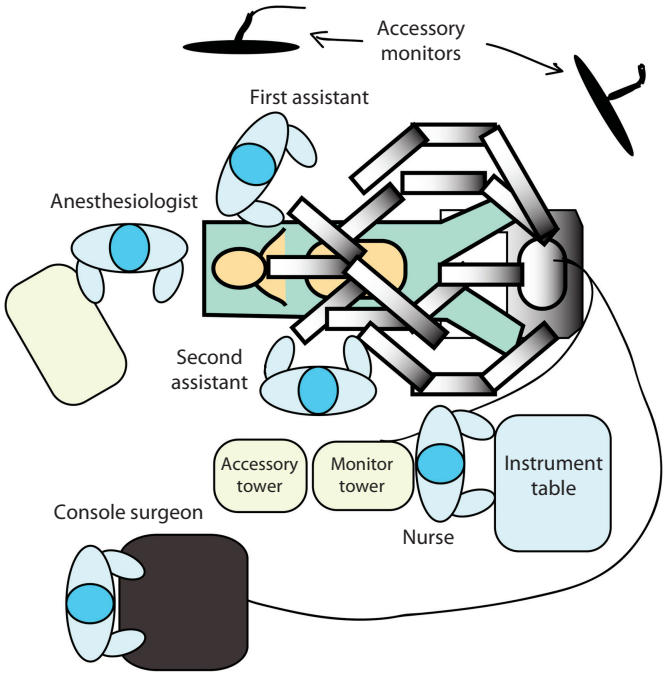

Figure 28.1 A schematic representation of our current operating room setup. The surgeon is in direct visual communication with the bedside assistant (first assistant) and the anesthesiologist. Two adjustable accessory monitors are available for use by the assistants and observers from different angles of the operating room.

of using invasive monitoring which is judged based on the combined experience and comfort level of both the surgical and anesthesia teams. As the surgical cart is placed in between the patient's lower limbs, care should be taken to position the limbs in a manner that will avoid contact with the mobile elements of the cart, keeping in mind not to extend the hip joint excessively and cause femoral nerve injury.

The patient is ventilated with pressure control rather than volume control that helps to minimize wide excursion and movement during dissection and reduces the risk of barotrauma. Pressure-controlled anesthesia is mandatory for obese women placed in a steep Trendelenburg position (Shafer and Boggess 2008).

Decompression of the stomach contents via an orogastric or nasogastric tube is necessary. Kinking of the endotracheal tube or its dislodgement is of concern when the robot is docked over the patient's head as advocated by some of our colleagues.

Once the platform is docked, the patient's position cannot be altered; thus it is essential to place the patient in the desired Trendelenburg position and adjust accordingly before docking the system. Therefore complete immobility via muscle relaxation is required and should be monitored for prior to docking the system. All members of the surgical team should be trained in emergency undocking if the situation arises. This requires prompt and clear communication among the surgical and anesthesia team members. As noted in our current operating room setup (Figure 28.1), the anesthesiology team and their equipments' position are not in contact with robotic components.

OPERATIVE ENTRY

We start all our robotic procedures in the same fashion from an entry standpoint. After appropriate sterilization and draping of the patient, an incision of 2 to 3 mm is made in Palmer's point and a 2-mm trocar is inserted into the peritoneal cavity followed by insufflation with CO_2 with a goal of 12 to 15 mmHg intra-abdominal pressure. A survey of the abdomen and pelvis is then performed with a 2-mm laparoscope. The patient is then placed in the maximum tolerated Trendelenburg position. The abdomen is marked for the appropriate procedure (Figures 28.2 and 28.3). Any adhesions are taken down using conventional laparoscopic techniques unless they can be done robotically.

SURGICAL PROCEDURES

In this section, we describe port placements for each surgical procedure and discuss the instruments used in addition to tips and challenging points if applicable.

Endometrial Cancer Staging

Robotic-assisted endometrial cancer staging has been a significant application of robotics in gynecologic oncology (Boggess 2007). The port site configuration we advocate in robotic staging of endometrial cancer is shown in Figure 28.2. After entry via the left upper quadrant (LUQ) and insufflation of the peritoneal cavity, the camera port is marked 23 to 25 cm above the symphysis pubis. The two lateral ports are placed at 15° below and 10 cm away from the camera port. A third port site is marked 10 cm away from the left laterally toward the left anterior–superior iliac spine. A 10 to 12 bladeless trocar is used for the camera site, the 8-mm robotic trocars are placed in their respective ports, and the assistant port is converted to a 10- to

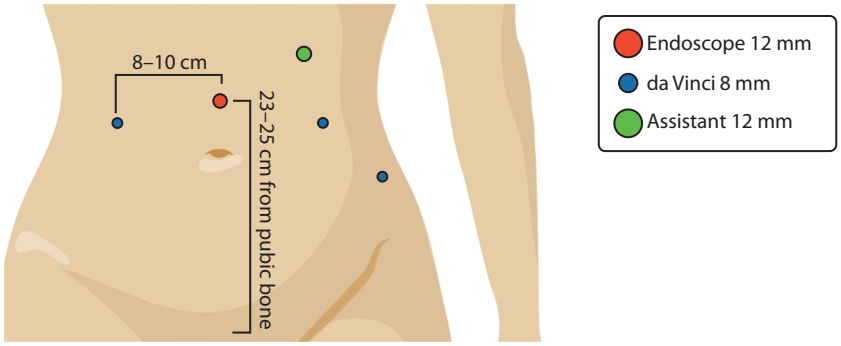

Figure 28.2 The port placement for robotic-assisted endometrial staging. If the surgeon is not planning on para-aortic lymph node dissection, we recommend using the port placement in Figure 28.3. (Courtesy of John F. Boggess, 2010.)

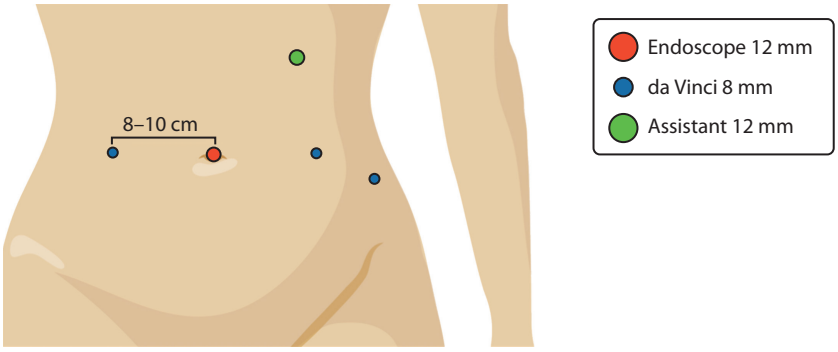

Figure 28.3 The port placement for robotically assisted radical hysterectomy, radical trachelectomy, and radical parametrectomy. (Courtesy of John F. Boggess, 2010.)

12-port (which allows introduction of Ray-Tec sponges and introduction of endoscopic pouches).

Instruments

1. A zero-degree camera.
2. Zumi™ uterine manipulator and Kho™ rings for delineation of the vaginal cuff.
3. Hot Shears™ (monopolar curved scissors) used for dissection in addition to cold and hot cutting and monopolar cautery.
4. Fenestrated bipolar forceps, which has the capability of coagulating the uterine and ovarian vessels, eliminating the need for laparoscopic vascular clips. Another fenestrated forceps is applied to the third arm to assist in intraoperative retraction.
5. SutureCut™ needle driver for vaginal cuff closure.

Surgical Tips

- Many endometrial cancer patients are obese; thus, a gradual rather than sudden Trendelenburg positioning illustrates the real capacity of how much can be tolerated by the patient.
- The curved abdomen in obese patients allows for a larger surface area for port placement.
- The procedure begins with the para-aortic lymph node dissection (PA-LND) to avoid accumulation of blood and fluid from the pelvic part of the procedure. During this part of the surgery, we ask the anesthesiologist to run the patient dry to minimize the excursion of the inferior vena cava during the lymph node dissection.
- Fold the bowel to uncover the root of the mesentery (Figure 28.4) in preparation of PA-LND prior to docking the robotic system but after maintaining

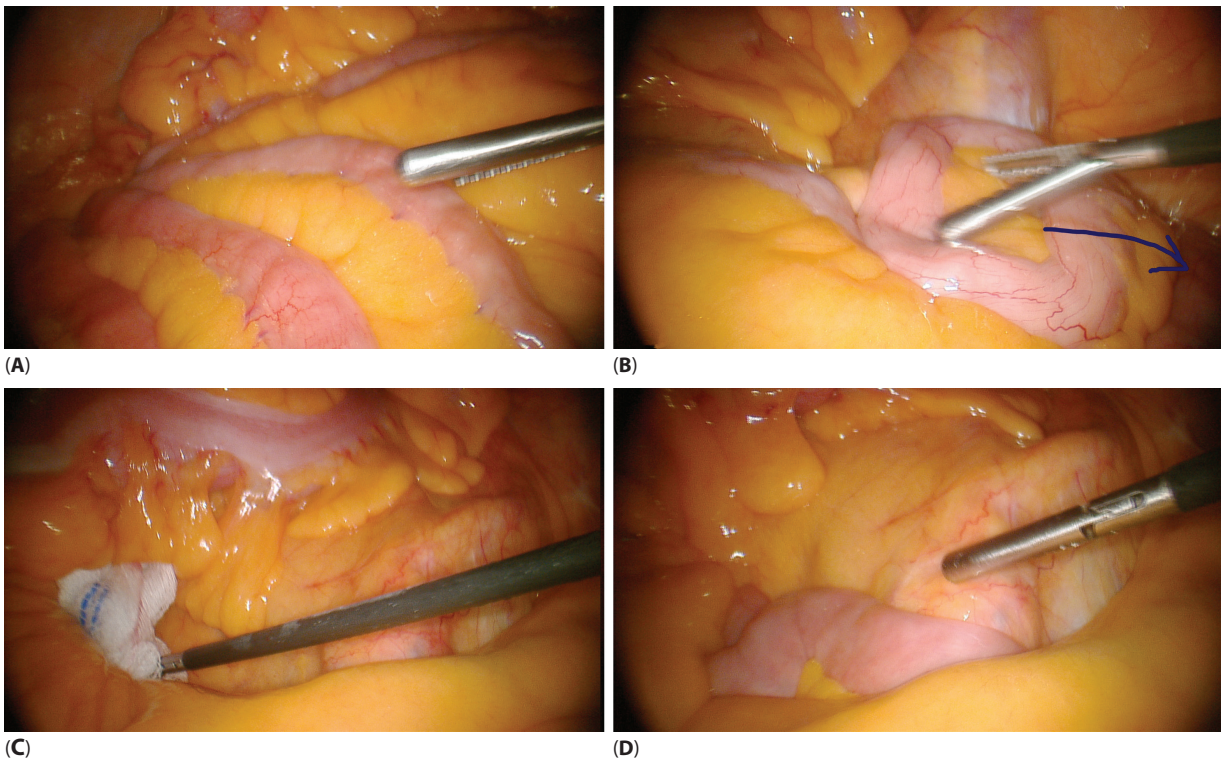

Figure 28.4 The appropriate para-aortic lymph node dissection exposure is achieved by folding the small bowel loops systematically using a 45-cm bariatric atraumatic laparoscopic grasper. (**A**) The proximal bowel loops are folded toward the left upper quadrant, loop by loop, starting with the most cephalad loops. (**B**) The distal small bowel is folded toward the right. (**C**) A Ray-Tec sponge may be inserted to prevent some small intestine loops from slipping into the operative field, as shown in **D**.

Trendelenburg positioning. This is done utilizing a 45-cm bariatric atraumatic laparoscopic grasper.

- The distal small bowel is folded toward the right (Figure 28.4B), whereas the proximal bowel loops are folded to the left side and slightly cephalad (Figure 28.4A). Folding the bowel should be performed elegantly without pushing the bowel into the upper abdomen. In some occasions, a Ray-Tec sponge may be inserted (Figure 28.4C) to prevent some small intestine loops from slipping into the operative field (Figure 28.4D). In patients with a short small bowel mesentery, the peritoneal incision over the aortic root will effectively lengthen it and the edge can be tented upward by the assistant using a laparoscopic grasper to create a shield against the small bowel loops cephalad to it (Figure 28.5).
- On rare occasions, adhesions in the upper abdomen could assist as natural retractors in holding the small bowel in place; thus, lysis of adhesions should be performed in a strategic manner.
- In patients with a redundant sigmoid colon that might overlay the root of the aorta, a figure-of-eight suture can be placed through the tenia coli and sutured to the anterior abdominal wall.
- While performing the PA-LND, the surgeon can achieve an easier dissection by placing the shears in the second robotic arm to be operated by the surgeon's left hand. Of note, the camera is rotated 90° so that the aorta lies horizontal with its most cephalad end to be located on the right of the surgical field.
- We advocate utilizing the robotic equipment rather than foreign apparatuses for vessel coagulation to minimize time without sacrificing technique and outcomes. Bipolar cautery is safe for vessels up to 8 mm in diameter. The cautery's current setting should be set at 45 W.
- Utilizing the least amount of cautery while performing the colpotomy minimizes the thermal injury to the vaginal cuff and decreases the chance of cuff dehiscence postoperatively. Using a single-blade maneuver during colpotomy will also minimize the thermal injury but increases the possibility of vaginal cuff bleeders that can be controlled with pinpoint cautery or while suturing the cuff.
- A water seal vaginal cuff closure can be performed by holding the suture tightly by the help of the assistant utilizing a laparoscopic needle holder while the console surgeon is suturing the cuff (Figure 28.6).
- Utilize the third arm as a retractor as much as possible. This allows for better control over the surgical field by the surgeon himself and the assistant will be freed from unnecessary stationary postures.

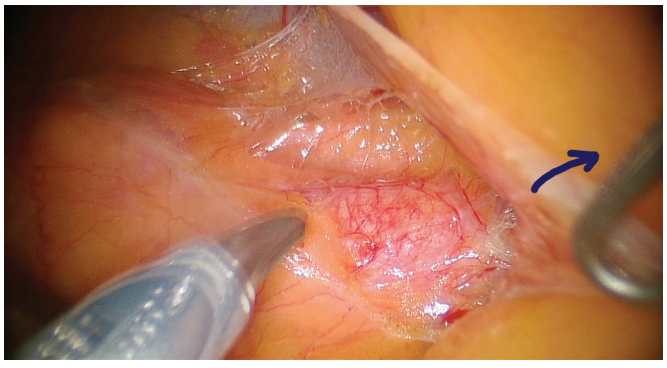

Figure 28.5 In patients with a short small bowel mesentery, the peritoneal incision over the aortic root will effectively lengthen it, and the edge can be tented upward by the assistant using a laparoscopic grasper to create a shield against the small bowel loops cephalad to it. The site of the arrow is where the grasper will be placed.

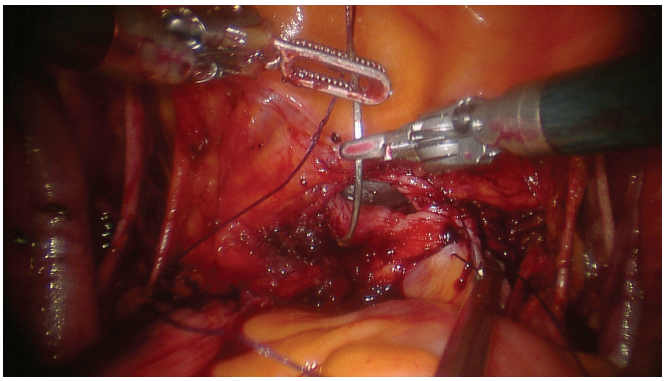

Figure 28.6 The assistant uses a laparoscopic needle driver to hold the suture on tension while console surgeon is suturing the vaginal cuff. This allows for a secure approximation of the vaginal cuff.

Radical Hysterectomy, Radical Trachelectomy, and Radical Parametrectomy

The port site configuration we advocate in these procedures is shown in Figure 28.3. After entry via the LUQ and insufflation of the peritoneal cavity, the camera port is marked at the supraumbilical site. The two lateral ports are placed 10 cm away from the camera port, maintaining a straight line across all three port sites. A third port site is marked 10 cm away from the left lateral toward the left anterior superior iliac spine. A 10 to 12 bladeless trocar is used for the camera site, the 8-mm robotic trocars are placed in their respective ports, and the assistant port is converted to a 10- to 12-port (which allows introduction of Ray-Tec sponges and introduction of endoscopic pouches).

Instruments

1. A zero-degree camera.
2. An EEA sizer for identification of the vaginal fornices and achieving a good vaginal margin.
3. Hot Shears (monopolar curved scissors) used for dissection in addition to cold and hot cutting and monopolar cautery.
4. The Maryland forceps' tips are utilized as excellent dissectors at the level of the ureteric tunnels and uterine artery dissection.
5. Fenestrated forceps is applied to the third arm and assists in retraction intraoperatively.
6. SutureCut needle driver for vaginal cuff closure.

Surgical Tips

In addition to the tips mentioned in the endometrial staging section (when applicable) the following should be considered in cervical cancer surgery.

- Restoration of the normal anatomy by developing all the appropriate surgical spaces allows for a smoother operative procedure.
- We advocate for preservation of the uterine arteries when performing a radical trachelectomy.
- When dissecting the ureteric tunnels, the ureter is protected from the bipolar cautery thermal effect by deviating it with the tips and body of the scissors.
- To perform an optimal pelvic lymph node dissection, the following is stressed: after deviating the superior vesical artery medially and releasing the lymphatic and adipose tissue from its lateral side, the space between the obturator lymphatic bundle and the psoas muscle is entered lateral to the external iliac vessels, allowing release of the lateral attachments of the obturator lymphatic bundle (Figure 28.7). In addition, removal of all lymphatic tissue in between the external iliac artery and vein should be performed.
- Separation of the neural bundle parallel and lateral to the uterosacral ligament can be achieved by gently separating it from the ligament without unnecessarily dissecting the lateral aspect of the ligament. This minimizes nerve damage and avoids bladder dysfunction.
- Closure of the vaginal cuff is performed with two separate sutures, one on each half of the vaginal cuff.

Pelvic Masses in Pregnancy

To date, we have performed close to 25 robotic-assisted ovarian cystectomies or adnexectomies in pregnancy. The advantages of the robotic platform are improving the success rate of the intended procedure minimizing the chances of laparotomy during pregnancy. All of our patients had the desired procedure performed successfully without any complications. We attempt to schedule the procedure in the 16- to 20-week gestation period. The challenge such patients pose is related to the size of the ovarian pathology. Any suspicious ovarian cysts or masses should be dealt with carefully to avoid intraperitoneal rupture. An endoscopic pouch is inserted to contain them as they are removed and safely morcellated through one of the ports.

Port placement is not universal, and the following tips are followed:

- Entry through the left upper quadrant, as mentioned earlier.
- Placement of the camera port above the umbilicus by 3 to 7 cm, depending on the gestational age, to avoid the gravid uterus and provide a better view of the pelvic organs.
- The two lateral ports must maintain the universal distance of 8 to 10 cm from the camera port.
- Utilization of two robotic arms rather than three, with the bipolar fenestrated grasper on the left arm and the monopolar shears on the right.
- On rare occasions where the uterus is larger than 20 to 22 weeks, a deviation in the port placement plan is allowed. In such situations, the potential space in the left upper quadrant is utilized for the camera port with placement of the other two robotic ports 8 to 10 cm on either side (Figure 28.8).

Other Uses of the Robotic Platform

- Management of urinary system complications such as ureteric reanastomosis or ureteroneocystotomy formation.
- Bulky lymph node dissection.
- Staging ovarian cancer in its early stages, which requires careful laparoscopic evaluation of the bowel loops and the upper abdomen to rule out the presence of metastatic implants.
- Localized recurrence of pelvic malignancies and pelvic exenterative procedures.

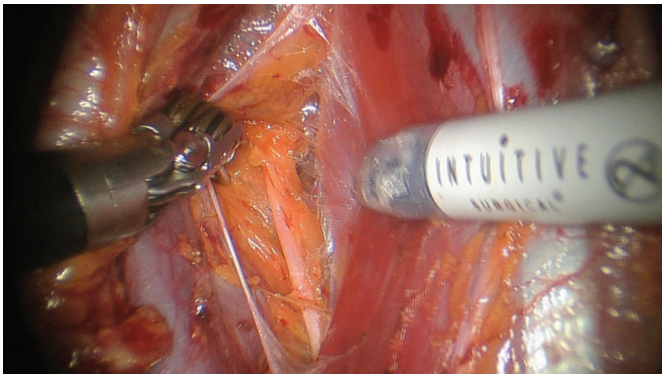

Figure 28.7 Portion of the right pelvic lymph node dissection, depicting an efficient method to locate the obturator nerve and release the most lateral attachments of the lymphatic bundle from the pelvic sidewall muscles; the space is approached lateral to the external iliac vessels.



Figure 28.8 A deviation in port placement is sometimes necessary, such as in this patient where the camera port is situated in the left upper quadrant and the two lateral ports are maintained at a distance of 10 cm from each side.

REFERENCES

Boggess J. 2007. Robotic surgery in gynecologic onology: Evolution of a new surgical paradigm. *J Robotic Surg* **1**:31–7.

Boggess JF, Gehrig PA, Cantrell L, et al. 2008a. A comparative study of 3 surgical methods for hysterectomy with staging for endometrial cancer: Robotic assistance, laparoscopy, laparotomy. *Am J Obstet Gynecol* **199**:360.e1–9.

Boggess JF, Gehrig PA, Cantrell L, et al. 2008b. A case-control study of robot assisted type III radical hysterectomy with pelvic lymph node dissection compared with open radical hysterectomy. *Am J Obstet Gynecol* **199**:357.e1–7.

Boggess JF, Gehrig PA, Cantrell L, et al. 2009. Perioperative outcomes of robotically assisted hysterectomy for benign cases with complex pathology. *Obstet Gynecol* **114**:585–93.

Shafer A, Boggess JF. 2008. Robotic-assisted endometrial cancer staging and radical hysterectomy with the da Vinci surgical system. *Gynecol Oncol* **111**:S18–23.

29 Gastrointestinal surgery in gynecologic oncology

Eileen M. Segreti, Stephanie Munns, and Charles M. Levenback

INTRODUCTION

The gastrointestinal tract is frequently affected by advanced or recurrent gynecologic malignancies. Complete removal of gynecologic tumors may require gastrointestinal surgical procedures. The gastrointestinal tract is often injured during the course of treatment, requiring subsequent surgical intervention during the follow-up period, particularly after exposure to ionizing radiation. High risk factors such as malnutrition and cancer cachexia increase the chance of a gastrointestinal complication. Finally, gastrointestinal symptoms may dominate end-of-life circumstances, necessitating palliative gastrointestinal procedures. This chapter focuses on common surgical procedures performed on the gastrointestinal tract during the management of gynecologic malignancies. Since gynecological oncologists are most familiar with the natural history of the underlying disease, these procedures are best done by them and not by other surgical consultants.

STOMACH

Indications

The most common procedure on the stomach performed in the management of gynecologic malignancy is the tube gastrostomy. Gastrostomy tubes are useful for decompression of the stomach and the small bowel. In the postoperative setting, gastrostomy tubes may also be used for enteral nutrition. A prolonged ileus may occur after small bowel resection and enterolysis for radiation complications. Most commonly in gynecologic patients, gastrostomy tubes are used to palliate women with end-stage ovarian cancer who suffer with vomiting secondary to carcinomatosis and multiple areas of partial small bowel obstruction not amenable to surgical correction. Gynecologic oncologists often operate on or near the stomach, as it is a site of metastatic disease or must be displaced to access other sites such as the pancreas, spleen, and lesser sac. Access to the celiac and superior mesenteric artery (SMA) nodes is also possible by displacing the stomach cephaled.

Anatomic Considerations

The blood supply to the stomach is derived from the celiac trunk. The greater curvature of the stomach is supplied by the right and left gastroepiploic arteries. The lesser curvature is supplied by the right and left gastric arteries. The right gastric artery and the right gastroepiploic artery are branches of the common hepatic artery and gastroduodenal artery, respectively. The left gastric artery is a branch of the celiac trunk, and the left gastroepiploic artery is a branch of the splenic artery. Routes of venous drainage include the gastric and gastroepiploic veins as well as small tributaries of the esophageal veins.

Surgical Procedures

Gastrostomy tubes may be placed percutaneously with endoscopic guidance or may be placed at the time of laparotomy or laparoscopy. The stomach should be mobile enough to reach the anterior abdominal wall. Multiple tubes can be utilized for this purpose, including a specialized gastrostomy tube or a self-retaining flanged Malecot urologic tube, or even a Foley catheter can placed into the stomach via a left upper quadrant incision. Two concentric purse-string sutures of absorbable suture are placed in the anterior stomach seromuscular wall approximately 1 cm apart. An electrosurgical monopolar instrument is used to create an opening in the stomach through which the tube is placed. The inner purse-string is tied first, then the outer purse-string, creating an inverted tunnel. Three to four interrupted 2-0 nonabsorbable sutures are placed to approximate the stomach to the anterior abdominal wall. After the abdomen is closed, the tube is secured to the skin with a nonabsorbable suture (Figure 29.1). If the tube is subsequently dislodged, it can often be immediately replaced through the gastrocutaneous fistula. Since the indication for a gastrostomy tube may not be apparent preoperatively, it cannot always be anticipated and therefore may not be included in the consent.

SMALL BOWEL

Introduction

Small bowel resection is often necessary to remove strictured, perforated, or tumor-infiltrated intestine. Resection of small bowel is preferred over bypassing a damaged segment. However, a bypass procedure may be preferable when damaged small bowel is densely adherent to a fibrotic and heavily irradiated pelvis. If the stomach is not accessible for a safe tube gastrostomy, a small bowel bypass may be considered to palliate an intestinal obstruction in a woman with advanced gynecologic cancer.

Anatomic Considerations

The small bowel begins at the pylorus and ends at the ileocecal valve. The duodenum and jejunum are separated by the ligament of Trietz. The duodenum is almost entirely retroperitoneal. The distinction between the jejunum and the ileum is gradual. The small bowel is perfused by straight vessels that disperse into the anterior and posterior surfaces of the bowel. The straight vessels emerge from the arcades of the superior mesenteric artery. In the ileum the straight vessels are surrounded by fat, and the fat encroaches upon the bowel wall. In the jejunum, the vasa recta are more easily seen, as the mesenteric fat ends prior to reaching the jejunal serosa. Increasing population obesity is making this distinction less apparent. The venous drainage of the small bowel is to the superior mesenteric vein which

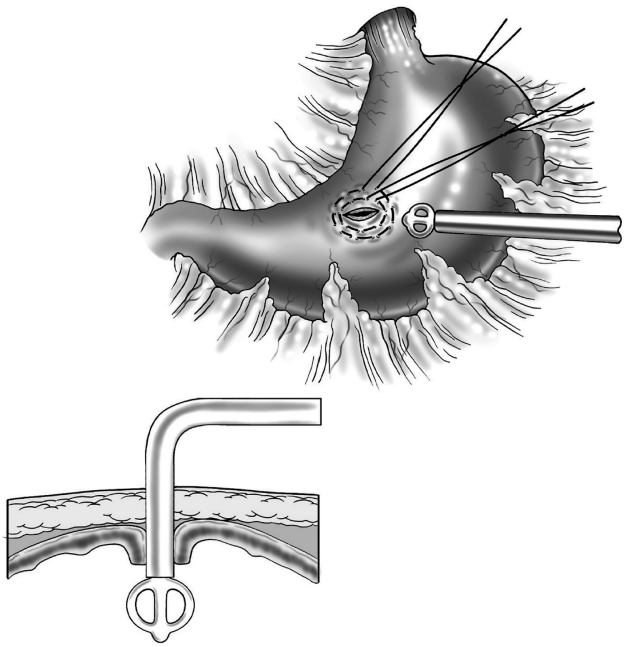

Figure 29.1 Gastrostomy tube with Malecot urologic catheter.

is a tributary of the portal vein. The autonomic nervous system, in conjunction with the gastrointestinal hormonal system, regulates peristalsis and bowel secretory action. The parasympathetic ganglia lie within the bowel wall, whereas the sympathetic ganglia lie close to the origin of the superior mesenteric artery.

The small intestine has four layers: the mucosa, the submucosa, the muscularis, and the serosa. The mucosa contains villi and crypts, which greatly increase the absorptive surface area. The submucosa is a strong connective tissue layer important for structural integrity. It is essential to include this layer during bowel anastomosis. The muscularis consists of an inner circular layer and an outer longitudinal layer. The serosa is the outermost layer and is a continuation of the mesothelium that lines the peritoneal cavity (Figure 29.2).

The terminal ileum is the site of absorption of the fat-soluble vitamins, A, D, E, and K, as well as vitamin B12. Extensive resection of the terminal ileum will require supplementation.

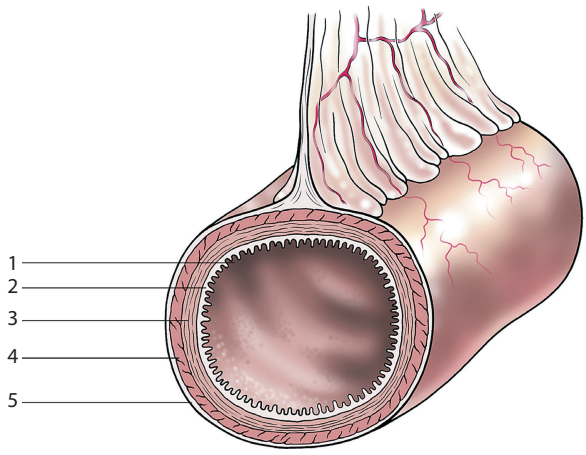

Figure 29.2 Layers of the small intestine wall. 1: Mucosa; 2: submucosa; 3: inner circular muscle; 4: outer longitudinal muscle; 5: serosa.

Surgical Procedures

To be successful, a small bowel resection must completely remove the damaged or involved intestinal segment. Intestinal continuity must then be re-established using healthy ends of bowel with good blood supply that are reapproximated without tension. Tissues should be handled gently, and a watertight anastomosis should be achieved. There should be no downstream areas of obstruction that could adversely affect healing. The submucosal layer of the bowel wall is the most critical layer to incorporate into the anastomosis. There are several different means to effect a small bowel anastomosis. Staplers are commonly used. A handsewn anastomosis takes more time, but requires no special devices. It is important to be familiar with both methods of bowel anastomosis (Matos et al. 2001).

The damaged or obstructed portion of the small bowel is identified. The vascular arcades are visualized by transillumination. Either a linear cutting stapler or Kocher clamps are used to isolate the abnormal section of small intestine. The stapler or clamps are oriented obliquely to maximize the mesenteric side of the bowel and minimize the antimesenteric side (Figure 29.3). This maneuver will also create a larger lumen, thereby decreasing the chance of a subsequent stricture. The mesentery is scored with scissors or with an electrosurgery device, and the vessels are isolated between small clamps. The vessels are cut and secured with 2-0 suture. Alternatively, a vascular stapler or an electrothermal bipolar tissue fusing device can be used to secure the mesenteric vessels. There is no clinically significant difference between these techniques.

Commonly, staplers are used to create a side-to-side, functional end-to-end, anastomosis. The ends of the small bowel are juxtaposed and inspected for viability. If there is any doubt as to bowel viability, the bowel is excised further until there is no question as to the quality of the bowel. The anastomosis must be tension-free. The bowel loops are mobilized as necessary to relieve any tension. The antimesenteric borders are lined up in parallel. Stay sutures may be placed 5 to 8 cm from the closed bowel ends along the antimesenteric border to facilitate proper

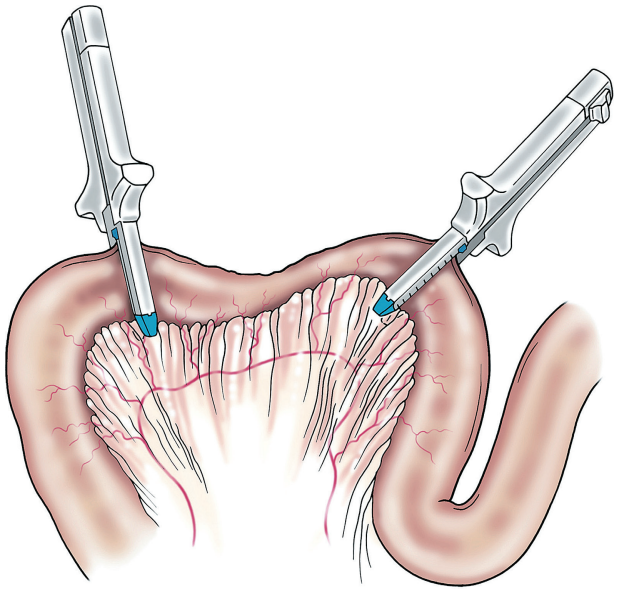

Figure 29.3 Positioning of clamps.

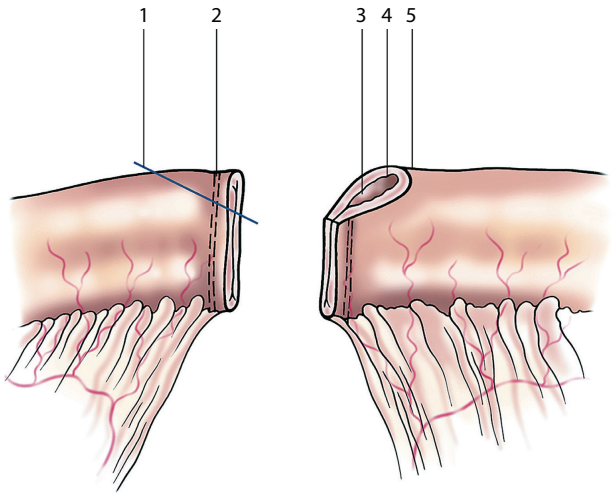

Figure 29.4 Preparation for anastomosis. 1: Incision; 2: staple line; 3: bowel lumen; 4: mucosa; 5: serosa.

alignment. The corners of the antimesenteric staple line are then excised (Figure 29.4). One arm of the stapler is then placed along the antimesenteric border of each limb of bowel and the stapler closed (Figures 29.5 and 29.6). Firing the stapler places two or three double rows of titanium staples, between which a knife cuts. Typically, staples used for small bowel anastomosis are 4 mm in width when open and 3.5 mm in depth, with a closed depth of 1.5 mm, contained often in a blue-colored cartridge. The staple line is then inspected for bleeding. Any bleeding area should be reinforced with an interrupted absorbable suture. The remaining luminal opening is grasped with Allis clamps, and a thoracoabdominal (TA) stapler is set and fired to close the remaining enterotomy. The staple lines should overlap to prevent leakage at the anastomosis (Figure 29.7). Excess tissue above the TA device can be excised. Staplers are held in place closed for approximately 60 seconds prior to firing.

The small bowel can also be anastomosed end to end with a single or double layer of sutures. If the bowel lumens are of disparate sizes, to equalize them a Cheatle slit can be made on the antimesenteric border of the smaller lumen (Figure 29.8). After the bowel is anastomosed, the mesenteric defect is then closed to prevent an internal hernia and subsequent bowel strangulation.

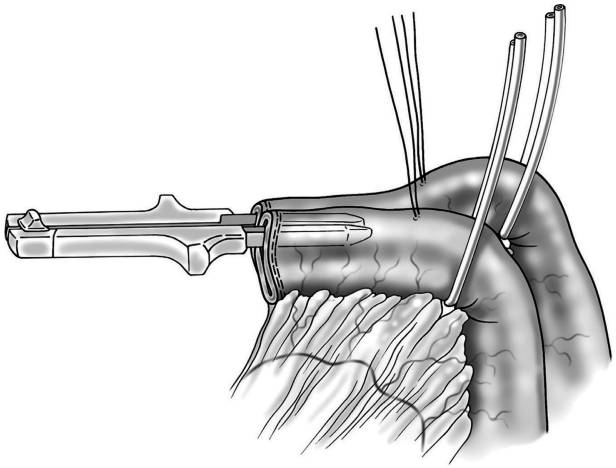

Figure 29.5 Positioning of stapler.

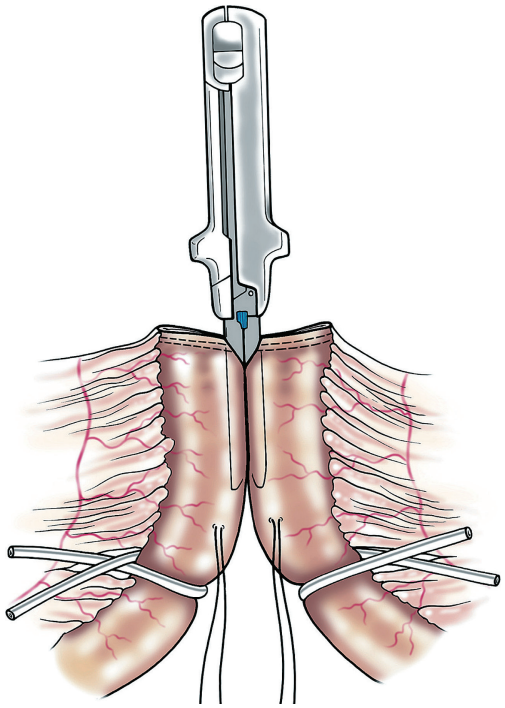

Figure 29.6 Stapling.

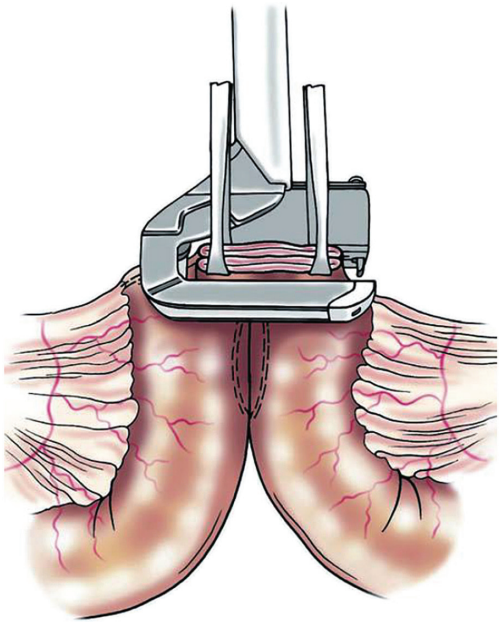

Figure 29.7 Positioning of TA Stapler.

A meta-analysis in 2006 of six trials and 670 patients did not demonstrate superiority of the two-layer versus the single-layer closure (Shikata et al. 2006). The double-layer closure consists of a continuous inverting layer of absorbable suture and an outer layer of interrupted silk seromuscular sutures. Both continuous and interrupted single-layer closures have been described. In the Gambee interrupted inverted seromucosal technique, 3-0 sutures are placed from the mucosa through the bowel wall to the serosa and back through, serosa to mucosa. The knots are tied on the mucosal side, and the interrupted sutures are placed 3 mm apart (Gambee et al. 1956) (Figure 29.9). More recently

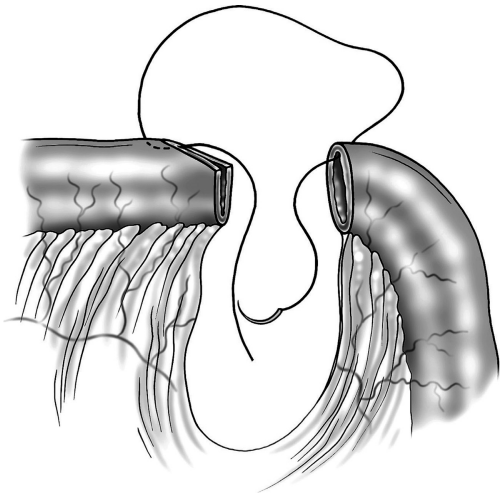

Figure 29.8 Cheatle slit on small bowel.

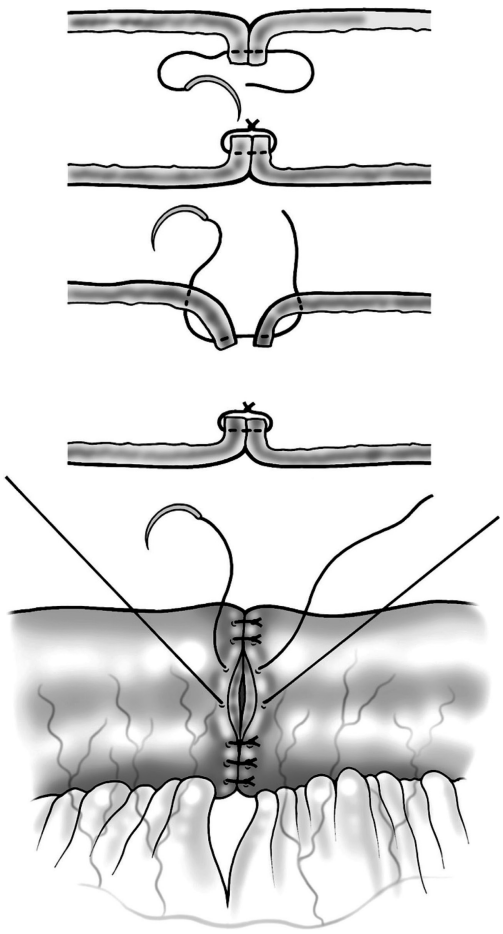

Figure 29.9 The Gambee technique.

described is a continuous over-and-over seromuscular running suture. Theoretical concerns regarding a single-layer running closure include an increased risk of luminal narrowing and a potentially increased risk of anastomotic leak compared to a double-layer technique; however, this has not been borne out in randomized trials (Burch et al. 2000). Patient factors and the underlying disease process are more important in determining results than are surgical technique variations, unless randomized clinical trials indicate otherwise.

An alternative to small bowel resection is small bowel bypass, whereby an abnormal area of bowel is bypassed, and a bowel anastomosis is created proximal to the abnormal area. This will allow intestinal contents to progress beyond an area of obstruction. A side-to-side enteroenterostomy is created, either with staplers or a double- or single-layer suture technique.

Alternatively, the bowel is divided proximally and distally to the damaged segment, and the damaged bowel is completely excluded from the intestinal stream. One end of the bypassed limb is brought up to the skin as a mucous fistula. A third option is to divide the bowel proximal to the damaged area and create an anastomosis distally. The mucous fistula may be incorporated into the inferior aspect of the incision. A disadvantage of bowel bypass is that it may subsequently foster a blind-loop syndrome. The blind-loop syndrome is characterized by bacterial overgrowth with subsequent cramps, diarrhea, anemia, and weight loss (Schlegel and Maglinte 1982). If a small bowel fistula is being bypassed, it is important to completely isolate this bowel from the intestinal stream.

Laparoscopic management of acute small bowel obstruction is increasingly reported. The largest meta-analysis of 1061 cases found a conversion rate to laparotomy of 33.5%, most often associated with adhesive disease and need for bowel resection (Ghosheh and Salameh 2007). There are few if any absolute contraindications to laparoscopy in a modern operating room with contemporarily trained staff.

LARGE INTESTINE SURGERY

Indications

Partial colectomy, rectosigmoid resection, and abdominal perineal resection are all utilized to treat gynecologic malignancies. These procedures may be integral to ovarian cancer debulking, treatment of radiation complications, or a component of pelvic exenteration for cervical, endometrial, vaginal, or vulvar cancer. If the sphincter or distal rectum is damaged or involved with tumor, colostomy may be required to provide fecal continence. Stoma formation is required for either permanent or temporary fecal diversion. End colostomies are typically preferred for permanent stomas, as they are smaller and are less prone to complications (Segreti et al. 1996). Loop colostomies are preferred when stomal closure in the future is anticipated or bowel obstruction occurs as a result of advanced, refractory ovarian cancer, and anticipated life expectancy is short. After a colostomy has served its purpose, allowing a distal anastomosis to heal or a fistula to be repaired, intestinal continuity is restored by closing the colostomy. Lastly, removal of the appendix may facilitate ovarian cancer debulking, urinary conduit construction, or serve as a prophylactic maneuver against future infectious or neoplastic complications.

Anatomic Considerations

The blood supply to the colon and rectum is derived from branches of the superior mesenteric, inferior mesenteric, and internal iliac arteries. The right colon is supplied by the SMA through the ileocolic artery, the right colic artery, and a branch of the middle colic artery. The transverse colon is chiefly supplied by the middle colic artery, but there is a communication with the inferior mesenteric arterial system via the marginal artery of Drummond. The inferior mesenteric artery supplies

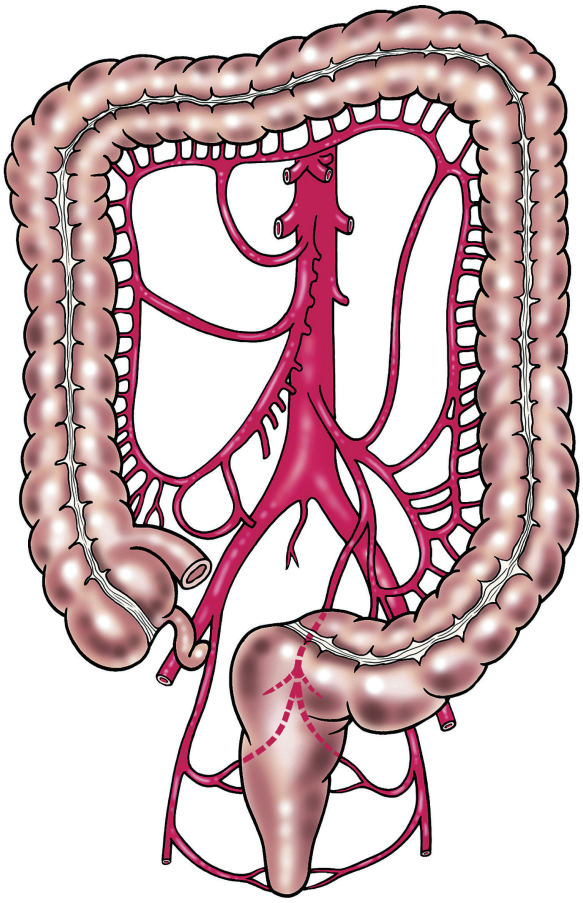

Figure 29.10 Blood supply to the colon and rectum.

the colon from the splenic flexure to the proximal rectum. The inferior mesenteric artery branches into the left colic artery, the superior rectal artery, and the sigmoid arteries. The distal rectum receives its blood supply from the paired middle and inferior rectal arteries which originate from the internal iliac artery system (Figure 29.10).

The appendix is the embryologic continuation of the cecum. Its location is identified by the confluence of the three taenia of the cecum. The position of the tip of the appendix relative to the cecum may vary. The tip may be found lateral, medial, or behind the cecum. The mesentery of the appendix passes behind the terminal ileum. The blood supply to the appendix is derived from the appendiceal artery, which is a branch of the ileocolic artery.

The nerves to the colon parallel the blood supply and consist of sensory afferent nerves, and the motor nerves from the autonomic system. The anal sphincter is under voluntary motor control. The colonic wall is more muscular than that of the small bowel. In addition, the longitudinal muscles are gathered in three places to form the taenia coli. The colon also has numerous fatty epiploica that hang from the taenia.

Surgical Procedures

Mechanical bowel preparation prior to elective colorectal surgery, once thought to be mandatory, is now under scrutiny and may not be necessary in most cases. A recent updated Cochrane database review of 18 randomized controlled studies that included 5805 participants undergoing elective colorectal surgery did not demonstrate any advantage to mechanical bowel preparation versus no prep in regard to the rate of anastomotic leakage or wound infection (Guenaga et al. 2011). Regardless of whether mechanical bowel preparation is used, wound infection rates are significantly decreased with the use of preoperative antibiotics. The addition of oral antibiotic prophylaxis reduced the risk of infection more than IV therapy alone. However, increasing trends to eliminate bowel preparation raise questions regarding the role of oral antibiotics in that setting (Nelson et al. 2014). In general, the preponderance of evidence would indicate that mechanical bowel prep should not be used unless a special circumstance exists.

Factors that may impair anastomotic healing are frequently encountered in gynecologic oncology patients, including hypoalbuminemia in ovarian cancer patients, smoking in cervical cancer patients, prior irradiation in cervical or endometrial cancer patients, and prior chemotherapy, radiation, and diabetes mellitus in many gynecologic oncology patients. Efforts should be made to optimize all reversible adverse factors if possible, that is, preoperative and postoperative nutritional support, avoid smoking, achieve euglycemia, etc. Gynecologists have long recognized the value of perioperative feeding, including minimizing pre-op starvation and immediately resuming postoperative enteral feeding. Other surgical specialties have resisted this despite decades of randomized clinical trial data. Recently, this older data has been repackaged as "enhanced recovery after surgery" (ERAS). With the associated marketing around this, older traditions in other surgical fields are catching up to evidence-based gynecologic oncology practices.

The principles of large bowel resection and anastomosis are similar to those for small bowel anastomosis and are based on the blood supply and the location of the pathologic segment. Resection and anastomosis of the colon and proximal rectum are performed equally well with either a handsewn or stapled technique. The Cochrane Colorectal Group performed an updated review of randomized trials in 2012 which confirmed earlier conclusions of non-superiority of either stapled or handsewn technique used for colorectal anastomosis. However, they did note a trend toward increased risk of anastomotic stricture with staplers and a longer time to perform the anastomosis with a handsewn technique (Neutzling et al. 2012). However, for ileocolic anastomoses, this group found in a review of seven studies an advantage to the stapled technique versus the handsewn technique, with fewer leaks noted in the stapled group (2.5% vs. 6%). Notably, none of the studies independently demonstrated a significantly different leak rate (Choy et al. 2011). Important to both methods is the adequate clearance of fat and vessels away from the colonic ends to be connected. The cardinal rules for a successful anastomosis remain a tension free, well vascularized, and watertight anastomosis.

Hand-sutured colonic anastomoses have classically been two layers in the tradition of Lembert and Halsted. Popular and commonly used by many surgeons for years is the double-layer closure. This method incorporates successive interrupted inverting seromuscular Lembert sutures (far–near–near–far), mucosa-sparing sutures placed in the posterior wall until half of the circumference is approximated (Figure 29.11). The bowel lumens are then exposed by excising excess tissue adjacent to the

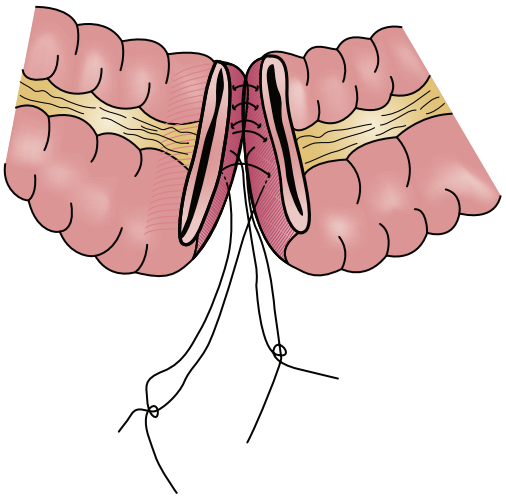

Figure 29.11 End-to-end anastomosis posterior wall sutures.

Kocher clamps or excising the staple line. The mucosal layer is closed with 4-0 or 5-0 running over and over absorbable suture. A Connell stitch is used on the anterior surface to complete the entire circumference of mucosal apposition. A Connell stitch varies from a running stitch in that advancement occurs on the same side of the bowel, for example, the suture goes through the wall from the serosa to the mucosa, then back from the mucosa to the serosa on the same side. The stitch then crosses the incision to the serosa on the other side and then repeats (Figure 29.12). Finally, the anterior surface is closed with an outer layer of Lembert sutures (Figure 29.13). Several investigators have reported using a one-layer inverting colonic closure with satisfactory results (Ceraldi et al. 1993, Curley et al. 1988, Law et al. 1999, Max et al. 1991). One-layer closures are faster and less expensive than the two-layer closure. The single-layer closure is performed with 3-0 or 4-0 polypropylene or polyglyconate suture using a double-armed needle. The suture is started at the mesenteric border of the bowel (Figure 29.14). The sutures

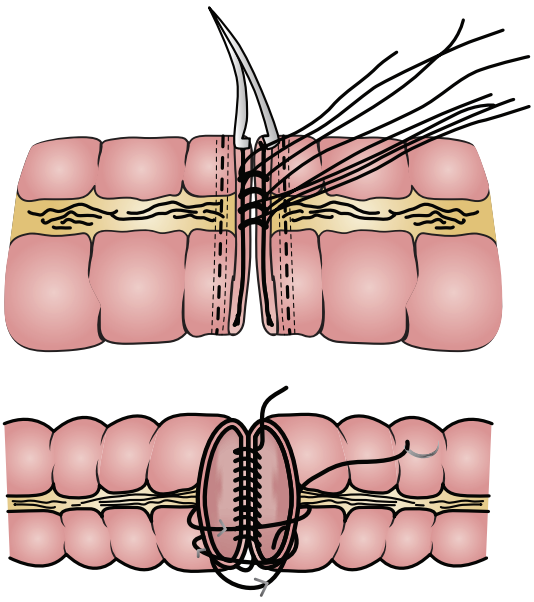

Figure 29.12 Anterior running closure using Connell stitch (lower).

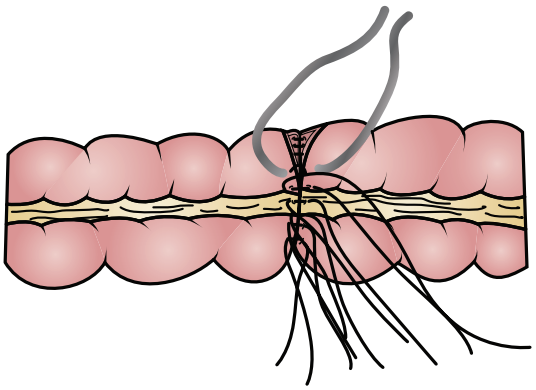

Figure 29.13 Front row sutures.

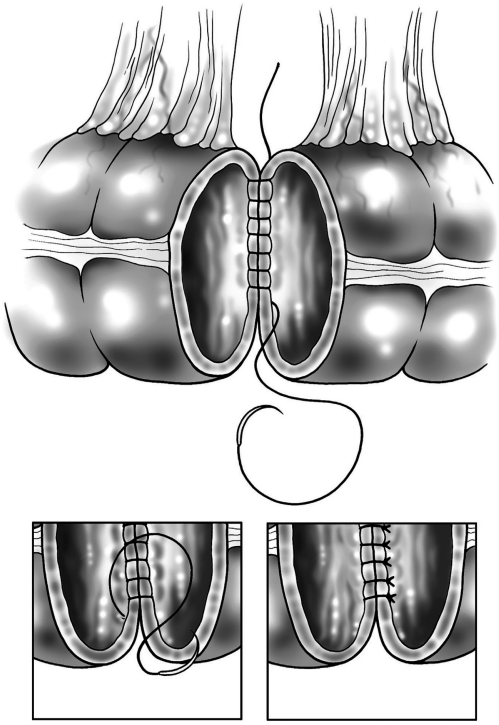

Figure 29.14 Single-layer anastomosis; (inset left) continuous sutures and (inset right) interrupted sutures.

are placed from outside in, including a larger amount of serosa, muscularis, and submucosa (approximately 5 mm) than mucosa (minimal) to affect mucosal inversion. The knot is secured outside the bowel lumen. Each end of the suture is then continued around to the antimesenteric border, spacing the stitches 3 to 4 mm apart. The sutures are then tied together. The TA instrument can also be used to create an end-to-end anastomosis by triangulation (Figures 29.15–29.19). Three stay sutures are placed equidistantly on each limb of the bowel.

One stay suture should be located at the level of the mesentery, and the other two stay sutures should be placed to form an equilateral triangle. The back wall is stapled first, and the mucosa is inverted. The second row of staples is placed to overlap the first row. The last row of staples is placed, and the mucosa is everted. The diameter of the lumen is palpated to ensure adequate size.

For the distal rectum, the automatic end-to-end circular stapling device (EEA) has provided the ability to perform successful

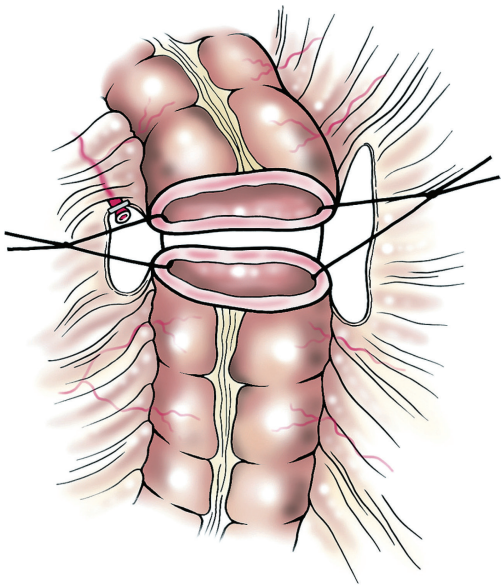

Figure 29.15 Stay sutures.

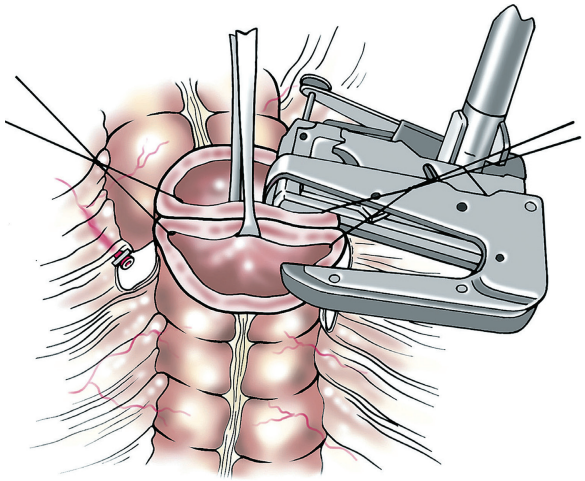

Figure 29.16 The posterior wall is stapled first.

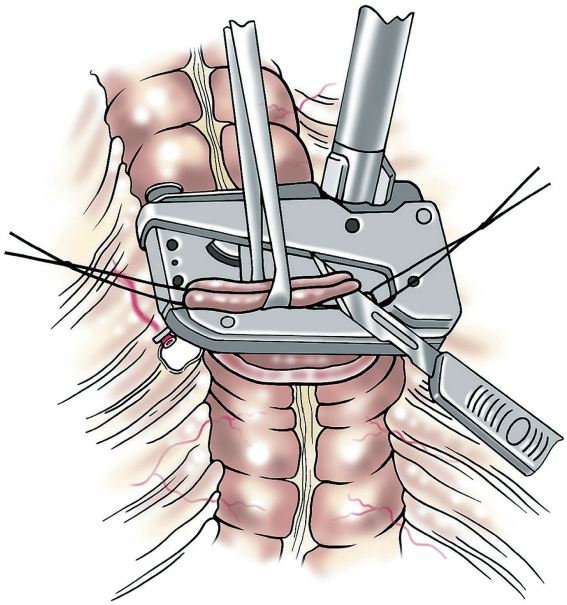

Figure 29.17 Excise the excess tissue.

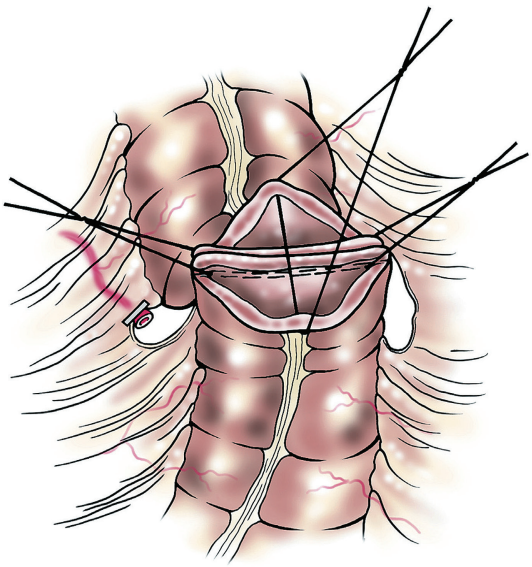

Figure 29.18 Place traction suture midway.

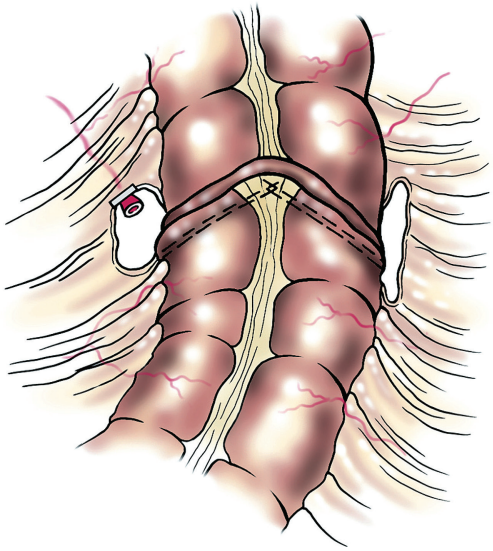

Figure 29.19 Completed anastomosis.

low and very low rectal anastomoses. Adequate mobility of the sigmoid must be achieved by incision along the lateral peritoneal reflection. The two ends of the bowel to be anastomosed must be mobile enough to lie adjacent to each other without tension. The largest EEA device that fits comfortably should be used. Sizers are available to measure the lumen. After resection of the diseased large bowel, a purse-string is placed around the proximal lumen. This is easily performed with the purse-string instrument and a straight needle. Alternatively, a preloaded disposable purse-string instrument is available. The purse-string suture is then secured tightly around the anvil of the EEA instrument (Figure 29.20). The rectal stump can similarly be circumscribed with a purse-string suture. Alternatively, a stapler can be used to close the rectal pouch. A trocar attached to the EEA is then used to puncture the closed rectal pouch at the site of the future anastomosis. The trocar is then removed, and the anvil shaft can be inserted into the EEA instrument. By turning

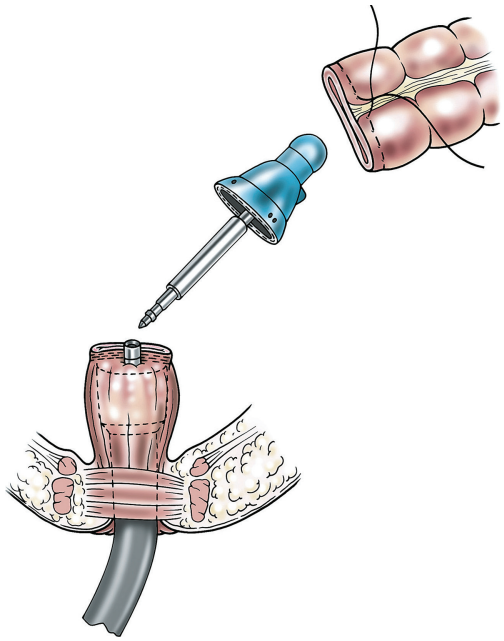

Figure 29.20 Closure of the EAA stapler and donuts.

the wing nut on the EEA handle, the two lumens are approximated. After releasing the safety, the handle is squeezed and two circular rows of staples are placed. A circular knife cuts the excess inverted tissue, and two donuts are created. The wing nut is then turned in the opposite direction to open the instrument, which is then withdrawn gently through the anorectum. The two donuts should be inspected and be intact (Figure 29.21). A defect in one of the donuts is a reason to redo or repair the anastomosis. The seal of the anastomosis can be tested by filling the pelvis with saline and injecting air into the rectum while gently occluding the proximal colon. Bubbles indicate an air leak that should be oversewn. One can also visually inspect the anastomosis with a sigmoidoscope.

When colostomy formation is considered, the patient should meet with an enterostomal therapist for preoperative teaching and evaluation of the abdominal wall for stomal placement. Stomas should ideally pass through the rectus muscles and avoid abdominal wall folds or creases (Figure 29.22). The patient should be examined in both the sitting and standing position. Stoma placement in the waistline should be avoided. The skin is then marked for ideal stomal placement. A laparoscopic or open technique can be used. Prior to dividing the colon, the bowel is mobilized by dividing the lateral peritoneal attachments. Adequate mobility must be achieved to provide a tension-free stoma. The distal bowel is resected or oversewn as a pouch. A 3-cm circular skin button is removed at the previously marked site. The subcutaneous tissues are bluntly separated. The anterior rectus sheath is incised in a cruciate fashion. The rectus muscles are split longitudinally with care taken to avoid the deep epigastric vessels. The peritoneum is then incised, and two or three fingers are passed through the abdominal wall. The stapled bowel end is grasped with a Babcock clamp and brought through the stomal aperture. Care is taken to not twist the mesentery. Excess fat and mesentery are trimmed from the stoma. The stoma is secured to the parietal peritoneum with absorbable suture, and the mesentery can be fixed to the lateral peritoneum to prevent internal hernia. The abdominal incision is then closed. The staple line on the bowel is excised. The stoma is matured in a rosebud fashion by inserting the needle into the

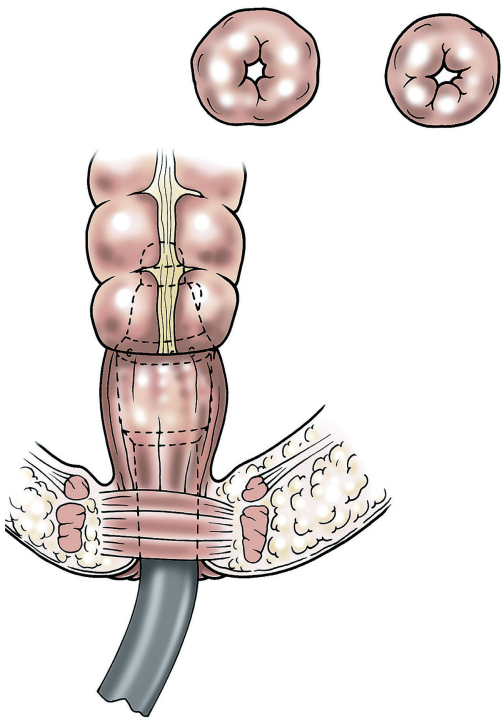

Figure 29.21 Firing EAA and resulting donuts.

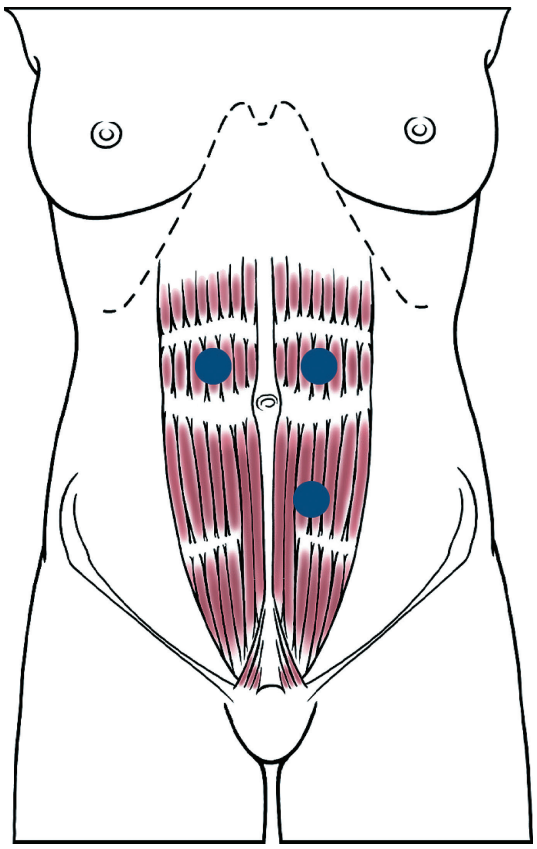

Figure 29.22 Positioning of purse-string suture.

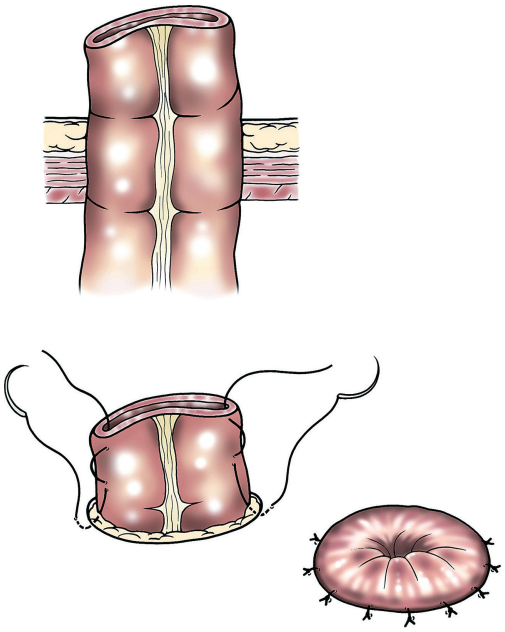

Figure 29.23 Maturation of the stoma in a "rosebud" fashion.

skin 1 cm from the stomal edge, then running it up the bowel serosa and muscularis for one or two stitches, exiting on the mucosal side and securing the knot over the mucocutaneous junction (Figure 29.23).

A loop colostomy may be situated at either the transverse or the sigmoid colon depending on site of obstruction and length of mesentery relative to body habitus. If a loop colostomy is performed for palliation of a sigmoid obstruction secondary to advanced, refractory ovarian cancer, the distal transverse colon is usually easy to identify through a small left upper quadrant incision. However, if the purpose is to create a temporary diverting colostomy while an anastomosis heals, the proximal transverse colon or terminal ileum are usually preferred. To relieve obstruction, a transverse skin incision of 10 to 12 cm is made in the right or left upper quadrant. The fascia is incised transversely, and the rectus muscles are separated longitudinally. The peritoneal cavity is entered sharply. The transverse colon is easily identified due to its dilatation, when a large bowel obstruction is present. The adjacent omentum fat is dissected off of the loop of colon. A defect is created in the mesentery to allow passage of a Penrose drain with which to lift and manipulate the colon. The fascia is then partially closed. A flat plastic bridge may be passed through the mesenteric defect and secured to the skin with a monofilament suture. Instead of a plastic bridge, a skin bridge can be created from skin flaps to elevate the loop colostomy. The skin incision, if larger than needed for the stoma, may be partially closed with skin staples or absorbable sutures. The colon is then opened either longitudinally along the taenia, or at a transversely oriented angle. If a plastic bridge is used, it may be removed in 7 to 10 days.

A loop stoma may be closed by incising the skin adjacent to the mucocutaneous junction, elevating the stoma with Allis clamps, and dividing the filmy attachments to the subcutaneous tissues. The edge of the fascia is then identified, and the plane sharply developed between the stoma and the fascia. The peritoneal adhesions are then lysed. The stomal edge can then be excised, and an extraperitoneal one- or two-layer closure can be performed. The loop is then dropped back into the peritoneal cavity, and the fascia closed with delayed absorbable suture. The skin defect can be packed open and left to close secondarily, or alternatively staples can be used for immediate skin closure (Hoffman et al. 1993).

A faster option to close a loop colostomy is to use the TA stapler. After incising the mucocutaneous junction, the edges of the stoma are grasped with Allis clamps. The colostomy edges are held together to form a line perpendicular to the long axis of the bowel. This will allow maximal lumen diameter. The stapler is fired, and the excess tissue is excised.

To close an end stoma, an exploratory laparotomy is usually required to identify the distal limb and create a large bowel anastomosis. Laparoscopy may alternatively be used and an extraperitoneal closure affected, if the distal limb is nearby and can be mobilized adequately. The end stoma is excised in a similar manner to that described for a loop stoma. The mucocutaneous junction of the distal end is excised. A large bowel anastomosis is performed similarly to that described in the previous section. Mesenteric defects are closed to prevent internal hernias.

Another option to palliate a large bowel obstruction is a colonoscopically placed endoluminal stent to acutely alleviate the obstruction. This may serve as a bridge prior to a definitive resection or as a pure palliative step in a poor operative candidate (Caceres et al. 2008).

Appendectomy is often performed during debulking surgery for ovarian cancer. Appendectomy is accomplished by isolating and ligating the blood supply to the appendix and closing or burying the stump of the appendix to prevent fecal spillage.

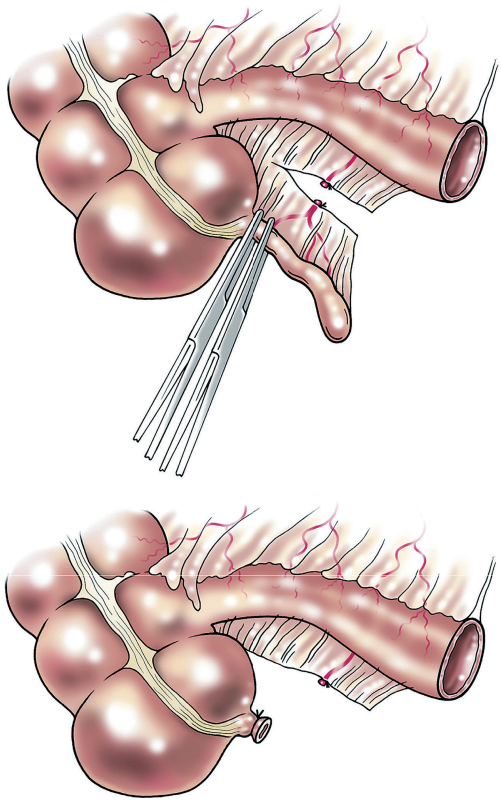

Figure 29.24 Appendectomy.

If present, filmy adhesions from the appendix to the peritoneal surfaces are lysed. If the appendix is retrocecal, the cecum is mobilized by incising the peritoneum along the peritoneal reflection. The appendiceal artery is isolated, doubly clamped, cut, and secured with 2-0 suture. The base of the appendix is then crushed between two straight hemostats. The specimen is excised between the hemostats, and the stump tied off with 2-0 suture (Figure 29.24). Alternatively, the unligated stump can be buried into the cecum with a Z stitch or purse-string suture. Ligation of the stump prior to burial into the cecum may promote a mucocele or an abscess. Another approach after dividing and securing the appendiceal artery is to remove the appendix using the GIA or the TA stapling device.

REFERENCES

Burch JM, Franciose RJ, Moore EE, et al. 2000. Single-layer continuous versus two-layer interrupted intestinal anastomosis: A prospective randomized trial. *Ann Surg* **231**:832–7.

Caceres A, Zhou Q, Iasonos A, et al. 2008. Colorectal stents for palliation of large-bowel obstructions in recurrent gynecologic cancer: An updated series. *Gynecol Oncol* **108:**482−5.

Ceraldi CM, Rypins EB, Monahan M, et al. 1993. Comparison of continuous single layer polypropylene anastomosis with double layer and stapled anastomoses in elective colon resections. *Am Surg* **59**:168–71.

Choy P, Bissett I, Docherty J, et al. 2011. Stapled versus handsewn methods for ileocolic anastomoses. *Cochrane Database Syst Rev* (**9**):CD004320.

Curley SA, Allison DC, Smith DE, et al. 1988. Analysis of techniques and results in 347 consecutive colon anastomoses. *Ann Surg* **155**:597–601.

Gambee LP, Garnjobst W, Hardwick CE. 1956. Ten years' experience with a single layer anastomosis in colon surgery. *Am J Surg* **92**:222–7.

Ghosheh B, Salameh JR. 2007. Laparoscopic approach to acute small bowel obstruction: Review of 1061 cases. *Surg Endosc* **21:**1945−9.

Guenaga KKFG, Matos D, Wille-Jørgensen P. 2011. Mechanical bowel preparation for elective colorectal surgery. *Cochrane Database Syst Rev* (**9**):CD001544.

Hoffman MS, Gleeson N, Diebel D, et al. 1993. Colostomy closure on a gynecologic oncology service. *Gynecol Oncol* **49**:299–302.

Law WL, Bailey HR, Max E, et al. 1999. Single-layer continuous colon and rectal anastomosis using monofilament absorbable suture: Study of 500 cases. *Dis Colon Rectum* **42**:736−40.

Matos D, Atallah ÁN, Castro AA, et al. 2001. Stapled versus handsewn methods for colorectal anastomosis surgery. *Cochrane Database Syst Rev* (**3**):CD003144.

Max E, Sweeney WB, Bailey HR, et al. 1991. Results of 1,000 single-layer continuous polypropylene intestinal anastomoses. *Am J Surg* **162**:461–7.

Nelson RL, Gladman E, Barbateskovic M. 2014. Antimicrobial prophylaxis for colorectal surgery. *Cochrane Database Syst Rev* (**5**):CD001181.

Neutzling CB, Lustosa SA, Proenca IM. 2012. Stapled versus handsewn methods for colorectal anastomosis surgery. *Cochrane Database Syst Rev* (**2**):CD003144.

Schlegel DM, Maglinte DDT. 1982. The blind pouch syndrome. *Surg Gynecol Obstet* **155**:541–4.

Segreti EM, Levenback C, Morris M. 1996. A comparison of end and loop colostomy for fecal diversion in gynecologic patients with colonic fistulas. *Gynecol Oncol* **60**:49–53.

Shikata S, Yamagishi H, Taji Y, et al. 2006. Single versus two layer intestinal anastomosis: A meta-analysis of randomized controlled trials *BMC Surg* **6**:2.

30 Urologic procedures

Padraic O'Malley and Peter N. Schlegel

INTRODUCTION

Given their anatomical proximity to gastrointestinal and reproductive organs, urological structures are innately prone to iatrogenic injury during obstetric and gynecological procedures. Among a large series of iatrogenic ureteral injuries, gynecological surgery was identified as the primary operation associated with injury in 73% of the cases (Dobrowolski et al. 2002). Rates of genitourinary injuries for specific gynecological surgeries vary greatly, especially among contemporary series, due in large part to the impact of the introduction of laparoscopic and robotic approaches (Brummer et al. 2011, Hwang et al. 2012, Lee et al. 2012). Carley et al. (2002) reported rates of 0.35% to 5.13% for genitourinary injury during gynecological procedures. However, three large population studies, either retrospective or prospective in nature, found rates of only 0.3% to 0.8% (Brummer et al. 2011, Lee et al. 2012, Ozdemir et al. 2011) in more contemporary settings. The improvement is most likely due to a number of factors, including modifications in surgical techniques, greater experience and training with minimally invasive techniques, use of adjunctive tools for identification of injury, and a greater emphasis on early recognition and prevention (Adelman et al. 2014, Brummer et al. 2008, Brummer et al. 2011, Gellhaus et al. 2015). In addition, there has been greater emphasis on identifying putative risk factors for injury and possible preventative measures to avoid injury. This chapter focuses on two main subjects, ureteric injuries and use of urinary diversion.

URETERIC INJURY

Risk Factors

Conditions identified as risk factors for injury include endometriosis, retroperitoneal fibrosis, malignancy, prior pelvic radiation, prior pelvic surgery, and anomalous genitourinary anatomy. In the large Finland hysterectomy (FINHYST) series, presence of adhesiolysis, endometriosis, and larger uterine size were associated with a greater risk of genitourinary injury (4). A systematic review by Adelman et al. (2014) identified a history of caesarean delivery, prior abdominal surgery and/or laparotomy, endometriosis, adhesions, broad ligament fibroids, and low-volume surgeons as risk factors. Injuries occur in one of two settings: either (1) it is oncologically necessary or (2) iatrogenic injury occurs due to poor visualization, difficult anatomy, or surgical error, which can be influenced by the risk factors mentioned. The latter may possibly be attenuated or avoided by utilization of preventative measures.

Prevention and Detection

Preventative and early detection measures include perioperative pyelography (intravenous or retrograde), prophylactic stent insertion, and routine cystoscopy at the time of surgery. Prophylactic ureteric catheterization has been suggested to allow better identification of the ureter intraoperatively. However, there is little evidence to support its routine use. In one large series consisting of over 3000 patients, of which 15% underwent prophylactic ureteric catheterization, no significant difference in rates of injury was found, albeit the rate of injury was very low overall (Kuno et al. 1998). A small but randomized control trial also demonstrated no significant difference in injury rates with the use of ureteric catheterization (Chou et al. 2009). Furthermore, in a decision analysis study it was determined that while insertion was not costly, because of the low rates of injury there was no cost savings from prophylactic insertion (Schimpf et al. 2008). A number of sources cite Watterson et al. (1998) as evidence for stent insertion allowing prompt identification of the ureter as a benefit. However, the authors themselves clearly state there is no evidence of benefit from insertion.

Routine cystoscopy at the time of surgery has also been investigated in a number of studies, however there is also a lack of well-designed studies in this area (Patel and Bhatia 2009). Cystoscopy, although not preventative, may allow for early detection of vesical injury; this is of paramount importance, as this early detection leads to lower morbidity, a decreased need for additional surgeries, and less long-term sequelae (Dowling et al. 1986, Gilmour and Baskett 2005, Kuno et al. 1998, Liapis et al. 2001). In a meta-analysis, intraoperative cystoscopy allowed for a superior rate of detection of ureteric and bladder injuries compared to surgeries without cystoscopy (ureteric 89% vs. 7%; bladder 95% vs. 43%) (Gilmour et al. 2006). In a prospective series, the rates of detection were also shown to be greatly improved with utilization of cystoscopy (Vakili et al. 2005). While there is a small cost associated with it and it requires an expanded skill set, the benefit gained from early recognition of potential injuries surely makes routine cystoscopy a wise choice. Furthermore, intraoperative consultation with a urologist or a gynecological oncologist can help improve identification of potential injuries (Aviki et al. 2015). There has also been recent work using fluorescent dyes in animal models, which appears promising for intraoperative identification (Korb et al. 2015). It is clearly in the patient's, primary surgeon's, and consultant's collective best interest to identify the injury at the time of the initial operative procedure. So, although to date we may not have identified significant preventative measures, we can optimize early detection, which greatly decreases the morbidity of injuries. Traditionally, laparoscopic approaches have been associated with a lower rate of immediate recognition of ureteral injuries (Grainger et al. 1990). However, this has not been studied in the more contemporary setting where the impact of the learning curve has now been overcome. The importance of detection is further defined in the following section.

Preoperative Imaging

Among a series of 493 patients undergoing hysterectomy for benign disease, 27% of patients were found to have an abnormal intravenous pyelogram (Piscitelli et al. 1987). However, rates of injury were no lower with preoperative intravenous pyelogram (Piscitelli et al. 1987). A number of studies have demonstrated that a more meticulous approach to intraoperative identification of the ureter is of greater benefit than preoperative imaging (Kuno et al. 1998, Sakellariou et al. 2002). Maintaining an awareness of the pelvic anatomy and a high suspicion of injury will allow for prompt identification.

Table 30.1 Principles of Ureteric Injury Repair

Mobilize ureter with care—preserve the adventitial tissue and vascular supply
Debride ureteric injury liberally—until bleeding/fresh tissue available for reconstruction
Repair ureters in **spatulated**, **tension-free**, **water-tight** fashion
Anastomosis over ureteric **stent**
Drain retroperitoneum/abdominal cavity
Consider **omental interposition** to isolate repair
Use **absorbable, monofilament** suture material

Management of Ureteric Injuries

Management of ureteric injuries is dependent on time of recognition, anatomical location, and extent of injury. Generally, if identified promptly, either intraoperatively or within the early postoperative period, these injuries can be managed with prompt surgical correction. Otherwise, if and when the injury is discovered in the delayed setting, the morbidity and quality of life of the patients is significantly affected. The mechanisms of injury during gynecologic oncology surgery include contusion, transection, ligation, crushing, obstruction, and avulsion. Management can require a range of interventions from intraoperative inspection of urinary structures to possible renal autotransplantation or ligation of the ureter and percutaneous drainage.

Contusions of the ureter can generally be handled with observation and conservative management. An indwelling ureteric stent should be placed whenever compromise of the ureter is suspected. If there is severe or extensive contusion, this is often associated with future stricture formation or possible necrosis. In these cases, a ureteroureterostomy is indicated. Similarly, in the case of ligation, if recognized, a trial period of intraoperative observation after release of the suture or clip may be reasonable. If concerned, then debridement and ureteroureterostomy is again warranted. Again, indwelling ureteric stenting should be placed for 4 to 6 weeks with any ureteral repair. More severe injuries, including transections, can be managed as per the algorithm in Figure 30.1. Upper ureteric injuries are unlikely to occur during gynecological oncology surgery, thus the algorithm focuses on mid- and distal ureteric injuries. General principles to abide by in repair of ureteric injury are listed in Table 30.1.

Anatomy

The most common sites of ureteric injury during hysterectomy are along the pelvic wall lateral to the uterine artery, the uretrovesical junction, and the base of the infundibulopelvic ligament (Liapis et al. 2001, Neuman et al. 1991).

Vascular Supply

The superior and inferior vesical arteries, both branches from the anterior internal iliac artery, provide the majority of the vascular supply to the bladder. The ureter takes its supply from the vessels it is in proximity to, namely the abdominal aorta, the internal and external iliacs, and the vesical arteries. It is helpful to remember during injury and reconstruction that the majority of the vascular supply for the distal ureter comes from the lateral aspect, while more proximately it arises medial to the ureter.

Innervation

Sympathetic and parasympathetic afferent and efferent fibers from the vesical plexus innervate the bladder. The vesical plexus arises from T11-L2. The ureter's innervation, because of its

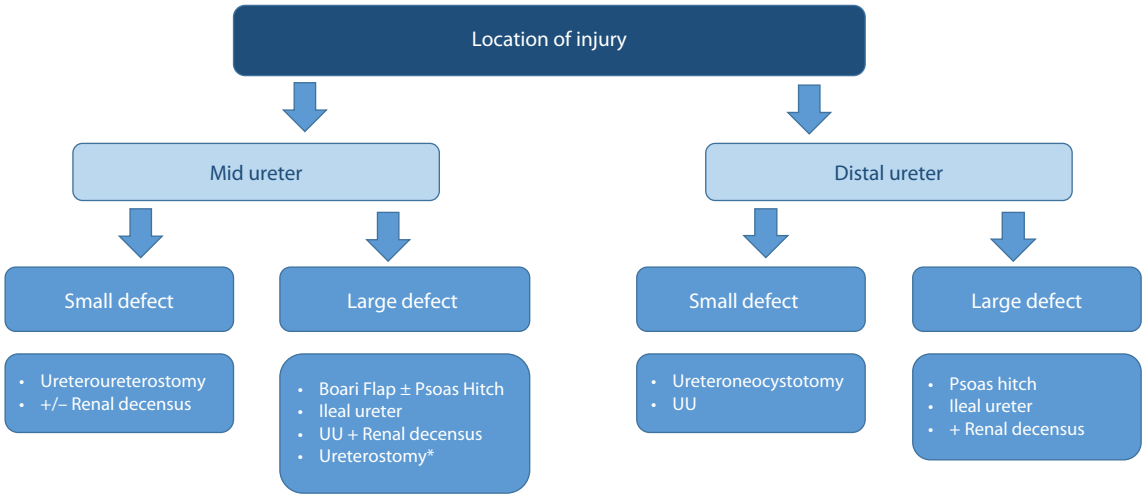

Figure 30.1 Intraoperative decision algorithm for urological repairs. *Ureterostomy – only if solid renal unit or patient critically ill.

length, arises from several plexi, including the renal (T9-12), aortic (L1), and hypogastric plexus (S2-4).

Ureteroureterostomy

Management of ureteric injuries requiring ureteroureterostomy can be approached in two ways. If there has been a laceration with less than 50% transection, primary repair may be indicated. If a laceration is present but there is healthy tissue at the site of injury, closure in a transverse fashion to offset the risk of stricture, and using absorbable, monofilament sutures in an interrupted fashion will allow for the least complex repair. Ureteric stenting is of course recommended once again. If transection is greater than 50%, we recommend dividing completely and spatulating the ends of the ureter in an opposing manner. Most urologists employ interrupted anastomotic sutures for the initial portion of the approximation. However, no evidence exists to suggest inferiority of a running anastomosis. We favor a double apical suture at the initiating apex. The anastomosis is then completed on one side, a stent is placed, and the anastomosis is then completed on the other half (Figure 30.2). This allows for a more efficient and less challenging anastomosis. Given the rapid uptake of robotic surgery in the United States, more and more procedures are performed robotically. These injuries are manageable robotically, and most urologists have robotic experience. This is not universally true, and the approach, whether open or robotically, that the urologist is most comfortable utilizing is most likely to offer the patient the best long-term success and repair. Given the dexterity afforded by the robot, outcomes should be considered equivalent. A number of single-institution studies examining robotic ureteroureterostomy outcomes performed for various etiologies, including iatrogenic causes, demonstrated an excellent reintervention rate of only 0% to 8% (Fifer et al. 2014, Lee et al. 2013, Lee et al. 2015).

Ureteroneocystotomy and Psoas Hitch

Similar to ureteroureterostomy, there are a number of ways to perform the anastomosis. The surgeon has also the choice of refluxing and non-refluxing reimplantation, and extravesical versus intravesical approaches. Non-refluxing approaches are generally considered more often in the pediatric population and refluxing anastomosis are preferred in adults for reconstruction purposes given their relative ease and quickness to perform. The psoas hitch is almost universally concomitantly utilized to achieve length, to ensure a tension-free anastomosis, and to allow for reimplantation to a fixed portion of the bladder where kinking of the ureter does not occur with filling or emptying of the bladder (Stein et al. 2013, Warwick and Worth 1969). Our approach to performing the anastomosis is the same as for ureteroureterostomy anastomosis.

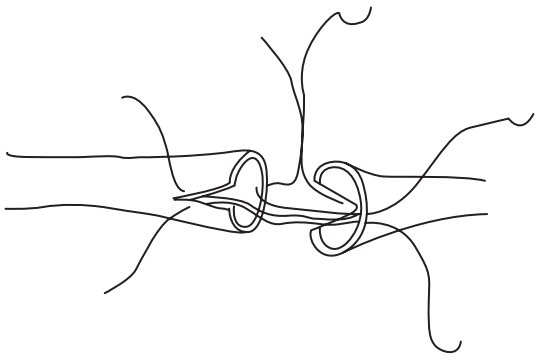

Figure 30.2 Ureteroureterostomy repair with spatulation of the ureter and running anastomosis.

Again, robotic approaches are being utilized to a greater degree in the current age. In the first case series report of robotic versus open ureteric reimplantation, Kozinn et al. (2012) identified a lower estimated blood loss and shorter hospitalization stay (5.1 [open] vs. 2.4 days [robotic]) with the robotic-assisted approach. There are inherent features which make the robotic-assisted approach attractive (McClung and Gorbonos 2014). Using the robotic system allows for 3D magnification and visualization while working deep within the pelvis. Second, the pneumoperitoneum allows for lower blood loss and thus improved visualization once again. Finally, fine and precise handling of the tissue and anastomotic suturing can be readily performed with robotic instruments. Despite the obvious potential benefits, there have only been a few retrospective, single-institution studies, with relatively small numbers, comparing the effectiveness of robotic to open ureteric reimplantation (Baldie et al. 2012, Kozinn et al. 2012, Musch et al. 2013). Further evidence and study is needed to determine if one approach offers superiority over the other, and currently both seem reasonable management strategies.

Boari Flap

The Boari flap was first described in 1899 as a bladder flap substitution for the distal ureter (Boari 1899). The Boari flap provides an excellent substitute for the psoas hitch technique when ureteric defects of longer than 6 to 8 cm exist (Stein et al. 2013). It is important to mobilize the bladder with division and ligation of the median umbilical ligament (urachus) and both medial umbilical ligaments. If greater mobilization is required, the contralateral superior vesicle pedicle can be divided and ligated. Caution must be used in patients who have had previous radiation, and thought given to the functional capacity of their bladder. A rhomboid flap is raised from the dome of the bladder, keeping the base of the flap at least 1 to 2 cm wider than the tip of the flap, and the length-to-width ratio not more than 3:1 in order to ensure good vascular supply (Figure 30.3). The ipsilateral vesical pedicle supplies the flap. The spatulated ureter may be implanted using a tunneled intravesical anastomosis or an extravesical mucosa-to-mucosa anastomosis and closure of the remaining flap vertically. The Boari flap can provide between 10 and 15 cm in length and can even reach the proximal ureter in certain cases on the right-hand side.

Once again, a robotic approach can be utilized, and several small studies have demonstrated excellent perioperative and intermediate functional outcomes with this approach. All three studies had numbers less than ten but all demonstrated minimal blood loss, reasonable operative times, and no intraoperative complications (Do et al. 2014, Fifer et al. 2014, Musch et al. 2013).

Ileal Ureter

Utilization of a segment of ileum as a ureteral substitute is indicated in situations where there is a defect that is not amenable

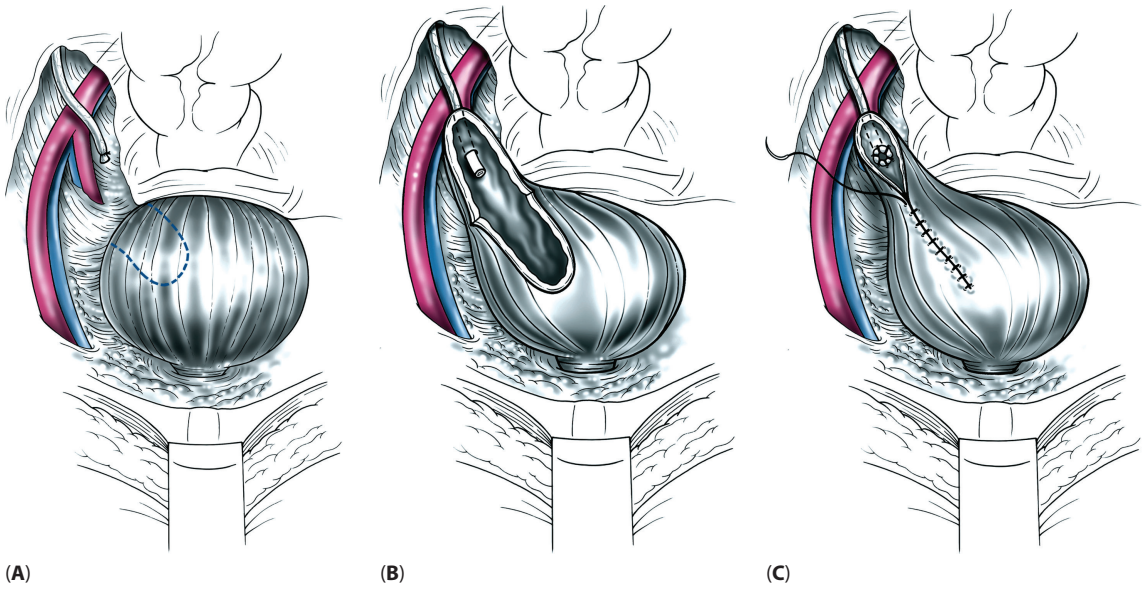

Figure 30.3 (**A–C**) Boari flap reconstruction and ureteric reimplant.

to other forms of repair and reconstruction (Benson et al. 1990, Goodwin et al. 1959). Contraindications to creation of an ileal ureter include renal insufficiency (creatinine >2 mg/dL), voiding or storage dysfunction, inflammatory bowel disease, or radiation enteritis. A series by Koch and MacDougall (1985) demonstrated nearly half of the patients with renal insufficiency developed hyperchloremic metabolic acidosis which required surgical management. Generally, only the worst ureteric injuries will require this form of management, and most gynecologists are not likely to see this severe form of injury given most injuries they encounter are mid to distal in nature. Of note, modifications such as tapering of the isoperistaltic ileal segment, non-refluxing anastomosis, and use of segmental substitution have not been demonstrated to offer any significant advantage (Waters et al. 1981). In patients with normal preoperative renal function who undergo ileal substitution and development of renal or metabolic abnormalities, evaluation of bladder dysfunction is warranted.

URINARY DIVERSION

The need for urinary diversion using a bowel segment in gynecological oncology is most often encountered in the setting of pelvic exenteration and also, but less frequently, when there has been severe radiation injury to the bladder, yielding it essentially nonfunctional. Important considerations to consider prior to surgery include age, along with neurological function and dexterity, renal function and metabolic abnormalities, prognosis, anatomy, and significantly, patient preference and quality of life. Older patients with neurological impairments or renal/metabolic abnormalities generally derive the best quality of care from use of an ileal conduit diversion. Younger, active, and healthier patients are often better served by continent cutaneous or orthotopic diversion. Quality of life associated with a conduit is higher in the first population versus continent diversion, while the reverse is true in the second population of patients. The following is a breakdown of considerations prior to diversion.

Renal Function, Metabolic Abnormalities, and Altered Sensorium

Renal function is important, as there is an increased acid load as a result of the chosen bowel segment's absorption of urinary components. Larger surface areas such as those used in continent diversion will clearly have a higher rate of absorption. With normal renal function, patients are usually able to compensate for the increased acid load. Although no hard and fast cutoff exists for renal function, a glomerular filtration rate of 50 mL/min is generally used (Studer et al. 1998).

Beyond the possible metabolic acidosis, urinary diversion can be associated with a number of other metabolically related disorders including vitamin B12 deficiency and osteomalacia. The most common segment utilized for diversion is the terminal ileum. Absorption of vitamin B12 occurs primarily at this point. The rates of vitamin B12 are unknown among patients with urinary diversion, although some have reported they can be as high as 30% (Pfitzenmaier et al. 2003). Usually development of the deficiency requires 3 to 5 years after surgery for the body's stores to have become depleted. However, serious neurological sequelae can occur as a result. Further neurological sequelae also occur as a result of magnesium deficiency, drug intoxication, and abnormalities of ammonium/bicarbonate metabolism in patients with urinary diversion. A clinician needs to keep these in mind in the long-term follow-up of their patients and be vigilant for signs of any of these metabolic derangements.

Patient Preference, Quality of Life, and Age

There is a lack of evidence to support one version of diversion over another when it comes to quality of life metrics. This is a result of the use of non-standardized, non-validated questionnaires in the past. A review by Porter and Penson (2005) demonstrated the lack of randomized trials to evaluate this. Despite the recognition of this lack of evidence in 2005 by Porter and Penson, to date there is still a lack of data to support one ideal diversion for different groups of patients (Hautmann et al. 2013). The issue is further complicated by the fact that the

evidence that does exist is derived from the urological literature of patients treated for bladder cancer, in whom a large proportion (70%–75%) of patients are male.

As noted above, the majority of reports on continence after orthotopic bladder diversion are from male patients. Data from the Mayo clinic reporting specifically on female patients demonstrated that among approximately 60 women, there was a daytime continence rate of 90%, defined as no pads per day (Granberg et al. 2008). The University of Southern California group reported incontinence rates that are lower, at 77% (Stein et al. 2009). However, both of these are at least as good if not better than those seen in male counterparts. Although daytime continence may be better in women, it does seem that nocturnal incontinence is worse. Rates of nocturnal incontinence ran between 57% to 66% among female patients (Granberg et al. 2008, Stein et al. 2009). Furthermore, although not studied specifically in women, older age is associated with worse rates of both daytime and nighttime incontinence (Froehner et al. 2009, Madersbacher et al. 2002, Sogni et al. 2008, Takenaka et al. 2009).

Generally, the three most common forms of diversion, in order, are ileal conduit, ileal neobladder, and Indiana pouch. We will now discuss the general operative principles and steps for these three diversion types. Of note, there are certain situations where other diversions not discussed here may be more appropriate, such as the use of Mainz II diversions, for example in developing or third-world countries.

Ileal Conduit

The ileal conduit is the most common urinary diversion used in developed countries. The basic steps include isolation of isoperistaltic segment of ileum, ureterointestinal anastomosis, and fashioning of ileal-cutaneous stoma.

The segment of ileum to be isolated should be at least 10 cm from the ileocecal valve in order to obviate lack of mobility and more importantly to obviate pressure upon the gastrointestinal anastomosis that restores GI continuity. A segment isolated using an intestinal stapler can be 5 to 15 cm in length; generally 8 to 12 cm allows for sufficient length without redundancy and overly long transit time. Once the segment is isolated GI continuity is restored first with a side-to-side ileal anastomosis using intestinal staplers. A single silk 2-0 suture at the internal aspect of the anastomosis helps reduce tension on the staple line. The stapled corners may be oversewn to decrease tension and prevent micro-leaks. Furthermore, a portion of omentum can be sewn over the entire anastomosis to protect and isolate it. The majority of surgeons tend to reapproximate the mesentery to prevent the possibility of a mesenteric hernia. Although the evidence for this is scant, the downside is essentially nil. It is important to ensure that the conduit portion is brought inferior to the GI anastomosis before it is performed. Much like the relationship of the uterine artery to the ureter, the saying "water under the bridge" is a simple way to remember this tenet.

Once GI continuity is restored, the segment of ileum is opened distally by resection of the staple line and the segment is flushed copiously with irrigation. The proximal staple line is commonly oversewn using an absorbable monofilament so as to isolate the staple line away from exposure to the urine to prevent stone formation. Ureterointestinal anastomosis is then performed. We favor proceeding with the left ureter first, as the left is often shorter in length. Tunneling of the left ureter over the sacral promontory form the left to right side can be facilitated by division of the posterior peritoneum on both sides of the sigmoid colon. Care should be taken when tunneling to avoid excessive bleeding and kinking or twisting of the ureter. A small aperture is then made in the distal aspect of the ileum approximately 1 to 2 cm from the distal end. The ureter is then spatulated. Several techniques exist for ureterointestinal anastomosis. We favor a simple Bricker anastomosis whereby the ureters are anastomosed individually in a refluxing fashion. Other commonly used techniques include the Wallace (refluxing) and Le Duc (non-refluxing) techniques. In our opinion, the Bricker is advantageous, as the ureters are separately anastomosed and the technique is straightforward and expedient. We perform our ureterointestinal anastomosis similarly to our ureteroureterostomy and ureteroneocystotomy anastomosis with a running anastomosis on either side of the ureter. Use of interrupted sutures for anastomosis is also a popular approach. Again, once half the anastomosis is complete, a ureteric stent is placed proximally with aid of a guidewire to advance it to the renal pelvis. The distal portion is then easily delivered through the anastomosis to exit the distal portion of the ileal segment using a right-angle forceps. Once both anastomoses are complete, we turn our attention to fashioning the exterior stoma.

Preoperative marking of a patient helps facilitate correct sighting of the stoma and ensures ease of use and proper ergonomics. The correct size of the portion of skin to be resected can be imprinted on the skin using the butt end of a standard 10 cc syringe. The skin and a portion of underlying fat are then removed. The anterior sheet is then incised in a cruciate fashion. Placement of the conduit through the rectus muscle helps to decrease the rate of prolapse and parastomal herniation. The muscle should simply be split vertically to avoid division of the fibers. The posterior sheet is then incised vertically as well. The appropriate amount of space for passage of the conduit can easily be approximated by passage of the surgeon's left and right index fingers through, one from internally and one from externally. This allows for sufficient room for most patients' caliber of ileum and maintains a low rate of herniation. We favor not using fascial anchoring stitches to the anterior sheet, as this limits the amount of eversion achievable and often results more in retraction of the exterior portion of the stoma than improving it. We do use a fascial anchoring suture once the stoma has been everted and fixed. This is performed by fixing it to the posterior sheet instead from the internal abdominal wall. Once the passage for the conduit is formed, the end of the ileal segment and ureteric stents are delivered using Babcock forceps.

Maturation of the stoma is performed by placing Brooke stitches at each corner (essentially the 3, 6, 9, and 12 o'clock positions) (Brooke 1952). A small portion of mesentery, not more than 1 cm, can be trimmed from the most distal portion of the ileum without risking devascularization of the segment; this often improves eversion. Brooke stitches are placed as far as is possible through the serosal and longitudinal and circular muscle layers, then through the full thickness at the distal aspect of the segment, and finally subcutaneously. All four stitches are placed prior to tying them in place. When tying, it is optimal to tie the two opposing sutures first. Once all four Brooke sutures have been tied in place, the ileal-cutaneous anastomosis

is completed with simple interrupted sutures circumferentially. The ureteric stents should then be sutured to the stoma externally to keep in place, often using a 3-0 chromic suture. We advocate the use of a multi-eye stomal catheter for the initial 48 hours after stomal creation until swelling and engorgement of the ileal segment has subsided. This ensures prompt transit and accurate monitoring of urine output from the conduit.

Most surgeons have developed their own specific techniques, usually a product of their training or regionalization, and no doubt many slightly varying techniques are used successfully. We encourage the use of the technique one is most comfortable and proficient with. It is prudent to leave an abdominal drain to monitor for a leak. A drain creatinine level can be checked, though not required, after 48 to 72 hours if concern for a urine leak exists. Use of a nasogastric tube is not recommended postoperatively. Use of a preoperative mechanical or antibiotic prep is surgeon dependent but the literature does not support its routine use (Large et al. 2012). The multi-eyed catheter can be removed between 48 to 72 hours postoperatively. The drain may be removed as early as 48 hours, although we routinely perform this 24 hours after the multi-eye catheter removal. Ureteric stents can then be removed 1 to 2 weeks later in the outpatient setting.

Orthotopic Neobladder

Neobladders are required to be low-pressure reservoirs with adequate capacity to allow socially acceptable voiding patterns, and must be able to be emptied to completion. This allows for a socially functional diversion with preservation of the upper tracts and kidney function and minimized metabolic disturbances (Hautmann et al. 2013). The ileum is the recommended portion of bowel used because of its lower contractility and greater compliance versus colonic or other small bowel segments, as well as its milder metabolic effects (Hautmann et al. 2013, Schrier et al. 2005, Steers 2000).

Generally, the segment of ileum should be taken at least 10 to 15 cm proximal to the ileocecal valve. A segment of 55 to 60 cm is then measured out and isolated. GI continuity is restored as in ileal conduits. To accomplish a low-pressure system with optimal capacity, the ileal segment, minus the proximal 12 to 15 cm, is detubularized. By doing so, a spherical reservoir can be constructed that will have a volume four times that of the ileal segment with one-fourth the pressure.

The most popular and acceptable techniques for formation of an ileal neobladder are the Studer (1996) and Hautmann (1997) neobladders. Both of these versions include an afferent limb of approximately 10 cm to which the ureters are anastomosed. We perform this using the Bricker type refluxing anastomosis as in conduits. Recently we have begun to keep the left ureter within the abdomen and have not brought it behind the sigmoid colon. This facilitates the anastomosis to the isoperistaltic segment. After reconstructing a spherical reservoir but before completely sealing it, the ureteric stents are delivered through the neobladder wall and fixed with a purse-string 4-0 chromic. A Malecot catheter is also placed, delivered through the reservoir wall, and sutured in place with a 2-0 chromic purse-string suture (see Figure 30.4). The reservoir is then placed in the pelvis to determine the most dependent portion, and an enterotomy is made at this point and the mucosa everted for the neobladder anastomosis to the urethra. The reservoir is then closed and the anastomosis performed with a Foley catheter placed in addition to the Malecot. Some surgeons have had good results without use of a Malecot catheter. The formation of the neobladder may be performed intracorporeally using a robotic technique, extracorporeally in traditional open surgery, or extracorporeally through a small midline incision with robotic-assisted urethral anastomosis. All three variations are acceptable, and no sufficient evidence exists to recommend one over another. Often whether they are performed open or robotically is dependent on the other procedures the patient may be undergoing.

Stents can then be removed as early as 48 hours. We recommend irrigation of the neobladder to begin after 48 hours and performed every 8 hours during the inpatient stay. The Foley is then removed 10 to 14 days after the operation. At this time, we clamp the Malecot and have the patient begin to cycle the neobladder through filling with emptying of the neobladder through the Malecot every 8 hours to obviate the risk of rupture. The Malecot is then removed 1 week later.

Indiana Pouch

The Indiana pouch continues to be the most widely adopted form of continent cutaneous diversion, followed by the Lundiana

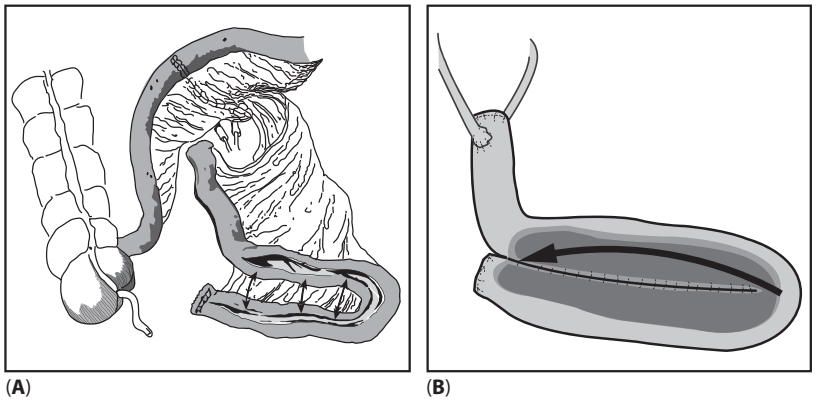

Figure 30.4 Studer neobladder reconstruction. (**A**) Preparation of the reservoir involves detubularization of the bowel segment. This is done by making a linear incision on the anti-mesenteric border of the intestinal wall. The small bowel harvest segment has undergone reanastomsis. (**B**) The ureters have been implanted into the proximal segment of the donor small bowel. The reservoir is created by folding the incised small bowel segment on itself after detubularization and suture closure. The process creates a low pressure system reducing ureteral regurgitation.

pouch. Although technically speaking, most gynecological patients who undergo pelvic exenteration for say a gynecological malignancy do not require removal of the urethra and thus are candidates for a neobladder, patients and surgeons may opt for a continent cutaneous diversion because the risk of leakage may be lower (Hautmann et al. 2013). Many believe that because, unlike an orthotopic neobladder there is no pop-off mechanism, non-refluxing anastomosis are a requisite (Hautmann et al. 2013). Our feeling is that with timely and routine catheterization this is not necessary. Although a number of outlet configurations exist, including the appendix, we generally utilize the terminal ileum and take advantage of the existing ileocecal valve.

The Indiana pouch is made up of the terminal 10 cm of ileum and the ascending colon. Whether the pouch is constructed intracorporeally or extracorporeally during robotic cases, it is less laborious to mobilize the ascending colon beyond the hepatic flexure while using the robot or laparoscopic. Once the colon and terminal ileum have been divided to isolate the ascending colon and terminal ileum, a side-to-side anastomosis is performed between the ileum and transverse colon. The colonic segment is then detubularized by incision along the taenia. It is then folded and reconstituted in a more spherical fashion (Figure 30.5A). No further attempts are needed to create a spherical reservoir, as the colon has a larger diameter than the ileum. However, of note, rupture is a higher risk among colonic pouches than among ileal reservoirs (Mansson et al. 1997). The ureter is then re-anastomosed using an intra-reservoir technique. The appendix must be removed, although some surgeons have removed it and used it as the efferent limb owing to its inherently smaller lumen than the terminal ileum. Generally speaking, continence of the pouches arises from two features, the presence of the ileocecal valve and tapering of this junction and the efferent ileal limb.

The ileum is commonly tapered by using an intestinal stapler to exclude a portion of the ileum's caliber. This is typically done with a 14- to 16F red rubber catheter in place (Figure 30.5B). The catheter is then removed and silk sutures are used to imbricate the terminal ileum closest to the ileocecal valve (Figure 30.5C). We routinely place these tapering sutures until when we attempt to catheterize the ileocecal valve we feel a "pop" as we pass the catheter through the valve. Although quite subjective, we find this allows for finely tuned tapering to each individual. As with neobladders, the ureteric stents and Malecot catheter are fixed using chromic sutures in a purse-string fashion. The drainage tubes are delivered only after siting the continent stomal site but prior to fixing the ileal-cutaneous anastomosis. Although use of the umbilicus has a cosmetic appeal we routinely use a spot consistent with where one might place an ileal conduit stoma. We feel this offers better continence, has a lower rate of stomal stenosis and retraction, and the cosmetics are easily rectified by placing a simple bandaid over the site when one has those concerns. An indwelling red rubber catheter is fixed exteriorly at the time of surgery. Management of stents and catheters is then analogous to a neobladder. The stoma is created by ileal cutaneous anastomosis in a low-profile fashion in four quadrants initially and then interrupted sutures between to secure the anastomosis further.

Summary

The three diversions listed here are not the only possibilities, but we feel the most broadly applicable, technically feasible, and have the greatest success in both the short and long term to optimize patient's quality and quantity of life. Although the use of urinary diversion may not be common in gynecological oncology or gynecology cases, familiarity with them is a bare minimum for surgeons to have in order to manage their

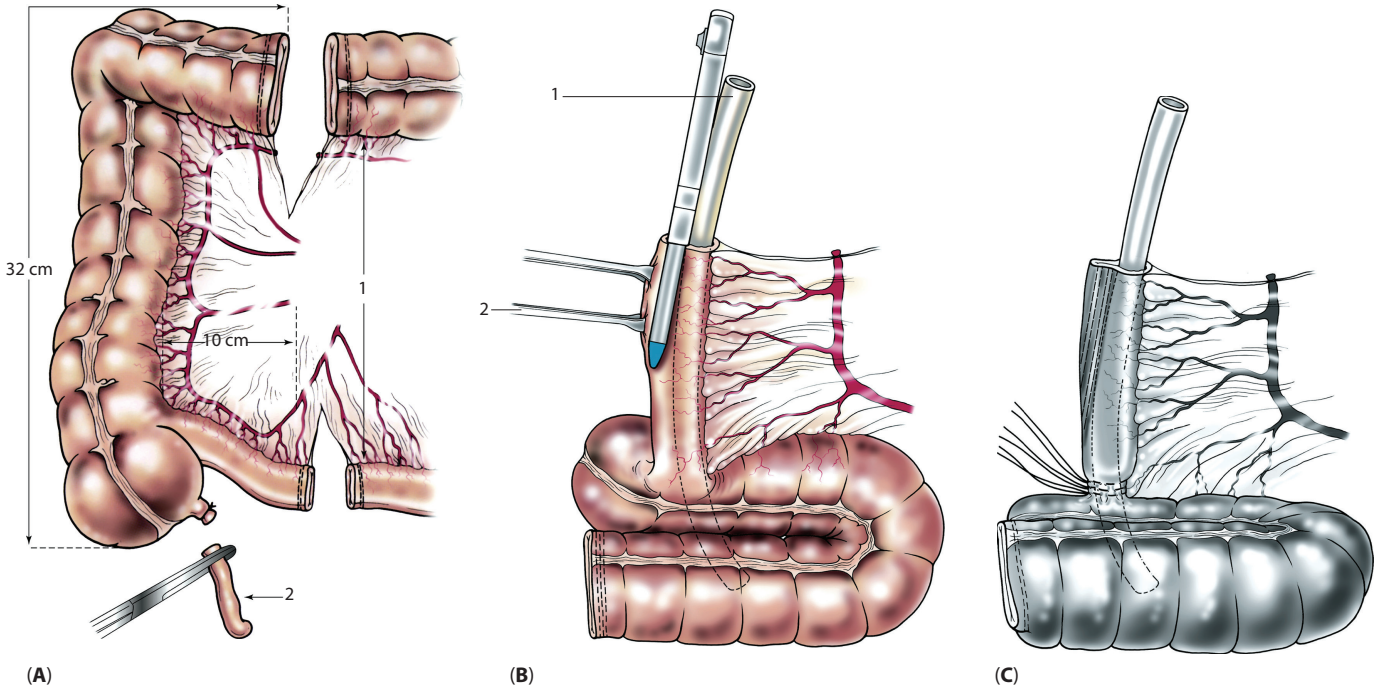

Figure 30.5 Orthotopic Indiana Pouch construction. (**A**) 1: Detubularization; 2: formation of spherical reservoir, (**B**) initial tapering of ileal limb over red rubber catheter, 1: Rubber catheter; 2: allis clamp, and (**C**) fine-tune tapering of ileocecal valve with silk sutures.

patients effectively. Some gynecological surgeons are facile and experienced enough to perform their own diversions. However, as a cautionary note, if those patients have complications, they then require management by a urologist who would no doubt have preferred to perform the diversion themselves so as to truly be familiar with the intraoperative findings and nuances of particular cases.

ACKNOWLEDGMENTS

POM is supported by The Frederick J. and Theresa Dow Wallace Fund of the New York Community Trust and by the Ferdinand C. Valentine Fellowship Award from the New York Academy of Medicine. POM would like to acknowledge Dr. Douglas S. Scherr, Clinical Director of Urologic Oncology and the Society of Urological Oncology Fellowship program director at Weill Cornell Medical College, and Dr. Peter N. Schlegel for their ongoing clinical, surgical, and career mentorship.

REFERENCES

Adelman MR, Bardsley TR, Sharp HT. 2014. Urinary tract injuries in laparoscopic hysterectomy: A systematic review. *J Minim Invasive Gynecol* **21**(4):558–66.

Aviki EM, Rauh-Hain JA, Clark RM, et al. 2015. Gynecologic Oncologist as surgical consultant: Intraoperative consultations during general gynecologic surgery as an important focus of gynecologic oncology training. *Gynecologic Oncology.* **137**(1):93–7.

Baldie K, Angell J, Ogan K, et al. 2012. Robotic management of benign mid and distal ureteral strictures and comparison with laparoscopic approaches at a single institution. *Urology* **80**(3):596–601.

Benson MC, Ring KS, Olsson CA. 1990. Ureteral reconstruction and bypass: Experience with ileal interposition, the Boari flap-psoas hitch and renal autotransplantation. *J Urol* **143**(1):20–3.

Boari A. 1899. L'utero-cystonostomie. Etude clinique et experimentale. *Ann Mal Org Gen Urin* **14**(1059–88):141–70.

Brooke BN. 1952. The management of an ileostomy, including its complications. *Lancet* **2**(6725):102–4.

Brummer TH, Seppala TT, Harkki PS. 2008. National learning curve for laparoscopic hysterectomy and trends in hysterectomy in Finland 2000-2005. *Hum Reprod* **23**(4):840–5.

Brummer TH, Jalkanen J, Fraser J, et al. 2011. FINHYST, a prospective study of 5279 hysterectomies: Complications and their risk factors. *Hum Reprod* **26**(7):1741–51.

Carley ME, McIntire D, Carley JM, et al. 2002. Incidence, risk factors and morbidity of unintended bladder or ureter injury during hysterectomy. *Int Urogynecol J Pelvic Floor Dysfunct* **13**(1):18–21.

Chou MT, Wang CJ, Lien RC. 2009. Prophylactic ureteral catheterization in gynecologic surgery: A 12-year randomized trial in a community hospital. *Int Urogynecol J Pelvic Floor Dysfunct* **20**(6):689–93.

Do M, Kallidonis P, Qazi H, et al. 2014. Robot-assisted technique for boari flap ureteral reimplantation: Is robot assistance beneficial? *J Endourol* **28**(6):679–85.

Dobrowolski Z, Kusionowicz J, Drewniak T, et al. 2002. Renal and ureteric trauma: Diagnosis and management in Poland. *BJU Int* **89**(7):748–51.

Dowling RA, Corriere JN, Jr, Sandler CM. 1986. Iatrogenic ureteral injury. *J Urol* **135**(5):912–5.

Fifer GL, Raynor MC, Selph P, et al. 2014. Robotic ureteral reconstruction distal to the ureteropelvic junction: A large single institution clinical series with short-term follow up. *J Endourol* **28**(12):1424–8.

Froehner M, Brausi MA, Herr HW, et al. 2009. Complications following radical cystectomy for bladder cancer in the elderly. *Eur Urol* **56**(3):443–54.

Gellhaus PT, Bhandari A, Monn MF, et al. 2015. Robotic management of genitourinary injuries from obstetric and gynaecological operations: A multi-institutional report of outcomes. *BJU Int* **115**(3):430–6.

Gilmour DT, Baskett TF. 2005. Disability and litigation from urinary tract injuries at benign gynecologic surgery in Canada. *Obstet Gynecol* **105**(1):109–14.

Gilmour DT, Das S, Flowerdew G. 2006. Rates of urinary tract injury from gynecologic surgery and the role of intraoperative cystoscopy. *Obstet Gynecol* **107**(6):1366–72.

Goodwin WE, Winter CC, Turner RD. 1959. Replacement of the ureter by small intestine: Clinical application and results of the ileal ureter. *J Urol* **81**(3):406–18.

Grainger DA, Soderstrom RM, Schiff SF, et al. 1990. Ureteral injuries at laparoscopy: Insights into diagnosis, management, and prevention. *Obstet Gynecol* **75**(5):839–43.

Granberg CF, Boorjian SA, Crispen PL, et al. 2008. Functional and oncological outcomes after orthotopic neobladder reconstruction in women. *BJU Int* **102**(11):1551–5.

Hautmann RE. 1997. The ileal neobladder to the female urethra. *Urol Clin North Am* **24**(4):827–35.

Hautmann RE, Abol-Enein H, Davidsson T, et al. 2013. ICUD-EAU International Consultation on Bladder Cancer 2012: Urinary diversion. *Eur Urol* **63**(1):67–80.

Hwang JH, Lim MC, Joung JY, et al. 2012. Urologic complications of laparoscopic radical hysterectomy and lymphadenectomy. *Int Urogynecol J* **23**(11):1605–11.

Koch MO, McDougal WS. 1985. The pathophysiology of hyperchloremic metabolic acidosis after urinary diversion through intestinal segments. *Surgery* **98**(3):561–70.

Korb ML, Huh WK, Boone JD, et al. 2015. Laparoscopic Fluorescent Visualization of the Ureter with Intravenous IRDye800CW. *J Minim Invasive Gynecol* **22**(5)799−806.

Kozinn SI, Canes D, Sorcini A, et al. 2012. Robotic versus open distal ureteral reconstruction and reimplantation for benign stricture disease. *J Endourol* **26**(2):147–51.

Kuno K, Menzin A, Kauder HH, et al. 1998. Prophylactic ureteral catheterization in gynecologic surgery. *Urology* **52**(6):1004–8.

Large MC, Kiriluk KJ, DeCastro GJ, et al. 2012. The impact of mechanical bowel preparation on postoperative complications for patients undergoing cystectomy and urinary diversion. *J Urol* **188**(5):1801–5.

Lee JS, Choe JH, Lee HS, et al. 2012. Urologic complications following obstetric and gynecologic surgery. *Korean J Urol* **53**(11):795–9.

Lee Z, Llukani E, Reilly CE, et al. 2013. Single surgeon experience with robot-assisted ureteroureterostomy for pathologies at the proximal, middle, and distal ureter in adults. *J Endourol* **27**(8):994–9.

Lee Z, Moore B, Giusto L, et al. 2015. Use of indocyanine green during robot-assisted ureteral reconstructions. *Eur Urol* **67**(2):291–8.

Liapis A, Bakas P, Giannopoulos V, et al. 2001. Ureteral injuries during gynecological surgery. *Int Urogynecol J Pelvic Floor Dysfunct* **12**(6):391–3; discussion 4.

Madersbacher S, Mohrle K, Burkhard F, et al. 2002. Long-term voiding pattern of patients with ileal orthotopic bladder substitutes. *J Urol* **167**(5):2052–7.

Mansson W, Bakke A, Bergman B, et al. 1997. Perforation of continent urinary reservoirs. Scandinavian experience. *Scand J Urol Nephrol* **31**(6):529–32.

McClung C, Gorbonos A. 2014. Ureteral reimplantation in adults: Open versus robotic. *J Urol* **192**(4):1023–5.

Musch M, Hohenhorst L, Pailliart A, et al. 2013. Robot-assisted reconstructive surgery of the distal ureter: Single institution experience in 16 patients. *BJU Int* **111**(5):773–83.

Neuman M, Eidelman A, Langer R, et al. 1991. Iatrogenic injuries to the ureter during gynecologic and obstetric operations. *Surg Gynecol Obstet* **173**(4):268–72.

Ozdemir E, Ozturk U, Celen S, et al. 2011. Urinary complications of gynecologic surgery: Iatrogenic urinary tract system injuries in obstetrics and gynecology operations. *Clin Exper Obstet Gynecol* **38**(3):217–20.

Patel H, Bhatia N. 2009. Universal cystoscopy for timely detection of urinary tract injuries during pelvic surgery. *Curr Opin Obstet Gynecol* **21**(5):415–8.

Pfitzenmaier J, Lotz J, Faldum A, et al. 2003. Metabolic evaluation of 94 patients 5 to 16 years after ileocecal pouch (Mainz pouch 1) continent urinary diversion. *J Urol* **170**(5):1884–7.

Piscitelli JT, Simel DL, Addison WA. 1987. Who should have intravenous pyelograms before hysterectomy for benign disease? *Obstet Gynecol* **69**(4):541–5.

Porter MP, Penson DF. 2005. Health related quality of life after radical cystectomy and urinary diversion for bladder cancer: A systematic review and critical analysis of the literature. *J Urol* **173**(4):1318–22.

Sakellariou P, Protopapas AG, Voulgaris Z, et al. 2002. Management of ureteric injuries during gynecological operations: 10 years experience. *Eur J Obstet Gynecol Reprod Biol* **101**(2):179–84.

Schimpf MO, Gottenger EE, Wagner JR. 2008. Universal ureteral stent placement at hysterectomy to identify ureteral injury: A decision analysis. *BJOG* **115**(9):1151–8.

Schrier BP, Laguna MP, van der Pal F, et al. 2005. Comparison of orthotopic sigmoid and ileal neobladders: Continence and urodynamic parameters. *Eur Urol* **47**(5):679–85.

Sogni F, Brausi M, Frea B, et al. 2008. Morbidity and quality of life in elderly patients receiving ileal conduit or orthotopic neobladder after radical cystectomy for invasive bladder cancer. *Urology* **71**(5):919–23.

Steers WD. 2000. Voiding dysfunction in the orthotopic neobladder. *World J Urol* **18**(5):330–7.

Stein JP, Penson DF, Lee C, et al. 2009. Long-term oncological outcomes in women undergoing radical cystectomy and orthotopic diversion for bladder cancer. *J Urol* **181**(5):2052–8; discussion 8–9.

Stein R, Rubenwolf P, Ziesel C, et al. 2013. Psoas hitch and Boari flap ureteroneocystostomy. *BJU Int* **112**(1):137–55.

Studer UE, Danuser H, Hochreiter W, et al. 1996. Summary of 10 years' experience with an ileal low-pressure bladder substitute combined with an afferent tubular isoperistaltic segment. *World J Urol* **14**(1):29–39.

Studer UE, Hautmann RE, Hohenfellner M, et al. 1998. Indications for continent diversion after cystectomy and factors affecting long-term results. *Urol Oncol* **4**(4–5):172–82.

Takenaka A, Soga H, Terakawa T, et al. 2009. Assessment of voiding function of orthotopic neobladders in elderly patients with long-term survival. *BJU Int* **103**(7):927–30.

Vakili B, Chesson RR, Kyle BL, et al. 2005. The incidence of urinary tract injury during hysterectomy: A prospective analysis based on universal cystoscopy. *Am J Obstet Gynecol.* **192**(5):1599–604.

Warwick RT, Worth PH. 1969. The psoas bladder-hitch procedure for the replacement of the lower third of the ureter. *British J Urol* **41**(6):701–9.

Waters WB, Whitmore WF, 3rd, Lage AL, et al. 1981. Segmental replacement of the ureter using tapered and nontapered ileum. *Invest Urol* **18**(4):258–61.

Watterson JD, Mahoney JE, Futter NG, et al. 1998. Iatrogenic ureteric injuries: Approaches to etiology and management. *Can J Surg* **41**(5):379–82.

31 Fistula repair

Paul Hilton

ETIOLOGY AND EPIDEMIOLOGY

Urogenital fistulas may occur congenitally, but are most often acquired from obstetric, surgical, radiation, and malignant causes. The same factors may be responsible for intestinogenital fistulas, although inflammatory bowel disease is an additional important etiological factor here. In most under-resourced countries over 90% of fistulas are of obstetric etiology (Hilton and Ward 1998, Hilton 2003, Kelly and Kwast 1993), whereas in the UK and US, approximately 70% follow pelvic surgery (Chassar Moir 1973, Hilton 2012, Lee et al. 1988).

Obstetric Causes

The overwhelming proportion of obstetric fistulas in under-resourced countries are complications of neglected obstructed labor, and result from ischemic necrosis of the soft tissues compressed between the bony pelvis and the fetal presenting parts. In the developed world, however, obstetric fistulas are most typically associated with rupture of the uterus following previous caesarean section or assisted vaginal delivery; such cases have more in common with surgical fistulas than true obstetric fistulas (Table 31.1). Obstetric factors leading to anovaginal or rectovaginal fistulas include an unrecognized fourth-degree tear or infection and breakdown of repair of a third- or fourth-degree tear.

Surgical Causes

Genital fistula may occur following a wide range of surgical procedures within the pelvis (Table 31.1, updated from Hilton 2012). It is often supposed that this complication results from direct injury to the lower urinary tract at the time of operation. Certainly on occasion this may be the case; careless, hurried, or rough surgical technique makes injury to the lower urinary tract much more likely. Of the 498 cases of fistula referred to the author over the last 30 years, 345 (69%) were associated with pelvic surgery and 246 followed hysterectomy (49% overall, 71% of surgical cases); of these, only 8 (3%) presented with leakage of urine on the first day postoperatively (updated from Hilton 2012). In other cases it is presumed that tissue devascularization during dissection, inadvertent suture placement, pelvic hematoma formation, or infection developing postoperatively results in tissue necrosis, with leakage developing usually 5 to 10 days later. Approximately 10% to 15% of postsurgical fistulae present late, between 10 and 30 days after the procedure. Overdistension of the bladder postoperatively may be an additional factor in many of these latter cases. It has been shown that there is a high incidence of abnormalities of lower urinary tract function in fistula patients (Hilton 1998); whether these abnormalities antedate the surgery or develop with or as a consequence of the fistula is unclear. It is likely that patients with a habit of infrequent voiding or those with inefficient detrusor contractility may be at increased risk of postoperative urinary retention; if this is not recognized early and managed appropriately, the risk of fistula formation may be increased. Although it is important to remember that the majority of surgical fistulas follow apparently straightforward hysterectomy in skilled hands, several risk factors may make direct injury more likely (Table 31.2); the actual significance of some of these factors has however recently been questioned (Hilton and Cromwell 2012). Data from Hospital Episode Statistics suggest a rate of one vesicovaginal or urethrovaginal fistula in 540 total (simple) abdominal hysterectomies carried out for benign indications, one in 3860 vaginal hysterectomies carried out for prolapse, one in 2280 subtotal hysterectomies, and one in 90 to 125 radical hysterectomies (for cervix or endometrial cancer) (Hilton and Cromwell 2012). Anovaginal and rectovaginal fistulae may also have a surgical etiology with vaginal hysterectomy, rectocele repair, hemorrhoidectomy, low anterior resection, and panproctocolectomy being commonly associated.

Radiation

Injury to the gastrointestinal tract may arise following therapeutic radiotherapy with the incidence of complications increasing when the radiation dose exceeds 5000 cGy. The obliterative endarteritis associated with ionizing radiation in therapeutic dosage proceeds over many years and may result in fistula formation long after the primary malignancy has been treated. Patients with a vesicovaginal fistula often have symptoms of radiation cystitis that improve on appearance of the fistula. Of the 47 radiation fistulas in the author's personal series, the interval between fistula development and radiotherapy ranged from 1 year to 50 years (updated from Hilton 2012). The associated devascularization in the adjacent tissues means that ordinary surgical repair has a high likelihood of failure, and modified surgical techniques are required.

Malignancy

Excluding the effects of treatment, malignant disease itself may result in genital tract fistula. Carcinoma of cervix, vagina, and rectum are the most common malignancies to present in this way. It is relatively unusual for urothelial tumors to present with fistula formation, other than following surgery or radiotherapy. The development of a fistula may be a distressing part of the terminal phase of malignant disease; it is nevertheless one deserving not simply compassion, but full consideration of the therapeutic or palliative possibilities. Bilateral permanent nephrostomies may achieve continence when all else fails (Krause et al. 1987).

Table 31.1 Etiology of Genital Fistulae in Two Series, from the North of England[a] and from Southeast Nigeria[b]

	NE England		SE Nigeria	
Etiology	***n* = 498**		***n* = 2389**	
Obstetric				
Obstructed labor	2		1918	
Caesarean section	24		165	
Ruptured uterus	9		119	
Forceps/ventouse	6			
Caesarean hysterectomy	5			
Symphysiotomy	2			
Breech extraction	1			
Placental abruption	1			
Obstetric subtotal (% of total)	50	10.0%	2202	92.2%
Surgical				
Abdominal hysterectomy	181		33	
Radical hysterectomy	27			
Colporrhaphy +/− mesh	23		35	
LAVH/TLH	18			
Urethral diverticulectomy	16			
Colectomy	14			
Mid-urethral tape procedures	10			
Vaginal hysterectomy	9		25	
LLETZ	7			
Partial vaginectomy	6			
Cervical stumpectomy	5			
Subtotal hysterectomy	4			
Cystoplasty and colposuspension	3			
Vaginoplasty	3			
Colposuspension	2			
Nephroureterectomy	2			
Sling	2			
Periurethral bulking agents	2			
Needle suspension	2			
Ileoanal pouch	2			
TAH and colporrhaphy	1			
TAH and colposuspension	1			
Laparoscopic oophorectomy	1			
Sub-trigonal phenol injection	1			
Lithoclast	1			
Sacrospinous fixation	1			
Unknown surgery in childhood	1			
Suture to vaginal laceration			12	
Surgical subtotal (% of total)	345	69.3%	105	4.4%
Radiation	47	9.4%	0	
Malignancy	3	0.6%	42	1.8%
Miscellaneous				
Vaginal pessary	20			
Foreign body	9			
Congenital	7			
Infection	6		7	
Catheter induced	4			
Trauma	3		11	
Unexplained	3			
Coital injury	1		22	
Miscellaneous subtotal (% of total)	53	10.6%	40	1.7%

Sources: Updated from Hilton P. 2012. *BJU Int* 110(1):102–10; Hilton P, Ward A. 1998. *Int Urogynecol J Pelvic Floor Dysfunct* 9189–194.

Note: 2389 patients for whom notes were examined, out of total series of 2484 patients.

Inflammatory Bowel Disease

Inflammatory bowel disease is the most significant cause of intestinogenital fistulas in the UK, although these fistulas rarely present directly to the gynecologist. Diverticular disease can produce colovaginal, colouterine, or colovesical fistulas, with surprisingly few symptoms attributable to the intestinal pathology. It has been estimated that 2% of patients with diverticulosis will develop fistulae arising either through direct extension from a ruptured diverticulum or through erosion from a diverticular abscess (Woods et al. 1988). This possibility should not be overlooked if an elderly woman complains of feculent discharge or becomes incontinent without concomitant urinary problems. Pneumaturia and fecaluria are late-presenting signs of a colovesical fistula. Crohn's disease appears to be increasing in frequency in the Western world, and a total fistula rate approaching 40% has been reported (Wagner et al. 2011); in females the involvement of the genital tract may be up to 7% (Badlani et al. 1980, Ben-Ami et al. 2002). Ulcerative colitis, unlike Crohn's disease, is not a transmural disease and therefore it is associated with only a small incidence of rectovaginal fistula. In the author's own series of rectovaginal fistulas, 65% are obstetric in origin, 21% relate to inflammatory bowel disease, 7% follow radiotherapy, and 7% are of uncertain cause.

Miscellaneous

Other miscellaneous causes of fistulas in the genital tract include infection (lymphogranuloma venereum, schistosomiasis, tuberculosis, actinomycosis, measles, noma vaginae), trauma (penetrating trauma, coital injury, neglected vaginal pessaries or other foreign bodies) and catheter-related injuries (see Table 31.1).

Classification

There is no standardized or universally accepted method for describing or classifying fistulas, although development of such a system has been recommended by the International Consultation on Incontinence, to include location and size of the fistula, functional impact, and quantification of the degree of vaginal scarring. The classifications reported by Waaldijk and Goh are increasingly utilized in the evaluation of obstetric fistula, although have little value in the classification of other fistula etiologies (Goh et al. 2009, Waaldijk 1995). Other reported classifications tend to be based on anatomical site, often subclassified into simple fistulas (where the tissues are healthy and access good) or complicated fistulas (where there is tissue loss, scarring, impaired access, involvement of the ureteric orifices, or a coexistent rectovaginal fistula). Urogenital fistulas may be classified into urethral, bladder neck, subsymphysial (a complex form involving circumferential loss of the urethra with fixation to bone), mid-vaginal, juxtacervical or vault fistulas, massive fistulas extending from bladder neck to vault, and vesicouterine or vesicocervical fistulas (Lawson 1978). While over 60% of fistulas in under-resourced countries are mid-vaginal, juxtacervical, or massive (reflecting their obstetric etiology), such cases are relatively rare in Western fistula practice; 50% of the fistulas managed in the UK are situated in the vaginal vault (reflecting their surgical etiology) (Hilton 2012). Rectovaginal fistulas are also classified according to anatomical site and relationship to the anal sphincter.

Table 31.2 Risk Factors for Postoperative Fistula

Risk Factor	Pathology	Specific Example
Anatomical distortion		Fibroids
		Ovarian mass
Abnormal tissue adhesion	Inflammation	Infection
		Endometriosis
	Previous surgery	Caesarean section
		Cone biopsy
		Colporrhaphy
	Malignancy	
Impaired vascularity	Ionizing radiation	Preoperative radiotherapy
	Metabolic abnormality	Diabetes mellitus
	Radical surgery	
Compromised healing		Anemia
		Nutritional deficiency
Abnormality of bladder function		Voiding dysfunction

PRESENTATION

Fistulas between the urinary tract and the female genital tract are characteristically said to present with continuous urinary incontinence, with limited sensation of bladder fullness, and with infrequent voiding. Where there is extensive tissue loss, as in obstetric or radiation fistulas, this typical history is usually present, the clinical findings gross, and the diagnosis rarely in doubt. With surgical fistulas, however, the history may be atypical and the orifice small, elusive, or occasionally completely invisible. Under these circumstances the diagnosis can be much more difficult, and a high index of clinical suspicion must be maintained.

Ureteric fistulas have similar causes to bladder fistulas, and the mechanism may be one of direct injury by incision, division, or excision, or of ischemia from strangulation by suture, crushing by clamp, or stripping by dissection; the presentation may therefore be similarly variable (Yeates 1987). With direct injury, leakage is usually apparent from the first postoperative day. Urine output may be physiologically reduced for some hours following surgery, and if there is significant operative or postoperative hypotension, oliguria may persist longer. Once renal function is restored, however, leakage will usually be apparent promptly. With other mechanisms, obstruction is likely to be present to a greater or lesser degree, and the initial symptoms may be of pyrexia or loin pain, with incontinence occurring only after sloughing of the ischemic tissue, from around 5 days up to 6 weeks later.

INVESTIGATIONS

If there is suspicion of a fistula but its presence is not easily confirmed by clinical examination with a speculum, further investigation will be necessary to confirm or exclude the possibility fully. Even where the diagnosis is clinically obvious, additional investigation may be appropriate for full evaluation prior to deciding treatment. The main principles of investigation therefore are:

- To confirm that the discharge is urinary/fecal
- To establish that the leakage is extraurethral rather than urethral
- To establish the site of leakage
- To exclude other organ involvement

Biochemistry and Microbiology

Excessive vaginal discharge or drainage of serum from a pelvic hematoma postoperatively may simulate a urinary fistula. If the fluid is in sufficient quantity to be collected, biochemical analysis of its urea content in comparison with that of urine and serum will confirm its origin. Urinary infection is surprisingly uncommon in fistula patients, although urine culture should be undertaken (especially where there have been previous attempts at surgery) and appropriate antibiotic therapy instituted.

Dye Studies

Although other imaging techniques undoubtedly have a role (see below), carefully conducted dye studies remain the investigation of first choice. Phenazopyridine may be used orally (no longer available in the UK), or indigo carmine intravenously, to stain the urine and hence confirm the presence of a fistula. The identification of the site of a fistula is best carried out by the instillation of colored dye (methylene blue or indigo carmine) into the bladder through a catheter with the patient in the lithotomy position. The traditional "three-swab test" has its limitations and is not recommended; the examination is best carried out with direct inspection, and multiple fistulas may be located in this way (Figure 31.1). If leakage of clear fluid continues after dye instillation a ureteric fistula is likely, and this is most easily confirmed by a "two-dye test," using phenazopyridine to

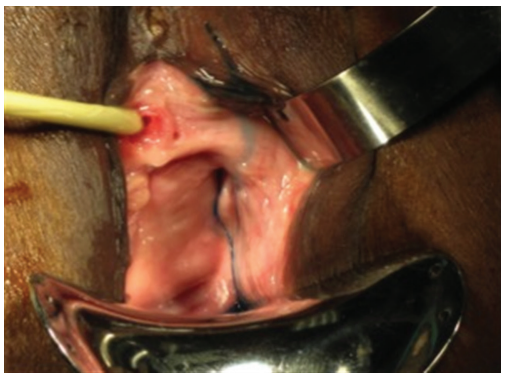

Figure 31.1 Urethrovaginal and vesicoperineal fistulas following pelvic fracture, identified by methylene blue dye testing.

stain the renal urine and methylene blue to stain bladder contents (Raghavaiah 1974).

Dye tests are less useful for intestinal fistulas, although a carmine marker taken orally may confirm their presence. Rectal distension with air via a sigmoidoscope may be of more value; if the patient is kept in a slight head-down position and the vagina filled with saline, the bubbling of any air leaked through a low fistula may be detected.

Imaging

Excretion Urography

Although intravenous urography is a particularly insensitive investigation in the diagnosis of vesicovaginal fistula, knowledge of upper urinary tract status may have a significant influence on treatment measures applied, and should therefore be looked on as an essential investigation for any suspected or confirmed urinary fistula. Compromise to ureteric function is a particularly common finding when a fistula occurs in relation to malignant disease or its treatment (by radiation or surgery).

Dilatation of the ureter is characteristic in ureteric fistula, and its finding in association with a known vesicovaginal fistula should raise suspicion of a complex ureterovesicovaginal lesion (Figure 31.2). While essential for the diagnosis of ureteric fistula, intravenous urography is not completely sensitive; the presence of a periureteric flare is, however, highly suggestive of extravasation at this site.

Retrograde Pyelography

Retrograde pyelography is a more reliable way of identifying the exact site of a ureterovaginal fistula (see Figure 31.3), and may be undertaken simultaneously with either retrograde or percutaneous catheterization for therapeutic stenting of the ureter (see Chapter 7).

Cystography

Cystography is not particularly helpful in the basic diagnosis of vesicovaginal fistulas, and a dye test carried out under direct vision is likely to be more sensitive. It may, however, occasionally be useful in achieving a diagnosis in complex fistulas or vesicouterine fistulas.



Figure 31.2 Intravenous urogram (with simultaneous cystogram) demonstrating a complex surgical fistula occurring after radical hysterectomy. After further investigation including cystourethroscopy, sigmoidoscopy, barium enema and retrograde cannulation of the vaginal vault to perform fistulography, the lesion was defined as an ureterocolovesicovaginal fistula.

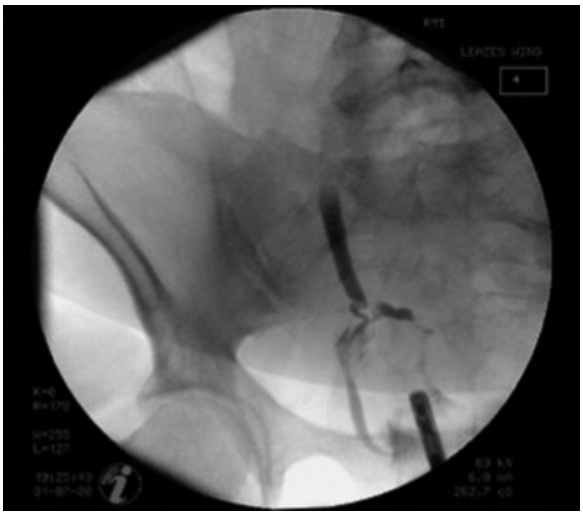

Figure 31.3 Retrograde pyelogram demonstrating ureterovaginal fistula.

Fistulography

Fistulography is a special example of the x-ray technique commonly referred to as sinography. For small fistulas a ureteric catheter is suitable, although if the hole is large enough a small Foley catheter may be used to deliver the radio-opaque dye; this is particularly valuable for fistulas for which there is an intervening abscess cavity. If a catheter will pass through a small vaginal aperture into an adjacent loop of bowel its nature may become apparent from the radiological appearance of the lumen and haustrations, although further imaging studies are usually required to demonstrate the underlying pathology.

Barium Enema, Barium Meal, and Follow-Through

Proctography may be used to identify the site of anovaginal or rectovaginal fistulas, although it has been suggested that vaginography has a higher sensitivity (Giordano et al. 1996). Barium enema, barium meal, or both may be required when a fistula is present above the anorectum. Aside from confirming the presence of a fistula, this allows evaluation of the intestinal condition, and malignant or inflammatory disease may be identified.

Ultrasonography, Computerized Tomography, and Magnetic Resonance Imaging

Ultrasonography, computerized tomography (CT) and magnetic resonance imaging (MRI) may occasionally be appropriate for the complete assessment of complex fistulas. Endoanal ultrasound scans and MRI are particularly useful in the investigation of anorectal and perineal fistulas and have been shown to have positive predictive rates of 100% and 92%, respectively (Stoker et al. 2002).

Examination Under Anesthesia

Careful examination, if necessary under anesthesia, may be required to determine the presence of a fistula, and is deemed by several authorities to be essential for definitive surgical treatment. It is important at the time of examination to assess the available access for repair vaginally, and the mobility of the tissues. The decision between the vaginal and abdominal approaches to surgery is thus made; when the vaginal route is chosen, it may

be appropriate to select between the more conventional supine lithotomy, with a head-down tilt, and the prone (reverse) lithotomy position with head-up tilt. This may be particularly useful in allowing the operator to look down onto bladder neck and subsymphysial fistulas, and is also of advantage in some massive fistulas in encouraging the reduction of the prolapsed bladder mucosa. A rectovaginal examination may detect a rectovaginal fistula; probing of a perineal sinus with a fine metallic catheter may identify an anoperineal tract.

Endoscopy

Cystoscopy

Although some authorities suggest that endoscopy has little role in the evaluation of fistulas, it is the author's practice to perform cystourethroscopy in all but the largest defects. Although in some obstetric and radiation fistulas the size of the defect and the extent of tissue loss and scarring may make it difficult to distend the bladder, nevertheless much useful information is obtained. The exact level and position of the fistula should be determined, and its relationships to the ureteric orifices and bladder neck are particularly important. Most post-hysterectomy fistulas are supra-trigonal and located on the posterior bladder wall (Figure 31.4), while post-radiation fistulas usually involve the trigone and/or bladder neck (Figure 31.5). With urethral and bladder neck fistulas, the failure to pass a cystoscope or sound may indicate that there has been circumferential loss of the proximal urethra, a circumstance which is of considerable importance in determining the appropriate surgical technique and the likelihood of subsequent urethral incompetence.

The condition of the tissues must be carefully assessed. Persistence of slough means that surgery should be deferred, and this is particularly important in obstetric and post-radiation cases. Biopsy from the edge of a fistula should be taken in radiation fistulas if persistent or recurrent malignancy is suspected. Malignant change has been reported in a longstanding benign fistula, so where there is any doubt at all about the nature of the tissues, biopsy should be undertaken (Hudson 1968). In endemic areas, evidence of schistosomiasis, tuberculosis, and lymphogranuloma may become apparent in biopsy material, and again it is important that specific antimicrobial treatment is instituted prior to definitive surgery.

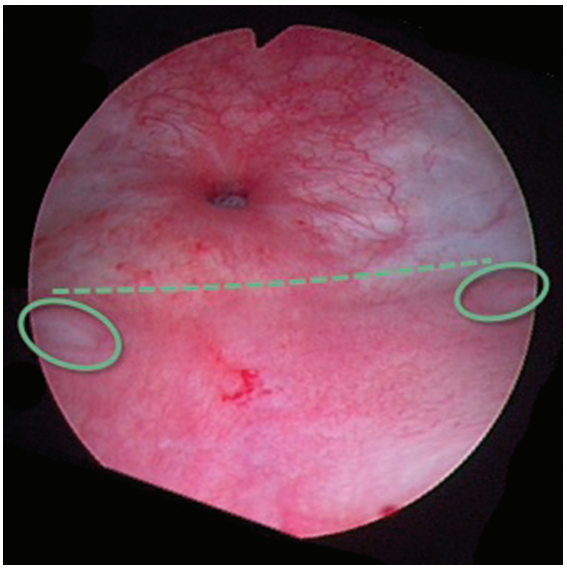

Figure 31.4 Cystoscopy demonstrating post-hysterectomy vesicovaginal fistula above interureteric bar (shown as dashed green line).



Figure 31.5 Vaginal examination in mid-vaginal fistula following radiotherapy for cervix cancer.

Colonoscopy, Sigmoidoscopy, and Proctoscopy

Colonoscopy, sigmoidoscopy, and proctoscopy are important for the diagnosis of inflammatory bowel disease, which may not have been suspected before the occurrence of a fistula. The presence of air bubbles escaping from the vagina when it is filled with saline allows identification of the site of any fistula. Biopsy specimens of the fistula edge of any unhealthy-looking area should always be obtained.

PREOPERATIVE MANAGEMENT

Before epithelialization is complete, an abnormal communication between viscera will tend to close spontaneously, provided that the natural outflow is unobstructed. Bypassing the sphincter mechanisms, for example by urinary catheterization or defunctioning colostomy, may encourage closure.

Urogenital Fistula

Early management is of critical importance, and depends on the etiology and site of the lesion. If surgical trauma is recognized within the first 24 hours postoperatively, immediate repair may be appropriate, provided that extravasation of urine into the tissues has not been great. The majority of surgical fistulas, however, are recognized between 5 days and 14 days postoperatively, and should be treated with continuous bladder drainage. It is worth persisting with this line of management in vesicovaginal or urethrovaginal fistulas for 6 to 8 weeks, since spontaneous closure may occur within this period (Davits and Miranda 1991, Gorrea et al. 1985, Waaldijk 1994, Waaldijk 1997).

Obstetric fistulas developing after obstructed labor should also be treated by continuous bladder drainage, combined with antibiotics to limit tissue damage from infection. Indeed, if a patient is known to have been in obstructed labor for any significant length of time, or is recognized to have areas of slough on the vaginal walls in the puerperium, prophylactic catheterization should be undertaken (Waaldijk 1994, Waaldijk 1997).

Immediate management should also include attention to palliation and skin care, nutrition, physiotherapy, rehabilitation, and overall patient morale. In women wishing to avoid surgery and where bladder drainage is unsuccessful, other conservative treatments may be indicated when the vesicovaginal fistula is very small. Small series and case reports have indicated success with fibrin glue (Shekarriz and Stoller 2002), electrofulguration, laser ablation (Dogra and Saini 2011), or combinations of these modalities; no large series, however, have confirmed their value.

Surgical fistula patients are usually previously healthy individuals who entered the hospital for what was expected to be a routine procedure, and end up with symptoms infinitely worse than their initial complaint. Obstetric fistula patients in under-resourced countries are social outcasts (Muleta et al. 2008, Muleta et al. 2010, Murphy 1981, Zacharin 1988). Whatever the cause, these women are invariably devastated by their situation. It is vital that they understand the nature of the problem, why it has arisen, and the plan for management at all stages. Confident but realistic counseling by the surgeon is essential, and the involvement of nursing staff or counselors with experience of fistula patients is also highly desirable. The support given by previously treated sufferers can also be of immense value in maintaining patient morale, especially where a delay prior to definitive treatment is required (Hilton 1997, de Ridder et al. 2013).

Intestinogenital Fistula

In determining the most appropriate management, consideration should be given to the underlying etiology of the intestinovaginal fistula. In patients with obstetric fistula, endoanal ultrasound should be performed to detect anal sphincter damage, as the presence or absence of sphincteric injury may alter the choice of procedure. In patients with radiation rectovaginal fistulae or in those with inflammatory bowel disease, preoperative anorectal manometry is necessary to assess rectal compliance. When rectal reservoir function is poor, there is unlikely to be a good response from local repair. For recurrent fistulas, radiation-induced fistulas, for those associated with active inflammatory bowel disease, or for ileo- or colovaginal fistulas, a preliminary defunctioning colostomy may be appropriate. However, for the majority of rectovaginal fistulas, defunctioning of the bowel is not required. Surgeons vary in the extent to which they prepare the bowel prior to rectovaginal fistula repair. Current evidence suggests that bowel cleansing can be safely omitted prior to colonic surgery without increasing the risk of perioperative complications (Guenaga et al. 2011), and most now would simply administer an enema prior to operation if patients have not moved their bowel within the previous 24 hours.

GENERAL PRINCIPLES OF SURGICAL TREATMENT

Timing of Repair

Urogenital Fistula

The timing of surgical repair is perhaps the single most contentious aspect of fistula management. While shortening the waiting period is of both social and psychological benefit to patients who are always very distressed, one must not trade these issues for compromise to surgical success. The benefit of delay is to allow slough to separate and inflammatory change to resolve. In both obstetric and radiation fistulas there is considerable sloughing of tissues, and it is imperative that this should have settled before repair is undertaken. In radiation fistulas it may be necessary to wait 12 months or more. In obstetric cases most authorities suggest that a minimum of 3 months should be allowed to elapse, although others have advocated surgery as soon as slough is separated (Waaldijk 2004).

With surgical fistulas the same principles should apply, and although the extent of sloughing is limited, extravasation of urine into the pelvic tissues inevitably sets up some inflammatory response. Although early repair is advocated by several authors, again most would agree that 10 to 12 weeks postoperatively is the earliest appropriate time for repair. However, few studies have reported their outcomes for both early and late approaches to management, and none have randomized patients between these approaches; overall the results do not appear to be significantly different (de Ridder et al. 2013).

Pressure from patients to undertake repair at the earliest opportunity is always understandably great, but is never more so than in the case of previous surgical failure. Such pressure must however be resisted, and 8 weeks is the minimum time that should be allowed between attempts at closure.

Intestinogenital Fistula

Similarly, repair should be delayed until infection has been treated and inflammation and induration has resolved, to allow improved tissue handling. Some rectovaginal fistulas will heal spontaneously during this time. After a failed repair, an interval of 3 months should be allowed before undertaking further repair surgery. When there is a coexisting urogenital fistula, then rectovaginal fistula repair should be undertaken after and separately from urogenital fistula repair. In such cases transverse colostomy may be used to temporarily divert feces away from the urogenital repair site until repair of the rectovaginal fistula. In patients with inflammatory bowel disease, repair should be delayed until the disease is quiescent and sepsis treated.

Route of Repair

Urogenital Fistula

Many urologists advocate an abdominal approach for all fistula repairs, claiming the possibility of earlier intervention and higher success rates in justification. Others suggest that all fistulas can be successfully closed by the vaginal route. Surgeons involved in fistula management must be capable of both approaches, and have the versatility to modify their techniques to select that most appropriate to the individual case (de Ridder et al. 2013, Hilton 1997). Where access is good and the vaginal tissues sufficiently mobile, the vaginal route is usually most appropriate. If access is poor and the fistula cannot be brought down, the abdominal approach should be used. When the fistula lies close to the ureteric orifices and there is a risk of ureteric injury during repair, then ureteric stenting may allow the vaginal approach. Alternatively, the need for ureteric reimplantation necessitates an abdominal approach. In the presence of a greatly reduced cystometric capacity, as often seen in post-radiation fistulas, the need for concomitant cystoplasty necessitates an abdominal approach. Overall,

more surgical fistulas are likely to require an abdominal repair than obstetric fistulas, although in the author's series of cases from the UK (Hilton 2012), and those reviewed from Nigeria (Hilton and Ward 1998), two-thirds of cases were satisfactorily treated by the vaginal route regardless of etiology.

Over the last decade there have been increasing reports of laparoscopic and robotic repair of vesicovaginal fistula. Recent systematic reviews have identified up to 35 reports of small case series (mean six cases) of laparoscopic repair and nine series of (mean four cases) of robotic repair; the quality of all reports was poor, with high risk of selection and reporting biases that make it difficult to fully evaluate these procedures against alternative surgical approaches (de Ridder et al. 2013, Hillary et al. 2016, Miklos et al. 2015).

Intestinogenital Fistula

This will depend on the anatomical site of the fistula, number of previous repair attempts, surgeon's preference, presence or absence of anal sphincter damage, and presence or absence of intestinal or vaginal stenosis. In cases of colovaginal or enterovaginal fistulas, laparotomy is usually required, and recurrence rates are low because of mobilization of healthy tissue. In repairing rectovaginal fistulae, the current approaches include transperineal, transanal, or transvaginal repair.

Instruments

All operators have their own favored instruments, although those described by Chassar Moir and Lawson (Chassar Moir 1967, Lawson 1978, Lawson and Hudson 1987) are eminently suitable for repair by any route (Figure 31.6). The following are particularly useful:

- Series of fine scalpel blades on the no. 7 handle, especially the curved no. 12 bistoury blade
- Chassar Moir 30° angled-on-flat and 90° curved-on-flat scissors
- Cleft palate forceps
- Judd-Allis, Stiles, and Duval tissue forceps
- Millin retractor for use in transvesical procedures, and Currie's retractors for vaginal repairs; the Lone Star™ (CooperSurgical Inc., Trumbull, CT, USA) ring retractor may also be used to advantage particularly for vaginal procedures
- Skin hooks to put the tissues on tension during dissection
- Turner-Warwick double curved needle holder—particularly useful in areas of awkward access, and has the advantage of allowing needle placement without the operator's hand or the instrument obstructing the view

Dissection

Great care must be taken over the initial dissection of the fistula, and this stage should probably take as long as the repair itself. The fistula should be circumcised in the most convenient orientation, depending on size and access. All things being equal, a longitudinal incision should be made around urethral or midvaginal fistulas; conversely, vault fistulas are better handled by a transverse elliptical incision. The tissue planes are often obliterated by scarring, and dissection close to a fistula should therefore be undertaken with a scalpel or scissors. Sharp dissection is easier with counter traction applied by skin hooks, tissue forceps, or retraction sutures; a Lone Star retractor can be particularly helpful in this regard (Figure 31.7). Blunt dissection with small pledgets or "stamps" may be helpful once the planes are established, and provided it takes place away from the fistula edge. Wide mobilization should be performed so that tension on the repair is minimized. Bleeding is rarely troublesome with vaginal procedures, except occasionally with proximal urethro-vaginal fistulas. Diathermy is best avoided, and pressure or under running sutures are preferred.

Suture Materials

Although a range of suture materials has been advocated over the years, and different opinions still exist, the author's view is that absorbable sutures should be used throughout all urinary fistula repair procedures. Polyglactin (Vicryl, Ethicon, Edinburgh, UK) 2-0 or 3-0 suture on a 25-mm heavy tapercut needle is preferred for both the bladder and vagina, and polydioxanone (PDS, Ethicon, Edinburgh, UK) 4-0 on a 13-mm round-bodied needle is used for the ureter; 3-0 sutures on a 30-mm round-bodied needle are used for bowel surgery, polydioxanone for the small bowel, and either polydioxanone or braided polyamide (Nurolon, Ethicon, Edinburgh, UK) for large bowel reanastomosis.

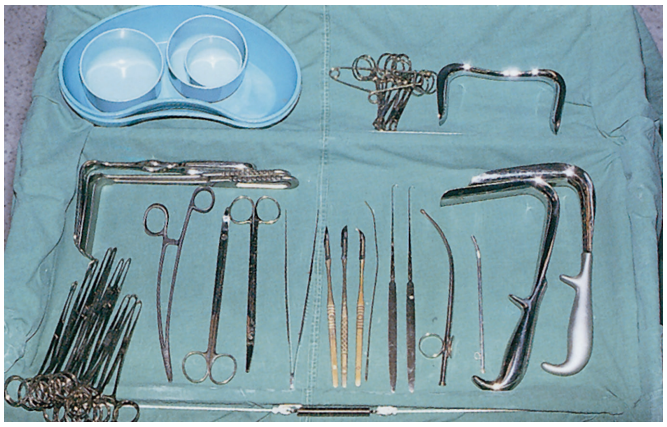

Figure 31.6 Fistula repair instruments.

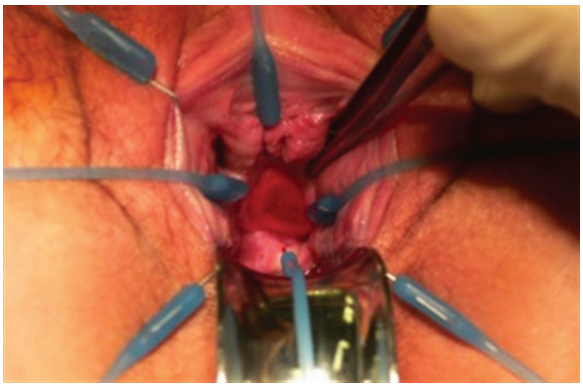

Figure 31.7 Lone Star retractor allows the fistula to be brought into a more accessible position.

OPERATIVE TECHNIQUE

Urogenital Fistula Repair

Dissection and Repair in Layers

Two main types of closure technique are applied to the repair of urinary fistulas: the classical saucerization technique described by Sims in 1852, and the much more commonly used dissection and repair in layers. Figures 31.8 to 31.13 demonstrate the latter form of repair in a post-hysterectomy vault fistula.

Tissue forceps, traction sutures, or Lone Star retractor are applied to bring the fistula more clearly into view and obtain optimal access for repair (Figure 31.7). Infiltration with 1:200,000 adrenaline helps to reduce bleeding, and may aid dissection by separating tissue planes to some degree. With small lesions it may be helpful to identify the fistula with a probe or Fogarty catheter so that the track is not "lost" after dissection. The fistula is then circumcised in a transverse elliptical fashion using a no. 12 scalpel blade (Figure 31.8); this should start posteriorly and be completed on the anterior aspect. The dissection is then extended using scissors; Chassar Moir 30° angled-on-flat and 90° curved-on-flat scissors are particularly useful in this respect (Figure 31.9). The vaginal walls should be undermined so that the underlying bladder is mobilized for 1 to 2 cm beyond the fistula edge. The vaginal scar edge may then be trimmed, although most often it is simply inverted within the repair. Sutures must be placed with meticulous accuracy in the bladder wall, care being taken not to penetrate the mucosa, which should be inverted as far as possible. The repair should be started at either end, working toward the midline, so that the least accessible aspects are sutured first (Figure 31.10). Interrupted sutures are preferred and should be placed approximately 3 mm apart, taking as large a bite of tissue as feasible. Stitches that are too close together, or the use of continuous or purse-string sutures, tend to impair blood supply and interfere with healing. Knots must

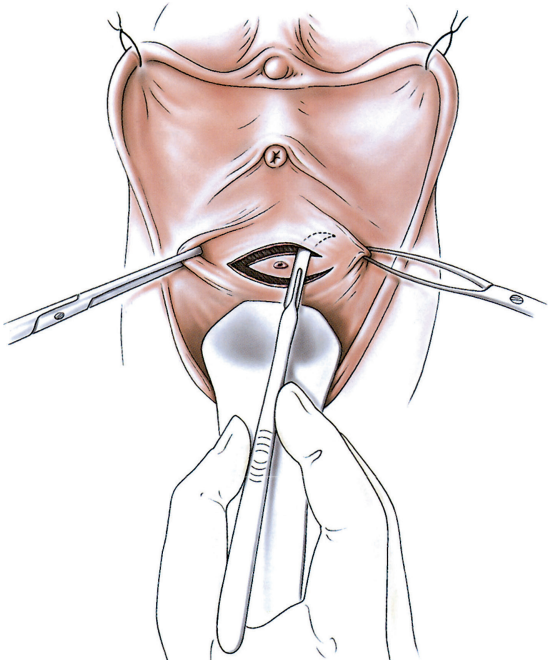

Figure 31.8 Traction sutures or tissue forceps allow the fistula to be brought into a more accessible position; the fistula is then circumcised in a transverse elliptical fashion, using a no. 12 scalpel blade.

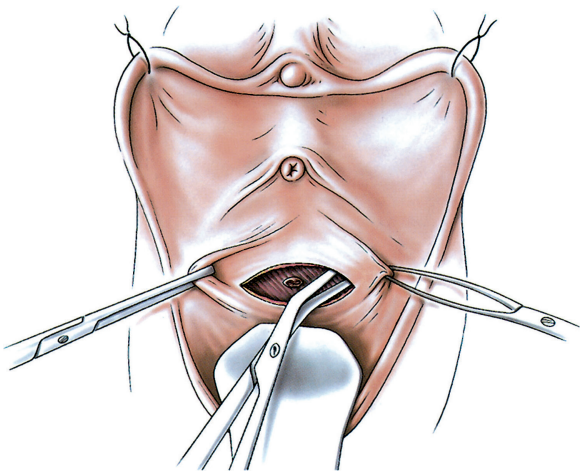

Figure 31.9 The dissection is then extended using scissors; the vaginal walls should be undermined so that the underlying bladder is mobilized for 1 to 2 cm beyond the fistula edge.

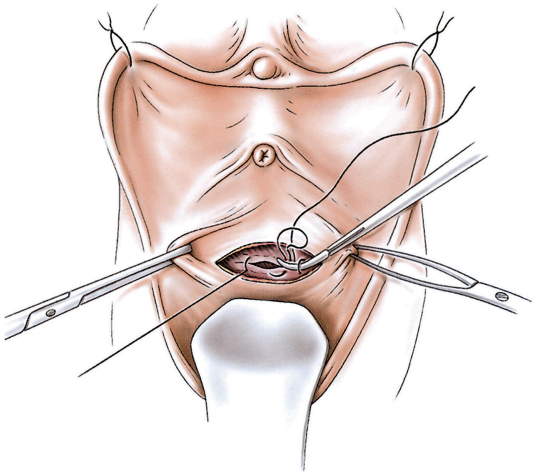

Figure 31.10 The repair is started at either end, working towards the midline, so that the least accessible aspects are sutured first.

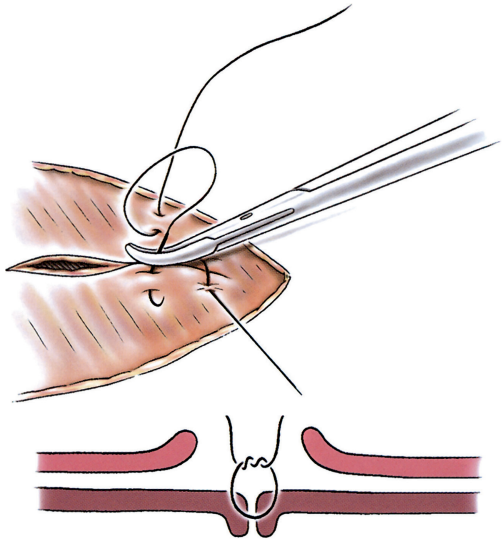

Figure 31.11 The first layer of sutures in the bladder inverts the bladder edges.

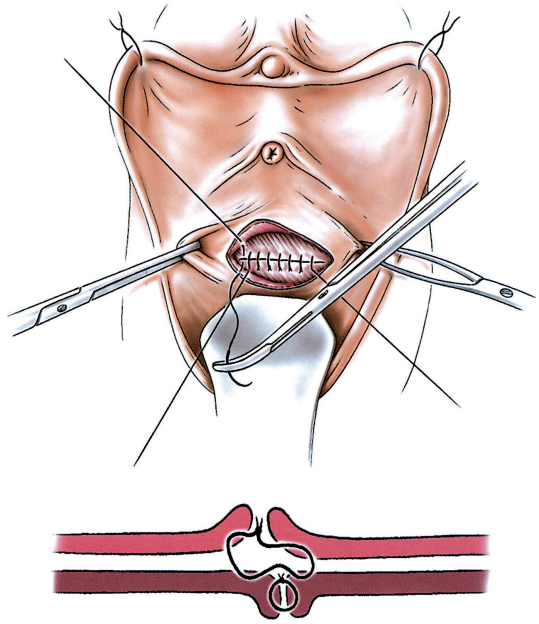

Figure 31.12 The second layer of sutures adds bulk to the repair by taking a wide bite of bladder wall, and closes off dead space by catching the back of the vaginal flaps.

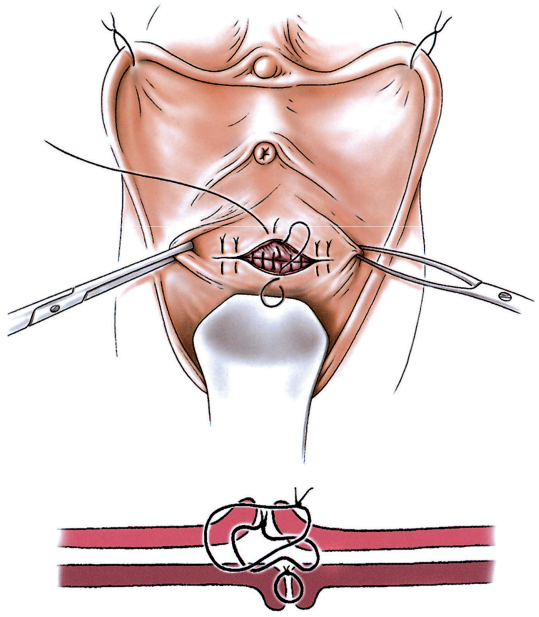

Figure 31.13 After the repair has been tested, a third layer of interrupted mattress sutures is used to evert and close the vaginal wall, consolidating the repair by picking up the underlying bladder wall.

be secure with three hitches so that they can be cut short, leaving the minimum amount of suture material. With dissection and repair in layers, the first layer of sutures in the bladder should invert the bladder edges (Figure 31.11); the second adds bulk to the repair by taking a wide bite of bladder wall, but also closes off dead space by catching the back of the vaginal flaps (Figure 31.12). After the repair has been tested, a third layer of interrupted mattress sutures is used to evert and close the vaginal wall, consolidating the repair by picking up the underlying bladder wall (Figure 31.13).

Saucerization

The saucerization technique involves converting the track into a shallow crater, which is closed without dissection of the bladder from the vagina using a single row of interrupted sutures (Figure 31.14). The method is only applicable to small fistulas, and perhaps to residual fistulas after closure of a larger defect; in other situations, the technique does not allow secure closure without tension.

Vaginal Repair Procedures in Specific Circumstances

The conventional dissection and repair in layers as described above is entirely appropriate for the majority of mid-vaginal fistulas, although modifications may be necessary in specific circumstances. In juxtacervical fistulas in the anterior fornix, vaginal repair may be feasible if the cervix can be drawn down to provide access. Dissection should include mobilization of the bladder from the cervix. The repair should be undertaken transversely to reconstruct the underlying trigone and prevent distortion of the ureteric orifices; the second layer of the repair is used to roll the defect onto the intact cervix, for additional support (Figure 31.15).

Vault fistulas, particularly those following hysterectomy, can again usually be managed vaginally (Hilton 2012, Lawson 1972). The vault is incised transversely and mobilization of the fistula is often aided by deliberate opening of the pouch of Douglas. The peritoneal opening does not need to be closed separately, but is incorporated into the vaginal closure.

With subsymphysial fistulas involving the bladder neck and proximal urethra as a consequence of obstructed labor, tissue loss may be extensive, and fixity to underlying bone a common problem. The lateral aspects of the fistula require careful mobilization to overcome disproportion between the defect in the bladder and the urethral stump. A racquet-shaped extension of the incision facilitates exposure of the proximal urethra. Although transverse repair is often necessary, longitudinal closure gives better prospects for urethral competence.

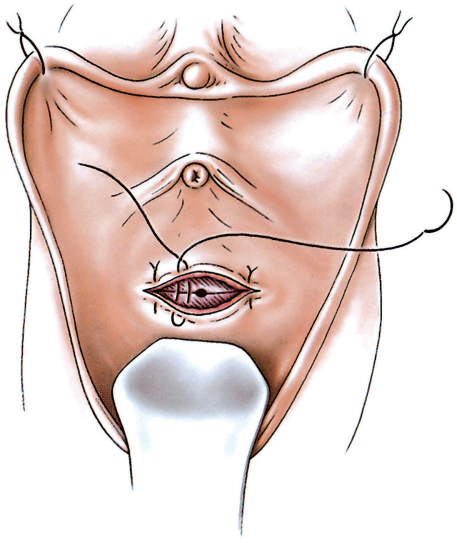

Figure 31.14 The saucerization technique involves converting the track into a shallow crater, which is closed without dissection of bladder from vagina using a single row of interrupted sutures.

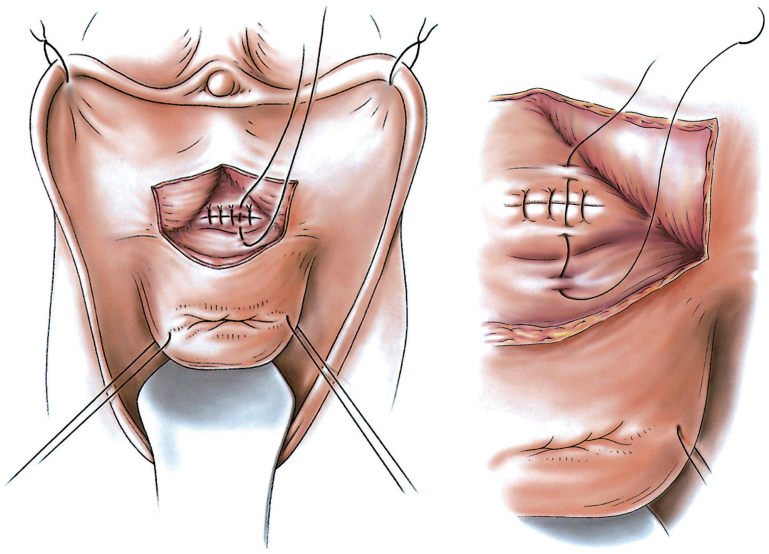

Figure 31.15 (**A**) Vaginal repair of a juxtacervical fistula may be feasible if the cervix can be drawn down to provide access; dissection includes mobilization of the bladder from the cervix, and the repair should be undertaken transversely to reconstruct the underlying trigone and prevent distortion of the ureteric orifices. (**B**) Shows this in greater detail.

Where there is substantial urethral loss, reconstruction may be undertaken using the method described by Chassar Moir (1967) or Hamlin and Nicholson (1969). After a U-shaped incision is made on the anterior vaginal wall, extending from the posterior edge of the fistula to the intended position of the external meatus, a strip of anterior vaginal wall is constructed into a tube over a catheter (Figure 31.16). Plication of muscle behind the bladder neck is probably important if continence is to be achieved. The interposition of a labial fat or muscle graft not only fills up the potential dead space, but provides additional bladder neck support and improves continence by reducing scarring between bladder neck and vagina (Browning 2006, Carey et al. 2002). When intrinsic sphincter deficiency is present, encouraging continence rates have been reported when a rectus sheath sling is fashioned at the time of the flap repair and where the sling is positioned below the interposition graft separating it from the urethra (Morton and Hilton 2009).

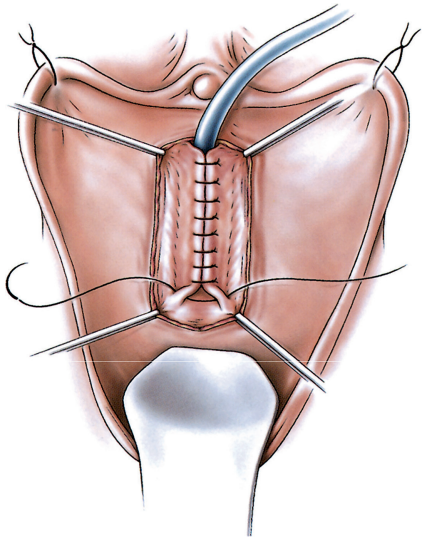

Figure 31.16 In urethral reconstruction a strip of anterior vaginal wall is constructed into a tube over a catheter.

With very large fistulas extending from bladder neck to vault, the extensive dissection required may produce considerable bleeding. The main surgical difficulty is to avoid the ureters. They are usually situated close to the superolateral angles of the fistula, and if they can be identified they should be catheterized. Straight ureteric catheters passed transurethrally, or double pigtail catheters, may both be useful in detecting the intramural portion of the ureters internally; nevertheless, great care must be taken during dissection.

Radiation fistulas present particular problems in that the area of devitalized tissue is usually considerably larger than the fistula itself. Mobilization is often impossible, and if repair in layers is attempted the flaps are likely to slough. For patients in whom sexual activity is not required, closure by colpocleisis may be the most effective means of achieving continence (Figure 31.17). Some have advocated total closure of the vagina, although it may be preferable to avoid dissection in the devitalized tissue entirely and to perform a lower partial colpocleisis, essentially converting the upper vagina into a diverticulum of the bladder. It is usually necessary to fill the dead space below this with an interposition graft (Figures 31.18, 31.19).

Abdominal Repairs

Transvesical Repair

Repair by the abdominal route is indicated when high fistulas are fixed in the vault and are therefore inaccessible per vaginam. Transvesical repair has the advantage of being entirely extraperitoneal. It is often helpful to elevate the fistula site by a vaginal pack, and the ureters should be catheterized under direct vision. The technique of closure is similar to that of the transvaginal flap-splitting repair except that for hemostasis the bladder mucosa is also closed, using a continuous suture (Figure 31.20).

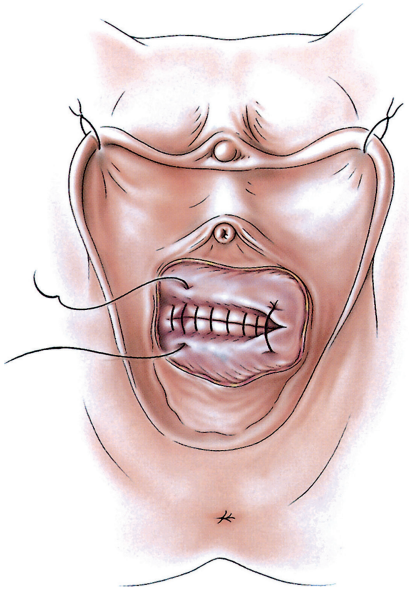

Figure 31.17 In colpocleisis for the treatment of a radiation fistula by the vaginal route, the dissection should be commenced well away from the fistula edge, aiming to be in normally vascularized tissues as far as possible. Several rows of sutures may be required.

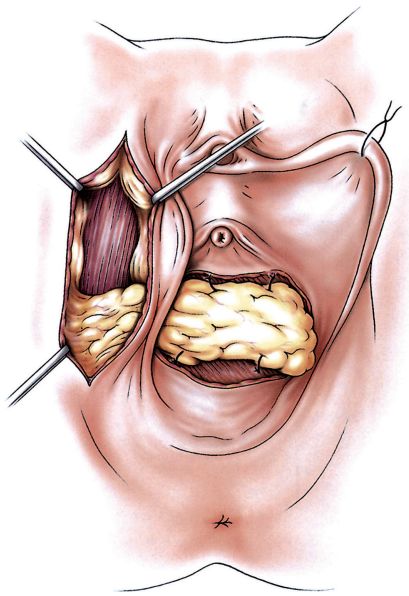

Figure 31.18 A Martius labial fat graft may often be necessary to fill dead space.

Transperitoneal Repair

It is often said that there is little place for a simple transperitoneal repair, although a combined transperitoneal and transvesical procedure is favored by urologists and is particularly useful for vesicouterine fistulas following caesarean section. A midline split is made in the vault of the bladder; this is extended downward in a racquet shape around the fistula (Figure 31.21). The fistulous track is excised and the vaginal or cervical defect closed in a single layer (Figure 31.22). The bladder is then closed in one or two layers; either continuous or interrupted sutures may be employed. The interposition of an omental graft may also be considered if there is doubt over the integrity of the repair; this is also said to be particularly appropriate when the technique is used for the repair of radiation fistulas (Kiricuta and Goldstein 1972),

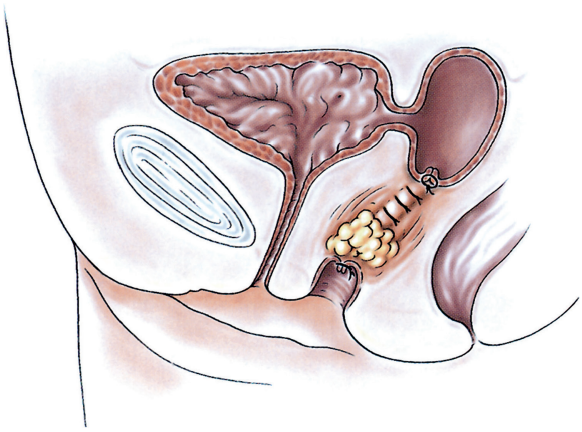

Figure 31.19 The vaginal or vulval skin is closed with interrupted sutures to cover the fat graft.

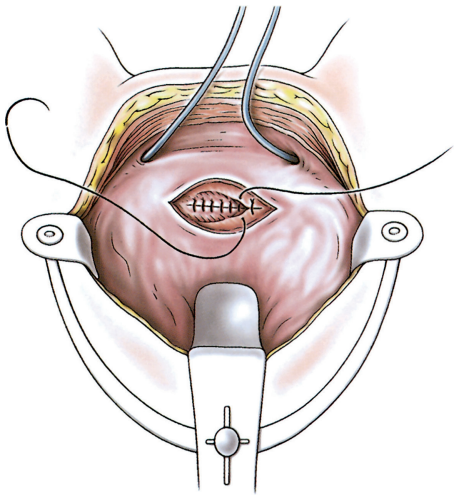

Figure 31.20 Transvesical fistula repair. After its mobilization from the overlying bladder wall, the vagina has been closed with a single layer of inverting interrupted sutures. The figure shows the bladder being closed with a similar layer of interrupted sutures, picking up the vagina also to close dead space. A continuous suture will be inserted into the urothelium for hemostatic purposes.

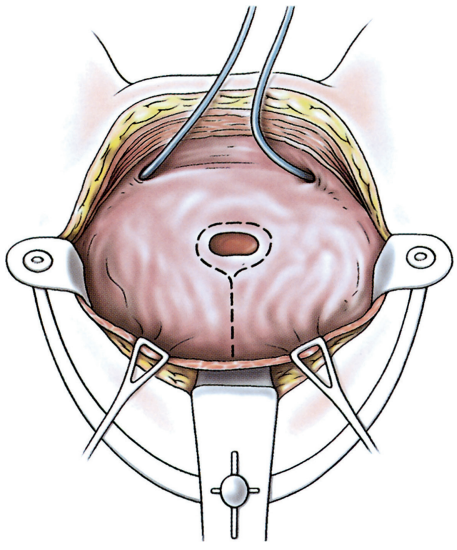

Figure 31.21 Transperitoneal transvesical repair. A midline split is made in the vault of the bladder and is extended downward in a racquet shape around the fistula.

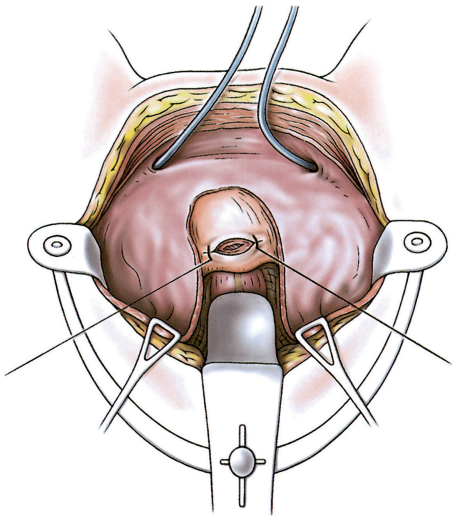

Figure 31.22 Transperitoneal transvesical repair. The fistulous track is excised and the vaginal or cervical defect closed in a single layer; the bladder is then closed in either one or two layers. An omental interposition graft may also be inserted, particularly when the technique is used for the repair of radiation fistula.

although there are no high quality studies confirming benefit from interposition grafts in this or other situations (de Ridder et al. 2013).

Ureteric Reimplantation

For ureteric fistulas not manageable by stenting, reimplantation is considered preferable to reanastomosis of the ureter itself, which carries a greater risk of stricture. Several techniques are described for ureteroneocystostomy, and the choice will depend on the level of the fistula and the nature of the antecedent pathology. For ureteric lesions within the pelvis, mobilization of the bladder from the opposite pelvic sidewall may be all that is required to allow reimplantation without tension. Otherwise the most widely used techniques are reimplantation using a psoas hitch (Figure 31.23) or the creation of a flap of bladder wall, the Boari–Ockerblad technique (Figure 31.24) (see Chapter 34). There are few lesions that are too high for these approaches, although where there is significant deficiency it may be necessary to perform an end-to-side anastomosis between the injured ureter and the good contralateral ureter; i.e., a transureteroureterostomy, or to interpose a loop of small bowel (Yeates 1987).

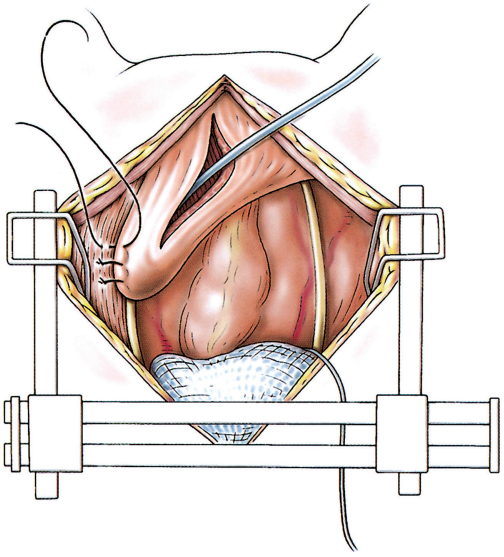

Figure 31.23 Ureteric reimplantations. Where the bladder cannot easily be mobilized sufficiently, a psoas hitch may allow reimplantation without tension.

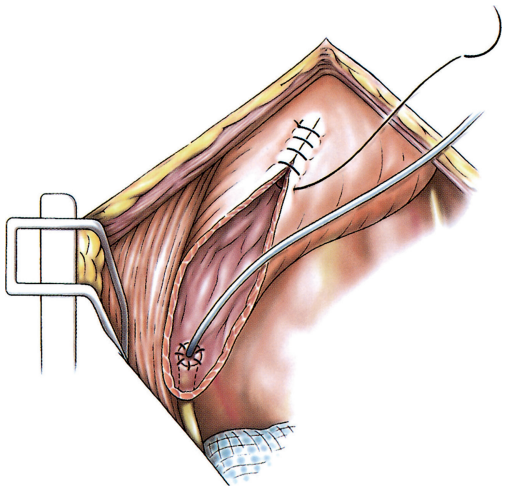

Figure 31.24 For high ureteric injury, the Boari–Ockerblad technique may be appropriate, utilizing a flap of bladder wall to fill the deficiency.

Interposition Grafting

Several techniques have been described to support fistula repair in different sites (see also Chapter 21). While there is no high-level evidence to support these techniques (de Ridder et al. 2013), the interposed tissue may serve to create an additional layer in the repair, to fill dead space, and to bring new blood supply into the area. The tissues used include:

- Martius graft—a vertical incision is made over the labium majus and a graft of labial fat and bulbocavernosus muscle fashioned by anterosuperior separation from the deep fascia (Colles fascia) over the urogenital diaphragm. Vascular supply is from the posterior labial branches of the internal pudendal artery. Good results are also seen when inferior separation is undertaken and the external pudendal vessels are preserved. The graft is passed subcutaneously to cover a vaginal repair; this is particularly appropriate to provide additional bulk in a colpocleisis, and in urethral and bladder neck fistulas may help to maintain competence of closure mechanisms by reducing scarring (see Figure 31.17).
- Gracilis muscle passed either via the obturator foramen or subcutaneously is used as above (see Chapter 33).
- Omental pedicle grafts may be dissected from the greater curve of the stomach and rotated down into the pelvis on either the right or left gastroepiploic arteries; this may be used at any transperitoneal procedure, but has its greatest advantage in post-radiation fistulas (see Chapter 21).

- Peritoneal flap graft is an easier way of providing an additional layer at transperitoneal repair procedures, by taking a flap of peritoneum from any available surface, usually the paravesical area. The anterior vaginal wall is opened and after the fistula is closed as described earlier, a peritoneal flap is created by dissecting posteriorly along the anterior vaginal wall to expose the edge of peritoneum in the anterior cul-de-sac. The peritoneal edge may then be mobilized from the posterior bladder wall and the flap tacked over the site of fistula closure. Cure rates of 97% and 96% are reported when Martius graft and peritoneal flap interposition, respectively, are used in cases of complex and/or failed vesicovaginal fistula (Eilber et al., 2003), although the lack of high quality supporting evidence should be noted.

Anal and Rectovaginal Fistula Repair

Laying Open of Fistula Track

An anoperineal fistula may be treated by laying open the tract using a diathermy probe and curetting to remove granulation tissue. Where there is an intersphincteric tract, it is laid open to the uppermost level by dividing the internal sphincter. If there is transsphincteric extension on the under surface of puborectalis, then the perianal skin should be incised at the external opening using fistula scissors and the granulation tissue curetted along the line of the tract.

Rectal Advancement Flap

Rectal advancement flap is indicated in cases of high transsphincteric anal fistulae. An Eisenhammer retractor is placed in the anus. A broad-based inverted U-shaped flap comprising rectal mucosa and muscularis is fashioned and separated from the internal sphincter muscle within the anal canal. The internal opening of the fistula tract is excised within the base of the flap (Figure 31.25) and the tract opening into the internal sphincter is curetted. The external opening of the tract is laid open and curetted. The internal anal sphincter is repaired with interrupted polyglactin sutures. The flap is then held in the advanced position, and beginning at the base and working toward the apex it is sutured around the margins with interrupted polyglactin sutures so that it comes to overlie the sphincter closure and advances to the mucocutaneous margin (Figure 31.26). The inter- or transsphincteric portion is left open to drain.

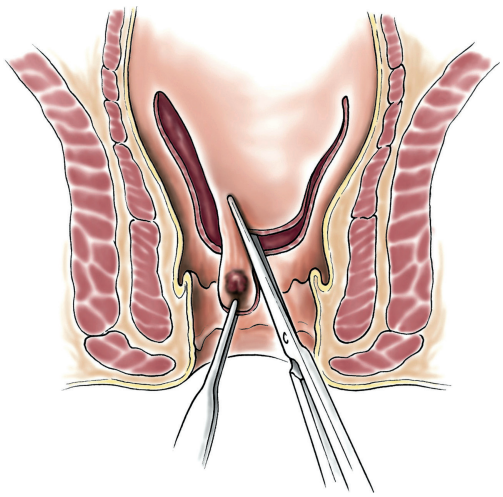

Figure 31.25 Rectal advancement flap. A flap of the whole thickness of rectal wall is fashioned, the internal opening excised, and the track curetted.

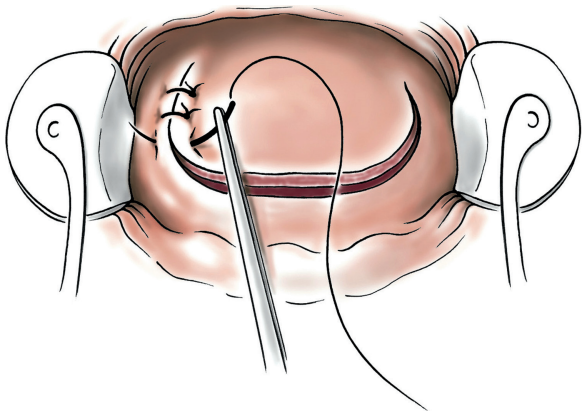

Figure 31.26 After mobilization of the flap and closing the defect in the internal sphincter, the flap is sutured in place with interrupted 2-0 polyglactin or polydioxanone sutures.

Transperineal

Conversion to Fourth-Degree Tear

Although dissection and repair in layers is appropriate for lesions higher in the vagina, most gynecologists when repairing fistula low in the vagina use the transperineal route and convert them into a "complete perineal tear" during the course of dissection. This technique is suitable for incompletely healed third- or fourth-degree obstetric perineal lacerations, although judgment needs to be used as to the appropriateness of sacrificing any remaining functioning sphincter muscle. The patient is positioned in the lithotomy position and the skin bridge incised with a scalpel. The fistula tract and perineal scar are then excised and the vagina and rectum (close to the fistula) are separated from prerectal fascia sufficiently to allow closure without tension and from the anal sphincters. The cut ends of the external sphincter should be identified and secured with stay sutures; if disrupted, the ends should be sought by dissection into the pararectal tissues. Only when all layers are clearly dissected and identified should the repair commence.

The rectal mucosa is closed with either continuous or interrupted suture using 3-0 polyglactin or polydioxanone, commencing above the limit of the dissection. The second layer. comprising muscularis (including the internal sphincter) and submucosa, is repaired with a series of Lembert sutures where the sutures do not enter the bowel lumen (Figure 31.27). An additional layer of sutures may be placed more superficially into the muscularis to help to create a zone of high pressure within the rectum, although simply reconstructing the prerectal fascia over the rectal repair as an alternative is entirely appropriate.

The external sphincter should then be repaired using 3-0 polydioxanone or Prolene sutures. While there is no convincing evidence that the overlap repair has advantage over the end-to-end repair in primary management of obstetric anal sphincter injury (Royal College of Obstetricians & Gynaecologists 2007),

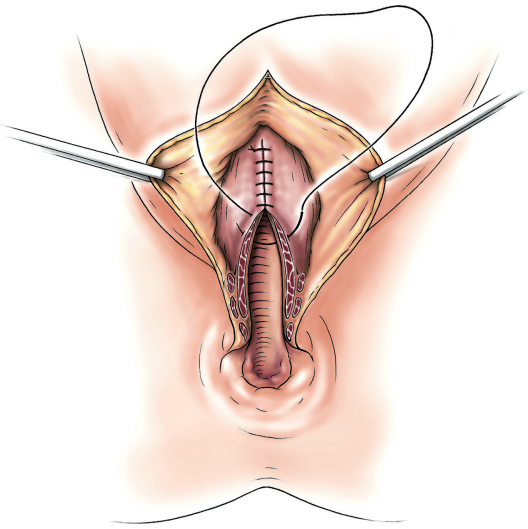

Figure 31.27 Repair of a low rectovaginal fistula. After the lesion has been converted into a "complete perineal tear," the tissues are widely mobilized. The rectal wall is closed using a continuous suture.

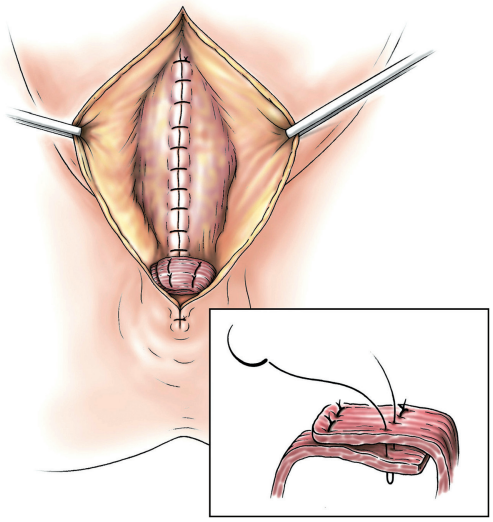

Figure 31.28 The "overlapping" technique of sphincter repair.

the latter has been found to be unsatisfactory in many cases of secondary repair, and the overlapping repair technique developed by Parks is perhaps particularly appropriate where there is sphincter deficiency in addition to the fistula (Parks and McPartlin 1971). The repair is accomplished by a series of interrupted sutures transfixing both layers of muscle, to achieve 2 cm overlap where possible (Figure 31.28). The superficial transverse perineal muscles are then reapproximated, and the vaginal wall is closed to the level of the hymenal ring, using continuous 2-0 polyglycolic acid. The perineal body may then be further built up using the medial fibers of the levator ani and bulbocavernosus muscles before the perineal skin is closed. If interposition grafting is thought to be necessary, the Martius graft is the most appropriate for use in low rectovaginal fistula repair.

Transverse Transperineal

This is another transperineal method used for low rectovaginal fistulas when it is important to preserve sphincteric function, such as in patients with Crohn's disease where it may be performed without the need for a defunctioning colostomy.

The patient is placed in the dorsal lithotomy position and the tissues are injected with 1:200,000 adrenaline. A transverse incision is made in the skin across the perineal body above the anal sphincter and the perineal skin is mobilized in a cephalad direction by sharp dissection and extended laterally and superiorly around the fistula between the anterior rectal wall and posterior vaginal wall. Scar tissue is then excised from the vaginal opening of the fistula and the vaginal mucosa repaired longitudinally in two layers with interrupted sutures. Scar tissue from the fistulous opening at the rectal end is then excised and the rectal wall repaired transversely with interrupted sutures to invert the rectal mucosa, followed by a second layer to imbricate and reinforce the first layer. The puborectalis muscle is then approximated in the midline with one or two interrupted sutures and the transverse perineii approximated with interrupted sutures. The skin is closed with interrupted sutures.

Transvaginal

This route offers the advantages of better access than the transanal route and avoidance of transection and repair of the anal sphincters, although it may be complicated by vaginal narrowing and subsequent dyspareunia. The patient is placed in the lithotomy position and the fistula is identified with a probe. Infiltration with 1:200,000 adrenaline is followed by circumferential incision of the fistula on the posterior vaginal wall, and the fistula tract is excised to the rectal mucosa. The vaginal mucosa is then separated from the underlying prerectal fascia with fistula scissors and the rectum closed with a series of interrupted polyglactin sutures to invert the fistulous opening into the rectal wall. The vaginal mucosa is then closed in the usual way. When the tissues are devitalized, such as in radiation fistulas, the repair may be combined with tissue interposition as described earlier.

Transanal

The transanal approach is favored by coloproctologists and is suitable for patients with low rectovaginal fistulas without fecal incontinence and with intact anal sphincters, although it may be combined with sphincteroplasty when there is sphincter involvement. It is not a suitable technique for radiation fistulas because of the lack of vascularized tissues. Dissection and repair in layers or rectal advancement flap, as described earlier, may be undertaken.

Advancement Rectal Sleeve Procedure

This is a more complex alternative to the transanal advancement flap, in which a circumferential incision is made from the mucocutaneous junction and extended circumferentially to the submucosa in a cephalad direction, to beyond the anorectal ring and supralevator space (Parks et al. 1978). The flap usually extends approximately 7 cm into the rectum, with the base at least 4 cm cephalad to the fistula, and is raised from the apex to the base with dissection commencing laterally and moving distally. The anterior rectal wall is then mobilized if necessary to the level of the peritoneal reflection and separated laterally from the submucosa and internal sphincter muscle so that it may be pulled down to the level of the dentate line without tension. The internal sphincter and submucosa are then approximated in the midline with interrupted polyglactin sutures. The rectal wall

flap is advanced over the repaired area and unhealthy anorectal mucosa with the site of the fistula is excised. The flap margins are attached with interrupted 3-0 polyglactin sutures.

Transabdominal

The transabdominal route is often chosen when the rectum is ulcerated or stenotic following radiation. At laparotomy the splenic flexure, left colon, sigmoid colon, and rectum are mobilized to the level of the levator hiatus and the diseased rectum is resected. A colonic reservoir is fashioned either as a J-pouch or as a coloplasty. In the frail or very elderly, colostomy may be the treatment of choice for radiation fistulas.

In patients with Crohn's disease affecting the rectum, proctectomy with colonic pull-through and delayed coloanal anastomosis may be the treatment of choice.

POSTOPERATIVE MANAGEMENT

Fluid Balance

Nursing care of patients who have undergone urogenital fistula repair is of critical importance, and obsessional postoperative management may do much to secure success (Hilton 1997). Poor nursing may easily undermine what has been achieved by the surgeon. Strict fluid balance must be kept, and an adequate daily fluid intake should be maintained until the urine is clear of blood. Hematuria is more persistent following abdominal surgery than vaginal procedures, and intravenous fluid is therefore likely to be required for longer in these patients.

Bladder Drainage

Continuous bladder drainage in the postoperative period is crucial to success, and nursing staff should check catheters hourly throughout each day to confirm free drainage and check output. Bladder irrigation and suction drainage are not recommended. Views differ as to the ideal type of catheter (Hilton 1988). The caliber must be sufficient to prevent blockage, although whether the suprapubic or urethral route is used is to a large extent a matter of individual preference. The author's usual practice is to use a "belt-and-braces [suspenders]" approach of both urethral and suprapubic drainage initially so that if one becomes blocked, free drainage is still maintained. The urethral catheter is removed first, and the suprapubic retained and used to assess residual volume, until the patient is voiding normally (Hilton 2012).

The duration of free drainage depends on the fistula type. Following repair of surgical fistulas, 12 days is adequate. With obstetric fistulas up to 21 days' drainage may be appropriate, and following repair of radiation fistulas 21 to 42 days are required. If there is any doubt about the integrity of the repair it is wise to carry out dye testing or cystography prior to catheter removal. Where a persistent leak is identified, free drainage should be maintained for 6 weeks.

Mobility and Thromboprophylaxis

The biggest problem in ensuring free catheter drainage lies in preventing kinking or drag on the catheter. Restricting patient mobility in the postoperative period helps with this, and some advocate continuous bed rest during the period of catheter drainage. If this approach is chosen, patients should be looked on as being at moderate to high risk for thromboembolism, and prophylaxis must be employed (see Chapters 1 and 2).

Antibiotics

Antibiotic cover is advised for all intestinovaginal fistula repairs. There is no evidence of benefit from prophylactic antibiotics in patients undergoing urogenital fistula repair, and only symptomatic infection needs be treated in the catheterized patient (Niel-Weise and van den Broek 2005).

Bowel Management

If patients are restricted to bed following urogenital fistula repair, a laxative should be administered to prevent excessive straining at stool. Following abdominal repair of an intestinovaginal fistula, patients should either have a nasogastric tube inserted or be restricted to nil by mouth until they are passing flatus; the majority prefer the latter approach. Once oral intake is allowed, or following vaginal repair of a rectovaginal fistula, a low-residue diet should be administered until at least the fifth postoperative day. Some authorities advocate total parenteral nutrition throughout the first week postoperatively for all intestinovaginal fistulas. Enemas and suppositories should be avoided, although a mild aperient such as dioctyl sodium (docusate sodium) is advised to ease initial bowel movements.

Subsequent Management

On removal of catheters most patients will feel the desire to void frequently, since the bladder capacity will be functionally reduced after being relatively empty for so long. In any case it is important that the bladder does not become overdistended, and hourly voiding should be encouraged and fluid intake limited. It may also be necessary to wake patients once or twice during the night for the same reason. After discharge from the hospital, patients should be advised to gradually increase the period between voiding, aiming to achieve a normal pattern by 4 weeks postoperatively. Tampons, pessaries, douching, and penetrative sex should be avoided until 3 months postoperatively.

REFERENCES

Badlani G, Sutton AP, Abram, HJ, et al. 1980. Enterovesical fistulas in Crohn disease. *Urology* **16**(6):599–600.

Ben-Ami H, Ginesin Y, Behar DM, et al. 2002. Diagnosis and treatment of urinary tract complications in Crohn's disease: An experience over 15 years. *Can J Gastroenterol* **16**(4):225–9.

Browning A. 2006. A new technique for the surgical management of urinary incontinence after obstetric fistula repair. *BJOG* **113**(4):475–8.

Carey MP, Goh JT, Fynes MM, et al. 2002. Stress urinary incontinence after delayed primary closure of genitourinary fistula: A technique for surgical management. *Am J Obstet Gynecol* **186**(5):948–53.

Chassar Moir J. 1967. *The Vesico-Vaginal Fistula.* London: Bailliere.

Chassar Moir J. 1973. Vesico-vaginal fistulae as seen in Britain. *BJOG* **80**(7):598–602.

Davits RJ, Miranda SI. 1991. Conservative treatment of vesicovaginal fistulas by bladder drainage alone. *Br J Urol* **68**(2):155–6.

de Ridder D, Hilton P, Mourad S, et al. 2013. Fistulae. In: Abrams P, Cardozo LD, Wein A, eds. *Incontinence – ICUD-EAU 5th International Consultation on Incontinence.* Geneva, Switzerland: EAU Publications, pp. 1527–79.

Dogra PN, Saini AK. 2011. Laser welding of vesicovaginal fistula—Outcome analysis and long-term outcome: Single-centre experience. *Int Urogynecol J Pelvic Floor Dysfunct* **22**(8):981–4.

Eilber KS, Kavaler E, Rodriguez LV, et al. 2003. Ten-year experience with transvaginal vesicovaginal fistula repair using tissue interposition. *J Urol* **169**(3):1033–6.

Giordano P, Drew PJ, Taylor D, et al. 1996. Vaginography—Investigation of choice for clinically suspected vaginal fistulas. *Dis Colon Rectum* **39**(5):568–72.

Goh J, Stanford EJ, Genadry R. 2009. Classification of female genito-urinary tract fistula: A comprehensive review. *Int Urogynecol J Pelvic Floor Dysfunct* **20**(5):605–10.

Gorrea A, Zuazu F, Sanchis MA, et al. 1985. Spontaneous healing of uretero-vesico-vaginal fistulas. *Eur Urol* **11**(5):341–3.

Guenaga KF, Matos D, Wille-Jorgensen P. 2011. Mechanical bowel preparation for elective colorectal surgery. *Cochrane Database Syst Rev* (**9**):CD001544.

Hamlin R, Nicholson E. 1969. Reconstruction of urethra totally destroyed in labour. *Br Med J* **2**(5650):147–50.

Hillary CJ, Osman NI, Hilton P, et al. 2016. The aetiology, treatment and outcome of urogenital fistulae managed in well- and low-resourced countries: A systematic review. *Eur Urol* **70**(3):478–92.

Hilton P. 1988. Bladder drainage: A survey of practices among gynaecologists in the British Isles. *BJOG* **95**(11):1178–89.

Hilton P. 1997. Debate: Post-operative urinary fistulae should be managed by gynaecologists in specialist centres. *Bri J Urol Suppl* **80**(1):35–42.

Hilton P. 1998. Urodynamic findings in patients with urogenital fistulae. *Brit J Urol* **81**(4):539–42.

Hilton P. 2003. Vesico-vaginal fistulas in developing countries. *Int J Gynaecol Obstet* **82**(3):285–95.

Hilton P. 2012. Urogenital fistula in the UK—A personal case series managed over 25 years. *BJU Int* **110**(1)**:**102−10.

Hilton P, Cromwell D. 2012. The risk of vesicovaginal and urethrovaginal fistula after hysterectomy performed in the English National Health Service—A retrospective cohort study examining patterns of care between 2000 and 2008. *BJOG* **119**(12):1447–54.

Hilton P, Ward A. 1998. Epidemiological and surgical aspects of urogenital fistulae: A review of 25 years experience in south-east Nigeria. *Int Urogynecol J Pelvic Floor Dysfunct* **9**(4):189−94.

Hudson CN. 1968. Malignant change in an obstetric vesicovaginal fistula. *Proc Roy Soc Med* **61**(12):1280–1.

Kelly J, Kwast B. 1993. Epidemiologic study of vesico-vaginal fistula in Ethiopia. *Int Urogynecol J* **4**:278–81.

Kiricuta I, Goldstein A. 1972. The repair of extensive vesicovaginal fistulas with pedicled omentum: A review of 27 cases. *J Urol* **108**:724–7.

Krause S, Hald T, Steven K. 1987. Surgery for urologic complications following radiotherapy for gynecologic cancer. *Scand J Urol Nephrol* **21**(2):115–8.

Lawson J. 1972. Vesical fistulae into the vaginal vault. *Br J Urol* **44**(6):623–31.

Lawson J. 1978. The management of genito-urinary fistulae. *Clin Obstet Gynaecol* **6**:209–36.

Lawson L, Hudson C. 1987. The management of vesico-vaginal and urethral fistulae. In: Stanton S, Tanagho E, eds. *Surgery for Female Urinary Incontinence.* Berlin: Springer-Verlag, pp. 193–209.

Lee RA, Symmonds RE, Williams TJ. 1988. Current status of genitourinary fistula. *Obstet Gynecol* **72**(3 Pt 1):313–9.

Miklos JR, Moore RD, Chinthakanan O. 2015. Laparoscopic and robotic-assisted vesicovaginal fistula repair: A systematic review of the literature. *J Minim Invasive Gynecol* **22**(5):727–36.

Morton HC, Hilton P. 2009. Urethral injury associated with minimally invasive mid-urethral sling procedures for the treatment of stress urinary incontinence: A case series and systematic literature search. *BJOG* **116**(8):1120–6.

Muleta M, Hamlin EC, Fantahun M, et al. 2008. Health and social problems encountered by treated and untreated obstetric fistula patients in rural Ethiopia. *J Obstet Gynaecol Can* **30**(1):44–50.

Muleta M, Rasmussen S, Kiserud T. 2010. Obstetric fistula in 14,928 Ethiopian women. *Acta Obstet Gynecol Scand* **89**(7):945–51.

Murphy M. 1981. Social consequences of vesico-vaginal fistula in northern Nigeria. *J Biosocial Sci* **13**(2):139–50.

Niel-Weise BS, van den Broek PJ. 2005. Antibiotic policies for short-term catheter bladder drainage in adults. *Cochrane Database Syst Rev* (**3**):CD005428.

Parks A, McPartlin J. 1971. Late repair of injuries of the anal sphincter. *Proc Roy Soc Med* **64**:1187–9.

Parks AG, Allen CL, Frank JD, et al. 1978. A method of treating post-irradiation rectovaginal fistulas. *Br J Surg* **65**(6):417–21.

Raghavaiah N. 1974. Double-dye test to diagnose various types of vaginal fistulas. *J Urol* **112**:811–2.

Royal College of Obstetricians & Gynaecologists. 2007. *The management of third and fourth degree perineal tears.* London: RCOG.

Shekarriz B, Stoller ML. 2002. The use of fibrin sealant in urology. *J Urol* **167**(3):1218–25.

Stoker J, Rociu E, Schouten WR, et al. 2002. Anovaginal and rectovaginal fistulas: Endoluminal sonography versus endoluminal MR imaging. *Am J Roentgenol* **178**(3):737–41.

Waaldijk K. 1994. The immediate surgical management of fresh obstetric fistulas with catheter and/or early closure. *Int J Gynaecol Obstet* **45**(1):11–6.

Waaldijk K. 1995. Surgical classification of obstetric fistulas. *Int J Gynaecol Obstet* **49**(2):161–3.

Waaldijk K. 1997. Immediate indwelling bladder catheterisation at postpartum urine leakage - personal experience of 1200 patients. *Tropical Doctor* **27**:227–8.

Waaldijk K. 2004. The immediate management of fresh obstetric fistulas. *Am J Obstet Gynecol* **191**(3):795–9.

Wagner M, Lefevre JH, Royer B, et al. 2011. Internal fistula leakage due to a road traffic accident: A fortuitous diagnosis of Crohn's disease. *J Crohns Colitis* **6**(5):603−5.

Woods RJ, Lavery IC, Fazio VW, et al. 1988. Internal fistulas in diverticular disease. *Dis Colon Rectum* **31**(8):591–6.

Yeates W. 1987. Uretero-vaginal fistulae. In: Stanton S, Tanagho E, eds. *Surgery for Female Urinary Incontinence.* 2nd ed. Berlin: Springer-Verlag, pp. 211–7.

Zacharin R. 1988. *Obstetric Fistula.* Vienna: Springer-Verlag.

32 Treatment of vascular defects and injuries

Karl A. Illig, Kenneth Ouriel, and Sean Hislop

INTRODUCTION

The pelvis and groin contain a complex web of blood vessels. Given the magnitude of resection often needed when treating pelvic malignancies, it is not uncommon to be faced with the need to address major vascular issues. These fall into three general categories: inadvertent injuries requiring repair, planned resection as part of tumor excision, requiring reconstruction, and use of inferior vena cava filters to reduce the risk of fatal pulmonary embolism.

Whenever major vascular hemorrhage is encountered, simple measures to initially control hemorrhage should be employed expeditiously. Initial attempts at repair may result in increasing the risk of further injury at the cost of significant blood loss. In general, apply direct pressure at the site of bleeding to control hemorrhage and consult a surgeon with experience in vascular reconstruction. Preservation of life should always take priority over preservation of blood flow to limbs.

INDICATIONS

The primary indication for vascular repair is of course a vascular injury. Major blood vessels may at times need to be resected along with the specimen as part of an en bloc extirpation. Not every defect requires reconstruction, however.

The aorta, common iliac, and external iliac arteries form the blood supply to the legs, and must always be reconstructed if the limb is to remain viable. If direct reconstruction is not possible, an "extra-anatomic" (femoral–femoral or axillary–femoral) bypass may be constructed to preserve limb blood flow. Venous bleeding can be much more serious than arterial bleeding, primarily because the thin walls and prodigious tributaries make control and repair difficult. Collateral drainage, also, is rich. These two concepts suggest that virtually any vein can be ligated if absolutely necessary. At times a venous reconstruction will be required, but urgency is less than after ligation of arterial structures.

ANATOMIC CONSIDERATIONS

The two hypogastric (internal iliac) arteries and the inferior mesenteric artery (IMA) supply blood to the pelvis, including the buttocks, left colon, and terminal spinal cord. It is a near-absolute requirement that at least one of these three vessels be preserved. The IMA is frequently the least important source of pelvic blood flow; every effort should be made, however, to preserve at least one hypogastric artery. Be aware of the impact of vascular disease and previous vascular or colorectal surgery on the vascular patency and anatomy of the colon and pelvis, as these factors may indicate a need for reconstruction. Within these guidelines, essentially any other vessel can be ligated with impunity.

The anatomy of the lower abdomen, pelvis, and groin vasculature is illustrated in Figures 32.1 and 32.2. Remember that arteries are thick-walled, resistant to tearing, and easier to repair than veins. Veins, by contrast, are thin-walled, do not hold their shape, and tear easily.

The veins tend to lie behind arteries (Figure 32.3). This is critically important at the region of the aortic bifurcation and proximal iliac arteries, where dissection behind these arteries (circled area) or within the aortic bifurcation can easily precipitate massive, life-threatening venous hemorrhage.

In general, trying to control an injury directly is counterproductive. For arterial injuries, proximal and distal control at sites remote from the bleeding source are required (Figure 32.4). Direct clamping can sometimes be problematic; for example, in the hypogastric arteries or in patients with significant atherosclerotic disease. In these cases, control can be accomplished by intraluminal balloon catheter occlusion. For venous injuries, direct pressure or packing while the situation is sorted out is much more useful than trying to see the injury or control it with a clamp. Direct manipulation with rigid instruments will often extend the tear or worsen the situation.

For vessel repair, autologous tissue is usually preferred (especially in a potentially infected field), although this "rule" must often be violated. An option in unfavorable situations is to route a graft through an unviolated, "extra-anatomic" plane. If vessel resection is planned or possible, include a source of autogenous vein (e.g., a leg, circumferentially prepared) in the surgical field (Figure 32.5).

The best procedure to follow in any unplanned vascular injury is first to control the bleeding with direct pressure; this may be accomplished with a finger or by packing with a sponge. Once bleeding is controlled, get help (in terms of both additional staff and specialist advice, when needed) and formulate a plan before anything further is done.

ARTERIAL CONTROL AND REPAIR

When dealing with an arterial injury or planned resection and repair, proximal and distal control are vitally important—this point cannot be overemphasized. In general, circumferential dissection of the aorta and common iliac arteries is counterproductive due to the risk of venous injury; dissection limited to the sides is usually sufficient. If the aorta is to be clamped, dissection should be carried down to the spine. In arterial surgery, a dissection plane directly on the adventitia is easiest and safest (Figure 32.6). Systemic heparin (125 units/kg) should be administered before clamping if bleeding is not diffuse; anticoagulation is reversed after arterial blood flow is re-established with protamine sulfate (1 mg per 100 units of heparin administered).

The ureter passes over the iliac bifurcation (Figure 32.7), making continuous exposure of the top of the iliac vessels problematic. Small lacerations of the major vessels, especially if oriented transversely to the vessel axis, can be readily repaired using

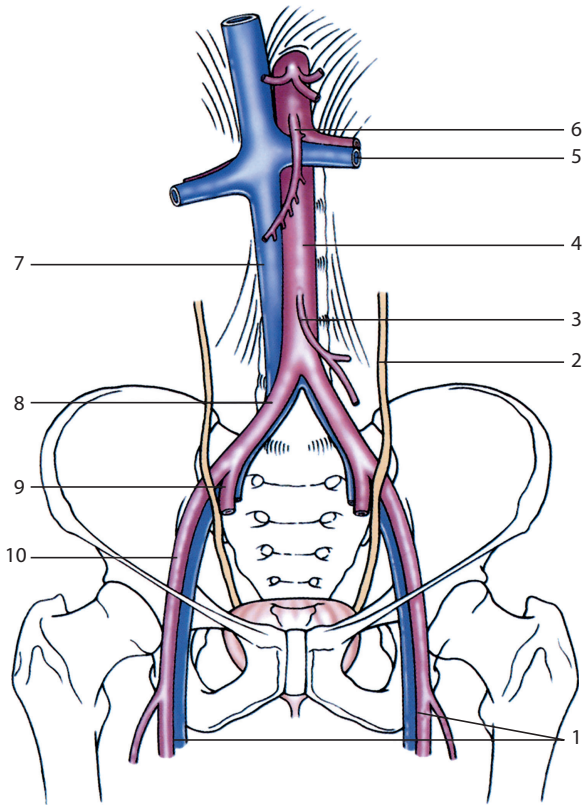

Figure 32.1 Abdominal and pelvic vasculature. 1: Femoral artery and vein; 2: ureter artery; 3: inferior mesenteric artery; 4: aorta; 5: renal artery and vein; 6: superior mesenteric; 7: inferior vena cava; 8: common iliac artery and vein; 9: internal iliac artery and vein; 10: external iliac artery and vein.

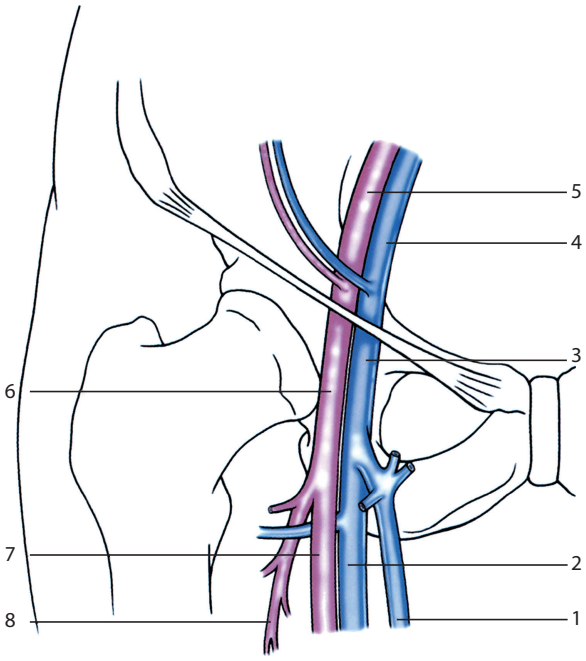

Figure 32.2 Vasculature of the groin. 1: Saphenous vein; 2: superficial femoral vein; 3: common femoral vein; 4: external iliac vein; 5: external iliac artery; 6: common femoral artery; 7: superficial femoral artery; 8: deep femoral artery (profunda).

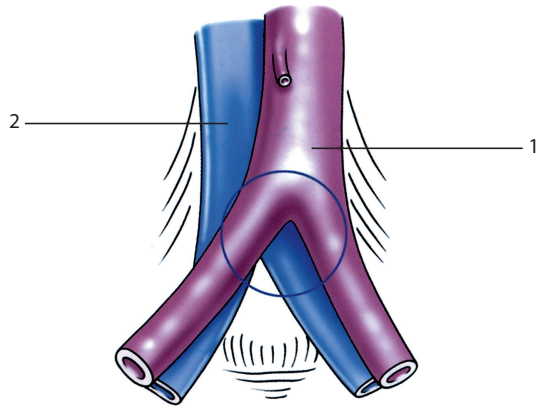

Figure 32.3 Aortic bifurcation—a danger area (circled). 1: Aorta; 2: vena cava.

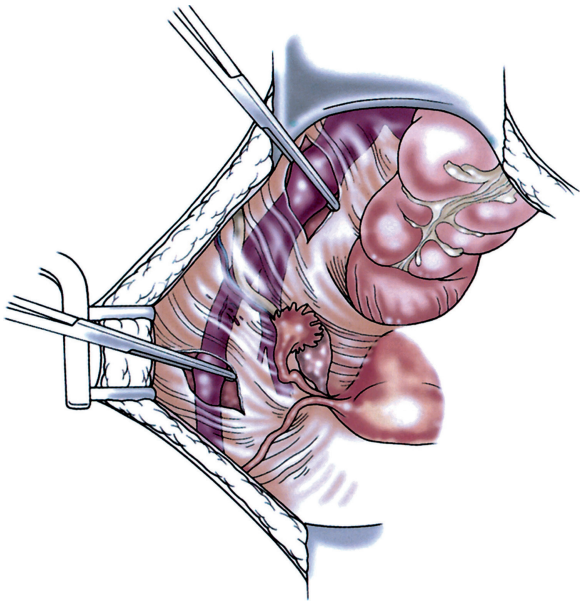

Figure 32.4 Control at sites remote from the bleeding is essential for arterial injuries.

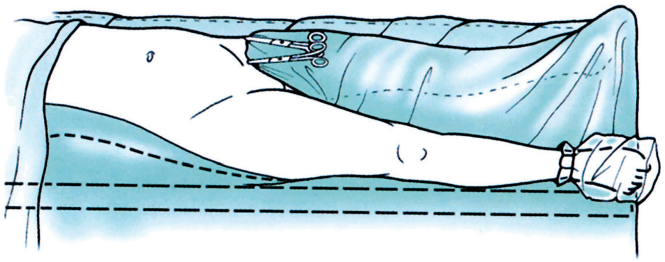

Figure 32.5 Draping to gain access for saphenous vein harvest.

monofilament, nonabsorbable suture (3-0 or 4-0 for aorta, 5-0 for iliac arteries). When the artery is diseased, the needle should be passed from inside to outside on the distal vessel wall to avoid dislodging intraluminal plaque or raising a distal intraluminal flap that could cause a dissection. All knots should be extraluminal (Figure 32.8). Direct repair of longitudinal injuries in the

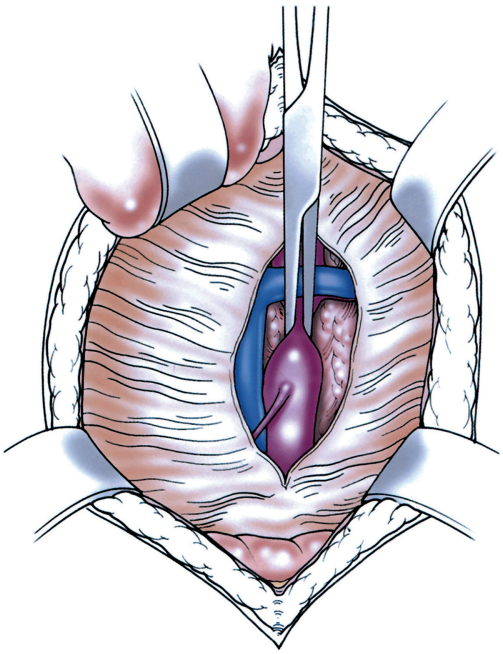

Figure 32.6 Exposure of the infrarenal aorta (duodenum is retracted laterally and superiorly). Note that the aorta itself is well cleared.

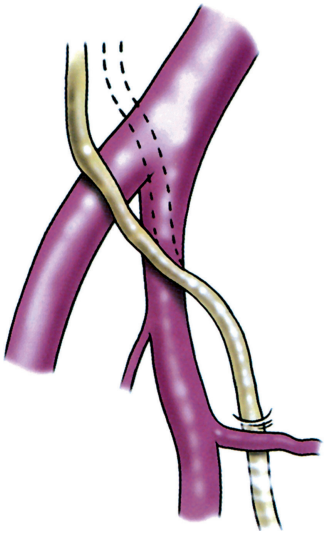

Figure 32.7 Ureter and the iliac bifurcation.

iliac (or smaller) vessels will usually narrow the lumen, so patch repair is preferred (Figures 32.9 and 32.10).

Any defect involving a large amount of tissue loss, especially encompassing the entire circumference of a vessel, will usually require an interposition vein or prosthetic graft. In a minority of these situations a primary repair may be possible, however only in cases where the vessel can be generously mobilized to provide a tension-free repair. These techniques are beyond the scope of this discussion, and a surgeon familiar with vascular reconstructive techniques should be consulted to assist in the repair of such defects.

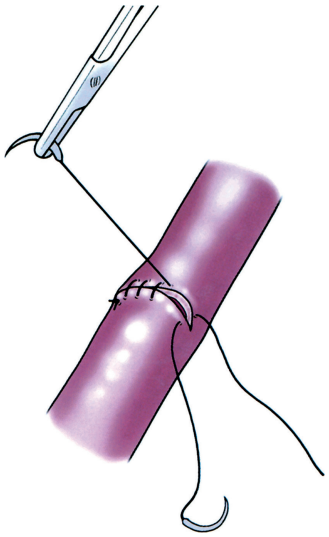

Figure 32.8 Suture technique for closure of a transverse arteriotomy.

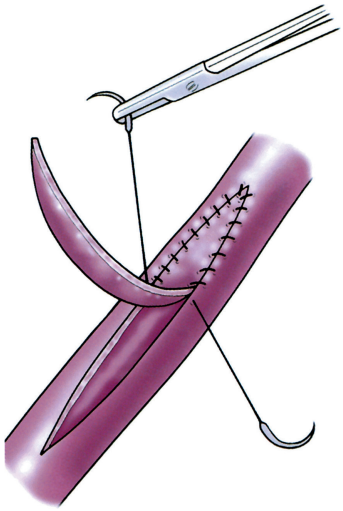

Figure 32.9 Initial stages of longitudinal arteriotomy: patch closure.

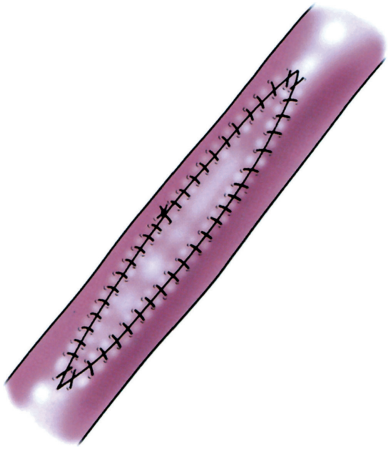

Figure 32.10 Completed closure.

VENOUS CONTROL AND REPAIR

Major venous injuries, somewhat paradoxically, can be more life-threatening than arterial defects. Veins are thin-walled, do not hold their shape, and are often less accessible. When faced with a major venous injury (dark, non-pulsatile bleeding), the first step is to apply gentle pressure. The temptation to control the injury with forceps or a clamp, even if the tear is apparently visible, should be resisted; doing so will often extend the tear and often convert a remediable situation into one that is very serious indeed. Several options are available. First, pressure itself will often solve the problem; if you are fortunate, resist the temptation to fiddle any further! Don't look, don't dissect, just accept your good fortune, and move on. Second, pressure proximally and distally, without any dissection (e.g., digitally or with sponge-sticks) can control the bleeding enough to make the defect visible. Third, blind suturing is sometimes acceptable if no critical structures (such as the ureter) are near. Finally, ligation is usually safe and well tolerated, especially if the patient's life is at risk.

In these situations, obtaining help, in terms of both experienced assistants to provide exposure and vascular surgical assistance, is of utmost importance, as is gaining control of the hemorrhage without any further damage so that a plan may be formulated and carried out.

VASCULAR PATCHES

Most longitudinal defects, even if no tissue is resected, will result in a narrowed lumen if repaired primarily. Thus, patch angioplasty is required for repair of most longitudinal defects in the iliac and smaller vessels.

Autologous tissue is preferred, especially in the presence of a potentially infected field. The greater saphenous vein is an excellent choice, as is the hypogastric artery. It is important that the endothelial surface should be oriented luminally. If, in a clean field, autologous tissue is not available, Dacron or polytetrafluoroethylene can be used. Fine monofilament nonabsorbable double-armed suture material on a non-cutting needle is used. Suturing begins at one corner of the defect, being careful to drive sutures from the inside to the outside on the native vessel. Exposure is best achieved by starting at one end and placing the first two or three stitches on either side of the corner in a "parachute" fashion before bringing the patch in contact with the vessel (Figure 32.9). The first "heel" suture should be mattressed at the corner so that the needle always passes from inside to outside the native artery (outside to inside on the patch). The suture is then continued around the patch and the knot tied along the long end of the patch (Figure 32.10).

INFERIOR VENA CAVA FILTERS

Malignancy is a well-known risk factor for venous thromboembolism (VTE, a collective term for deep venous thrombosis [DVT] and pulmonary embolism [PE]) and occurs in up to 15% of women with cancer. Half of all VTEs that occur in surgical patients occur in the operating room. VTE accounts for almost one-half of all postoperative deaths among women undergoing surgery for gynecological malignancy.

Inferior vena cava (IVC) filters are placed for the prevention of a fatal pulmonary embolism and work by mechanically preventing the embolism of large lower extremity clots capable of causing hemodynamically significant cardiopulmonary events. They have been shown to decrease the short-term incidence of PE from 5% to 1% in patients with a proximal venous thrombus. Indications for placement of an IVC filter in women with gynecological cancer and a diagnosis of VTE include:

1. Surgery as a primary treatment for cancer
2. Surgery as a delayed procedure as part of a definitive treatment (i.e., those undergoing neoadjuvant chemotherapy)
3. Contraindication to anticoagulation such as acute hemorrhagic anemia or recent hemorrhagic stroke
4. VTE despite appropriate therapeutic anticoagulation
5. Proximal (iliac or IVC) thrombosis in a patient with decreased cardiopulmonary reserve who is unlikely to tolerate an embolic event
6. Complication of anticoagulation which prevents further anticoagulation such as significant bleeding

IVC filters come in many shapes and delivery system sizes and have been refined to a point where they are smaller (6 French) than the typical introducer sheath (9 French) used for IV resuscitation. They can be placed safely through either the femoral of internal jugular veins and are deployed in the IVC just below the renal veins (Figure 32.11). IVC filters are placed under local anesthesia, similar to the placement of a central venous catheter. It takes approximately 10 to 15 minutes for a vascular surgeon to perform the procedure under fluoroscopic guidance. In patients too moribund to be moved, IVC filters can be placed safely by a vascular surgeon at the bedside under intravascular ultrasound guidance.



Figure 32.11 Inferior vena cava filter placed below the renal veins.

BIBLIOGRAPHY

Adib T, Belli A, McCall J, et al. 2008. The use of inferior vena caval filters prior to major surgery in women with gynaecological cancer. *BJOG* **115**:902–7.

Ouriel K, Rutherford RB. 1998. *Atlas of Vascular Surgery: Operative Procedure*. Philadelphia: WB Saunders.

Riles T. 2014. General Principles of Vascular Surgery. In: Chaikof EL, Cambria RP, eds. *Atlas of Vascular Surgery and Endovascular Therapy*. Philadelpha: Elsevier/Saunders, pp. 2–16.

Rutherford RS. 1993. *Atlas of Vascular Surgery: Basic Techniques and Exposures*. Philadelphia: WB Saunders.

33 Plastic reconstructive procedures

Andrea L. Pusic, Richard R. Barakat, and Peter G. Cordeiro

INTRODUCTION

Surgical cure demands adequate disease-free margins. Since large debulking procedures are often necessary, reconstructive techniques are required to restore anatomy and promote uncomplicated healing. Regional flaps are the most commonly used and effective of procedures. Flap selection is based on the type of defect and patient characteristics. The pudendal thigh flap is relatively simple and has the distinction of being at least partially sensate. The rectus abdominis muscle flap is a very versatile flap, useful in covering many defects. It is highly reliable, with a consistent vascular supply and muscular development. The gracilis flap has been popular for many years for vaginal reconstruction, but it is somewhat less reliable.

ANATOMIC CONSIDERATIONS

Vascular Supply

Skin vascularization may be direct or indirect. Direct vessels travel between muscles and along fascial planes to enter the skin. Indirect vessels arise from named vessels as perforators of the fascia from the underlying muscle. Regional flaps (e.g., gracilis flap) require a well-defined vascular pedicle to support the indirect blood supply to the overlying skin. Certain muscles used for flaps have a single dominant vascular pedicle (e.g., epigastric vessels for the rectus abdominis) or one dominant vascular pedicle with several minor ones (e.g., the medial femoral circumflex or femoral artery for the gracilis muscle). The pudendal thigh flap derives its blood supply mostly from the posterior labial vessels and the anastomotic channels involving the medial femoral circumflex and the obturator arteries. Knowledge of the vascular anatomy will allow better planning of the available territories for covering defects.

Nerve Supply

No major nerve should be encountered during these reconstructive procedures. Although the gracilis muscle is innervated by a branch of the obturator nerve, it is usually not identified as a distinct structure. As with all surgical procedures, some loss of sensation will be encountered in the operative field. Because reconstructive surgery involves the retention of a large skin island after it is severed from its nerve supply (e.g., the rectus flap), the patient may be more aware of this deficiency than after non-reconstructive surgery. With use of either the pudendal thigh flap or gracilis flap, a partially sensate reconstruction may be achieved.

Muscles Involved

The rectus abdominis muscle inserts in the pubic tubercle and arises from the sixth, seventh, and eighth ribs. It plays a role in protecting the abdominal contents, breathing, and defecating, and stabilizes the pelvis during walking. The gracilis muscle arises from the pubic tubercle and inserts onto the medial tibia pes anserinus. It helps to stabilize the knee and laterally rotates the thigh. Loss of these muscles is usually compensated for by the remaining muscles in their functional group so that no significant motor defect remains.

Bony Landmarks

A line drawn from the pubic symphysis to the medial epicondyle should approximate the anterior border of the gracilis muscle.

INDICATIONS

Vaginal defects may be classified based on their location and size (Figure 33.1). The type of defect determines the most appropriate flap choice. Small defects may be amenable to primary or advancement flap closure while more significant defects will require regional flaps. Defects are either partial (type I) or circumferential (type II). Type I, or partial, defects can be further classified based on whether they involve the anterolateral or posterior walls of the vagina. Type II, or circumferential, defects involve either the upper two-thirds of the vagina or the entire vaginal cylinder (Figure 33.2).

Partial defects involving the anterior or lateral vaginal walls (type IA) may be reconstructed with pudendal fasciocutaneous flaps. Unilateral or bilateral flaps can be used. Partial defects involving the posterior wall (type IB) will benefit from use of the rectus flap. This flap will supply bulk to close dead space in the posterior pelvis. It will also provide sufficient skin to resurface the posterior vaginal wall. Circumferential defects of the upper two-thirds of the vagina (type IIA) are also best reconstructed with the rectus flap. The flap may be "tubed" to create a cap that can be sutured to the remaining vaginal cuff. Circumferential total defects (type IIB) are generally reconstructed with bilateral gracilis flaps. Such defects commonly result from total pelvic exenteration. The large surface area of the gracilis flaps facilitate restoration of the vaginal cylinder while also providing sufficient volume to fill the pelvis and promote healing.

SURGICAL PROCEDURE

Full-Thickness Cutaneous Advancement Flaps

Cutaneous advancement flaps (V-Y procedure, Z-plasty) are useful for closure of small wounds, where mobilization of adjacent skin and subcutaneous tissue can reduce tension and allow adequate skin approximation. Such flaps should not be used for larger defects. Skin islands of varying sizes and shapes can be created adjacent to the defect as long as the patient has a good microvasculature (Figure 33.3). Advancement flaps should be used with great caution in irradiated tissue. The skin and subcutaneous tissue are mobilized from the underlying fascia of the transverse perineal muscle (Figure 33.4). The size of the flap is tailored to the size of the defect. The flap is undermined and in

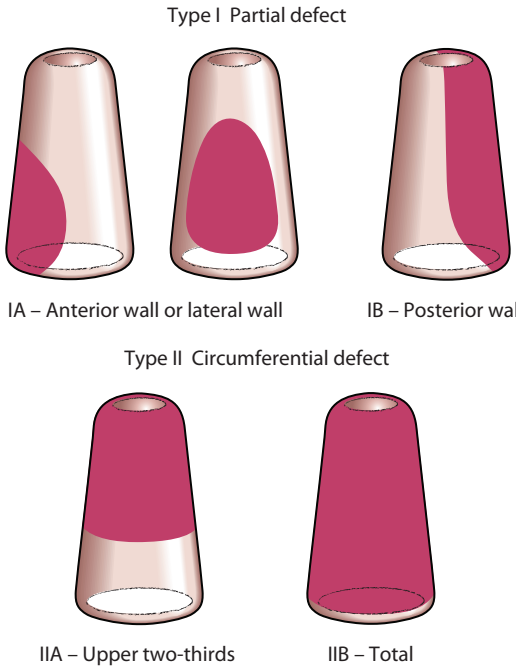

Figure 33.1 Classification of acquired vaginal defects. Defects are either partial (type I) or circumferential (type II).

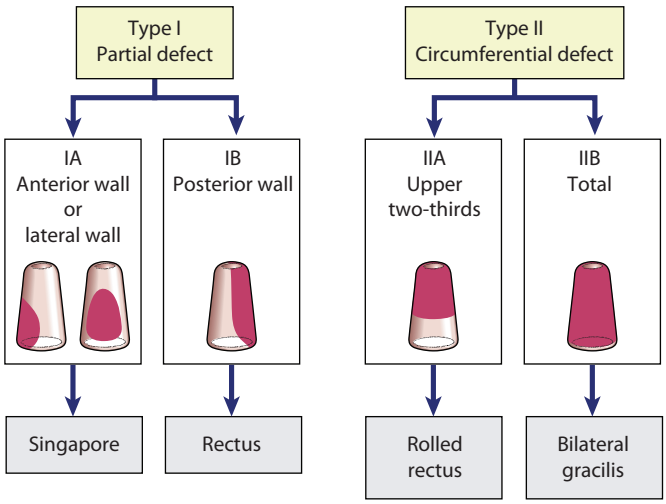

Figure 33.2 Algorithm for reconstruction of the vagina based on defect type I.

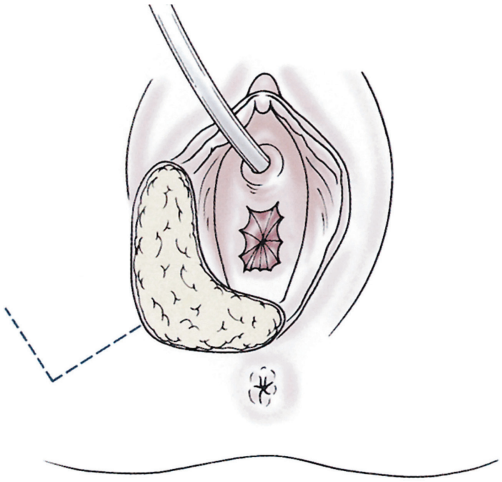

Figure 33.3 Z-plasty.

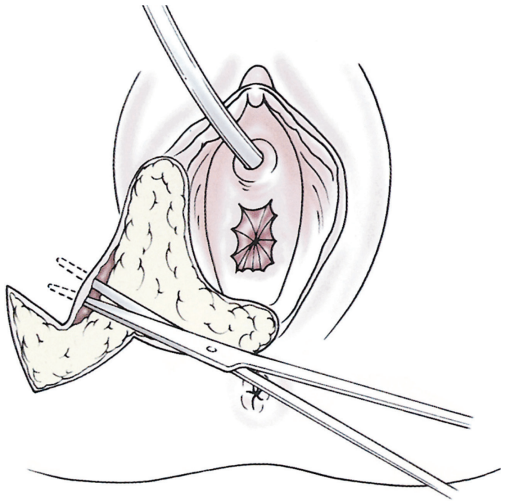

Figure 33.4 Z-plasty mobilization.

a Z-plasty is rotated through 90° to fill the defect (Figure 33.5). Once the flap is rotated, the remaining skin edges are united (Figure 33.6).

In a V-Y procedure the initial wedge (Figure 33.7) is advanced to fill the gap and then closed as a Y (Figure 33.8). Prolene 4-0 sutures should be used for these closures; Vicryl Rapide 3/0 sutures can also be utilized.

Occasionally if a patient has a very short vagina and has not been exposed to radiotherapy, a Williams vaginoplasty can achieve an extra 4 to 5 cm of vaginal length. This involves a "U"-shaped incision distal to the introitus on the inside of the labia minora. The two layers are then separated and the inner layers are sutured together, followed by the outer layers. This creates a pouch, while the vagina has an angle within it. Satisfactory results are reported with respect to sexual function, the penis in fact providing greater friction to the clitoral area with this anatomical arrangement.

The Rectus Abdominis Flap

The flap is dissected with the patient supine or in the lithotomy position. Skin islands may be designed in a wide variety of

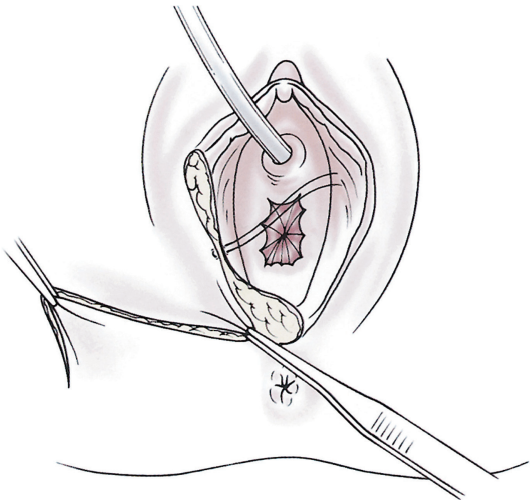

Figure 33.5 Ninety percent rotation of flap.

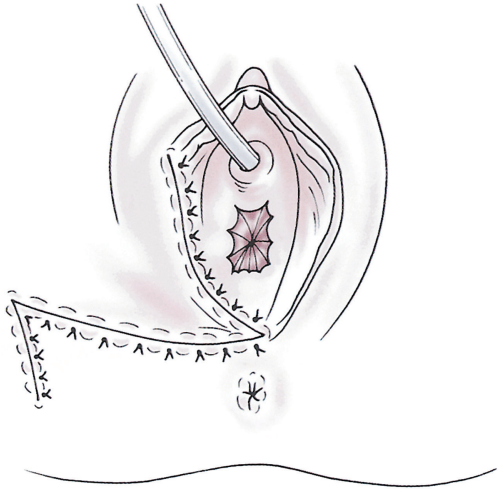

Figure 33.6 End result.

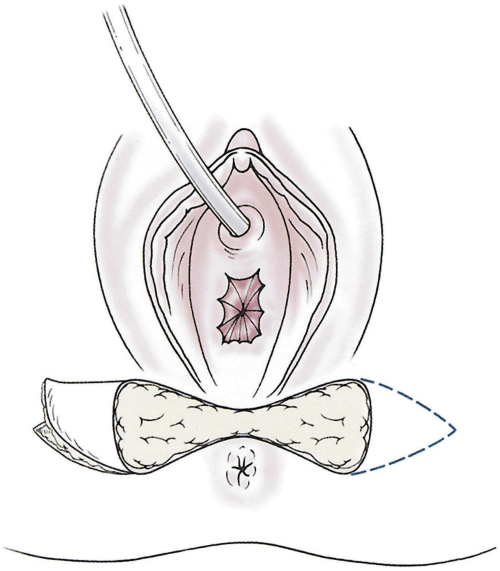

Figure 33.7 V-Y procedure.

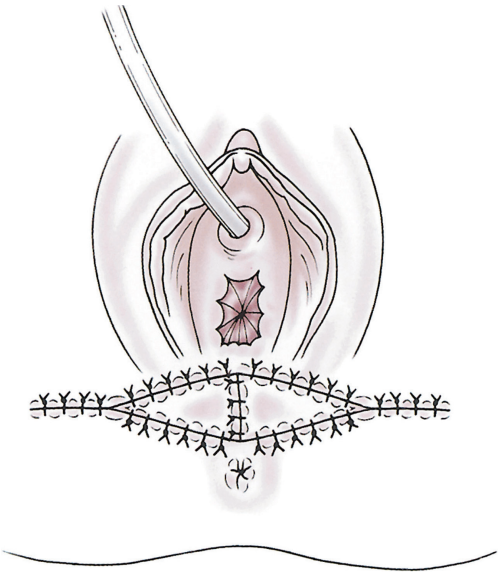

Figure 33.8 End result.

shapes and orientations as long as a significant portion of the skin and subcutaneous tissues is centered over the muscle.

In most cases, an elliptical skin island is oriented vertically over the muscle (Figure 33.9). For vaginal reconstruction, a more transversely oriented skin island may be designed above or below the level of the umbilicus, depending on the placement of ostomy sites. The skin islands should approximate the dimensions of the defect to be covered.

The skin incision is carried down to the level of the anterior rectus sheath; subcutaneous tissue and skin are then elevated off the sheath to allow an incision through the fascia to be made 1 cm from the lateral edge of the muscle. The dissection is then carried around the anterior and lateral surfaces of the muscle to the posterior surface. Care is taken to minimize injury to the tendinous intersections while mobilizing the muscle. The muscle can be divided above the level of the costal margin if needed. The muscle is then dissected away from the abdominal wall in a distal-to-proximal direction along the posterior rectus sheath toward the inferior epigastric pedicle. Several large intercostal perforators are ligated laterally and the deep inferior epigastric pedicle (artery and two venae comitantes) is then identified and dissected out of its origin from the iliac vessels (Figure 33.10). The insertion of the muscle into the pubic symphysis can be left intact or detached, depending on the arc of rotation that is required. For vaginal reconstruction, the skin island can be tubed and shaped into a pouch. It is then sutured to the remaining vaginal cuff from above. If perineal coverage is necessary, the flap can be tunneled in the subcutaneous plane over the inguinal ligament into the perineum or groin as needed (Figure 33.11). The donor site is closed primarily by approximating the remaining 1-cm cuff of anterior rectus sheath to itself with a

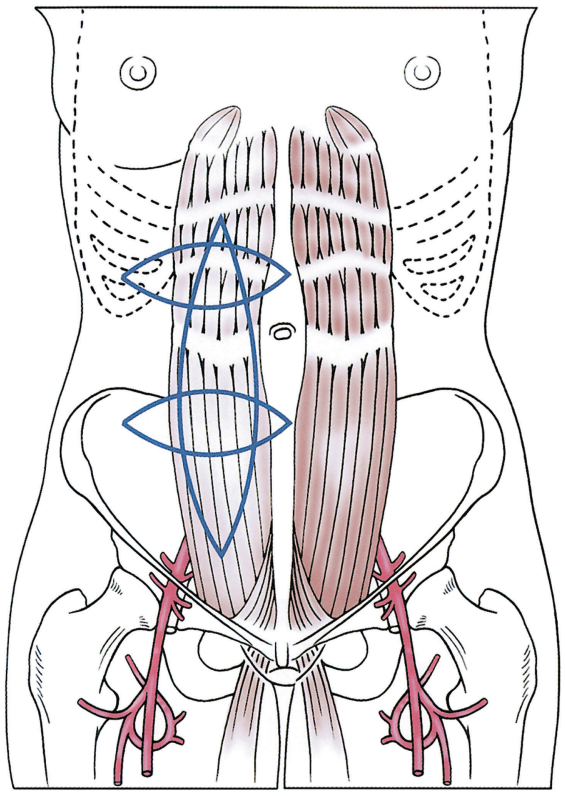

Figure 33.9 Possible elliptical skin islands.

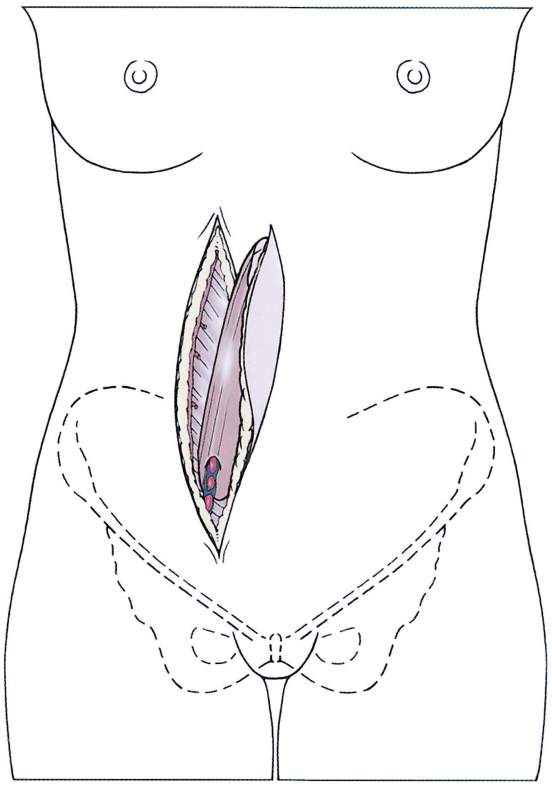

Figure 33.10 Rectus abdominis myocutaneous flap elevated. Note the inferior epigastric pedicle entering the caudal aspect of the flap.

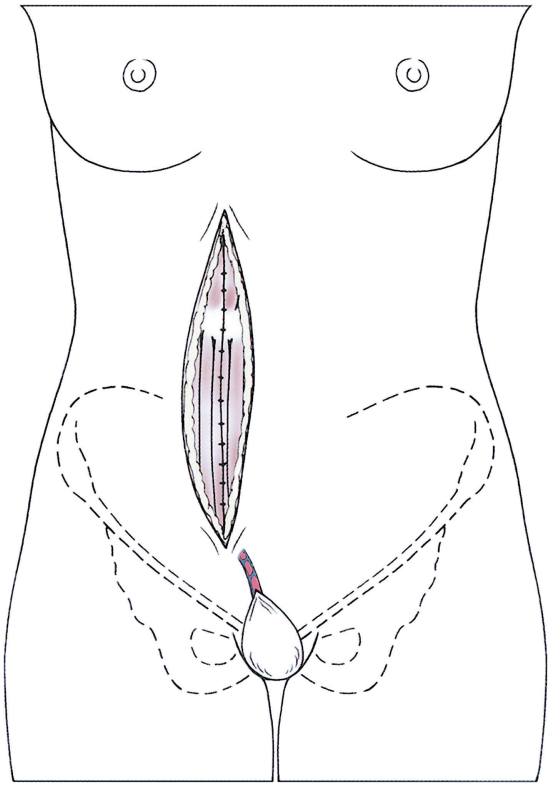

Figure 33.11 The anterior rectus fascia is approximated.

large nonabsorbable suture. If necessary, skin and subcutaneous tissue flaps can be mobilized to reapproximate the skin flaps in the abdominal donor site.

The Gracilis Flap

The patient is usually placed in the lithotomy position for resections in this area. The hips are flexed and abducted. The medial thigh is prepared circumferentially down to the knee, allowing access to the medial group of muscles. Figure 33.12 shows the underlying anatomy.

An elliptical skin island measuring up to 6 cm × 20 cm is outlined over the proximal two-thirds of the muscle (Figure 33.13). The anterior border of the incision lies on a line drawn between the pubic tubercle and the semitendinosus tendon. A separate, small access incision may be made distally if needed to identify the muscle tendon.

The skin is incised anteriorly down to the medial group of muscles. The sartorius muscle is identified and retracted superiorly. The gracilis tendon can now be identified distally, usually through a separate short distal incision, and the tendinous insertion divided (Figure 33.14). The posterior incision is made down to the muscle, taking care not to undermine perforators from the muscle to the skin or to shear the cutaneous aspect of the flap off the muscle. The flap is then elevated from distal to proximal on the thigh. One or two large perforators to the muscle

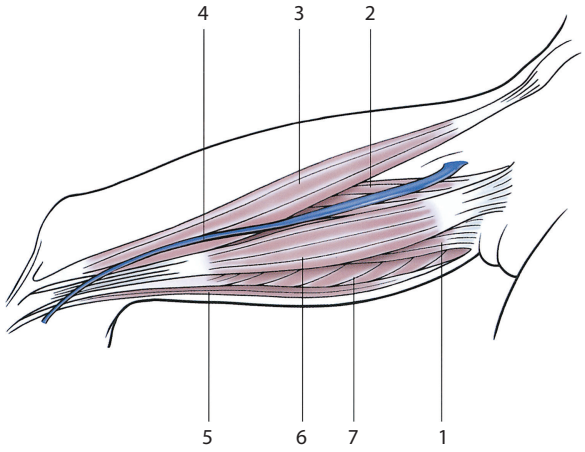

Figure 33.12 Underlying anatomy of medial thigh. 1: Adductor magnus muscle; 2: adductor longus muscle; 3: sartorius muscle; 4: greater saphenous vein; 5: semitendinosus muscle; 6: gracilis muscle; 7: semimembranosus muscle.

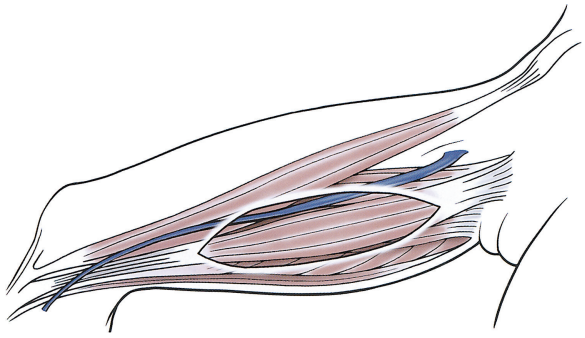

Figure 33.13 Outline of skin island over proximal two thirds of gracilis muscle.

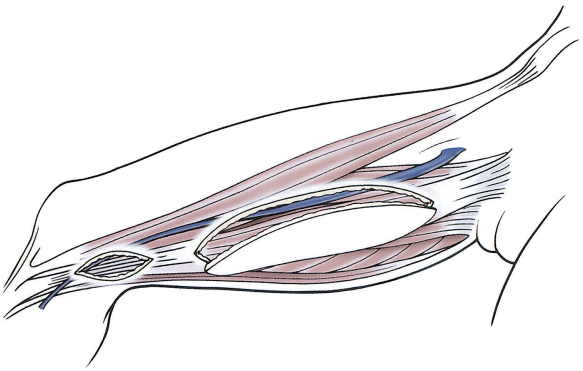

Figure 33.14 Skin and cutaneous skin island incised and distal gracilis muscle identified near knee.

are ligated distally. The main pedicle is identified entering the proximal third of the gracilis muscle in the space between the adductor longus and adductor magnus muscles (Figure 33.15), approximately 8 to 10 cm below the pubic tubercle. Once the pedicle is identified and preserved, the proximal muscle can be dissected and, if necessary, the origin from the pubic symphysis may be divided. The entire myocutaneous flap can then be tunneled through the subcutaneous skin bridge into the vaginal defect (Figure 33.16) and exteriorized through the introitus (Figure 33.17). The bilateral flaps are sutured to each other in the midline (Figure 33.18). The neovagina is shaped into a pouch by approximating the anterior, posterior, and distal skin

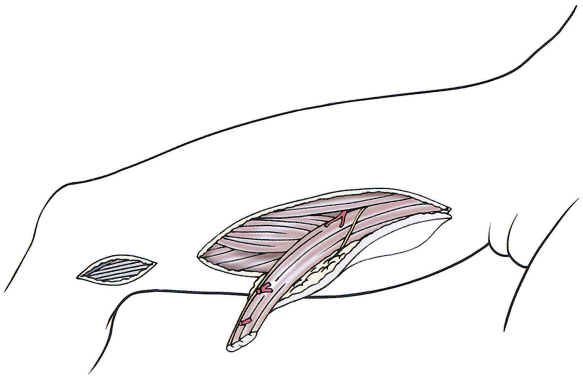

Figure 33.15 Myocutaneous flap elevated. Note neurovascular pedicle entering into proximal third of muscle.

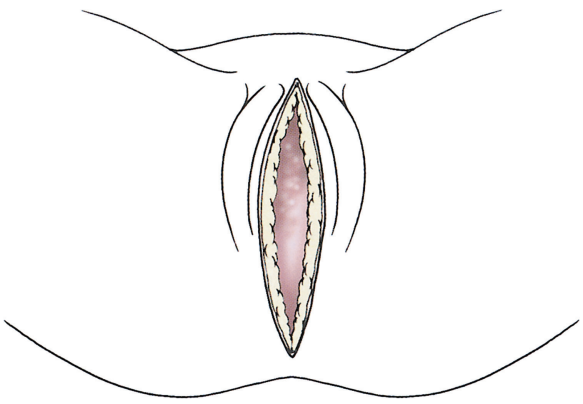

Figure 33.16 Typical defect in perineum after total pelvic exenteration.

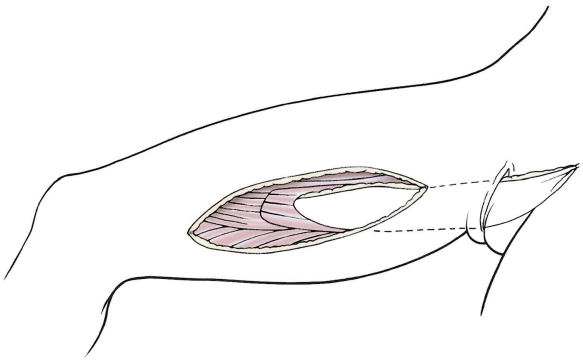

Figure 33.17 Myocutaneous flap exteriorized through the introitus.

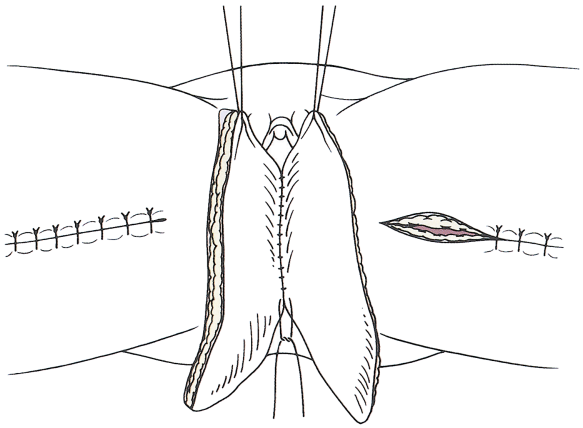

Figure 33.18 Bilateral gracilis myocutaneous flaps sewn together.

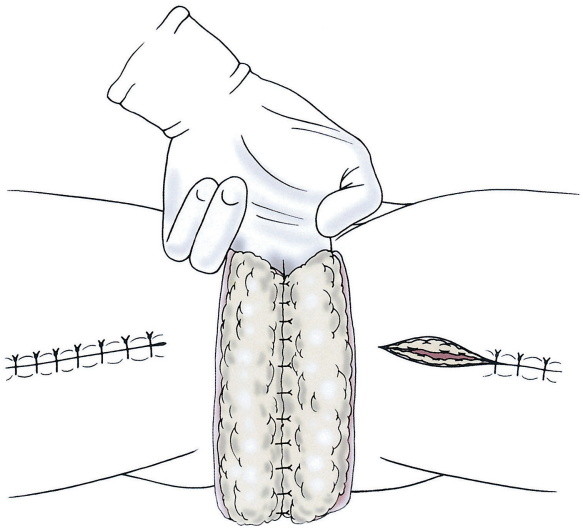

Figure 33.19 Bilateral flaps shaped into a pouch.

edges of the flaps (Figure 33.19); this can then be inserted into the pelvic space that is left after the exenteration. The proximal end of the neovagina is sutured to the introitus (Figure 33.20).

Fasciocutaneous Neurovascular Pudendal Thigh Flaps

The fasciocutaneous flap is based on the posterior labial arteries, which are a continuation of the perineal artery. The posterior

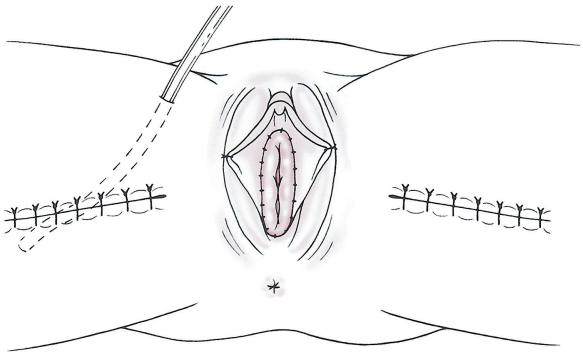

Figure 33.20 Neovaginal pouch inserted into pelvic space and sutured to the introitus.

aspect of this flap is innervated by the posterior labial branches of the pudendal nerve and the perineal branches of the posterior cutaneous nerve of the thigh.

The patient is placed in the lithotomy position. A flap 3 to 6 cm wide and 10 to 15 cm long can be designed within the medial groin crease just lateral to the labia majora and the defect. Bilateral flaps can be designed for large posterior wall defects. The perineal defect is partially closed anteriorly and posteriorly, leaving an entrance of suitable size into which the neovagina will be inserted (Figure 33.21).

The skin and subcutaneous tissues are incised as well as the deep fascia overlying the muscles of the medial thigh compartment as they insert onto the pubis and ischium (Figure 33.22).

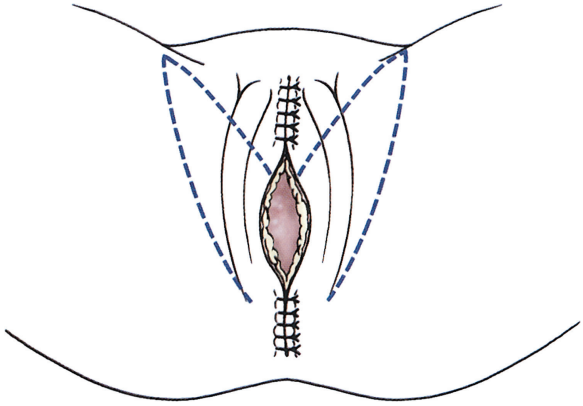

Figure 33.21 Partial anterior and posterior defect repair.

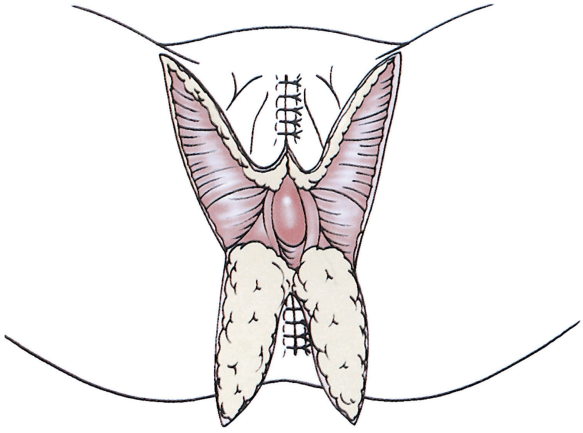

Figure 33.22 Skin subcutaneous tissue and deep fascial incision.

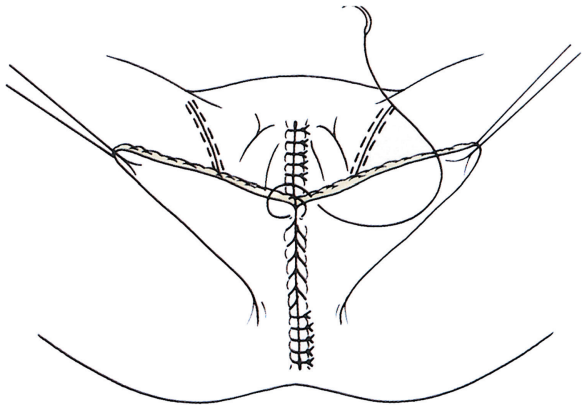

Figure 33.23 Flap elevation.

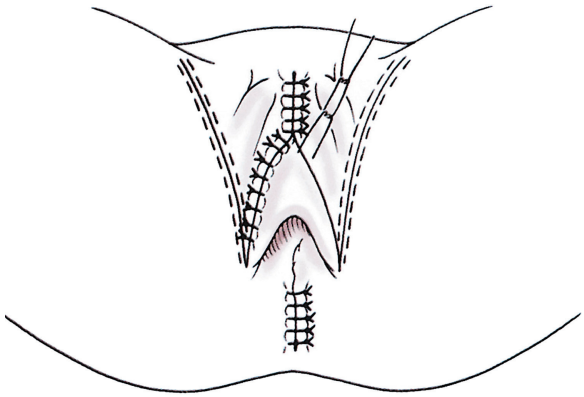

Figure 33.24 A suture of lateral margins of bilateral flaps to each other.

The flap is then elevated from distal to proximal in the subfascial plane over the adductor muscles in order to avoid injury to the neurovascular pedicle (Figure 33.23). The large distal branches of the perineal and pudendal vessels are identified and preserved. Often, the dissection is carried into the fat of the ischiorectal fossa in order to achieve adequate rotation and mobilization of the flap. The flap can then be rotated into the defect. The donor site is closed primarily in layers. A neovaginal pouch can be reconstructed by suturing the lateral margins of bilateral flaps to each other (Figure 33.24); the neovagina is then transposed into the rectovesical space and the proximal ends sutured into the new vaginal introitus.

BIBLIOGRAPHY

Cordeiro PG, Pusic AL, Disa JJ. 2002. A classification system and reconstructive algorithm for acquired vaginal defects. *Plast Reconstr Surg* **110**(4):1058–65.

Crowe PJ, Temple WJ, Lopez MJ, et al. 1999. Pelvic exenteration for advanced pelvic malignancy. *Semin Surg Oncol* **17**:152–60 [Review].

Martello JY, Vasconez HC. 1995. Vulvar and vaginal reconstruction after surgical treatment for gynecologic cancer. *Clin Plast Surg* **22**:129–40.

McCraw JB, Massey FM, Shanklin KD, et al. 1976. Vaginal reconstruction with gracilis myocutaneous flaps. *Plast Reconstr Surg* **58**:176–83.

Small T, Friedman DJ, Sultan M. 2000. Reconstructive surgery of the pelvis after surgery for rectal cancer. *Semin Surg Oncol* **18**:259–65.

Tobin GR, Day TG. 1988. Vaginal and pelvic reconstruction with distally based rectus abdominis and myocutaneous flaps. *Plast Reconstr Surg* **83**:62–73.

Tobin GR, Pursell SH, Day TG, Jr. 1990. Refinements in vaginal reconstruction using rectus abdominis flaps. *Clin Plast Surg* **17**:705–12.

Wee JT, Joseph VT. 1989. A new technique of vaginal reconstruction using neurovascular pudendal thigh flaps. A preliminary report. *Plast Reconstr Surg* **83**:701–9.

34 Additional plastic surgery procedures

Albert H. Chao, Georgia A. McCann, and Jeffrey M. Fowler

INTRODUCTION

Reconstructive procedures are sometimes necessary in patients with gynecologic malignancies, including for both external soft tissue wounds as well as intra-pelvic defects. These types of procedures may be indicated not only to achieve wound closure, but also to facilitate progression to adjuvant therapies in a timely fashion, and to restore form and function. Traditional methods (skin grafts, local skin flaps, rectus abdominis and gracilis muscle/myocutaneous flaps) are effective in reconstructing a wide variety of defects (Carlson et al. 1996, Copeland et al. 1989, Fowler 2009, Jurado et al., Soper et al. 1995). However, there are situations where these commonly used methods of reconstruction can be inadequate, impractical, or unavailable. In these cases, the ability to appropriately select and perform alternative techniques of reconstruction is essential.

TRADITIONAL RECONSTRUCTIVE OPTIONS AND THEIR LIMITATIONS

Skin Grafts

Skin grafts require a well-vascularized and clean wound bed and are generally most useful for relatively superficial wounds. They have limited utility in situations where obliteration of dead space is needed, such as resections of the pelvic cavity. Skin grafts also are less effective in poorly vascularized wounds, such as in patients who have previously received radiation therapy. In addition, because skin grafts experience relatively greater tissue contraction during healing than flaps, they have limited use in anatomic areas where supple soft tissue reconstruction is desired. Skin grafts are susceptible to shear force, which often requires a patient to be confined to bed rest for an extended period of time after pelvic reconstruction. Lastly, the aesthetic outcome for skin grafts can be inferior with respect to three-dimensionality and color match.

Local Skin Flaps

Local skin flaps are most useful for relatively small cutaneous defects, particularly when surrounding soft tissues are well vascularized. As a result, they can be limited in patients who have previously received radiation therapy. Also, since local skin flaps have a random-pattern blood supply (in contrast to myocutaneous/muscle flaps which have an axial blood supply), they may not always be usable in previously operated patients where existing surgical scars have altered local blood supply. Local skin flaps also typically lack sufficient bulk for cases where dead space obliteration is necessary.

Rectus Abdominis Flap

The rectus abdominis flap has been well described for the reconstruction of gynecologic defects (Carlson et al. 1996, Casey et al. 2004, Goldberg et al. 2006), commonly as a vertical rectus abdominis myocutaneous (VRAM) flap. Use of this flap is precluded when the deep inferior epigastric vessels have been previously resected or ligated, which sometimes can occur with major pelvic resections or groin dissections, as well as surgical approaches using a Maylard or Cherney incision (Nelson and Butler 2009). A VRAM flap also may not be used in patients who have had prior elevation of the abdominal subcutaneous tissues, such as may occur during hernia repair or tissue advancement for tight wound closures. There are also circumstances when a VRAM flap is feasible, but not the best option. In patients who will require both fecal and urinary diversion, placement of both stomas through a single rectus abdominis muscle or through the flap donor site is not preferable. Also, for pelvic and perineal reconstruction, a laparotomy is typically required to transfer a rectus abdominis-based flap, which may be a significant concern in patients who would not otherwise be undergoing a laparotomy (e.g., vulvar resection) or those who present with a postoperative wound infection or dehiscence.

Gracilis Flap

As a thigh-based flap, the gracilis flap does not have many of the same constraints as the rectus abdominis flap; its vascular pedicle is rarely involved in resections, a laparotomy is not required for tissue transfer, and the flap is generally located out of the zone of prior radiation (Soper et al. 1995). However, other characteristics of the gracilis flap can limit its use in certain cases. Since the pivot point of the flap is in the proximal thigh, it has limited ability in reaching defects of the pelvic cavity. In addition, the distal aspect of the flap that is transferred to defects is often relatively thin and may lack sufficient bulk. Although the gracilis flap may be performed as a myocutaneous flap which can enhance tissue volume, the skin paddle overlying the muscle can be unreliable when designed parallel to the longitudinal axis of the muscle and subject to necrosis (Copeland et al. 1989, Lacey et al. 1988).

GENERAL CONSIDERATIONS

Patients in whom alternative reconstructive methods are considered will often (1) be undergoing an extensive surgical resection (e.g., pelvic exenteration, radical vulvectomy), (2) have had prior pertinent surgical procedures including both resections and reconstructive procedures, and (3) have received and/or will be receiving neoadjuvant/adjuvant therapies. Detailed surgical planning in advance of procedures is essential, and a multidisciplinary approach is often helpful.

Treatment History

Two of the most important historical factors to consider in planning reconstruction are the nature of prior surgical procedures and radiation therapy. In patients who have undergone prior surgery, operative reports should be reviewed, with special

attention paid to any neurovascular structures that may have been resected or potentially involved. In addition, on physical examination, the location of scars should be carefully assessed. Prior scars may impact not only the viability of a skin paddle of a flap planned for transfer, but also healing at the flap donor site, particularly if watershed perfusion areas are created by adjacent scars. In patients who have received prior radiation therapy, the territory of irradiation should be known, and flaps designed to be outside of it when possible.

Goals of Reconstruction

As with all reconstruction in the gynecologic oncology patient, there may be one or several objectives, including achieving wound closure, obliterating dead space, coverage of critical structures, restoring anatomic form, and minimizing postoperative wound healing complications, especially when adjuvant therapies are likely. The extent of the defect should be anticipated preoperatively, and the goals of reconstruction clearly defined in order to properly select the appropriate reconstructive method. For instance, if the primary aim is only to fill dead space, then a muscle-only flap might be suitable, which would allow for primary donor site closure. Conversely, if only skin coverage is needed, then a fasciocutaneous flap could be performed without needing to sacrifice a muscle. In some cases there may be multiple goals, in which case the various possible reconstructive options should be carefully compared in order to determine which would best meet those goals overall. Once a list of possible reconstructive methods is made (Table 34.1), this in turn allows for appropriate informed consent and setup for the surgical procedure (e.g., inclusion of all donor sites in the field, patient position).

Execution of the Surgical Plan

While careful preoperative planning is essential to a successful reconstructive outcome, intraoperative decision-making to finalize the plan is equally critical. Although one may be able to reasonably anticipate the defect and consider harvesting the flap concurrently with the resection when a two-team approach is possible, it is generally advisable not to commit to a reconstructive technique until after the surgical resection is complete; unexpected findings can significantly influence the defect, which may in turn alter the most appropriate reconstructive method. Intraoperative use of a template of the defect with emulation of flap transposition can aid surgical planning prior to commencement of flap elevation and reveal issues that may not have been readily apparent preoperatively that warrant modification of the reconstructive plan.

Table 34.1 Commonly Used Reconstructive Options and Alternatives

Anatomic Site	Reconstructive Options	
	Commonly Used	Alternatives
Groin/ Suprapubic	Rectus abdominis flap	Anterolateral thigh flap Sartorius flap Tensor fascia lata flap Vastus lateralis flap
Pelvic cavity	Gracilis flap Rectus abdominis flap	Anterolateral thigh flap Omental flap Posterior thigh flap Vastus lateralis flap
Perineum	Gracilis flap	Anterolateral thigh flap Gluteal flap Posterior thigh flap
Vagina	Gracilis flap Pudendal thigh flap Rectus abdominis flap	Anterolateral thigh flap Gluteal flap Posterior thigh flap

DEFECT SITES

While each defect that results from a gynecologic resection is unique and may involve multiple anatomic areas, an understanding of the specific issues involved and the reconstructive options for each individual anatomic area can aid surgical planning. In the gynecologic oncology patient, defects for reconstruction can be broadly classified into those of the groin/suprapubic area, pelvic cavity, perineum, and vagina. When defects span multiple regions, selection of a reconstructive option that can address more than one anatomic area is preferable, when possible.

Groin/Suprapubic

Defects of the groin can occur following procedures such as groin lymphadenectomy, especially in the setting of recurrent disease with or without a history of radiation therapy to the surgical field (Gaarenstroom et al. 2003, Hinten et al. 2011, Paley et al. 1997, Zhang et al. 2000).

This region can be problematic due to a variety of factors, including devascularization of skin flaps from tissue undermining, disruption of lymphatic channels during dissection, and location within a soft tissue crease. Prior radiation in patients with recurrent disease can further exacerbate wound healing (Montana et al. 2000). Reconstruction of groin defects can aim to fill dead space, repair a skin defect, and/or cover neurovascular structures (Gravvanis et al. 2009, Nirmal et al. 2011). When a skin defect needs to be reconstructed, use of a flap with a skin paddle is preferable to a muscle flap with skin graft when considering that the groin is a site of motion and shear. When exposed neurovascular structures result from a resection, use of a myocutaneous flap can be advantageous, as it confers a more layered reconstruction that can minimize the severity of the wound in case breakdown occurs at the skin.

Pelvic Cavity

Reconstruction in patients who have undergone ultra-radical resections of the pelvic cavity aims primarily to fill dead space within the pelvis, which can reduce the incidence of enteric complications such as small bowel obstruction and fistula formation, wound healing problems, and fluid collections (Berger et al. 2012, Goldberg et al. 2006). This may especially be true in patients who have received prior radiation therapy, where subsequent surgical resection exposes poorly vascularized and immobile radiated wound surfaces (Butler et al. 2008, Hinojosa et al. 2009). Muscle flaps alone are sometimes adequate to reconstruct these defects. However, pelvic cavity defects in the gynecologic oncology patient frequently coexist with vaginal and/or perineal defects, in which case a myocutaneous flap, or sometimes two separate flaps, may be necessary.

Perineum

Defects of the perineum typically require primarily skin wound coverage. As an area that experiences frequent pressure and shear, achieving a durable reconstruction is of utmost importance. For this reason, although skin grafts can be considered in some cases, use of local or pedicled flaps is often advisable. When perineal defects communicate with a pelvic cavity defect, pedicled soft tissue flaps are preferable, which can both help to fill dead space and provide a more layered reconstruction to protect pelvic contents.

Vagina

Reconstruction of vaginal defects aims to restore both physical form and sexual function, which has been shown to improve quality of life (Hawighorst-Knapstein et al. 1997, Ratliff et al. 1996). Traditionally, these defects have been reconstructed with local flaps and rectus abdominis/gracilis flaps (Cordeiro et al. 2002, Pusic and Mehrara 2006); however, several other types of flaps have also been described for use in vaginal reconstruction. Similar to defects of the perineum, vaginal defects may often coexist with pelvic cavity, where consideration should be given to choosing a technique that meets multiple reconstructive goals.

FLAP OPTIONS

Anterolateral Thigh Flap

The anterolateral thigh flap (ALT) has become a commonly used option in reconstructive surgery due to its reliability and versatility, as well as improved understanding of its anatomy (Ali et al. 2009). Its wide arc of rotation as a pedicled flap and location in the thigh makes it well suited for gynecologic defects, where it has most often been described for use in reconstructing vulvar/perineal and pelvic exenteration defects (Lannon et al. 2011, Wong et al. 2009, Zeng et al. 2011). In addition, a large amount of tissue can be transferred, especially if the donor site is skin grafted, which makes the ALT flap a useful option for extensive defects that cross multiple anatomic areas.

The blood supply to the ALT flap is the descending branch of the lateral circumflex femoral artery, which travels between the vastus lateralis and rectus femoris muscles in the thigh. As it traverses the thigh, the descending branch gives rise to numerous perforator vessels that supply the skin of the anterolateral aspect of the thigh. Since the vastus lateralis and the skin of the anterolateral thigh share a common blood supply, the ALT flap can be harvested either as a myocutaneous flap or as a perforator flap that includes skin only. In addition, the vastus lateralis can be transferred as a muscle flap alone. This versatility is useful in the gynecologic oncology patient since, for example, reconstruction of a vulvar defect might be best accomplished with a skin-only flap, while a composite pelvic cavity and vaginal defect would be most suitably reconstructed with a myocutaneous flap where the muscle obliterates dead space and the skin paddle resurfaces the vaginal defect.

The harvest technique of the ALT flap has been well described (Wei et al. 2002, Yu 2004). Briefly, a line is marked between the anterior superior iliac spine (ASIS) and the superolateral patella, which approximates the intermuscular septum between the vastus lateralis and rectus femoris muscles. Since the majority of cutaneous perforators are concentrated within the midpoint of this line (Yu 2004), the ALT flap is typically tentatively centered on this point. A limited medial incision is made first, and then dissection performed from medial to lateral to identify the location of cutaneous perforators, after which the final flap skin paddle position may be shifted as necessary based on anatomy, and the remaining incisions made. If the ALT flap will be performed as a skin-only flap, then the perforator(s) to be included with the flap are dissected to the vascular pedicle. If the ALT flap will be performed as a myocutaneous flap, then the vastus lateralis is included without need for perforator dissection. The flap is usually tunneled beneath the rectus femoris and sartorius muscles to increase the reach of the flap for groin, pelvic cavity, and perineal defects (Figure 34.1A–C).

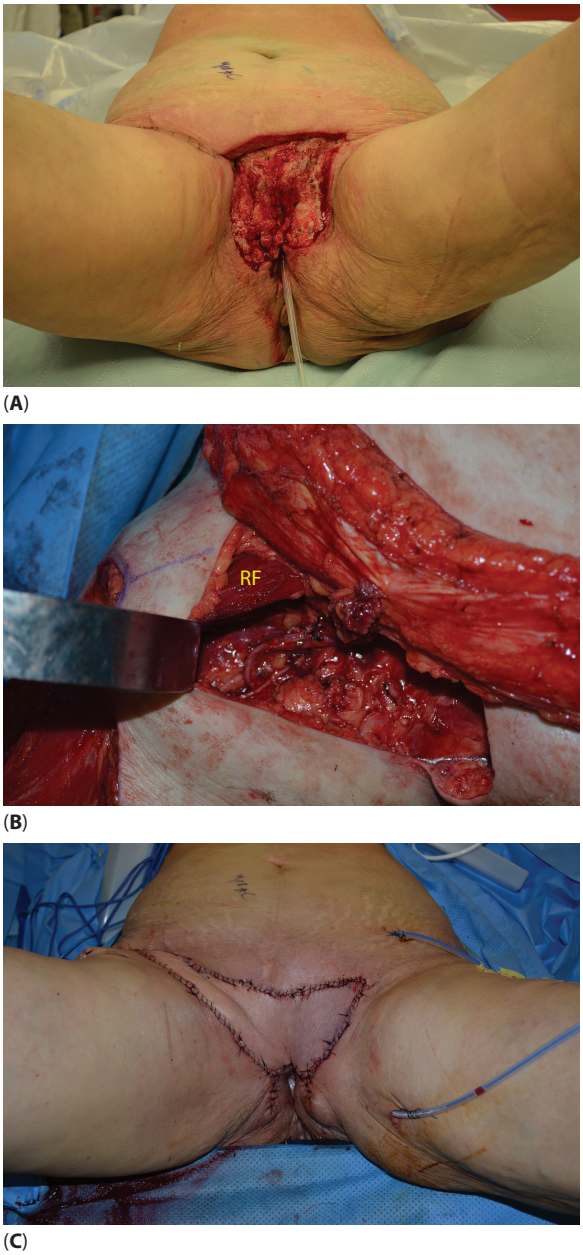

(**A**)

(**B**)

(**C**)

Figure 34.1 Anterolateral thigh (ALT) flap. (**A**) Patient with vulvar defect following resection of recurrent squamous cell carcinoma. (**B**) ALT flap is tunneled deep to the rectus femoris (RF) muscle into the defect. (**C**) Final flap inset.

Gluteal Flap

In cancer patients, gluteal flaps utilize the skin and soft tissues overlying the gluteus maximus muscle. Both the skin over the superior aspect (superior gluteal artery perforator [SGAP] flap) and the inferior aspect (inferior gluteal artery perforator [IGAP] flap) of the gluteal region may be used. Gluteal flaps have most often been used to reconstruct defects of the perineum and vagina (Cheon et al. 2010, Wagstaff et al. 2009).

The blood supply to the SGAP is the superior gluteal artery, which exits the greater sciatic foramen at a point approximately between the medial and middle thirds of a line between the posterior superior iliac spine (PSIS) and the greater trochanter. The blood supply to the IGAP flap is the inferior gluteal artery, which exits the greater sciatic foramen approximately two-thirds of the way along a line from the PSIS to the ischial tuberosity. Both vessels originate from the internal iliac artery, and supply perforators to the overlying skin.

SGAP/IGAP flaps are most easily raised from a prone position. The main vascular pedicle is first marked using the described anatomic landmarks, and then a handheld Doppler is used to identify the location of perforators. An elliptical skin paddle is then designed encompassing the pedicle and perforators. After the skin is incised, flap elevation is typically performed from lateral to medial until the perforators are encountered. Then, intramuscular dissection is performed through the gluteus maximus muscle in order to gain additional vascular pedicle length. The flap can then be transferred into the defect either as a rotational or V-Y advancement flap (Figure 34.2A–D).

Omental Flap

The omental flap has been widely used in gynecologic oncology, including in the prevention of postoperative complications following radical abdominal hysterectomy and pelvic lymphadenectomy, pelvic floor reconstruction following exenteration, and vaginal reconstruction and fistula repair (Fujiwara et al. 2003, Hultman et al. 2010, Kusiak and Rosenblum 1996, Patsner and Hackett 1997, Schloericke et al. 2012). Open harvest of the omental flap is most common, and typically begins with reflection of the flap cranially to expose its attachments to the transverse colon, which are taken down to isolate the flap on only its anterior attachments. Usually the flap is based on either the right or left gastroepiploic artery, each of which can independently supply the flap. The other pedicle is ligated, as well as the short gastric branches, in order to allow its transposition to defects of the pelvis.

Posterior Thigh Flap

The posterior thigh flap (PTF), also known as the gluteal thigh flap, is a superiorly based fasciocutaneous flap located on the posterior aspect of the thigh. In gynecologic oncology, it has been described for use in the reconstruction of defects involving

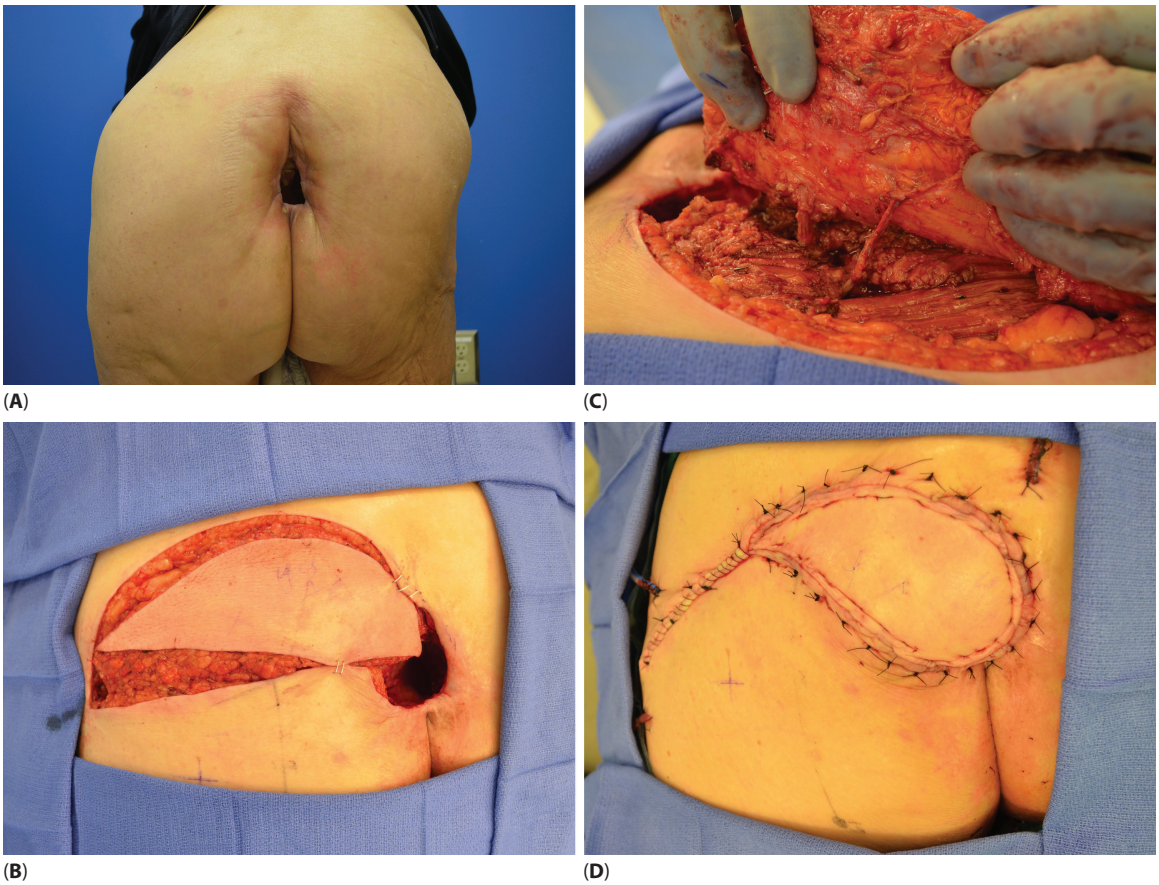

Figure 34.2 Gluteal flap. (**A**) Patient with history of cervical cancer previously treated with surgery and radiation therapy who subsequently developed sacral wound breakdown and exposed coccyx. (**B**) Left superior gluteal artery perforator (SGAP) flap elevated. (**C**) Two perforator vessels were dissected through the gluteus maximus muscle to increase mobility of the flap. (**D**) Final flap inset is shown after V-Y advancement of the SGAP flap.

the perineum after vulvectomy, the pelvic cavity after exenteration, as well as in vaginal reconstruction (Achauer et al. 1984, Hurwitz et al. 1981, Friedman et al. 2010).

The blood supply to the PTF is the descending branch of the inferior gluteal artery, which exits from beneath the gluteus maximus approximately at the midpoint of the gluteal crease. It then continues subcutaneously along the midline of the posterior thigh, where a handheld Doppler can be useful in identifying its course. The skin paddle territory of the flap involves the surface of the posterior thigh, from gluteal crease to popliteal fossa (Friedman et al. 2010), although generally flap design stops a few centimeters proximal to the popliteal fossa to prevent scar contracture at the knee (Figure 34.3A).

For perineal and vaginal reconstruction, flap harvest may be performed from either lithotomy or prone position, depending in part on the location of the defect. In cases where the flap will be transferred to the pelvic cavity, lithotomy is utilized. Flap elevation begins inferiorly, where a subfascial plane is entered. The PTF is then raised from inferior to superior up to the level of the gluteal crease (Figure 34.3B). The flap may then be transferred to the defect by creating a subcutaneous tunnel, or by excising the native intervening thigh tissue and replacing it with flap tissues (Figure 34.3C). In cases where both pelvic dead space needs to be filled as well as reconstruction of external soft tissues, bilateral flaps can be performed, with one de-epithelialized and used for the pelvic cavity, and the other used for external skin coverage.

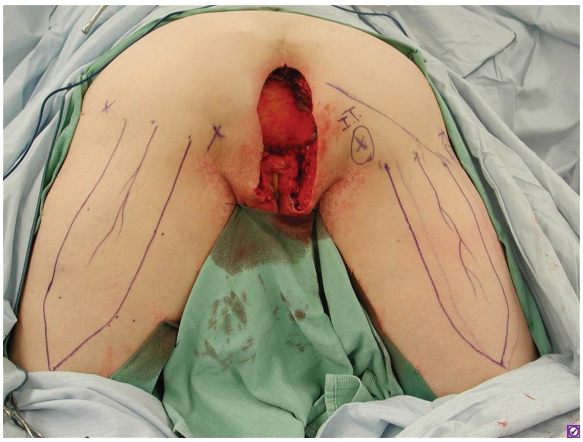

(**A**)

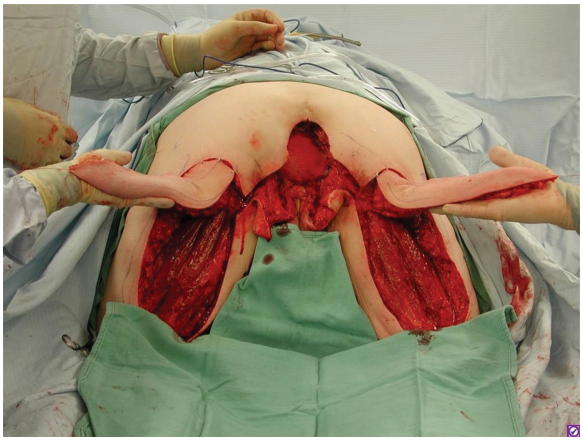

(**B**)



(**C**)

Figure 34.3 Posterior thigh flap. (**A**) Patient with large perineal and vaginal defect following pelvic exenteration. Preoperative markings for bilateral posterior thigh flaps are shown. (**B**) Both flaps have been elevated, and the intervening skin bridges between the flap donor and defect recipient sites have been divided. (**C**) Long-term postoperative result.

Sartorius Flap

The sartorius is a thin muscle located in the anterior thigh that assists in hip flexion, abduction, and lateral rotation. It has been widely used in the reconstruction of groin defects of both oncologic and other etiologies as a muscle-only flap (Bartlett et al. 2013, Fischer et al. 2013, Wu et al. 2006). The sartorius receives a segmental blood supply from the superficial femoral artery, which gives branches to the muscle that enter its deep medial surface. The size and blood supply of the sartorius flap limit its use to relatively smaller groin defects. Flap harvest usually begins in a subcutaneous plane to expose the superficial surface of the muscle. Then, its deep aspect is carefully dissected to mobilize the flap while preserving as much of its segmental blood supply as possible. The superior and/or inferior muscle substance may be divided to facilitate mobility, and then the flap either advanced or turned over into the groin defect.

Tensor Fascia Lata Flap

The tensor fascia lata (TFL) muscle is located on the lateral aspect of the thigh and functions in knee stabilization, and can be harvested with minimal donor site morbidity. In the gynecologic oncology patient, the TFL flap is most often used to reconstruct defects of the groin and suprapubic area, typically as a myocutaneous flap (Chafe et al. 1983). In our experience, use of the TFL flap has largely been replaced by the more versatile ALT flap.

The blood supply to the TFL is via the ascending branch of the lateral circumflex femoral artery, which enters the muscle approximately at the junction of the proximal and middle thirds of a line between the ASIS and patella. This line also roughly delineates the anterior extent of the muscle and is used for designing the flap. Based on the dimensions of the defect, the posterior extent of the flap can then be designed. The TFL flap is usually designed over the proximal two-thirds of the thigh where the skin paddle is more reliable. Flap elevation begins inferiorly, where the insertion of the TFL is divided, and then the flap is raised off of its deep surface from inferior to superior, where the vascular pedicle is identified. The superior skin

attachment to the skin paddle is usually left intact, and the flap then transferred to the defect.

CONCLUSION

As more treatment options have become available for gynecologic oncology patients, the complexity of surgery, including reconstructive surgery, has increased. There is a wide range in the complexity of surgical situations that require reconstruction in the gynecologic oncology patient. Reconstructive goals include bringing in healthy tissue to fill the defect in order to enhance wound healing, and restoration of anatomic form and function. In these situations, reconstructive surgery is optimal when applied concurrently with the primary extirpative procedure but is sometimes performed secondarily for postoperative conditions such as repair of vaginal stenosis or vulvovaginal wound breakdown. There are general guidelines that prioritize reconstructive options based on the size and location of the vaginal defect. However, the optimal reconstructive procedure will be dependent not only on the site and extent of the defect, but also upon previous therapy applied to the pelvis and other intraoperative variables. Many reconstructive techniques are available, and most often there is not one best option for any situation requiring reconstruction of the pelvis, vagina, and/or vulva. Important considerations include not only the goals at the site of reconstruction, but also the patient's preoperative history, intraoperative condition, total length of the procedure, and potential donor site sequelae. Ultra-radical procedures that leave the patient with various combinations of pelvic, vaginal, and/or perineal defects provide the greatest challenge. Preoperative planning is important and the surgeon needs to be prepared to choose from a portfolio of reconstructive options based on the extent of the radical surgery and other intraoperative factors. Therefore it is necessary that the surgical team be proficient in multiple reconstructive options in order to optimally address the various defects one may encounter. Fortunately, there are numerous options for reconstruction in patients in whom standard or commonly used reconstructive techniques are unavailable or insufficient. Given the continued evolution of these alternative techniques, an integrated multidisciplinary approach may be beneficial in these cases.

REFERENCES

Achauer BM, Braly P, Berman ML, et al. 1984. Immediate vaginal reconstruction following resection for malignancy using the gluteal thigh flap. *Gynecol Oncol* **19**:79–89.

Ali RS, Bluebond-Langner R, Rodriguez ED, et al. 2009. The versatility of the anterolateral thigh flap. *Plast Reconstr Surg* **124**:e395–407.

Bartlett EK, Meise C, Bansal N, et al. 2013. Sartorius transposition during inguinal lymphadenectomy for melanoma. *J Surg Res* **184**:209–15.

Berger JL, Westin SN, Fellman B, et al. 2012. Modified vertical rectus abdominis myocutaneous flap vaginal reconstruction: An analysis of surgical outcomes. *Gynecol Oncol* **125**:252–5.

Butler CE, Gündeslioglu AO, Rodriguez-Bigas MA. 2008. Outcomes of immediate vertical rectus abdominis myocutaneous flap reconstruction for irradiated abdominoperineal resection defects. *J Am Coll Surg* **206**:694–703.

Carlson JW, Carter JR, Saltzman AK, et al. 1996. Gynecologic reconstruction with a rectus abdominis myocutaneous flap: An update. *Gynecol Oncol* **61**:364–8.

Casey WJ 3rd, Tran NV, Petty PM, et al. 2004. A comparison of 99 consecutive vaginal reconstructions: An outcome study. *Ann Plast Surg* **52**:27–30.

Chafe W, Fowler WC, Walton LA, et al. 1983. Radical vulvectomy with use of tensor fascia lata myocutaneous flap. *Am J Obstet Gynecol* **145**:207–13.

Cheon YW, Lee MC, Kim YS, et al. 2010. Gluteal artery perforator flap: A viable alternative for sacral radiation ulcer and osteoradionecrosis. *J Plast Reconstr Aesthet Surg* **63**:642–7.

Copeland LJ, Hancock KC, Gershenson DM, et al. 1989. Gracilis myocutaneous vaginal reconstruction concurrent with total pelvic exenteration. *Am J Obstet Gynecol* **160**:1095–101.

Cordeiro PG, Pusic AL, Disa JJ. 2002. A classification system and reconstructive algorithm for acquired vaginal defects. *Plast Reconstr Surg* **110**:1058–65.

Fischer JP, Mirzabeigi MN, Sieber BA, et al. 2013. Outcome analysis of 244 consecutive flaps for managing complex groin wounds. *J Plast Reconstr Aesthet Surg* **66**:1396–404.

Fowler JM. 2009. Incorporating pelvic/vaginal reconstruction into radical pelvic surgery. *Gynecol Oncol* **115**:154–63.

Friedman JD, Reece GR, Eldor L. 2010. The utility of the posterior thigh flap for complex pelvic and perineal reconstruction. *Plast Reconstr Surg* **126**:146–55.

Fujiwara K, Kigawa J, Hasegawa K, et al. 2003. Effect of simple omentoplasty and omentopexy in the prevention of complications after pelvic lymphadenectomy. *Int J Gynecol Cancer* **13**:61–6.

Gaarenstroom KN, Kenter GG, Trimbos JB, et al. 2003. Postoperative complications after vulvectomy and inguinofemoral lymphadenectomy using separate groin incisions. *Int J Gynecol Cancer* **13**:522–7.

Goldberg GL, Sukumvanich P, Einstein MH, et al. 2006. Total pelvic exenteration: The Albert Einstein College of Medicine/Montefiore Medical Center Experience (1987 to 2003). *Gynecol Oncol* **101**:261–8.

Gravvanis A, Caulfield RH, Mathur B, et al. 2009. Management of inguinal lymphadenopathy: Immediate sartorius transposition and reconstruction of recurrence with pedicled ALT flap. *Ann Plast Surg* **63**:307–10.

Hawighorst-Knapstein S, Schönefussrs G, Hoffmann SO, et al. 1997. Pelvic exenteration: Effects of surgery on quality of life and body image—A prospective longitudinal study. *Gynecol Oncol* **66**:495–500.

Hinojosa MW, Parikh DA, Menon R, et al. 2009. Recent experience with abdominal perineal resection with vertical rectus abdominis myocutaneous flap reconstruction after preoperative pelvic radiation. *Am Surg* **75**:995–9.

Hinten F, van den Einden LC, Hendriks JC, et al. 2011. Risk factors for short- and long-term complications after groin surgery in vulvar cancer. *Br J Cancer* **105**:1279–87.

Hultman CS, Sherrill MA, Halvorson EG, et al. 2010. Utility of the omentum in pelvic floor reconstruction following resection of anorectal malignancy: Patient selection, technical caveats, and clinical outcomes. *Ann Plast Surg* **64**:559–62.

Hurwitz DJ, Swartz WM, Mathes SJ. 1981. The gluteal thigh flap: A reliable, sensate flap for the closure of buttock and perineal wounds. *Plast Reconstr Surg* **68**:521–32.

Jurado M, Bazán A, Elejabeitia J, et al. 2000. Primary vaginal and pelvic floor reconstruction at the time of pelvic exenteration: A study of morbidity. *Gynecol Oncol* **77**:293–7.

Kusiak JF, Rosenblum NG. 1996. Neovaginal reconstruction after exenteration using an omental flap and split-thickness skin graft. *Plast Reconstr Surg* **97**:775–81.

Lacey CG, Stern JL, Feigenbaum S, et al. 1988. Vaginal reconstruction after exenteration with use of gracilis myocutaneous flaps: The University of California, San Francisco experience. *Am J Obstet Gynecol* **158**:1278–84.

Lannon DA, Ross GL, Addison PD, et al. 2011. Versatility of the proximally pedicled anterolateral thigh flap and its use in complex abdominal and pelvic reconstruction. *Plast Reconstr Surg* **127**:677–88.

Montana GS, Thomas GM, Moore DH, et al. 2000. Preoperative chemoradiation for carcinoma of the vulva with N2/N3 nodes: A gynecologic oncology group study. *Int J Radiat Oncol Biol Phys* **48**:1007–13.

Nelson RA, Butler CE. 2009. Surgical outcomes of VRAM versus thigh flaps for immediate reconstruction of pelvic and perineal cancer resection defects. *Plast Reconstr Surg* **123**:175–83.

Nirmal TJ, Gupta AK, Kumar S, et al. 2011. Tensor fascia lata flap reconstruction following groin dissection: Is it worthwhile? *World J Urol* **29**:555–9.

Paley PJ, Johnson PR, Adcock LL, et al. 1997. The effect of sartorius transposition on wound morbidity following inguinal-femoral lymphadenectomy. *Gynecol Oncol* **64**:237–41.

Patsner B, Hackett TE. 1997. Use of the omental J-flap for prevention of postoperative complications following radical abdominal hysterectomy: Report of 140 cases and literature review. *Gynecol Oncol* **65**:405–7.

Pusic AL, Mehrara BJ. 2006. Vaginal reconstruction: An algorithm approach to defect classification and flap reconstruction. *J Surg Oncol* **94**:515–21.

Ratliff CR, Gershenson DM, Morris M, et al. 1996. Sexual adjustment of patients undergoing gracilis myocutaneous flap vaginal reconstruction in conjunction with pelvic exenteration. *Cancer* **78**:2229–35.

Schloericke E, Hoffmann M, Zimmermann M, et al. 2012. Transperineal omentum flap for the anatomic reconstruction of the rectovaginal space in the therapy of rectovaginal fistulas. *Colorectal Dis* **14**:604–10.

Soper JT, Rodriguez G, Berchuck A, et al. 1995. Long and short gracilis myocutaneous flaps for vulvovaginal reconstruction after radical pelvic surgery: Comparison of flap-specific complications. *Gynecol Oncol* **56**:271–5.

Wagstaff MJ, Rozen WM, Whitaker IS, et al. 2009. Perineal and posterior vaginal wall reconstruction with superior and inferior gluteal artery perforator flaps. *Microsurgery* **29**:626–9.

Wei FC, Jain V, Celik N, et al. 2002. Have we found an ideal soft-tissue flap? An experience with 672 anterolateral thigh flaps. *Plast Reconstr Surg* **109**:2219–26.

Wong S, Garvey P, Skibber J, et al. 2009. Reconstruction of pelvic exenteration defects with anterolateral thigh-vastus lateralis muscle flaps. *Plast Reconstr Surg* **124**:1177–85.

Wu LC, Djohan RS, Liu TS, et al. 2006. Proximal vascular pedicle preservation for sartorius muscle flap transposition. *Plast Reconstr Surg* **117**:253–8.

Yu P. 2004. Characteristics of the anterolateral thigh flap in a Western population and its application in head and neck reconstruction. *Head Neck* **26**:759–69.

Zeng A, Qiao Q, Zhao R, et al. 2011. Anterolateral thigh flap-based reconstruction for oncologic vulvar defects. *Plast Reconstr Surg* **127**:1939–45.

Zhang SH, Sood AK, Sorosky JI, et al. 2000. Preservation of the saphenous vein during inguinal lymphadenectomy decreases morbidity in patients with carcinoma of the vulva. *Cancer* **89**:1520–5.

35 Fat transfer: Applications in gynecology

Deborah C.M. Boyle and Simon H. Wood

INTRODUCTION

In this chapter, we consider the use of fat transfer for the treatment of cancer therapy-related side effects and for a vulvar skin dystrophy with low neoplastic potential lichen sclerosus (LS).

OVERVIEW

Significant scarring may result in cases where radiotherapy, with or without concomitant chemotherapy, has been used to treat anogenital neoplasia. This can lead to morbidity from inflexible areas causing pain when sitting or moving and can also lead to impaired sexual function.

LS, an autoimmune skin dystrophy which more often affects the genital skin than extragenital areas, may also cause significant scarring and poor skin compliance leading to easy or even spontaneous skin splitting and sexual dysfunction. The true incidence of LS is unknown but is estimated to be at least 1/1000 (Powell and Wojnarowska 1999) and like most autoimmune conditions, affects more women than men. LS is estimated to have a 2% to 5% lifetime risk of developing cancer (Smith and Haefner 2004).

Fat transfer is a widely accepted technique in plastic surgery since its first description in 1893 by Gustav Neuber (Van de Graaf and Korteweg 2010), who transferred fat from the orbit to treat depressed scars resulting from osteomyelitis. It has since been shown to act as more than simply a "filler." Animal and clinical studies have shown that fat transfer improves the quality of the skin, with changes in skin texture and mechanical properties, associated with stimulation of collagen synthesis (Foyatier JL et al. 2004, Mojallal and Foyatier 2007, Mojallal et al. 2009, von Heimburg et al. 2001). It is associated with low complication rates (Coleman 2006, Mojallal et al. 2009). In 1995, Sydney Coleman published his technique of fat grafting, which has been widely adopted (Coleman 1995). Although variations exist, the basic principles are the same and are described below.

METHODS

The technique we have used for fat harvest and lipo-filling is based on the method described by Coleman (1995). There are variations on the technique such as that described by Casabona and colleagues (2010), who used a combination of fat and platelet-rich plasma. In our experience platelet-rich plasma is not required to achieve good results and may overcomplicate the procedure.

In the technique used by the authors of this chapter, patients are marked preoperatively while standing to identify suitable donor sites for fat harvest. In all cases this was from the lower and/or upper abdomen. Under general anesthesia patients are prepared supine and donor sites infiltrated with the following preparation: 500 mL normal saline, 1 vial Hyalase® (Hyaluronidase 1500 international units/ampoule) and 1 mL 1:1000 epinephrine. Small stab incisions are made with a size 11 blade in either the umbilicus or Caesarean section scar in order to make the incisions unobtrusive. Liposuction is carried out using a Coleman fat harvest cannula with aspiration into 10-mL syringes. After removal of their plungers, syringes are centrifuged with a sterile cap at 3000 rpm for 3 minutes. Typically, the harvested fat, after preparation, results in one-third volume of fat for final transfer. Fat is injected via stab wounds into the area to be treated (Figure 35.1). This is injected using multiple tracks using 1-mL syringes, with a Coleman injection cannula, where small volumes of fat are deposited in each track. In cases where the technique is being used to treat vulvar LS with a view to improving introital compliance, fat is deposited superficially and deeply perivaginally, around the margin of the introitus, deep to the labia minora and into the labia majora. In these cases, fat deposits are particularly concentrated over the perineal body and where tears associated with the disease were seen in mucosa. Fat is also injected into the periclitoral and periurethral areas with meticulous care considering the delicacy of these areas and the potential risks involved in damaging these structures. All wounds are closed with 5-0 Vicryl Rapide® and patients are allowed to go home the same day, depending on pain control. In our series, all LS patients required two episodes of fat transfer. In these patients, a mean of 26 mL of prepared fat was injected per patient during the first procedure, and a mean of 18 mL for the second procedure. The second procedure was on average 7 months after the first. Patients were reviewed in post-op clinic at 1 week and followed up in outpatient clinic.

In the case of the patient with post-radiotherapy change, the volume of fat injected was 30 mL on both occasions. The area treated was more extensive and covered the perianal and perivulvar areas that had clinically evident radiotherapy changes.

ADVERSE EVENTS

No adverse events were observed in our patients. All patients had moderate pain in the treated areas with some bruising in donor sites and more markedly at the injected areas.

CLINICAL APPLICATIONS AND EXPERIENCE

Post radiotherapy skin change and vulvar LS are difficult conditions to treat, with previous strategies being far from optimal. One of the characteristics of LS is subcutaneous atrophy, and we feel that the volume generated using fat transfer is essential in treating LS where it affects the aperture of introitus and compliance of the skin leading to entry pain and splitting of the skin.

Fat grafting has been successfully used in radiotherapy-damaged tissue (Rigotti et al. 2007). It is not certain whether the treatment acts via regeneration by delivering stem cells, although fat transfer has been reported to stimulate collagen synthesis, angiogenesis, and immunomodulation (Coleman 2006, Hausman and Richardson 2004, Mojallal et al. 2009, Puissant et al. 2005, Rigotti et al. 2007). The benefit of fat transfer in vulvar LS may be due to one or more of a combination of correction



(**A**) (**B**)

Figure 35.1 (**A**) Preoperative and (**B**) immediate postoperative photographs of a patient at second-stage lipofilling demonstrating the six sites of injection and immediate volume filling change of perineum and vulva.

of soft tissue loss by introducing additional tissue, encouraging vascularization and healing in dystrophic areas, and improved skin texture and elasticity (Coleman 2006, Mojallal et al. 2009). In any case, the subjective symptomatic improvement seen in this case series provides support for the use of fat transfer in vulvar LS.

We have previously successfully used fat grafting in a case of constant severe saddle pain in a woman secondary to radiotherapy for anal cancer. The examination findings were of a fixed, scarred saddle area which was causing a severe pulling sensation and restriction of movement, including walking. The patient was very uncomfortable even when sitting due to the pulling sensation of the completely inflexible area.

Following a significant improvement in symptoms after one episode of fat grafting, the patient had a small area of residual discomfort where the skin remained inflexible that was completely alleviated after a second fat transfer. Similar fixation of the skin and subcutaneous tissues as seen in our patient are also seen in women treated for vulvar cancers by radiotherapy. These women can be potentially helped with respect to quality of life by the fat transfer.

There are some similarities in the findings on examination of patients with LS of the vulva, notably scarring and atrophy, and this led us to use fat transfer, successfully, for this difficult problem.

When seen some months after the second injection, all patients reported resolution of entry pain and other symptoms (such as skin splitting), with restoration of anatomical features of the vulva, less distortion of the introitus, and disappearance of vulvar atrophy. All patients regained sexual activity. One of the patients who had been previously apareunic went on to conceive spontaneously and deliver a child (by elective Caesarean section). One patient had disease progression around the anus with fissuring, although the perineal disease had resolved, and at the time of writing is currently having further treatment to this area. It is important that the skin disease is controlled by the use of the medical therapies (principally steroid applied topically) as fat transfer will not abolish the LS but rather will treat the effects. Although these outcomes are arguably, at least to some extent, subjective, the fact that all LS patients were able to return to sexual intercourse reflects the significance of their symptomatic improvement.

It is important that all patients understand the risks of fat transfer. These include the need for more than one procedure, that approximately half of the fat is reabsorbed, and that there can be donor site complications such as bruising (due to the vascularity of the area), and contour abnormalities if the fat is harvested too superficially. There may be widespread donor site infections and skin loss, although these problems are rare and were not seen in any of our patients.

REFERENCES

Casabona F, Priano V, Vallerino V, et al. 2010. New surgical approach to lichen sclerosus of the vulva: The role of adipose-derived mesenchymal cells and platelet-rich plasma in tissue regeneration. *Plast Reconstr Surg* **126**:210e–1e.

Coleman SR. 1995. Long-term survival of fat transplants: Controlled demonstrations. *Aesthet Plast Surg* **19**:421–5.

Coleman SR. 2006. Structural fat grafting: More than a permanent filler. *Plast Reconstr Surg* **118**:108S–20S.

Foyatier JL, Mojallal A, Voulliaume D, et al. 2004. Clinical evaluation of structural fat tissue graft (Lipostructure) in volumetric facial restoration with face-lift. About 100 cases. *Ann Chir Plast Esthet* **49**:437–55.

Hausman GJ, Richardson RL. 2004. Adipose tissue angiogenesis. *J Animal Science* **82**:925–934.

Mojallal A, Foyatier J. 2007. Autologous fat transfer in post-trauma sequelae: experimental study demonstrating skin quality improvement. Personal communication. International Symposium on Fat Injection. Milan, Italy: Fondazione G. Sanvenero Roselli.

Mojallal A, Lequeux C, Shipkov C, et al. 2009. Improvement of skin quality after fat grafting: Clinical observation and an animal study. *Plast Reconstr Surg* **124**:765–74.

Powell J, Wojnarowska F. 1999. Lichen sclerosus. *Lancet* **353**:1777–83.

Puissant B, Barreau C, Bourin P, et al. 2005. Immunomodulatory effect of human adipose tissue derived adult stem cells: Comparison with bone marrow mesenchymal stem cells. *Br J Haematol* **129**:118–29.

Rigotti G, Marchi A, Galie M, et al. 2007. Clinical treatment of radiotherapy tissue damage by lipoaspirate transplant: A healing process mediated by adipose-derived adult stem cells. *Plast Reconstr Surg* **119**:1409–22; discussion 1423–4.

Smith YR, Haefner HK. 2004. Vulvar lichen sclerosus. *Am J Clin Dermatol* **5**:105–25.

Van de Graaf R, Korteweg S. 2010. Gustav Adolf Neuber (1850–1932) and the first report on fat auto-grafting in humans in 1893. *Hist Plast Surg* **1**:7–11.

von Heimburg D, Zachariah S, Kühling H, et al. 2001. Human preadipocytes seeded on freeze-dried collagen scaffolds investigated in vitro and in vivo. *Biomaterials* **22**:429–38.

36 Surgical management of postpartum hemorrhage

Men-Jean Lee, Renata A. Sawyer, and Charles J. Lockwood

INTRODUCTION

Postpartum hemorrhage (PPH) is a common complication of vaginal and Caesarean deliveries and remains one of the top causes of maternal mortality in the United States and the number one cause worldwide (Say et al. 2014). This chapter is included because around the world, when massive hemorrhage occurs in the labor ward, gynecological cancer surgeons are often called upon to manage these difficult cases. There are several well-tested and effective pharmacotherapy options for early treatment (Table 36.1). Blood products are often needed and are crucial in resuscitative efforts. This chapter focuses on surgical treatment alternatives that are often the last resort, as well as blood conserving techniques and the role of interventional radiology (IR) procedures. Surgical techniques range from conservative measures; e.g., uterine tamponade methods and arterial ligation to total or supracervical hysterectomy.

UTERINE COMPRESSION SUTURES

Uterine atony is the number one cause of primary postpartum hemorrhage, defined as vaginal bleeding occurring within 24 hours of delivery. Bimanual massage is the first intervention in addition to uterotonics and a thorough exploration of the uterine cavity for retained placenta. Curettage, preferably utilizing a large curette, e.g., a Banjo curette, is useful to minimize uterine perforation. In cases of a vaginal birth, ultrasound guidance is helpful. A uterine tamponade balloon may be used (Figure 36.1). When the above measures and uterotonics fail to control the bleeding, laparotomy should be performed promptly, via a vertical midline or large transverse incision to optimize exposure. However, in centers with immediately available IR, this may be a faster and preferred option. An open abdomen allows for the introduction of ancillary tamponade methods such as the placement of uterine compression sutures. The most recognized technique is the B-Lynch uterine compression suture. Several modifications have been described, e.g. Pereira, Hayman, Cho, and multiple square suturing. B-Lynch compression suture was first performed in 1989 by Christopher B-Lynch in a patient with PPH who refused hysterectomy (B-Lynch et al. 1997).

B-Lynch Suture Technique

It is suggested to perform a brief "efficacy test" prior to performing the procedure (Allam and B-Lynch 2005). During the Caesarean or at laparotomy after a vaginal delivery, the patient is placed in the supine or low lithotomy position. If not already created during the Caesarean procedure, a bladder flap will need to be created. Bimanual compression is applied to the entire uterine fundus with the surgeon's hands respectively on the anterior and posterior wall, reaching from the top to the cervix level. If the compression stops or significantly improves the bleeding, one can proceed with the B-Lynch suture. The bimanual compression should be maintained by the assistant during the entire procedure. The original B-Lynch technique suggests that the hysterotomy site remains open during the suture placement. With the most commonly performed low transverse hysterotomy, the first suture originates about 3 cm inferiorly to the hysterotomy, at the lateral aspect of the incision, on either side (Figure 36.2). The suture should encompass the full thickness of the uterine wall. The suture then emerges about 3 cm superiorly to the uterine incision, ideally about 4 cm medial to the lateral uterine margin. The suture is then carried vertically and over the uterine fundus, simulating a "suspender." The needle is then reintroduced into the posterior uterine wall at the level of the insertion of the uterosacral ligament, drawing the suture horizontally within the uterine cavity, to emerge on the inner posterior uterine wall opposite the incision site. The suture is pulled under moderate tension assisted by manual compression exerted by an assistant. Another "suspender" is then created by reinserting the needle from inside the uterus through the posterior wall 4 cm across from the entry point on the opposite posterior side, leading the suture vertically over the fundus to the anterior uterine wall. The needle enters the uterine cavity about 3 cm superiorly to the left aspect of the hysterotomy and about 4 cm medially to the lateral uterine wall margin, in a maneuver symmetrical to what was performed on the other side of the uterus. The needle then emerges 3 cm inferiorly to the incision and both ends of the suture are tied while continuous bimanual compression is maintained by the assistant. The hysterotomy itself can be closed before or after the two ends of the B-Lynch suture are tied. If the former is chosen, even tension on both ends of the B-Lynch suture must be maintained during the closure (Allam and B-Lynch 2005).

The suture procedure is a simple and inexpensive, tamponade method that often effectively controls the hemorrhage while preserving fertility (B-Lynch 2015). A large (65- to 70-mm) curved tapered needle is preferred for B-Lynch suture placement to allow for easy incorporation of full thickness of uterine wall while traveling the distance of at least 6 centimeters. The suture material type is operator dependent; #1 chromic or catgut, or a #1 delayed, synthetic, monofilament suture on a large curved needle have been utilized. Most authors prefer the use of catgut or chromic suture material due to their faster absorption times (Barbieri 2012). The rationale for the fast absorption is that the tamponade is crucial only in the first hours after the procedure while hemostasis by thrombosis is being achieved. In addition, in the setting of relatively quick involution of the pregnant uterus to nonpregnant size, there is a theoretical risk for bowel entrapment from persistent dangling loops of persistent sutures if a delayed absorption suture was used. Regardless of the type of the suture used, it has to have a sufficient length to allow for full

Table 36.1 Commonly used medications for initial management of postpartum hemorrhage

Agent	Dose Details[a]	Comments
Repeat Oxytocin	IV 10–40 U/500 mL variable rate	Watch for hyponatremia
Methyergonovine (methergine)	IM 0.2 mg usually only once	Watch for hypertension
Protaglandin F2 alpha	IM 250 µg q15 min usually only twice	Watch for hypertension and wheezes
Misoprostol (cytotec)	per rectum 1000 µg; sublingual 800 µg; orally 600 µg	
Tranexamic acid	IV 1–2 grams	Watch for thrombosis

[a] Example before moving onto next medication.

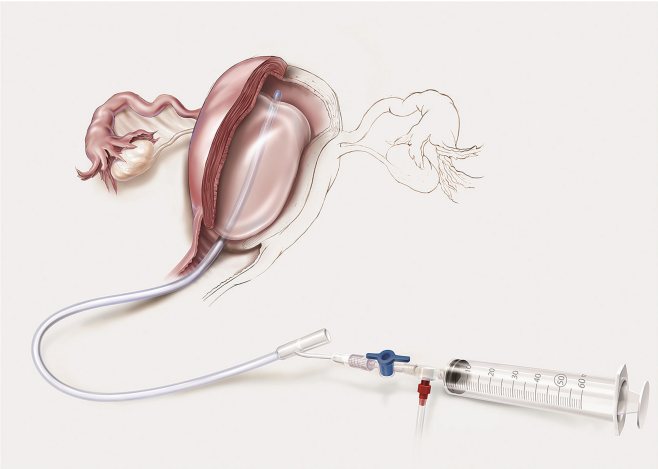

Figure 36.1 Bakri tamponade balloon. (Courtesy of Cook Medical, © Lisa Clark, MA, CMI.)

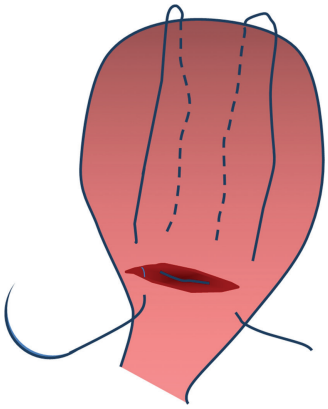

Figure 36.2 B-Lynch suture technique, anterior view. (From B-Lynch C. 2015. B-Lynch suture technique. Available at http://www.cblynch.co.uk/description-of-technique, accessed May 26, 2015).

encirclement of the uterus (e.g., 30 inches). The B-Lynch suture is performed through a Cesarean hysterotomy (or a uterine incision is made during an emergency laparotomy performed after a post-vaginal delivery hemorrhage) to avoid complications such as an obliteration of the cervical and/or uterine lumen which in turn could lead to pyometra and associated morbidity (Allam and B-Lynch 2005, Ochoa et al. 2002). In addition, hysterotomy allows for thorough inspection of the uterine cavity.

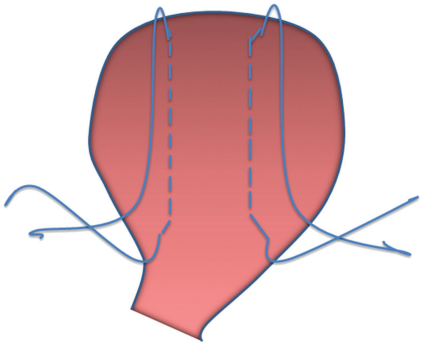

Figure 36.3 B-Lynch suture technique, posterior view. (From B-Lynch C. 2015. B-Lynch suture technique. Available at http://www.cblynch.co.uk/description-of-technique, accessed May 26, 2015).

Uterine atony may be noted after the hysterotomy closure in a Caesarean procedure. In this situation, some authors suggest placement of other types of compression sutures, e.g., Hayman or Pereira techniques (Nelson and Birch 2006) (Figure 36.3).

The success rate of the uterine compression sutures is reported to be 70% to 90%. However, the evidence to support efficacy is weak, primarily derived from observational studies and case series. One of the largest studies addressing this procedure, a prospective population-based study of 211 women who received various types of a compression suture (B-Lynch technique was most common) demonstrated 70% success rate (success was defined as avoidance of hysterectomy) (Kayem et al. 2011). No significant difference was found between B-Lynch and other techniques.

Compression Suture Postoperative Complications

The following complications have been reported in case reports and case series from the placement of uterine compression sutures: pyometra, hematometra, uterine synechiae and Asherman syndrome, focal necrosis, or defects in the uterine wall.

Evaluation of the uterine cavity (hysteroscopy, magnetic resonance imaging [MRI], hysterosalpingogram [HSG], saline infusion sonogram), remote from the time of delivery, has been suggested by several authors, particularly in patients desiring future fertility (Amorim-Costa et al. 2011, Barbieri 2012, Poujade et al. 2011).

BALLOON TAMPONADE

Another effective method of uterine tamponade is placement of the Bakri balloon (Cook® Medical Inc.; Bloomington, Indiana; Figure 36.1). The balloon was first described by Bakri and colleagues in 2001 (Bakri et al. 2001). It was demonstrated that the balloon was effective in controlling postpartum hemorrhage that originated from the placental site of the lower uterine segment as well as in controlling bleeding from the implantation site of cervical ectopic pregnancy. The balloon is now used widely in cases of uterine atony as well. The device consists of a 24 French, 54-cm long silicone catheter that is attached to a balloon which can be filled up to 500 mL of water to apply pressure to the uterine cavity. The catheter has distal side ports at the tip to allow for assessment of ongoing blood loss from above the balloon.

Placement Technique

1. The uterus should be first cleaned of all placental fragments. Any lacerations/arterial bleeding from the cervix need to be addressed prior to insertion of the catheter. Purulent infection of the uterus is a contraindication to the balloon placement.
2. The Bakri balloon is typically inserted transvaginally through the cervix in the setting of postpartum hemorrhage after a vaginal delivery.
3. If the hemorrhage occurs during a Cesarean delivery, transabdominal placement can be performed. The deflated tamponade balloon is passed retrograde through the hysterotomy into the uterine cavity; the inflation port is passed through the cervix to the vagina until the base of the balloon comes in contact with the internal cervical os. In the setting of a Caesarean delivery, it is suggested to close the hysterotomy site before inflating the balloon, to avoid the balloon rupture.
4. The balloon is then filled with sterile fluid, up to 500 mL, through the stopcock.
5. The vaginal canal may be packed with iodine- or antibiotic-soaked gauze.
6. The balloon shaft should be secured to the patient's leg under gentle traction.
7. The drainage port needs to be connected to the fluid collection bag.
8. The drainage ports and tubing should be periodically flushed with sterile fluid to clear any clots that may be occluding the tubing.
9. The balloon can stay in situ for up to 24 hours. The balloon is deflated with the inflation port with a syringe, then easily removed by applying gentle traction to the shaft.

The Bakri balloon can be used in combination with uterine compression sutures or uterine artery ligation techniques.

In the absence of the Bakri balloon, other methods of uterine tamponade may be used, such as packing of the uterine cavity with gauze (e.g., a 4-inch length gauze soaked in 5000 units of thrombin in 5 mL sterile saline [ACOG Practice Bulletin #76, October 2006]), a Sengstaken catheter (typically used for esophageal varices bleeding) or multiple Foley bulbs (one Foley balloon may be insufficient due to its small size). Care must be taken to document the total number of items left in the uterus to help ensure complete removal after hemostasis is achieved. Moistening the retained articles with hot normal saline and slow extraction may help avoid restarting the bleeding from disrupting clots in the removal process. In cases of uncontrolled surface bleeding, as can occur in placenta accreta, hemostatic agents such as Floseal (Baxter International Inc., Fremont, Calif., USA) or Surgicel (Johnson & Johnson, New Brunswick, NJ, USA) can also be used. These other methods of intrauterine tamponade represent off-label use of those medications.

ARTERIAL LIGATION

Arterial ligation aims to decrease the uterine perfusion to decrease bleeding from the uterine cavity. Several vessels may be ligated, including uterine, utero-ovarian, and hypogastric arteries. The latter procedure may be technically difficult for a general obstetrician-gynecologist and requires the expertise of physicians skilled in pelvic dissection; e.g., gynecologic oncologists or vascular surgeons. Ligation of the internal iliac artery poses a risk of injury to the ureter, to the internal iliac vein, which is difficult to repair, as well as the risk of erroneous ligation of the external iliac artery, which in turn can lead to an ischemia of the lower extremity. The artery should be mobilized with the clamp manipulated laterally to medially, with the tip of the clamp pointing away from the internal iliac vein (Steer 2009). The effectiveness of this procedure is relatively low; in a case series of 19 patients with PPH, hysterectomy was avoided in 42% of cases (Clark et al. 1985). At least four of these six branches supplying the uterus can likely be performed without significant risk of necrosis.

Bilateral ligation of the ascending branch of the uterine artery (O'Leary suture; Figure 36.4) is a simple technique of decreasing the flow of blood into the uterus (O'Leary and O'Leary 1974). The technique is as follows:

1. The uterus is grasped and elevated from the pelvis. If a low transverse hysterotomy was previously performed, the sutures are placed below the level of the incision.
2. A large atraumatic needle with #1 delayed absorbable suture is passed through the myometrium from anterior to posterior, with the point of entry 2 to 3 cm medially to the ascending branch of the uterine artery.
3. The needle exits from posterior to anterior through the avascular area of the broad ligament.
4. The suture is then tied. It is important to place the suture as close to the uterus as possible, given that the ureter is usually 1 cm lateral to the artery.
5. The opposite side is performed in reverse, with entry starting from the posterior uterine wall below the Caesarean incision or the insertion of the uterine artery.

Inclusion of a portion of myometrium in the O'Leary suture allows for occlusion of some of the inferior branches of the uterine artery (O'Leary and O'Leary 1974). Utero-ovarian arteries are ligated immediately below the juncture of the ovarian suspensory ligament with the uterus.

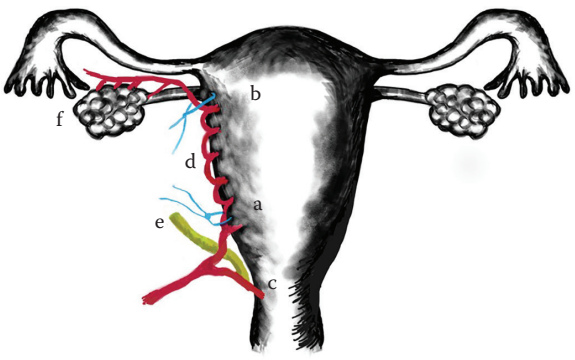

Figure 36.4 Anatomy of uterine and uteroovarian artery ligation (a = site of uterine artery ligation or O'Leary suture; b = uteroovarian artery ligation; c = vaginal artery; d = uterine artery; e = ureter; f = ovary).

Aortal compression can also be used while awaiting expert assistance, decreasing the bleeding from the uterus by around 40%. Clamping the aorta below the renal arteries may be performed by a surgeon skilled in vascular procedures; the clamp may stay in situ for up to 4 hours (Steer 2009). However, the shortest amount of time needed is greatly preferred. Even after only minutes of aortal occlusion, ischemia-related release of intracellular potassium and other serum consequences from the lower extremities carry the risk of intraoperative sudden cardiac death. Intermittent manual occlusion, i.e., thumb compression, may be a safer initial technique. Reperfusion lower extremity injury and systemic consequences must be monitored and managed proactively; e.g., frequent blood analysis, ICU, and extremity elevation.

The uterine artery ligation and utero-ovarian artery ligation can be combined with the compression techniques.

The combination of ligation sutures with the compression suture may have a higher rate of uterine ischemia and necrosis than when the ligation sutures are used with the tamponade balloon (Fotopoulou and Dudenhausen 2010).

Uterine ligation sutures do not appear to significantly compromise future fertility and pregnancy outcomes, but complications have been reported. Recanalization to a normal uterine circulation and return of menses is expected after the ligation procedures. In a cohort of 32 patients with a relatively long follow-up, all but 4 had a return of normal menses. Two had amenorrhea/ovarian failure (suspensory ligament of ovary was ligated in these cases), and there was one case of uterine synechiae and one report of uterine wall necrosis (Sentilhes et al. 2008).

HYSTERECTOMY

Caesarean hysterectomy and postpartum hysterectomy require a multidisciplinary approach, including the gynecologic surgeon(s), anesthesiologist, and blood bank assistance. Due to the heightened awareness that postpartum hemorrhage is a leading cause of maternal death, many institutions have developed "massive transfusion protocols" to facilitate rapid treatment of this emergency condition. Hysterectomy should be promptly undertaken if the aforementioned hemorrhage control methods and uterotonics are failing to control bleeding. Patients particularly at risk for postpartum hysterectomy are multiparous with a history of a Caesarean (or undergoing their first Caesarean in the index pregnancy) and who have suspected abnormal placentation such as a placenta accreta, increta, or percreta (Rossi et al. 2010). In the latter, Caesarean hysterectomy is often a planned procedure. A helpful adjunct to the massive transfusion protocols is the use of thromboelastometry; e.g., ROTEM, to assess hemostasis to direct blood product replacement. There are many versions of this intraoperative rapid assessment of coagulation status for use in the operating room as directed by the anesthesiologist.

Supracervical hysterectomy is often sufficient and is preferred if bleeding is controlled, given the increased risk of pelvic organ injury and morbidity associated with total hysterectomy (e.g., ureter or bladder injury). Postpartum hysterectomy poses challenges that are not present in a nongravid state: enlarged uterus, increased blood supply to the pelvic organs, engorged blood vessels that may be difficult to ligate, friable pregnant tissues, and dilation/effacement of the cervix which makes identification of the external os difficult (Matthews and Rebarber 2010).

Caesarean Hysterectomy Technique

1. Ideally, a vertical skin incision should be used to maximize exposure, particularly in cases when the index of suspicion for an abnormal placentation is high. Alternatively, the initial transverse incision should be extended prior to the start of hysterectomy.
2. In cases of suspected abnormal placentation, intraoperative ultrasound guidance is useful in placental mapping and avoiding cutting through the placenta during the hysterotomy. After the fetus is delivered, the hysterotomy site should be closed to minimize bleeding.
3. A bladder flap should be created if not previously done. Sharp dissection is preferred to blunt dissection with a sponge stick. The latter may lead to increase in bleeding and potentially increases the risk for a bladder injury.
4. Large abdominal retractor, e.g., Bookwalter or Balfour, should be used.
5. Round ligaments are tented upward with a Babcock, doubly clamped, cut, and ligated with a transfixing suture of 0-Vicryl.
6. The broad ligament is then perforated in an avascular region with electrocautery and the Fallopian tube, utero-ovarian ligament, and ovarian vessels are clamped near the uterus with two or three clamps (e.g., Heaney, Masterson, or curved Zeppelin clamp). The tissue between the clamps is cut and the pedicles ligated. The lateral pedicle, i.e., proximal blood supply side, should be doubly ligated with a free tie followed by a transfixing suture placed distally.
7. Uterine vessels are then skeletonized and clamped with two or three clamps (Heaney, Masterson, or curved Zeppelin) at right angle to the vessels. The vessels are then transected and suture ligated.
8. If a supracervical hysterectomy is being performed, the uterine fundus is amputated with scissors or electrocautery. The cervical margins are oversewn with running locked or figure-of-eight sutures.
9. If the decision is made to remove the cervix, the dissection is carried out anteriorly to mobilize the bladder.
10. The cardinal ligaments are clamped, cut, and suture ligated until the external cervical os is reached. Curved or straight Heaney clamps, Ballentine, or Zeppelin clamps can be used at this stage. Attention should be paid at all times to avoid the ureters and the bladder.
11. The uterosacral ligaments are clamped into a bundle with a large curved Heaney or Zeppelin clamp; the vagina is then severed with the Mayo scissors and the pedicles suture ligated and sutured to the cardinal ligament pedicle to provide support for the cuff. The vaginal cuff is then closed in a running fashion.
12. The abdomen is closed after ensuring adequate hemostasis.

If venous bleeding from the pelvic floor continues after hysterectomy, a tamponade technique may be used while enlisting assistance from gynecology oncologists, vascular surgeons, or interventional radiologists, while any coagulopathy is being corrected. The technique, known as the Logothetopulos pack, is as follows: a large sterile plastic bag is filled with gauze; the neck of the bag is firmly tied with a Penrose or similar tubing, which is passed through the vagina and attached to a bag of fluid and allowed to freely hang over the bed, facilitating tamponade of the pelvic floor (Steer 2009, Robie et al. 1990). A similar effect may be achieved by opening a large square gauze sponge and using it as a "parachute," filling it with individual large gauze sponges. Each gauze can be brought out of the vagina separately or by tying all the loop material attachments together. We prefer to pass the loops separately so that they may be extracted separately and at different times. Again, soaking the sponges with hot saline prior to their removal may facilitate the process.

INTRAOPERATIVE CELL SALVAGE (ICS) SYSTEMS

A select group of patients can be identified antenatally to be at risk for massive intrapartum and postpartum hemorrhage, namely those women with abnormal placentation such as placenta previa and those with suspected placenta accreta, placenta increta, and placenta percreta. These women are excellent candidates for intraoperative autologous blood transfusion with a cell salvage system, or "Cell Saver" technology. In addition, pregnant women who are identified prenatally to refuse allogeneic blood transfusion due to religious reasons, such as Jehovah's Witnesses, may be willing to accept a cell salvage program.

There are two broad classes of ICS systems (Freischlag 2004):

1. *Hemofiltration only*—These devices only collect the lost blood, filter out large particulate matter, and reinfuse it. The system returns whole blood with coagulation factors and platelets into the patient. However, smaller harmful debris or contaminants are not filtered out.
2. *Red blood cell washing device*—These units collect the shed blood, centrifugally separate out the red blood cells (RBCs), wash out contaminants, and then reinfuse RBCs back into the patient. The RBC washing devices theoretically can remove contaminating debris or other inflammatory mediators before transfusion.

The RBC washing unit is the system that has been adopted for use in the management obstetrical hemorrhage due to concerns over iatrogenic amniotic fluid embolism (Liumbruno et al. 2011). There are a variety of cell salvage systems being manufactured; they all consist of a circuit that includes collection, anticoagulation, washing, separation, and reinfusion (Allum et al. 2008).

The ICS system is typically set up intraoperatively with two sets of suction tubing—one to use for amniotic fluid suction at the time of ruptured membranes, and another to suction off the free-flowing blood from the surgical site (No Blood Editorial Team 2015). The typical closed-circuit system used for the blood salvage starts with a double-lumen anticoagulated suction tubing that aspirates the blood into a collection reservoir that washes the RBCs with saline and differentially separates the RBCs from the other components before transfer into a reinfusion bag for transfusion back into the patient. The cell salvage system used in obstetrics includes a series of filters before the centrifugation process which separates debris such as amniocytes and fat, and dangerous contaminants such as the potent procoagulant, tissue factor (Bernstein et al. 1997). In addition, a leukocyte depletion filter can be placed in the circuit between the reinfusion bag and transfusion to the patient to prevent other transfusion reactions. The series of washing, filtration, and concentration of the recycled RBCs removes approximately 70% to 90% of soluble contaminants and prepares a saline suspension of RBCs with a hematocrit of 50% to 80% (Liumbruno et al. 2011). The cell salvage system is limited to free-flowing blood at the surgical site, although some authors have reported salvaging blood from blood-soaked laparotomy sponges that have been placed in sterile, anticoagulated saline (Allum et al. 2008). Other investigators are evaluating the safety of ICS systems in the setting of postpartum vaginal hemorrhage following vaginal births where infectious microbial contamination is more of a concern (Teare et al. 2015).

Use of any of the ICS systems requires a hospital that has access to the equipment, as well as availability of trained personnel to run the device. The cost-effectiveness of acquiring and running such a system has been frequently questioned. ICS has been used in cardiovascular surgery when anticipated blood loss and the need to reinfuse blood is routine. However, its use in obstetrical hemorrhage has been limited to planned caesarean surgeries with or without hysterectomy to make the ICS System and training of personnel with actual RBC units reinfused more cost-effective than using it in a "stand-by" mode (Liumbruno et al. 2011).

UTERINE ARTERY EMBOLIZATION/OCCLUSION

Postpartum hemorrhage occurs in a variety of clinical scenarios, including:

- Expected intraoperative hemorrhage due to preoperative diagnosis of placenta previa, placenta accreta, and its subsets for patients undergoing Caesarean delivery
- Subacute postpartum hemorrhage due to expanding pelvic hematomas, intraabdominal bleeding following surgery, delayed vaginal bleeding, or recurrent vaginal bleeding due to other vascular or hematologic defect.

Interventional radiologic (IR) procedures using transcatheter endovascular techniques such as prophylactic balloon catheter tamponade of the pelvic vessels and selective uterine artery embolization are emerging as valuable adjuncts to surgical management of postpartum hemorrhage (Angstmann et al. 2010), particularly in an attempt to minimize blood loss in the setting of an emergency hysterectomy or for fertility preservation in the younger gravida.

For antenatally diagnosed complete placenta previa in the setting of a prior caesarean delivery or a high suspicion for placenta accreta, increta, percreta diagnosed by sonogram or magnetic resonance imaging (MRI), one consideration in surgical planning is the use of temporary balloon catheter for temporary

occlusion of the internal iliac arteries to decrease the pulse pressure to the uterus immediately after delivery of the fetus. On the morning of the scheduled Caesarean delivery, the patient is taken to the IR suite for placement of two 6- or 7-French sheaths into bilateral common femoral arteries under ultrasound guidance. Two 6- or 7-mm diameter 20- or 40-mm long semicompliant balloon catheters are inserted through the sheaths into each contralateral internal iliac artery, and reduction of perfusion is tested by temporary inflation of the balloons to a maximum of 2 mL by fluoroscopy. The sheath/balloon catheter system is then sterilely flushed with heparin, sutured with 3-0 suture, and covered with an occlusive dressing to prevent dislodgement during patient transport to the operating room (Angstmann et al. 2010, Carnevale et al. 2011, Vinas et al. 2014).

Immediately after delivery of the fetus and umbilical cord clamping, the previously inserted bilateral balloon catheters are inflated to tamponade blood flow to the uterus while the obstetrician completes the Caesarean surgical procedure with or without removal of the placenta, with or without hysterectomy. Once the procedure is completed, the balloons should be deflated before abdominal closure so that bleeding from the operative sites can be assessed. If persistent bleeding is suspected despite surgical management, the vascular sheaths can be reaccessed and the balloon occlusion catheters can be exchanged for angiographic catheters to facilitate embolization. If there is no further evidence of bleeding following the Caesarean delivery, the femoral sheaths and catheters can be removed the next day by the interventional radiologist with sealing of the femoral puncture sites, pressure dressings, and continuous pressure on both groins.

To control subacute postpartum bleeding, either postsurgical intraabdominal bleeding or vaginal bleeding, the patient can be transferred to the IR suite, 4- to 5-French bilateral introducers can be inserted using the Saldinger technique, and selective angiography of bilateral internal iliac arteries is performed to map out the vascular anatomy of the anterior division of the internal iliac arteries and localize the bleeding sites of extravasation using 4- to 5-French angiographic catheters and appropriate guidewires (Cali et al. 2014, Vinas et al. 2014). The uterine arteries can be selectively identified endovascularly by microcatheters, and particulate occlusive agents such as 500- to 700-micrometer polyvinylalcohol particles, gel foam/gelatin sponge pledgets, and Spongegel can be injected into the bleeding vessel (Angstmann et al. 2010, Pinto et al. 2012, Salazar et al. 2009). Fiber coils and vascular plugs with polymerizing agents such as N-butyl cyanoacrylate and Onyx (MicroTherapeutics, Inc, Irvine CA, USA) may be used to occlude larger vascular anomalies such as aneurysms or arteriovenous malformations (Salazar et al. 2009).

Complications of these endovascular catheterization technique include rare distal thrombosis, hematomas, and pseudoaneurysms at the catheterization site. Theoretic concerns include unnecessary exposure of the fetus to radiation from the prophylactic catheter placement and technical malfunction of the catheterization equipment.

Surgical management of postpartum hemorrhage requires a thorough knowledge of pelvic anatomy, vascular perfusion, and pathophysiology of pregnancy. Fortunately, lifesaving surgical interventions such as hysterectomy, compression sutures, integration of the Bakri balloon, ICS systems, and new cutting-edge technologies such as endovascular catheterization procedures from the field of IR, provide multiple methods to treat postpartum hemorrhage, prevent additional maternal morbidity, and potentially preserve fertility in a young gravida.

SUMMARY

Postpartum hemorrhage is typically managed with pharmacologic therapy and uterine massage. However, if those maneuvers are unsuccessful, surgical intervention, balloon tamponade, and IR techniques are lifesaving. Furthermore, for those women who are at high risk for postpartum hemorrhage due to a suspected morbidly adherent placenta, ICS systems as well as preoperative interventional radiological balloon tamponade may be considered.

REFERENCES

ACOG Practice Bulletin #76, October 2006.

Allam MS, B-Lynch C. 2005. The B-Lynch and other uterine compression suture techniques. *Int J Gynaecol Obstet* **89**:236–41.

Allum J, Cox M, Yentis SM. 2008. Cell salvage in obstetrics. *Int J Obstet Anesth* **17**:37–45.

Amorim-Costa C, Mota R, Rebelo C, et al. 2011. Uterine compression sutures for postpartum hemorrhage: Is routine postoperative cavity evaluation needed? *ACTA Obstet Gynecolog Scand* **90**(7):701–6.

Angstmann T, Gard G, Harrington T, et al. 2010. Surgical management of placenta accreta: A cohort series and suggested approach. *Am J Obstet Gyne*col **202**:38.e1–9.

Bakri YN, Amri A, Abdul Jabbar F. 2001. Tamponade-balloon for obstetrical bleeding. *Int J Gynaecol Obstet* **74**(2):139–42.

Barbieri RL. 2012. A stitch in time: The B-Lynch, Hayman, and Pereira uterine compression sutures. *OBG Management* **24**:12.

Bernstein HH, Rosenblatt MA, Gettes M, et al. 1997. The ability of the Haemonetics@ 4 Cell Saver System to remove tissue factor from blood contaminated with amniotic fluid. *Anesth Analg* **85**: 831–3.

B-Lynch C. 2015. B-Lynch suture technique. Available at http://www.cblynch.co.uk/description-of-technique (accessed May 26, 2015).

B-Lynch C, Coker A, Lawal A, et al. 1997. The B-Lynch surgical technique for the control of massive postpartum hemorrhage: An alternative to hysterectomy? Five cases reported. *Br J Obstet Gynaecol* **104**:372–5.

Cali G, Forlani F, Giambanco L, et al. 2014. Prophylactic use of intravascular balloon catheters in women with placenta accreta, increta and percreta. *Eur J Obstet Gynecol Reprod Biol* **179**:36–41.

Carnevale FC, Kondo MM, Sousa Jr WO, et al. 2011. Perioperative temporary occlusion of the internal iliac arteries as prophylaxis in cesarean section at risk of hemorrhage in placenta accreta. *Cardiovasc Intervent Radiol* **34**:758–64.

Clark AL, Phelan JP, Yeh SY, et al. 1985. Hypogastric artery ligation for obstetric hemorrhage. *Obstet Gynecol* **66**(3):353–6.

Fotopoulou C, Dudenhausen JW. 2010. Uterine compression sutures for preserving fertility in severe postpartum hemorrhage: An overview 13 years after the first description. *J Obstet Gynaecol* **30**(4):339–49.

Freischlag JA. 2004. Intraoperative blood salvage in vascular surgery—Worth the effort? *Critical Care* **8**(Suppl 2):S53–6. DOI 10.1186/cc2409.

Kayem G, et al. 2011. Uterine compression sutures for the management of severe postpartum hemorrhage. *Obstet Gynecol* **117**:14–20.

Liumbruno GM, Meschini A, Liumbruno C, et al. 2011. The introduction of intra-operative cell salvage in obstetric clinical practice: A review of the available evidence. *Eur J Obstet Gynecol Reprod Biol* **159**:19–25.

Matthews G, Rebarber A. 2010. Practical perspective on Cesarean hysterectomy: when, why, and how. *Contemp Ob Gyn* **55**(5):30–40.

Nelson GS, Birch C. 2006. Compression sutures for uterine atomy and hemorrhage following cesarean delivery. *Int J Gynaecol Obstet* **92**:248–50.

No Blood Editorial Team. 2015. Cell Saver—The procedure step by step. http://noblood.org/forum/content/165-Cell_Saver (accessed July 4, 2015).

Ochoa M, Allaire AD, Stitley ML. 2002. Pyometria after hemostatic square suture technique. *Obstet Gynecol* **99**:506–9.

O'Leary JL, O'Leary JA. 1974. Uterine artery ligation for control of postcesarean section hemorrhage. *Obstet Gynecol* **43**:849–53.

Pinto A, Niola R, Brunese L, et al. 2012. Postpartum hemorrhage: What every radiologist needs to know. *Curr Probl Diagn Radiol* **41**:102–10.

Poujade O, Grossetti A, Mougel L, et al. 2011. Risk of synechiae following uterine compression sutures in the management of major postpartum haemorrhage. *BJOG* **118**(4):433–9.

Robie GF, Morgan MA, Payne GG, Jr, et al. 1990. Logethotopulos pack for the management of uncontrollable postpartum hemorrhage. *Am J Perinatol* **4**:327–8.

Rossi AC, Lee RH, Chmait RH. 2010. Emergency postpartum hysterectomy for uncontrolled postpartum bleeding. A systematic review. *Obstet Gynecol* **115**:637–44.

Salazar GMM, Petrozza JC, Walker TG. 2009. Transcatheter endovascular techniques for management of obstetrical and gynecologic emergencies. *Tech Vasc Interventional Radiol* **12**:139–47.

Say L, et al. 2014. Global causes of maternal death: A WHO systematic analysis. *Lancet Global Health* **2**(6):e323−33.

Sentilhes L, et al. 2008. Fertility and pregnancy outcomes following uterine devascularization for severe postpartum haemorrhage. *Hum Reprod* **23**(5):1087–92.

Steer PJ. 2009. The surgical approach to postpartum hemorrhage. *TOG* **1**1:231–8.

Teare KM, Sullivan IJ, Ralph CJ. 2015. Is cell salvaged vaginal blood loss suitable for re-infusion? *Int J Obstet Anesth* **24**:103–10.

Vinas MT, Chandraharan E, Moneta MV, et al. 2014. The role of interventional radiology in reducing haemorrhage and hysterectomy following caesarean section for morbidly adherent placenta. *Clin Radiol* **69**:e345–51.

37 Brachytherapy

Matthew Harkenrider, Fiori Alite, and William Small, Jr.

INTRODUCTION

Radiation therapy is one of several modalities of cancer care that can be used as a definitive, neoadjuvant or adjuvant, or palliative agent. Radiation therapy can be broadly categorized as either teletherapy (*tele*, Greek for far) or brachytherapy (*brachy*, Greek for near). Teletherapy can be delivered by a linear accelerator or by a radioactive source in the treatment machine such as a Cobalt-60 unit. Brachytherapy most commonly utilizes radioactive sources placed in a patient cavity (intracavitary) and/or in patient tissues (interstitial). Additionally, radiation sources can be placed on or near the surface of an organ. This technique is used commonly to treat skin cancer or malignancies of the eye. Both intracavitary and interstitial applications of brachytherapy are integral to treat malignancies of the gynecologic tract.

The purpose of this chapter is to outline the various disease sites, applicators, techniques, and treatment planning for gynecologic brachytherapy.

BRACHYTHERAPY TECHNIQUES

Dose Rate

Brachytherapy can be delivered with high dose rate (HDR), low dose rate (LDR), or pulsed dose rate (PDR). HDR delivers dose at a quick rate, and a single treatment usually takes minutes to deliver. LDR delivers dose slowly and usually takes days to deliver a treatment. Fewer total treatments are therefore done when LDR is being performed. PDR uses a combination of the techniques as it delivers pulses of HDR brachytherapy over a period of time that can last many hours to days.

Intracavitary Brachytherapy

Gynecologic intracavitary brachytherapy generally involves placing an applicator through the cervical os into the uterine cavity, in the vaginal canal or vaginal fornices, or both. There are numerous applicators that can be chosen by the brachytherapist to individualize treatment delivery for the patient. Intracavitary brachytherapy for cervical cancer is a necessary component of treatment following external beam radiotherapy (EBRT) for locally-advanced disease (Eifel et al. 1994, Perez et al. 1983, Tanderup et al. 2014, Viswanathan et al. 2009). Commonly used applicators for intracavitary cervical brachytherapy include tandem and ovoids, tandem and ring, tandem and vaginal mold, tandem and cylinder, and Miami applicator (tandem and multichannel cylinder). Commonly used intracavitary brachytherapy applicators are shown in Figure 37.1A. These applicators can be placed in the operating room with general anesthesia or in a brachytherapy suite with deep or conscious sedation.

For endometrial cancer, after hysterectomy, intracavitary vaginal brachytherapy (VBT) with a vaginal cylinder or other applicator may be utilized to decrease the risk of a vaginal cuff failure. These applicators do not require anesthesia for placement. For unresectable endometrial cancer, intracavitary brachytherapy can be performed with one or multiple tandems placed into the uterus with general anesthesia or in a brachytherapy suite with deep or conscious sedation.

Vaginal cancer can be treated with an intracavity single- or multichannel vaginal cylinder for superficial and early stage tumors (Chyle et al. 1996, Jang et al. 2012, Nonaka et al. 2013, Vargo et al. 2015). Interstitial brachytherapy should be performed for locally advanced and deeply invasive vaginal cancer (Beriwal et al. 2012, Chyle et al. 1996, Dimopoulos et al. 2012). Brachytherapy for vulvar cancer can be performed with interstitial techniques, though there is potentially an increased risk of necrosis with brachytherapy for vulvar cancer compared to other gynecologic sites (Tewari et al. 1999).

Intracavitary applicators are universally computed tomography (CT) compatible and many are made of plastic or titanium for magnetic resonance imaging (MRI) compatibility. Both HDR and LDR applications can be performed with intracavitary applicators, though the devices are not interchangeable to be both HDR and LDR compatible.

Interstitial Brachytherapy

Interstitial brachytherapy involves placement of catheters into or surrounding a tumor. In gynecologic cancers, these catheters are most commonly needles that are placed through a perineal template to optimize proper needle spacing. Figure 37.1B shows interstitial templates with the vaginal obturator and intrauterine tandems. The vaginal obturator acts as an anchor for the template and a guide for the needles that are most proximate to the vagina. For patients with an intact uterus, an intrauterine tandem can be placed through the cervix with the obturator placed over the tandem. This allows for dose to be delivered to the uterus and cervix, as in cases of locally advanced or recurrent cervical cancer with parametrial or pelvic sidewall involvement.

More recently applicators have been developed that combine intracavitary and interstitial techniques, known as hybrid applicators. These applicators have been developed by groups from Vienna and Utrecht and named after those cities, respectively. These applicators can be seen in Figure 37.1C. These applicators use an intrauterine tandem and vaginal ring (Vienna) or ovoids (Utrecht) which act as a template for interstitial needles to be placed improving the geometry of the implant (Kirisits et al. 2006, Nomden et al. 2012). They allow for additional customization of treatment and are recommended for patients with parametrial or pelvic sidewall extension, large or bulky cervical tumors, and those with poor response to initial EBRT (Dimopoulos et al. 2006).

Choice of technique and applicator is important because every patient, tumor, and response to EBRT is different. An array of applicators allows the brachytherapist to individualize treatment.

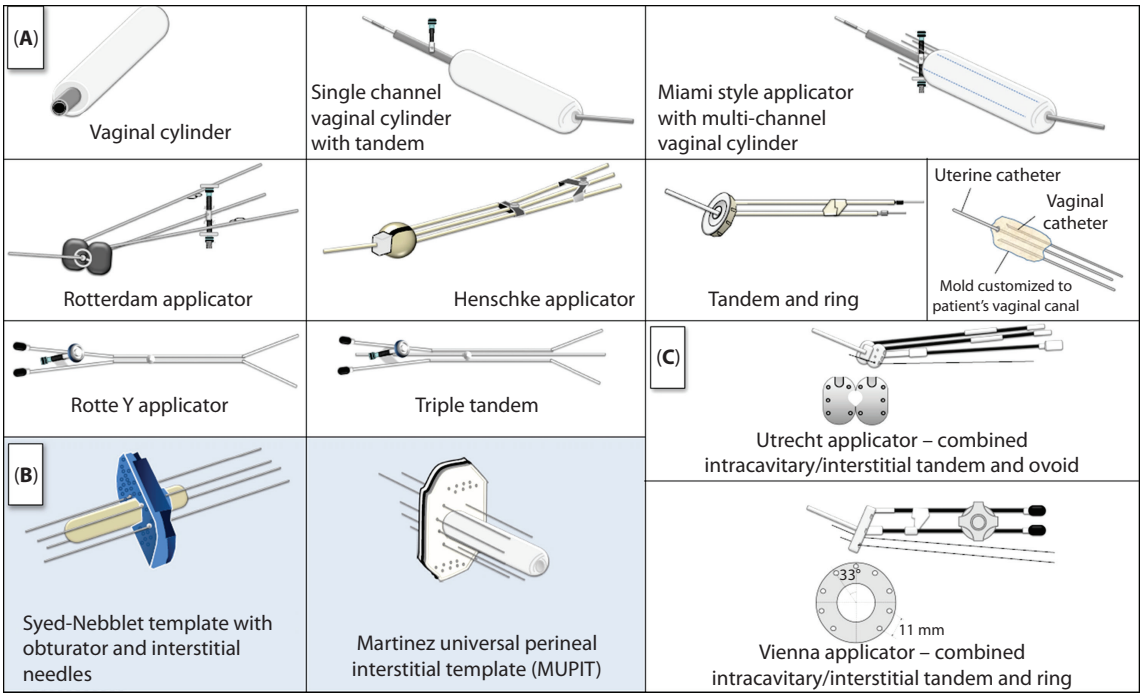

Figure 37.1 Common intracavitary (**A**) vaginal, cervical, endometrial); (**B**) interstitial, and (**C**) hybrid intracavitary/interstitial applicators. (Image modified and reproduced from Harkenrider MM, Grover S, Erickson BA, et al. 2015, *Brachytherapy* 2016; **15**(1):23–9. With permission.)

BRACHYTHERAPY BY MALIGNANCY

Cervical Cancer

Cervical cancer is an international malignancy that is the deadliest cancer in many developing nations. Early stage disease (FIGO IA-IB1) is most commonly treated surgically, routinely with radical or modified radical hysterectomy with pelvic and para-aortic lymph node dissection. Locally advanced disease (FIGO IB2-IVA and/or node positive) is standardly treated with radiation theraphy (RT) (with or without para-aortic nodal RT) with concurrent cisplatin chemotherapy (Bachaud et al. 1991, Barillot et al. 1997, Eifel et al. 2004, Landoni et al. 1997, Morris et al. 1999, Newton 1975, Rose et al. 2007, Rotman et al. 1990). Brachytherapy is a crucial component of the treatment course for curable cervical cancer patients. Han et al. (2013) demonstrated that utilization of brachytherapy is decreasing in the United States. Those patients not undergoing brachytherapy have a comparative decrease in overall survival (Eifel et al. 1994, Perez et al. 1983, Tanderup et al. 2014, Viswanathan et al. 2009). In addition, increased brachytherapy dose and quality implants have been shown to improve overall survival and disease-free survival, respectively (Viswanathan et al. 2009, Viswanathan et al. 2012b). Despite the progresses of external beam radiotherapy, brachytherapy affords patients outcomes that cannot be matched with other modalities of radiotherapy.

The goal of brachytherapy for cervical cancer is to choose a procedure and corresponding applicator to deliver the desired dose to the tumor and at-risk adjacent structures. Point A is an artificial point within the patient using the superior phlange or midpoint of the superior ovoid/ring as the starting point; it is located 2 cm superior along the angle of the tandem and 2 cm perpendicularly lateral toward the pelvic sidewall (Figures 37.2, 37.3). Point A dose is a way to compare and unify dose prescription for patients receiving LDR versus HDR or different dose-fractionation schedules (Tod and Meredith 1938, Wilkinson and Ramachandran 1989). Another way to prescribe brachytherapy dose in cervical cancer is milligram radium equivalent-hours. This method uses the total implant activity (unit of milligram radium equivalent) multiplied by the number of hours the implant is loaded. Advocates of this method prefer the direct manipulation of the two factors that affect dose—activity and time (Pierquin 1964, Walstam 1954). Both of these methods can be planned with dose prescribed based on orthogonal planar x-rays.

More recently, the use of volumetric imaging to design and even individualize treatment plans has increased. Image-based brachytherapy can be performed with ultrasound, CT, and MRI. Figure 37.4 shows x-ray-, CT-, and MRI-based planning images.

CT-based brachytherapy has shown to decrease severe (grade 3–4) toxicity, and MRI-based brachytherapy further evolved to improve the way in which dose is prescribed and treatment plans are optimized (Charra-Brunaud et al. 2012, Kang et al. 2010, Wachter-Gerstner et al. 2003). Applicators have been developed which are made of plastic or titanium, making them MRI compatible, so images can be obtained with the applicator in place. MRI, preferably T2-weighted sequences, allows for better soft tissue delineation of any residual gross tumor volume (GTV), peritumoral "gray zones" with intermediate signal, and the cervix. These three regions comprise the high-risk clinical target volume (HR-CTV) and is a common way to prescribe dose when MRI-based brachytherapy is performed (Haie-Meder et al. 2005, Potter et al. 2006).

Cervical cancer is most commonly treated with intracavitary brachytherapy. There are several different applicators that accomplish the goals of intracavitary brachytherapy, many

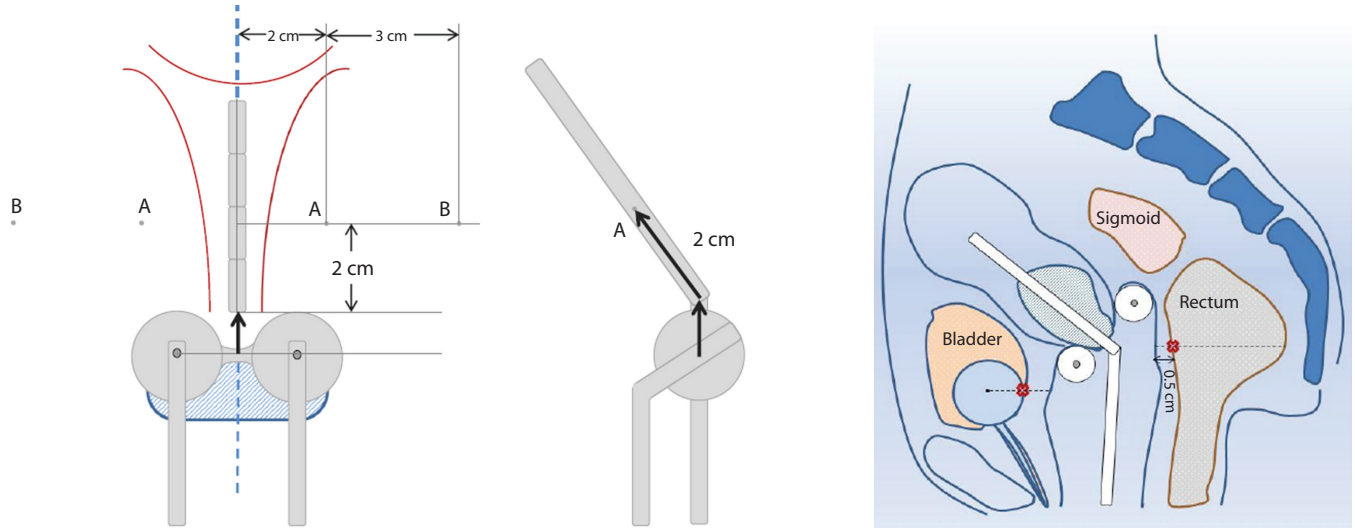

Figure 37.2 Location of point A, point B, bladder point, and rectal point. (Image modified and reproduced from Harkenrider MM, Grover S, Erickson BA, et al. 2015, *Brachytherapy* 2016; **15**(1):23–9. With permission.)

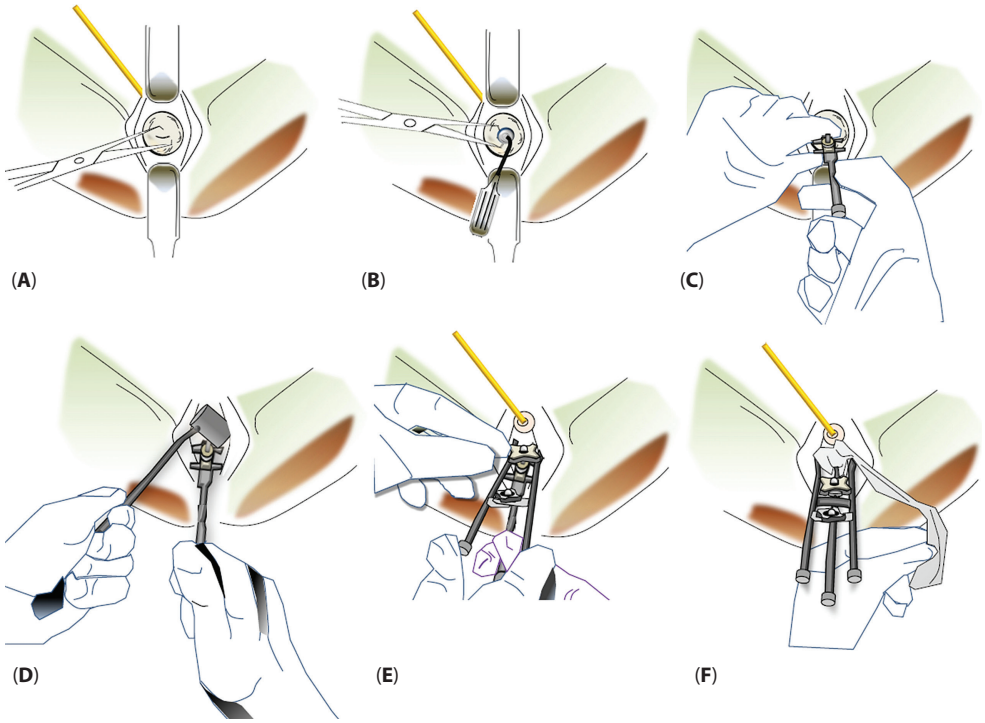

Figure 37.3 Placement steps of the Intracavitary tandem and ovoid applicator. (**A**) With Foley catheter in place, insert right angle retractors, and grasp cervix with a tenaculum. (**B**) Pull to straighten uterine canal and insert sound to measure length and curve of uterine canal. (**C**) Affix phlange at the sounded distance on the tandem. Insert tandem through cervical os and check position with ultrasound guidance. (**D**) Lubricate and insert right and left ovoids, while ensuring that tandem is grasped in position throughout. (**E**) Adjust rotation angle of tandem and ovoids and separate ovoids laterally in the vaginal fornices ensuring that the tandem bisects the ovoids. Then tighten screws to secure the system. (**F**) Pack slowly in even segments of gauze along anterior and posterior wall of vagina and against the phlange then filling the vagina, leaving a few inches of packing accessible outside vagina.

of which are shown in Figure 37.1. The goal of intracavitary brachytherapy is to surround the tumor and cervix with the applicator so that a very high radiation dose can be delivered.

The steps for classic placement of the intracavitary applicator are shown in Table 37.1. The procedure is routinely performed under anesthesia, ranging from conscious sedation to general anesthesia. A good examination under anesthesia is important prior to the procedure, as this will direct treatment planning. Manual and visual examination of the cervix and extent of tumor should be performed. Location and amount of extension to the vagina should be noted. A rectovaginal examination should focus on presence and extent of parametrial or pelvic sidewall involvement. If there is significant parametrial involvement or extension to the pelvic sidewall, then interstitial brachytherapy should be considered. Once prepped and draped, the cervix should be visualized and grasped with a tenaculum.

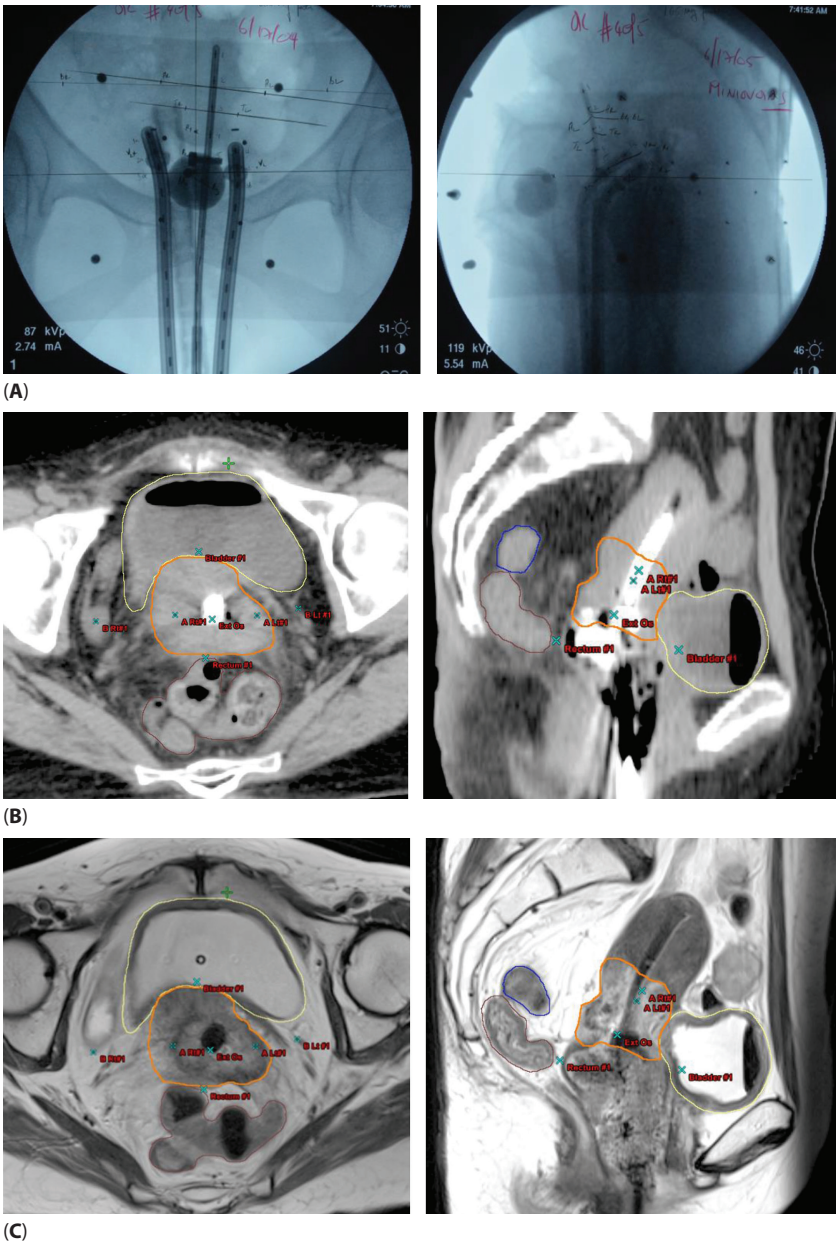

Figure 37.4 (**A**) X-ray-, (**B**) CT-, and (**C**) MRI-based planning images. (Image modified and reproduced from Harkenrider MM, Grover S, Erickson BA, et al. 2015, *Brachytherapy* 2016; **15**(1):23–9. With permission.)

Two fiducial markers should be placed in the cervix, classically at the 12 and 6 o'clock positions though other positions can be considered to avoid being placed in the direct plane of the tandem on plain radiographs. Fiducials act as a soft tissue surrogate of the cervix and ensure that applicator positioning remains optimal on intraoperative plain films after vaginal packing has been completed. The cervix and should be dilated, preferentially under ultrasound guidance, to help ensure that the dilators and ultimately the tandem are placed in the uterine canal (Small et al. 2011). Uterine perforations are common given that the cervix and cervical os are often obliterated following tumor growth and subsequent treatment. Ultrasound guidance of tandem placement has been shown to decrease rates of uterine perforation, and it is especially beneficial in patients with challenging anatomy (Segedin et al. 2013). The uterine canal should be sounded and measured to determine the length from the external cervical os to the uterine fundus. The cervical stopper (phlange) should be placed at that distance from the tip of the tandem to prevent the tandem from perforating through the uterine fundus upon tandem placement. The largest ring or ovoids that fit snugly in the right and left vaginal fornices should be placed. The system should be assembled and manipulated to maximize the distance between the two halves of the ring or the ovoids. The tandem should bisect the ring/ovoids in the anterior/posterior direction. Figure 37.3 depicts the various aspects of this procedure.

The intracavitary brachytherapy applicator comprises a tandem that is placed transvaginally through the cervical os extending to the uterine fundus. A vaginal ring, two colpostats (ovoids), or mold is placed in the vaginal fornices. The applicator can be assembled externally into a fixed system once optimal placement

Table 37.1 Step-by-Step Description of Classical Tandem and Ovoid Insertion Procedure

1. Appropriate general anesthesia initiated.
2. A rectovaginal exam is performed in order to assess for response to previous therapy and guide selection of ovoid size, need for interstitial needles, and document clinical exam in a drawing in the patient's medical record.
3. In the lithotomy position, the perineum is sterilely prepped and draped.
4. Two gold seeds are placed in the cervix at 3 o'clock and 9 o'clock.
5. The Foley catheter is inserted into the bladder.
6. The catheter is clamped and the bladder filled with sterile water or saline; Foley balloon is filled with 7 cc of radiopaque solution.
7. Ultrasound with a transabdominal probe can expedite insertion process, assist with accurate placement, and prevent perforation.
8. The cervix is dilated and the uterus is sounded.
9. The optimal tandem angle is chosen and the phlange is placed at the corresponding length that was sounded. The largest ovoids that the patient's anatomy will accommodate are selected.
10. Tandem is placed and correct placement into the uterine canal confirmed with ultrasound.
11. Iodinated vaginal packing is placed anterior and posterior to the ovoids, abutting the phlange, and filling the vagina. The packing serves to displace the bladder and rectum and maintain proper applicator position and geometry.
12. AP and lateral x-rays are performed to confirm correct placement.
13. Patient is awoken, transferred to recovery, keeping the head of the bed at ≤15°.
14. Volumetric imaging of the applicator is obtained (CT or MRI).
15. Target delineation, computerized dosimetry, dose optimization, dose delivery (HDR, LDR, or PDR).

and geometry is achieved. Vaginal packing is placed anterior and posterior to the ring or ovoids, with subsequent packing of the vagina. Packing displaces the bladder anteriorly and the rectum posteriorly to minimize dose to those normal tissues. It also maintains the optimal geometry that was achieved during placement and holds the applicator in place for the duration of the implant. The packing gauze can be iodinated with an internal ribbon or by soaking in betadine so that it is visible on intraoperative x-rays to ensure proper packing prior to completion of applicator placement. Alternatively, the gauze can be soaked with gadolinium or ultrasound gel to assist with visualization of the packing during MRI.

At completion of the procedure, intraoperative x-rays should be taken to verify proper applicator placement. Table 37.2 describes the characteristics of and shows a well-positioned implant.

In patients with large tumors, poor responses to EBRT, parametrial or pelvic sidewall extension, or unfavorable topography (tumor very near the organs at risk), a combination of intracavitary and interstitial brachytherapy can be performed. An intracavitary implant with an intrauterine tandem and ring/ovoids is placed as above. Special ring/ovoids have holes in them to allow placement of needles into the more lateral tissues. Newer devices allow for needles to be placed obliquely to extend to the very lateral tissues that may involve the pelvic sidewall. These strategies allow for increased dose delivered to the target volume and/or decreased doses to the bladder, rectum, and sigmoid colon (Dimopoulos et al. 2006, Nomden et al. 2012).

If disease is more extensive with pelvic sidewall involvement that doesn't respond well to EBRT or distal vaginal extension, then interstitial brachytherapy implant can be performed. This allows for better dose delivery to the vagina and potentially better coverage of the lateral tissues than the previously mentioned methods.

Treatment planning and optimization involves balancing the dose delivered to the target (i.e., point A, HR-CTV) against dose delivered to normal tissues. The normal tissues that are prioritized include the bladder, rectum, sigmoid colon, and vaginal mucosa. Dose constraints to these structures also consider the dose delivered with EBRT. Most organizations recommend doses of ≥85 Gy to point A or the target volume, most commonly to 90% of the high-risk clinical target volume (D90 HR-CTV) (Lee et al. 2012, Viswanathan and Thomadsen 2012, Viswanathan et al. 2012a).

The American Brachytherapy Society and GEC-ESTRO have published guidelines for target delineation, nomenclature, use of imaging, and treatment delivery for cervical brachytherapy (Haie-Meder et al. 2005, Viswanathan and Thomadsen 2012, Viswanathan et al. 2012a). Table 37.3 depicts and further defines the target volumes for image-based brachytherapy.

ENDOMETRIAL CANCER

Postoperative Vaginal Cuff Brachytherapy

Endometrial cancer is most commonly treated with total hysterectomy and bilateral salpingo-oophorectomy with or without bilateral pelvic and paraaortic lymph node dissection (Aalders et al. 1980, Blake et al. 2009, Creasman et al. 1987, Creutzberg et al. 2000, Keys et al. 2004, Nout et al. 2010). For early stage patients, patient and pathologic characteristics are used to risk-stratify patients for having recurrent disease. Randomized studies showed risk factors for recurrence include increasing age, increasing depth of myometrial invasion, higher grade, and presence of lymphovascular space invasion. External beam radiation therapy has been shown to decrease the risk of locoregional recurrence in studies of early stage, intermediate risk disease. These studies showed that about 75% of recurrences occur in the vagina (Creutzberg et al. 2000, Keys et al. 2004). For this reason, VBT has been performed with low risk of pelvic recurrences (Aalders et al.1980, Alektiar et al. 2005, Diavolitsis et al. 2012, Eltabbakh et al. 1997, Nout et al. 2010, Sorbe and Smeds 1990). PORTEC-2 demonstrated that VBT is not inferior to EBRT at preventing vaginal recurrence in high-intermediate risk patients after surgery (Nout et al. 2010). Patients who even have a small risk of recurrence often prefer to undergo adjuvant VBT for a modest perceived decrease in risk of recurrence (Kunneman et al. 2014). VBT can also be used as a supplemental (boost) treatment following EBRT for patients with more

Table 37.2 Characteristics of a Well-Positioned Tandem and Ovoid Applicator

AP

1. Tandem is positioned in mid-pelvis on AP film.
2. Phlange is proximate to the fiducial markers placed in the cervix.
3. The ovoids are high in the vaginal fornices as evidenced by proximity to the phlange and fiducial markers.
4. The tandem bisects the ovoids.

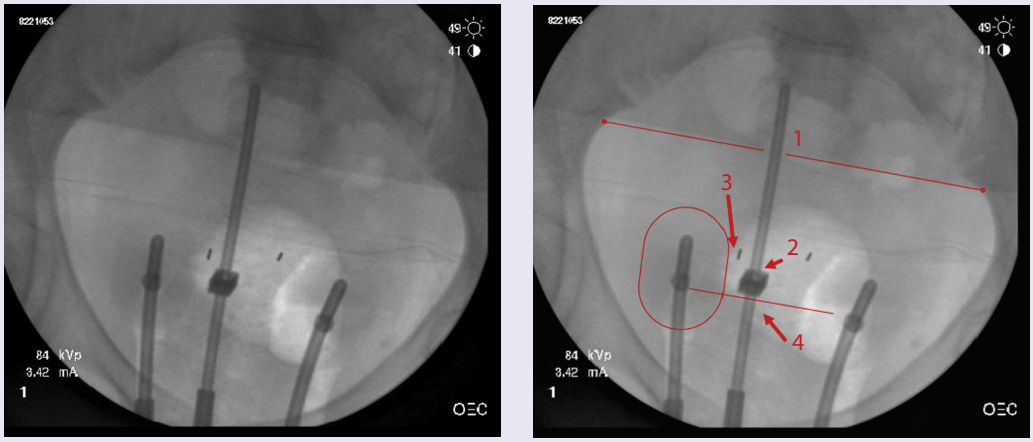

Lateral

1. Phlange and ovoids are proximate to the fiducial markers placed in the cervix.
2. The tandem bisects the ovoids.
3. Tandem does not approach the sacral promontory.
4. Appropriate packing in place to displace bladder and rectum without packing superior to the ovoids. Packing must be iodinated to be visible (not shown).

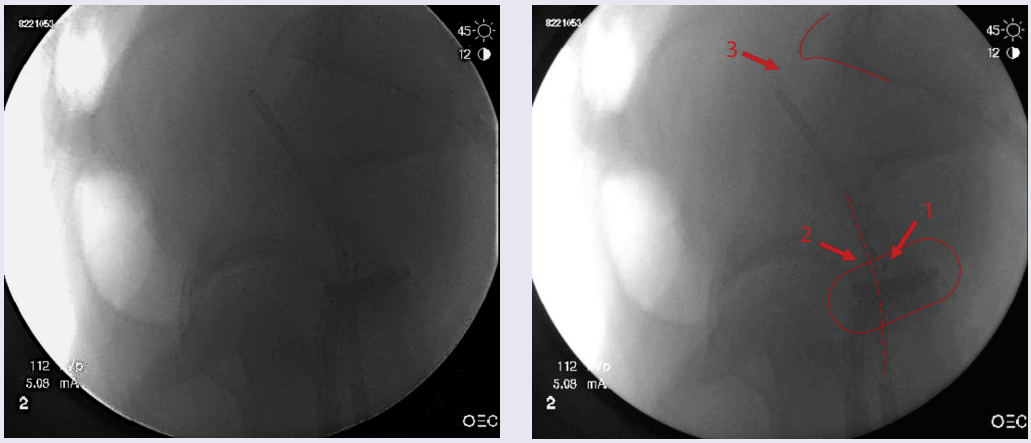

advanced disease, though there is not data to support VBT boost to decrease vaginal failure following EBRT (Aalders et al. 1980, Lybeert et al. 1989, Nori et al. 1994, Sorbe et al. 2012).

VBT is a form of intracavitary brachytherapy where an applicator is placed into the proximal vagina and a radiation source introduced into the applicator to deliver treatment. It is first important to perform a good pelvic exam postoperatively to ensure that the vaginal cuff is healed. Placement of a vaginal applicator if the cuff is not healed can result in dehiscence or vaginal cuff perforation. VBT applicators include a single-channel cylinder, multichannel cylinder, vaginal ovoids, ring, or mold, as shown in Figure 37.1A. The goal of the applicator placement is to place the largest diameter applicator that the patient's vagina can comfortably accommodate. Larger sized applicators have improved dose gradient at the surface of the vagina relative to depth, which may decrease toxicity. There are a variety of methods to hold the applicator in proper contact with the proximal vaginal mucosa that ensure the applicator is not displaced inferiorly and dose is properly delivered.

After placement of the applicator, images should be acquired to ensure proper placement. Most commonly, CT images are acquired to evaluate that the applicator is placed at the apex of the vaginal canal, that there are no airgaps between the applicator and the mucosa, and to evaluate the position of the vagina relative to the adjacent normal organs. Prior to applicator placement, gold fiducials can be inserted at the vaginal cuff so an anteroposterior x-ray can validate that the applicator is proximate to the fiducials. Adjustments to the applicator positions should be made until the positioning is optimal. The acquired CT images are used for treatment planning. Dose is most commonly specified to either the vaginal surface or at a depth of 0.5 cm. Since the proximal vagina is the portion at greatest risk

Table 37.3 GEC-ESTRO[a]

Volume	Definition	Sagittal MRI[b] Volume Example	Coronal Diagram
GTV-D[c]	Based on visualization, palpation, and T2 intensity MRI		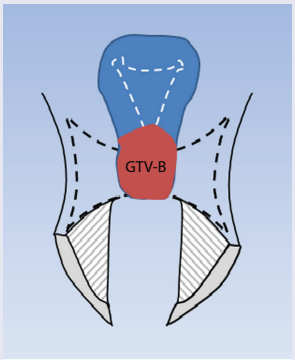
GTV-B[d]	Based on visualization, palpation, and T2 intensity on MRI *Note:* For multiple brachytherapy fractions, convention to name GTV-B_1, GTV-B_2, etc.	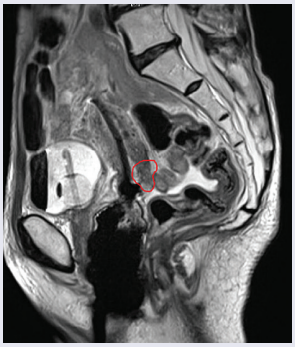	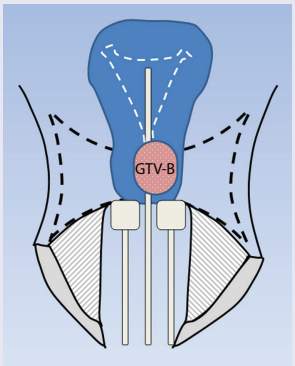
HR-CTV-B[e]	Includes GTV-B, entire cervix, and "gray zones" of intermediate signal on MRI T2 sequence	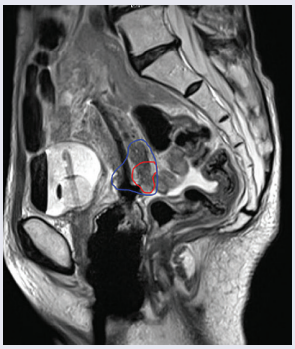	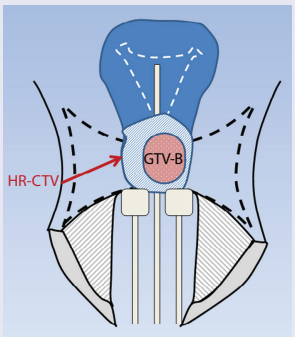
IR-CTV[f]	Includes 5–15-mm margin around HR-CTV and includes initial sites of involvement *Note:* Safety margin based on tumor size, location, spread, regression, and/or treatment technique		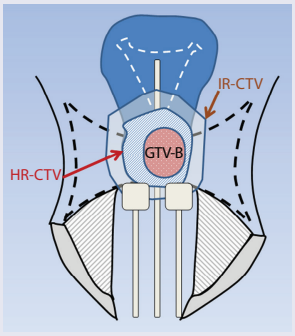

[a] The Groupe Européen de Curiethérapie (GEC) and the European Society for Radiotherapy & Oncology (ESTRO)
[b] Magnetic resonance imaging
[c] Gross tumor volume at diagnosis
[d] Gross tumor volume at brachytherapy
[e] High-risk clinical target volume at brachytherapy
[f] Intermediate-risk clinical target volume

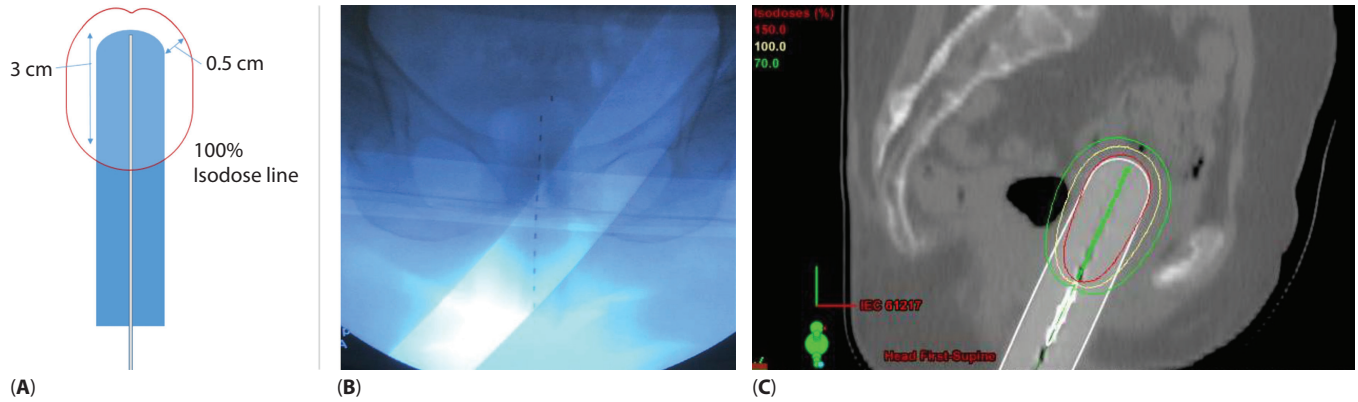

Figure 37.5 (**A**) Schematic depicting vaginal cylinder in place and 100% isodose line treating the proximal 3 cm of the vagina at 0.5 cm from the surface of the applicator; note expected anisotropy superiorly. (**B**) Plain film confirming the placement of applicator with radiopaque marker dummy wire in the cylinder and gold seed implanted in vaginal cuff. (**C**) Sagittal CT image depicting applicator in place and isodose distribution.

of recurrence, it is the proximal 3 to 5 cm or proximal one-third to one-half of the vagina that is most commonly specified the prescription dose. VBT is fractionated to deliver several fractions over 2 to 3 weeks, though there is no consensus on the optimal dose-fractionation schedule. Subsequent fractions of VBT can be performed without repeat CT imaging since the treatment plan has already been generated. The physician must only place the applicator and verify adequate placement on x-ray as comparable to the initial treatment day (Harkenrider et al. 2015, Small et al. 2012). Figure 37.5 shows imaging and ideal dosimetry when treating the proximal vagina with VBT.

Medically Inoperable Endometrial Brachytherapy

Factors such as increased age, obesity, and medical comorbidities may place the patient at high risk for perioperative morbidity or mortality. In those situations non-operative management with hormonal therapy or radiation therapy alone may be considered. Radiation therapy for medically inoperable endometrial cancer patients can comprise brachytherapy alone or EBRT followed by brachytherapy. Data show that incorporating brachytherapy into the treatment of medically inoperable patients improves survival compared to EBRT alone (Gill et al. 2015). In such patients, clinical staging is utilized, which relies on physical examination and radiographic imaging, preferably with MRI, as tumor location, depth of myometrial invasion, invasion of adjacent structures/organs, and lymph node size and architecture can all be assessed (Schwarz et al. 2015).

Brachytherapy for medically inoperable endometrial cancer patients most commonly comprises intracavitary brachytherapy in the uterine canal which may utilize a vaginal applicator for stabilization or with some dose contribution. The classic applicator is the Hayman capsule, which is designed as a long, thin applicator with a capsule on one end into which a radioactive source is placed. The cervical os is identified and dilated and a series of capsules containing LDR radionuclides are sequentially placed to fill the uterine canal. Images are acquired for dosimetric planning, and the patient retains the Hayman capsules according to the duration of the treatment plan. Single, dual, or triple intrauterine tandems are currently more commonly used, as they can deliver HDR treatment; these applicators are shown in Figure 37.1A. Dual and triple tandems have been shown to have better dose coverage compared to single-tandem systems. These systems can have a vaginal cylinder component for stabilization. Some single-tandem users prefer to use the ring or ovoids similar to treatment for cervical cancer, though treatment planning optimization can generate a plan more specific for the endometrial cancer patient (Schwarz et al. 2015). Figure 37.6 shows imaging and ideal dosimetry when treating the uterus with a dual-tandem applicator.

VAGINAL CANCER

Primary vaginal cancer is a rare tumor diagnosed with a vaginal tumor that does not involve either the cervix or the vulva. Tumors that involve either of those structures are diagnosed as primary malignancies of that site with vaginal extension. Primary vaginal tumors are routinely treated with definitive external beam radiation therapy alone for early-stage disease and with concurrent chemotherapy for locally advanced disease. As with cervical cancer, brachytherapy is an integral component to curative treatment (Dimopoulos et al. 2012). Lesions that are superficial, usually defined as ≤5 mm thick, can be treated with intracavitary brachytherapy, most commonly with a vaginal cylinder. Interstitial therapy can be utilized for deeper lesions that cannot be adequately covered with intracavitary brachytherapy without overdosing the uninvolved vaginal mucosa (Glaser et al. 2015). For these superficial lesions, VBT is similar to the treatment delivered for postoperative endometrial cancer, but the area treated in the vagina is customized to the location of the tumor.

For thicker or bulkier tumors and those that are locally advanced at diagnosis, interstitial brachytherapy should be performed. A possible exception is vaginal fornix lesions, where treatment techniques could mimic cervical cancer treatment. Interstitial brachytherapy is advantageous for tumors with extensive vaginal disease, paravaginal extension, parametrial extension, unfavorable response to radiochemotherapy, and those with deeper invasion beyond 5 mm from the vaginal mucosa. Interstitial brachytherapy allows for more uniform dose to be delivered to the tumor while avoiding overdosing the vaginal mucosa. The number of needles to be placed can be customized to account for the size and depth of the vaginal tumor.

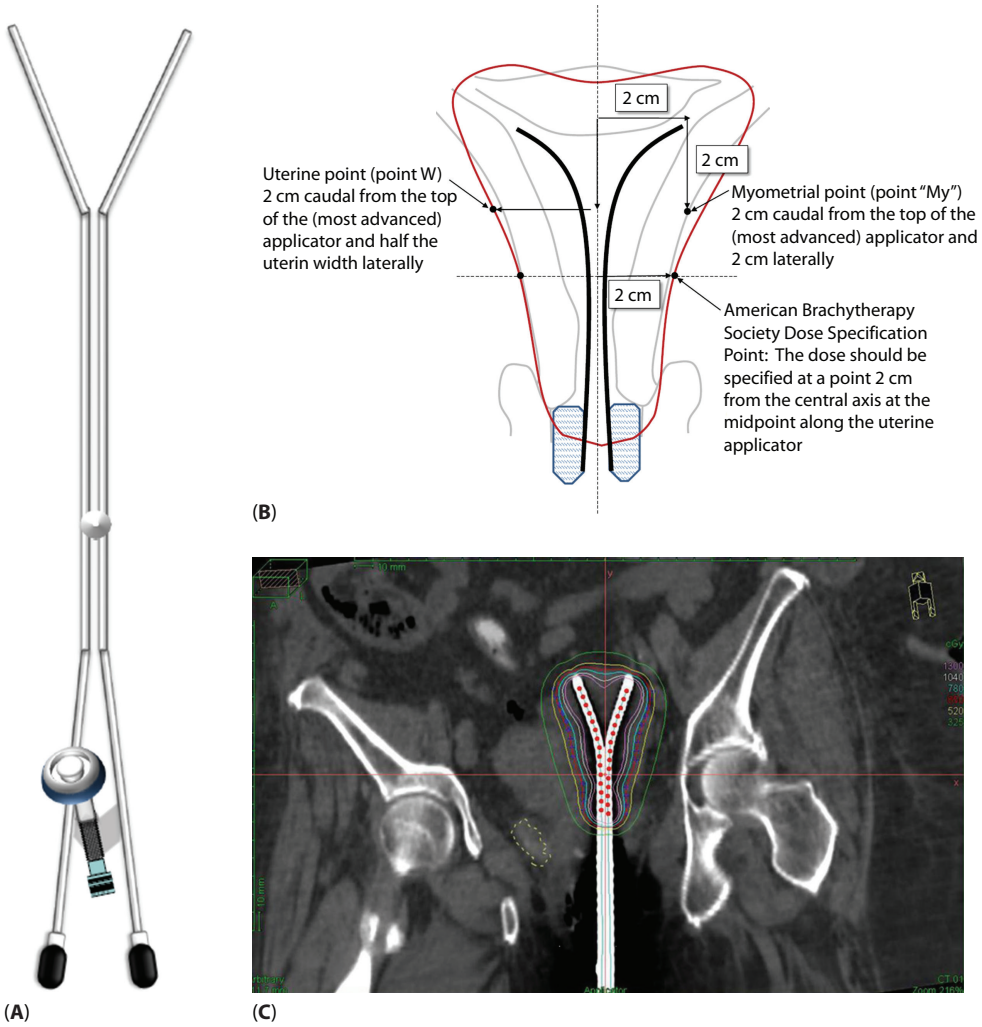

Figure 37.6 (**A**) Schematic depicting dual tandem (Rotte-Y) applicator. (**B**) Display of definitions of uterine point (point W), myometrial point (point "My"), and ABS dose specification point, all of which are dose specification points that have been described in the literature. (**C**) Coronal CT image depicting dual tandem applicator in place with representative Isodose distribution. (Reproduced from Schwarz JK, Beriwal S, Esthappan J, et al. 2015, *Brachytherapy* **14**:587–99. With permission.)

Interstitial brachytherapy can be either LDR or HDR, and the technique is similar to the previously described interstitial techniques (Beriwal et al. 2012). MRI-based adaptive brachytherapy for vaginal cancer has been reported as well. Similar to cervical cancer, MRI-based tumor delineation and treatment planning can result in more individualized brachytherapy (Dimopoulos et al. 2012).

VULVAR CANCER

The primary modality for the treatment of vulvar cancer is surgery with adjuvant EBRT to the vulva primarily for positive margins or close margins that cannot be re-excised (Heaps et al. 1990). Indications for nodal irradiation include node-positive disease, extracapsular extension, or absence of a surgical nodal assessment but with a risk of lymph node metastases (Homesley et al. 1986, Raspagliesi et al. 2006). Locally advanced vulvar cancer can be treated with surgery and adjuvant radiotherapy with or without chemotherapy as described, or with concurrent radiochemotherapy with or without adjuvant surgery (Beriwal et al. 2008, Moore et al. 1998).

For patients undergoing definitive radiochemotherapy, brachytherapy can be used to deliver an additional dose into the tumor following EBRT. Usual EBRT doses of 45 to 50.4 Gy to the vulva are delivered with concurrent chemotherapy. Additional doses of 10 to 20 Gy are commonly delivered to the primary tumor and involved lymph nodes. This boost dose can be delivered with EBRT or brachytherapy. Brachytherapy for vulvar tumors must be individualized based on the location and extension of disease (Seeger et al. 2006, Tewari et al. 1999).

For superficial tumor extension, brachytherapy would involve the freehand or template-based placement of needles through which plastic tubes are passed into and surrounding the vulvar tumor. The needles and plastic tubes should be placed in the plane of the labia. The plastic tubes can accommodate both LDR or HDR brachytherapy techniques. For deeper extension of disease into the vagina, paravaginal, urethra, paraurethral, or parametrial tissues, a vaginal cylinder with needles placed through a perineal template should be used. This technique is similar to the interstitial techniques described previously, and it allows for adequate dose coverage to these deeper tissues.

SUMMARY

Brachytherapy is an integral technique for the treatment of gynecologic malignancies. For locally advanced cervical and vaginal cancer, brachytherapy delivers high doses to the tumors while keeping normal tissues to limited doses. Incorporation of brachytherapy into the treatment of these patients results in increased tumor control and overall survival with reasonable rates of toxicity. Intra-operative barchytherapy is an uncommon but useful technique. Close pre-, intra-, and post-operative collaboration between surgeon and radiotherapist will best guide this application. Vaginal brachytherapy for postoperative endometrial cancer decreases the rates of vaginal recurrence at very modest rates of toxicity. Medically inoperable endometrial cancer is optimally treated with brachytherapy, often in combination with EBRT. Incorporation of advanced imaging with MRI and specialized applicators allows for true individualization of brachytherapy. Especially for cervical cancer, high-quality brachytherapy results in improved disease-free and overall survival and should be a mandatory part of the patient's treatment.

REFERENCES

Aalders J, Abeler V, Kolstad P, et al. 1980. Postoperative external irradiation and prognostic parameters in stage I endometrial carcinoma: Clinical and histopathologic study of 540 patients. *Obstet Gynecol* **56**:419–27.

Alektiar KM, Venkatraman E, Chi DS, et al. 2005. Intravaginal brachytherapy alone for intermediate-risk endometrial cancer. *Int J Radiat Oncol Biol Phys* **62**:111–7.

Bachaud JM, Fu RC, Delannes M, et al. 1991. Non-randomized comparative study of irradiation alone or in combination with surgery in stage Ib, IIa and "proximal" IIb carcinoma of the cervix. *Radiother Oncol* **22**:104–10.

Barillot I, Horiot JC, Pigneux J, et al. 1997. Carcinoma of the intact uterine cervix treated with radiotherapy alone: A French cooperative study: update and multivariate analysis of prognostics factors. *Int J Radiat Oncol Biol Phys* **38**:969–78.

Beriwal S, Coon D, Heron DE, et al. 2008. Preoperative intensity-modulated radiotherapy and chemotherapy for locally advanced vulvar carcinoma. *Gynecol Oncol* **109**:291–5.

Beriwal S, Demanes DJ, Erickson BJ, et al. 2012. American Brachytherapy Society consensus guidelines for interstitial brachytherapy for vaginal cancer. *Brachytherapy* **11**:68–75.

Blake P, Swart AM, Orton J, et al. 2009. Adjuvant external beam radiotherapy in the treatment of endometrial cancer (MRC ASTEC and NCIC CTG EN.5 randomised trials): Pooled trial results, systematic review, and meta-analysis. *Lancet* **373**:137–46.

Charra-Brunaud C, Harter V, Delannes M, et al. 2012. Impact of 3D image-based PDR brachytherapy on outcome of patients treated for cervix carcinoma in France: Results of the French STIC prospective study. *Radiother Oncol* **103**:305–13.

Chyle V, Zagars GK, Wheeler JA, et al. 1996. Definitive radiotherapy for carcinoma of the vagina: Outcome and prognostic factors. *Int J Radiat Oncol Biol Phys* **35**:891–905.

Creasman WT, Morrow CP, Bundy BN, et al. 1987. Surgical pathologic spread patterns of endometrial cancer. A Gynecologic Oncology Group Study. *Cancer,* **60**:2035–41.

Creutzberg CL, Van Putten WL, Koper PC, et al. 2000. Surgery and postoperative radiotherapy versus surgery alone for patients with stage-1 endometrial carcinoma: Multicentre randomised trial. PORTEC Study Group. Post Operative Radiation Therapy in Endometrial Carcinoma. *Lancet* **355**:1404–11.

Diavolitsis V, Rademaker A, Lurain J, et al. 2012. Clinical outcomes in international federation of gynecology and obstetrics stage IA endometrial cancer with myometrial invasion treated with or without postoperative vaginal brachytherapy. *Int J Radiat Oncol Biol Phys* **84**:415–9.

Dimopoulos JC, Kirisits C, Petric P, et al. 2006. The Vienna applicator for combined intracavitary and interstitial brachytherapy of cervical cancer: Clinical feasibility and preliminary results. *Int J Radiat Oncol Biol Phys* **66**:83–90.

Dimopoulos JC, Schmid MP, Fidarova E, et al. 2012. Treatment of locally advanced vaginal cancer with radiochemotherapy and magnetic resonance image-guided adaptive brachytherapy: Dose-volume parameters and first clinical results. *Int J Radiat Oncol Biol Phys* **82**:1880–8.

Eifel PJ, Thoms WW, Jr, Smith TL, et al. 1994. The relationship between brachytherapy dose and outcome in patients with bulky endocervical tumors treated with radiation alone. *Int J Radiat Oncol Biol Phys* **28**:113–8.

Eifel PJ, Winter K, Morris M, et al. 2004. Pelvic irradiation with concurrent chemotherapy versus pelvic and para-aortic irradiation for high-risk cervical cancer: An update of radiation therapy oncology group trial (RTOG) 90–01. *J Clin Oncol* **22**:872–80.

Eltabbakh GH, Piver MS, Hempling RE, et al. 1997. Excellent long-term survival and absence of vaginal recurrences in 332 patients with low-risk stage I endometrial adenocarcinoma treated with hysterectomy and vaginal brachytherapy without formal staging lymph node sampling: Report of a prospective trial. *Int J Radiat Oncol Biol Phys* **38**:373–80.

Gill BS, Chapman BV, Hansen KJ, et al. 2015. Primary radiotherapy for non-surgically managed Stage I endometrial cancer: Utilization and impact of brachytherapy. *Brachytherapy* **14**:373–9.

Glaser SM, Kim H, Beriwal S. 2015. Multichannel vaginal cylinder brachytherapy-Impact of tumor thickness and location on dose to organs at risk. *Brachytherapy* **14**:913–8.

Haie-Meder C, Potter R, Van Limbergen E, et al. 2005. Recommendations from Gynaecological (GYN) GEC-ESTRO Working Group (I): Concepts and terms in 3D image based 3D treatment planning in cervix cancer brachytherapy with emphasis on MRI assessment of GTV and CTV. *Radiother Oncol* **74**:235–45.

Han K, Milosevic M, Fyles A, et al. 2013. Trends in the utilization of brachytherapy in cervical cancer in the United States. *Int J Radiat Oncol Biol Phys* **87**:111–9.

Harkenrider MM, Grover S, Erickson BA, et al. 2015. Vaginal brachytherapy for postoperative endometrial cancer: 2014 Survey of the American Brachytherapy Society. *Brachytherapy* 2016; **15**(1):23–9.

Heaps JM, Fu YS, Montz FJ, et al. 1990. Surgical-pathologic variables predictive of local recurrence in squamous cell carcinoma of the vulva. *Gynecol Oncol* **38**:309–14.

Homesley HD, Bundy BN, Sedlis A, et al. 1986. Radiation therapy versus pelvic node resection for carcinoma of the vulva with positive groin nodes. *Obstet Gynecol* **68**:733–40.

Jang WI, Wu HG, Ha SW, et al. 2012. Definitive radiotherapy for treatment of primary vaginal cancer: Effectiveness and prognostic factors. *Int J Gynecol Cancer* **22**:521–7.

Kang HC, Shin KH, Park SY, et al. 2010. 3D CT-based high-dose-rate brachytherapy for cervical cancer: Clinical impact on late rectal bleeding and local control. *Radiother Oncol* **97**:507–13.

Keys HM, Roberts JA, Brunetto VL, et al. 2004. A phase III trial of surgery with or without adjunctive external pelvic radiation therapy in intermediate risk endometrial adenocarcinoma: A Gynecologic Oncology Group study. *Gynecol Oncol* **92**:744–51.

Kirisits C, Lang S, Dimopoulos J, et al. 2006. The Vienna applicator for combined intracavitary and interstitial brachytherapy of cervical cancer: Design, application, treatment planning, and dosimetric results. *Int J Radiat Oncol Biol Phys* **65**:624–30.

Kunneman M, Pieterse AH, Stiggelbout AM, et al. 2014. Treatment preferences and involvement in treatment decision making of patients with endometrial cancer and clinicians. *Br J Cancer* **111**:674–9.

Landoni F, Maneo A, Colombo A, et al. 1997. Randomised study of radical surgery versus radiotherapy for stage Ib-IIa cervical cancer. *Lancet* **350**:535–40.

Lee LJ, Das IJ, Higgins SA, et al. 2012. American Brachytherapy Society consensus guidelines for locally advanced carcinoma of the cervix. Part III: Low-dose-rate and pulsed-dose-rate brachytherapy. *Brachytherapy* **11**:53–7.

Lybeert ML, Van Putten WL, Ribot JG, et al. 1989. Endometrial carcinoma: High dose-rate brachytherapy in combination with external irradiation; a multivariate analysis of relapses. *Radiother Oncol* **16**:245–52.

Moore DH, Thomas GM, Montana GS, et al. 1998. Preoperative chemoradiation for advanced vulvar cancer: A phase II study of the Gynecologic Oncology Group. *Int J Radiat Oncol Biol Phys* **42**:79–85.

Morris M, Eifel PJ, Lu J, et al. 1999. Pelvic radiation with concurrent chemotherapy compared with pelvic and para-aortic radiation for high-risk cervical cancer. *N Engl J Med* **340**:1137–43.

Newton M. 1975. Radical hysterectomy or radiotherapy for stage I cervical cancer. A prospective comparison with 5 and 10 years follow-up. *Am J Obstet Gynecol* **123**:535–42.

Nomden CN, De Leeuw AA, Moerland MA, et al. 2012. Clinical use of the Utrecht applicator for combined intracavitary/interstitial brachytherapy treatment in locally advanced cervical cancer. *Int J Radiat Oncol Biol Phys* **82**:1424–30.

Nonaka T, Nakayama Y, Mizoguchi N, et al. 2013. Definitive radiation therapy for invasive carcinoma of the vagina: Impact of high-dose rate intracavitary brachytherapy. *Int J Clin Oncol* **18**:314–20.

Nori D, Merimsky O, Batata M, et al. 1994. Postoperative high dose-rate intravaginal brachytherapy combined with external irradiation for early stage endometrial cancer: A long-term follow-up. *Int J Radiat Oncol Biol Phys* **30**:831–7.

Nout, RA, Smit VT, Putter H, et al. 2010. Vaginal brachytherapy versus pelvic external beam radiotherapy for patients with endometrial cancer of high-intermediate risk (PORTEC-2): An open-label, non-inferiority, randomised trial. *Lancet* **375**:816–23.

Perez CA, Breaux S, Madoc-Jones H, et al. 1983. Radiation therapy alone in the treatment of carcinoma of uterine cervix. I. Analysis of tumor recurrence. *Cancer* **51**:1393–402.

Pierquin B. 1964. *Precis de curietherapie, endocurietherapie et plesiocurietherapie*, Paris, France: Masson.

Potter R, Haie-Meder C, Van Limbergen E, et al. 2006. Recommendations from gynaecological (GYN) GEC ESTRO working group (II): Concepts and terms in 3D image-based treatment planning in cervix cancer brachytherapy-3D dose volume parameters and aspects of 3D image-based anatomy, radiation physics, radiobiology. *Radiother Oncol* **78**:67–77.

Raspagliesi F, Hanozet F, Ditto A, et al. 2006. Clinical and pathological prognostic factors in squamous cell carcinoma of the vulva. *Gynecol Oncol* **102**:333–7.

Rose PG, Ali S, Watkins E, et al. 2007. Long-term follow-up of a randomized trial comparing concurrent single agent cisplatin, cisplatin-based combination chemotherapy, or hydroxyurea during pelvic irradiation for locally advanced cervical cancer: A Gynecologic Oncology Group Study. *J Clin Oncol* **25**:2804–10.

Rotman M, Choi K, Guse C, et al. 1990. Prophylactic irradiation of the paraaortic lymph node chain in stage IIB and bulky stage IB carcinoma of the cervix, initial treatment results of RTOG 7920. *Int J Radiat Oncol Biol Phys* **19**:513–21.

Schwarz JK, Beriwal S, Esthappan J, et al. 2015. Consensus statement for brachytherapy for the treatment of medically inoperable endometrial cancer. *Brachytherapy* **14**:587–99.

Seeger AR, Windschall A, Lotter M, et al. 2006. The role of interstitial brachytherapy in the treatment of vaginal and vulvar malignancies. *Strahlenther Onkol* **182**:142–8.

Segedin B, Gugic J, Petric P. 2013. Uterine perforation - 5-year experience in 3-D image guided gynaecological brachytherapy at Institute of Oncology Ljubljana. *Radiol Oncol* **47**:154–60.

Small W Jr, Beriwal S, Demanes DJ, et al. 2012. American Brachytherapy Society consensus guidelines for adjuvant vaginal cuff brachytherapy after hysterectomy. *Brachytherapy* **11**:58–67.

Small W Jr, Strauss JB, Hwang CS, et al. 2011. Should uterine tandem applicators ever be placed without ultrasound guidance? No: A brief report and review of the literature. *Int J Gynecol Cancer* **21**:941–4. PMID 21697682.

Sorbe B, Horvath G, Andersson H, et al. 2012. External pelvic and vaginal irradiation versus vaginal irradiation alone as postoperative therapy in medium-risk endometrial carcinoma—A prospective randomized study. *Int J Radiat Oncol Biol Phys* **82**:1249–55.

Sorbe BG, Smeds AC. 1990. Postoperative vaginal irradiation with high dose rate afterloading technique in endometrial carcinoma stage I. *Int J Radiat Oncol Biol Phys* **18**:305–14.

Tanderup K, Eifel PJ, Yashar CM, et al. 2014. Curative radiation therapy for locally advanced cervical cancer: Brachytherapy is NOT optional. *Int J Radiat Oncol Biol Phys* **88**:537–9.

Tewari K, Cappuccini F, Syed AM, et al. 1999. Interstitial brachytherapy in the treatment of advanced and recurrent vulvar cancer. *Am J Obstet Gynecol* **181**:91–8.

Tod M, Meredith W. 1938. A dosage system for use in the treatment of cancer of the uterine cervix. *Br J Radiol* **1**:809–824.

Vargo JA, Kim H, Houser CJ, et al. 2015. Image-based multichannel vaginal cylinder brachytherapy for vaginal cancer. *Brachytherapy* **14**:9–15.

Viswanathan AN, Cormack R, Rawal B, et al. 2009. Increasing brachytherapy dose predicts survival for interstitial and tandem-based radiation for stage IIIB cervical cancer. *Int J Gynecol Cancer* **19**:1402–6.

Viswanathan AN, Beriwal S, De Los Santos JF, et al. 2012a. American Brachytherapy Society consensus guidelines for locally advanced carcinoma of the cervix. Part II: High-dose-rate brachytherapy. *Brachytherapy* **11**:47–52.

Viswanathan AN, Moughan J, Small W, Jr, et al. 2012b. The quality of cervical cancer brachytherapy implantation and the impact on local recurrence and disease-free survival in radiation therapy oncology group prospective trials 0116 and 0128. *Int J Gynecol Cancer* **22**:123–31.

Viswanathan AN, Thomadsen B. 2012c. American Brachytherapy Society consensus guidelines for locally advanced carcinoma of the cervix. Part I: General principles. *Brachytherapy* **11**:33–46.

Wachter-Gerstner N, Wachter S, Reinstadler E, et al, R. 2003. The impact of sectional imaging on dose escalation in endocavitary HDR-brachytherapy of cervical cancer: Results of a prospective comparative trial. *Radiother Oncol* **68**:51–9.

Walstam R. 1954. The dosage distribution in the pelvis in radium treatment of carcinoma of the cervix. *Acta Radiol* **42**;237–50.

Wilkinson JM, Ramachandran TP, 1989. The ICRU recommendations for reporting intracavitary therapy in gynaecology and the Manchester method of treating cancer of the cervix uteri. *Br J Radiol* **62**:362–5.

38 Innovative methods to teach and train minimally invasive surgery

Helai Hesham, Thomas Lendvay, Ritu Salani, and Martin A. Martino

INTRODUCTION

As years of surgical training have evolved, multiple surgical mediums and techniques have been developed that have revolutionized the field of gynecologic oncology. Minimally invasive surgery has significantly changed the way surgeons care for patients, with the vast majority of gynecologic oncology patients receiving minimally invasive approaches to help manage complex gynecologic conditions. What have not changed through the years are the basic surgical principles that are needed to accomplish a surgical procedure safely. Halsted's principles remain the tenets of surgical technique regarding tissue handling. The key points that Halsted illustrated in the nineteenth century, including gentle handling of tissue, meticulous hemostasis, preservation of blood supply, strict aseptic technique, minimum tension on tissues, accurate tissue apposition, and obliteration of dead space, have been taught to every surgical trainee in one form or another for decades (Polavarapu 2013). What has changed over time is how those skills translate into minimally invasive surgical technique and how to appropriately teach and validate those skills in our trainees.

Laparoscopic surgery began within gynecology with the introduction of a camera into a patient's abdomen. In 2005, with the Food and Drug Administration (FDA) approval of robotic surgery for gynecologic procedures, minimally invasive approaches have become the leading mediums of surgery in our field. Robotic assisted surgery remains a unique training arena where both surgeons (teacher and student) are not simultaneously doing surgery at the patient bedside. Thus many traditional training curricula are inherently not customized for these new surgical procedures. Residency and fellowship programs throughout the country are adapting and building innovative methods to teach and train in minimally invasive surgery with validated programs.

While training programs are dealing with this new paradigm, challenges exist as to how best to teach and evaluate surgical skills with an objective and validated approach. Duty hour restrictions now require residents to average no more than 80-hour work weeks over the course of a month. Although there are many benefits for residents with these restrictions, multiple studies within general surgery programs have shown that mandated work-hour guidelines have decreased the number of operative cases for residents (Carlin 2007, Kairys 2008). One study within gynecology identified no changes in overall volume of cases with duty hour restrictions, but noted a difference in types of cases. Gynecology residents had more hysteroscopy and laparotomy procedures, but less total abdominal hysterectomies and total vaginal hysterectomies (Kane 2010). With decreasing surgical volume and limited time in the workday, innovative curricula have been optimized to be both efficient and simulation-based.

Hospitals are also now dealing with a changing healthcare system where our economic model is shifting from fee-for-service to fee-for-performance (James 2012). By 2016, over 80% of all reimbursement by Medicare will be driven by performance-based metrics, and healthcare costs will become more shared by individuals and employers (medicare.gov 2015). This will drive demand for objective data on surgeons. With so many variables in the future of training, reimbursement, and surgical volume, validated surgical training programs are of utmost importance.

The American Board of Surgery (ABS) has already created a mandatory curriculum with the Fundamentals of Laparoscopic Surgery for their residents to train and assess the basic skills needed for laparoscopic surgery (frsurgery.org). Since the majority of hysterectomy procedures as of 2013 were performed through a robotic-assisted approach, standardizing this training platform is essential to safely teach future surgeons how to utilize emerging technologies such as robotics. In 2010, nine Accreditation Council for Graduate Medical Education (ACGME)-approved OB-GYN educational programs developed a consensus-based curriculum to teach and assess residents and fellows training in robotic surgery (robotictraining.org).

CURRENT METHODS OF ASSESSMENT IN RESIDENCY PROGRAMS (OB-GYN)

The American Board of Obstetrics and Gynecology (ABOG) provides oversight to general obstetricians and gynecologists and the four accredited subspecialty fellowships in the specialty. ABOG, along with the American Congress of Obstetricians and Gynecologists (ACOG), have worked together throughout the years to establish appropriate levels of competency for residency and fellowship graduates with the aim of having a standardized baseline of skill throughout the nation. This is best illustrated through the board certification process, which requires a written and oral examination to all generalists and subspecialists. With the successful completion of these examinations and completion of an ACGME-approved residency program, graduates are considered competent practitioners. They are provided with documentation from their respective training program directors and/or chairs that they can safely perform a series of surgical procedures. Despite 4 to 8 years of surgical training, graduates may not be given a standardized, validated form of assessment of their surgical skills. As technology advances, new mediums exist to both educate and allow the surgeon in training (or practicing surgeon) to demonstrate proficiency and to be benchmarked against practicing surgeons.

Currently, most programs utilize "hands-on" teaching in the operating room by attending physicians. Feedback is often given at the end of rotations, usually incorporating core ACGME milestones. Assessment of skill is included, but often in comparison of the trainee and their peers within their own year of training.

In 2003, the Council on Resident Education in Obstetrics and Gynecology (CREOG), of the ACOG, sought to change how surgical skills are assessed. In a CREOG Task Force entitled *Evaluating Surgical Competency*, training programs were urged to utilize Objective Structured Assessments of Technical Skills (OSATS) as well as the use of models and laboratory teaching. This was to not only standardize assessment of residents, but also to standardize teaching of basic gynecological skills to ensure that all residents are exposed to the same core procedures, and to assess their competency.

Surgical skills were to be tested objectively with the following core principles:

1. Feasibility—Can the test easily be conducted?
2. Reliability—If tested again, would results be the same?
3. Validity—Are we measuring what we think we are measuring?

OSATS was created by Dr. Richard Reznick at the University of Toronto. He and his group designed and validated both global and procedure-specific skills assessment tools to be used within surgical instruction and assessment. A modification of their global rating scale was recommended by the ACGME for use with graduate medical education (Table 38.1) (Reznick et al. 1997, Winckel et al. 1994). With these first steps, analysis of competency within surgery became more objective. General surgery residency programs used OSATS and began using models and laboratory teaching to standardize their teaching and testing of competence within laparoscopic surgery. The Fundamentals of Laparoscopic Surgery, a program used for nearly 10 years, is mandatory for accredited general surgery residencies. Residents complete a cognitive web-based education module and a hands-on skills training component with assessment. This is designed to teach the physiology, fundamental knowledge, and technical skills required in basic laparoscopic surgery.

Table 38.1 Global Rating Scale of Operative Performance

Please circle the number corresponding to the candidate's performance in each category, irrespective of the training level.

		Respect for Tissue		
1 Frequently used unnecessary force on tissue or caused damage by inappropriate use of instruments	**2**	**3** Careful handling of tissue but occasionally caused inadvertent damage	**4**	**5** Consistently handled tissues appropriately with minimal damage
		Time and Motion		
1 Many unnecessary moves	**2**	**3** Efficient time/motion but some unnecessary moves	**4**	**5** Clear economy of movement and maximum efficiency
		Instrument Handling		
1 Repeatedly makes tentative or awkward moves with instruments by inappropriate use of instruments	**2**	**3** Competent use of instruments but occasionally appeared stiff or awkward	**4**	**5** Fluid moves with instruments and no awkwardness
		Knowledge of Instrument		
1 Frequently asked for wrong instrument or used inappropriate instrument	**2**	**3** Knew names of most instruments and used appropriate instrument	**4**	**5** Obviously familiar with the instruments and their names
		Flow of Operation		
1 Frequently stopped operating and seemed unsure of next move	**2**	**3** Demonstrated some forward planning with reasonable progression of procedure	**4**	**5** Obviously planned course of operating with effortless flow from one move to the next
		Use of Assistants		
1 Consistently placed assistants poorly or failed to use assistants	**2**	**3** Appropriate use of assistants most of the time	**4**	**5** Strategically used assistants to the best advantage at all times
		Knowledge of Specific Procedure		
1 Deficient knowledge; needed specific instructions at most steps	**2**	**3** Knew all important steps of operation	**4**	**5** Demonstrated familiarity with all aspects of operation
OVERALL ON THIS TASK, SHOULD THE CANDIDATE:		FAIL		PASS

Source: Reprinted from Reznick R, Regehr G, MacRae H, et al. 1997. *Am J Surg* **180**:226–30. With permission.

INNOVATIVE TRAINING NETWORKS AND VALIDATION OF SKILLS

The Robotic Training Network

Within a decade of FDA approval for use in gynecology (2005–2015), robot-assisted surgery was performed more commonly than laparoscopic hysterectomy, vaginal hysterectomy, and open hysterectomy (robotictraining.org). During this time, educational groups have been challenged with teaching standard laparoscopic skills along with more advanced skills to learners. Most education has been completed through select centers using self-instruction and then instruction of peers. Five years after the introduction of robotics to gynecology, the Robotic Training Network (RTN) was developed to standardize education and training in robotic surgery. The goal was to improve safe utilization of this technology and teach learners in a systematic and objective approach with evidence-based metrics. In addition, RTN members were interested in developing and validating a proficiency-based objective test to determine when a learner can safely perform surgery at the surgeon's console.

In an effort to develop objective benchmarks, the RTN validated an assessment tool known as Robotic-Objective Structured Assessments of Technical Skills (R-OSATS). OSATS is used in surgical training to allow for assessment of technical skills with predefined criteria. OSATS allows for less biased and more objective analysis of technical performance and has demonstrated validity and reliability. Due to the objectivity, training programs in surgery have utilized OSATS extensively. Training programs have developed modified versions of OSATS for new surgical techniques, including laparoscopic and endoscopic procedures. R-OSATS within the RTN are completed by directly observing and recording performance on robotic simulation drills.

Performance for each simulation drill is assessed across four categories:

1. Depth perception/accuracy
2. Force/tissue handling
3. Dexterity
4. Efficiency

Each category is scored from 1 to 5, with higher scores indicating higher proficiency. Scores are summed across categories, giving a maximum score of 20 per drill.

Recent research validated the R-OSATS exam as a valid and reliable assessment form for robotic surgical skill by evaluating residents, fellows, and attending physicians on the ability to perform standardized robotic skill drills (Siddiqui et al. 2014). In this study, participants were evaluated on their robotic surgical skills by expert surgeons (attending physicians who had done over 100 robotic cases). The surgical skills are performed in a dry lab and include five drills (Figure 38.1). The first drill is "tower transfer," in which the participant picks up rubber bands

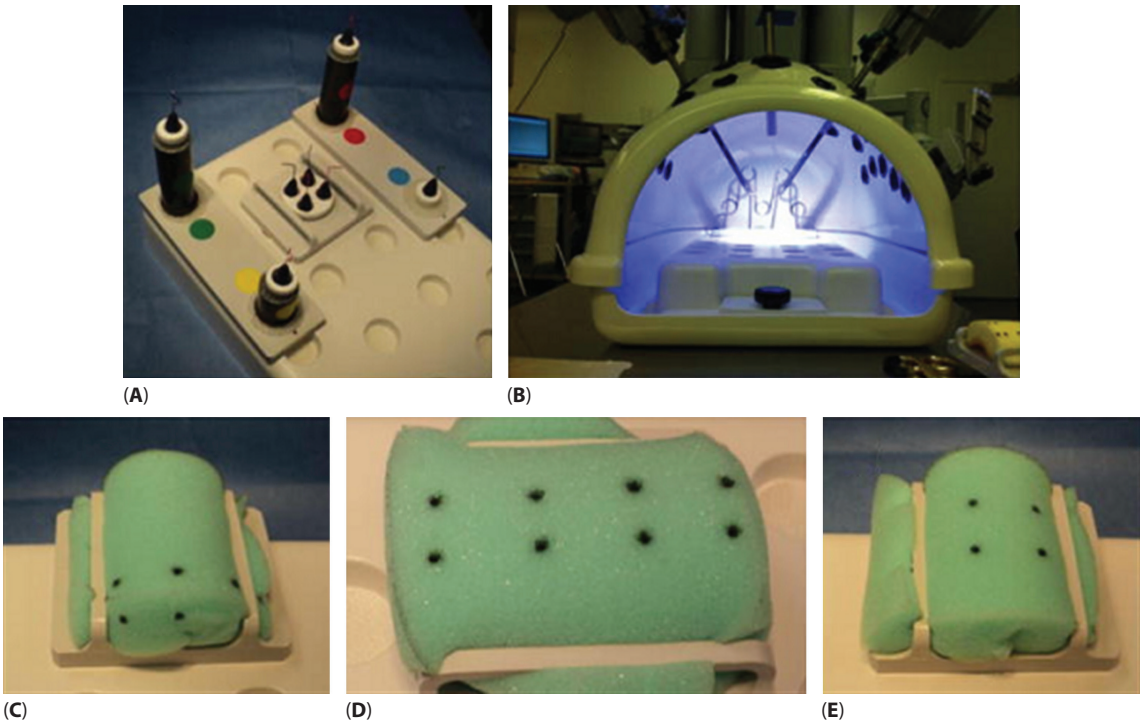

Figure 38.1 (**A**) Towers. Learning objective: improve EndoWrist dexterity and develop camera control skills. Execute multiple precise object manipulations. Task objective: remove rings from cones on a central pod. Transfer the rings to the towers located in the four corners of a structure under a time constraint. (**B**) Roller coaster. Learning objective: coordinate control of an object's position and orientation along a trajectory using EndoWrist instruments. Improve camera control skills. Task objective: pick up a flexible ring and move the ring along a bending rail to the other end within a time limit. (**C**) Big dipper. Learning objective: improve dexterity and accuracy when driving a needle through an object at different angles. Task objective: pass a needle between instruments. Insert and extract the needle through several pairs of targets on a sponge within a 5-minute time constraint. (**D**) Railroad tracks. Learning objective: develop suturing and EndoWrist manipulation skills. Task objective: apply a running suture through a series of four pairs of targets on a sponge within a 5-minute time constraint. (**E**) Suture drill. Learning objective: Further develop suturing, knot tying and EndoWrist manipulation skills. Task objective: drive a needle and suture through two pairs of targets and complete it by tying a surgeon's knot and a square knot. (Courtesy of Dr. Martin Martino.)

and transfers them to towers of varying heights. The second drill is "roller coaster," in which a rubber band is moved around a series of wire loops. The third drill is "big dipper," in which a needle is placed into a sponge in various prespecified directions. The fourth drill is "train tracks," which involves placing a running suture. The final drill is "figure-of-eight," in which the participant places a figure-of-eight suture and ties it using square knots. The outcome of the study showed that the R-OSATS test demonstrated construct validity—it could differentiate between novice and expert surgeons. Benchmark scoring using the modified Angoff method resulted in the learners having to achieve a score of 14 or higher out of 20 on each of the five drills described above in order to pass R-OSATS in entirety (Livingston et al. 1982).

In 2014, RTN shared their consensus-developed robotic training curriculum with multiple institutions. This included the R-OSATS tool developed and tested previously within a two-phase system that both instructs and tests the competence of trainees.

Phase 1 of the curriculum includes (Figure 38.3):

1. Baseline assessment test: Multiple choice question test designed to evaluate minimal baseline knowledge regarding robotic surgery.
2. Online modules: Regarding the basic mechanics of the robot, appropriate docking of the robot, port placement for various procedures, and knowledge of robotic instruments.
3. Dry lab: Appropriately dock the robot on a simulated torso with instrument transfer and troubleshooting.
4. Surgical setup: Appropriately dock the robot within a live case and transfer instruments.
5. Complete both a cost quality improvement exercise as well as a professionalism activity.

Once trainees have successfully completed the first phase of the curriculum, they are allowed to start the second phase.

	Activity	ACGME core competency
Phase I (bedside)	Self-learning	Medical knowledge
	Dry lab/simulation	Practice-based learning and improvement
	Operating room	Patient care; practice-based learning and improvement; systems based practice; professionalism; interpersonal skills and communication
Phase II (console)	Self-learning	Medical knowledge
	Dry lab/simulation	Practice-based learning and improvement
	Operating room	Patient care; practice-based learning and improvement; systems based practice; professionalism; interpersonal skills and communication

Figure 38.2 Phase 1 and 2 of Robotic Training Network curriculum with coinciding ACGME core competency. (Courtesy of Dr. Martin Martino.)

Phase 2 of the curriculum includes (Figure 38.4):

1. Online modules: Regarding the Si console.
2. Dry lab: Successful completion of R-OSATS, scoring >13.
3. Operating room: Completing 30 minutes on the console with feedback review from attending, then completion of five more cases with review of set skills with attending.
4. Completion of two quality improvement and one professionalism activity.

Once these phases are completed, the trainee is not only console-ready, but is considered to have baseline competence on the robot. Both phases of the curriculum incorporate many of the ACGME needed core competencies (Figure 38.2).

The Fundamentals of Robotic Surgery

While the Robotic Training Network has been in use, the Fundamentals of Robotic Surgery (FRS) has also been created. FRS is a multispecialty, proficiency-based curriculum to both instruct and assess surgeons to safely and proficiently perform robotic-assisted surgery. The curriculum focuses on the training of basic technical skills within robotic surgery (Smith 2014). Through four consensus conferences with nearly 80 national and international surgical experts, medical educators, behavioral psychologists, statisticians, and psychometricians, a new standardized curriculum was created.

The three main sections developed were:

1. Cognitive learning
2. Psychomotor training
3. Team training

As a result, they have developed an online curriculum and are in the process of testing this along with a high-fidelity simulator developed for dry lab and virtual reality as part of a randomized trial to validate the curriculum. The validation trial began in 2015 and is currently underway at 14 clinical training sites throughout the world.

In 2013, members of the RTN joined with leaders from major educational and medical societies as well as the Joint Commission and the American Medical Association to develop consensus through the Fundamentals of Robotic Gynecologic Surgery (FRGS). This program was also funded by the Department of Defense and has led to the current adoption of the RTN curriculum to be the current standard until FRGS develops virtual reality simulation and is tested and validated internationally. The FRGS curriculum is being developed to be a "final proficiency test" for residents/fellows recorded ideally in an educational portfolio to demonstrate surgical skills and knowledge to use for credentialing if they are interested in obtaining privileges to perform robotic-assisted surgery.

DEMONSTRATING SURGICAL EXCELLENCE

Crowdsourcing for Proficiency Assessment

With the changes that will be seen in healthcare, we will see more emphasis on quality outcomes for reimbursement rather than

Robotic Training Network

Resident checklist – Phase I: Bedside assistant		
1. Create an online account on www.robotictraining.org 2. Maintain training session LOG 3. Maintain OR case LOG 4. Complete training, print components for your portfolio if applicable		
You must complete each step prior to proceeding to the next, and before moving on to Phase II		
Self-learning		
Read review article: ☐ Robotic surgery (Visco) Review the online modules: ☐ Si (S) system overview ☐ Safety features ☐ Si (S) docking ☐ First assistant essentials ☐ Patient positioning and side docking (view only)	☐ Complete article study guide ☐ Print the certificate of completion for each module for your portfolio (if applicable for your program)	Date ☐ __
Dry lab		Date
☐ Complete article study guide ☐ Attend Dry Lab: instrument transfer	☐ Score 100%: surgical setup checklist in dry LAB ☐ Score 100%: Instrument transfer checklist in dry LAB	☐ __ ☐ __
OR		Date
☐ Perform surgical setup in OR cases ☐ Perform instrument transfer in OR cases	☐ Score 100%: Surgical setup checklist in OR in at least 1 surgical case ☐ Score 100%: Instrument transfer checklist in at least 1 surgical case	☐ __ ☐ ___
Quality improvement		Date
☐ Read review article: cost containment (Cima et al.)	☐ Complete cost-quality improvement exercise for 1 case	☐ __
Professionalism		Date
☐ Review professionalism eval (PROM) with faculty proctor	☐ One completed faculty evaluation for bedside assistant	☐ __
After completing the above steps, you may proceed to Phase II and console training.		

Figure 38.3 Phase 1 of the Robotic Training Network Robotic curriculum. (Courtesy of Dr. Martin Martino.)

fee-for-service. This will require surgeons to be compensated for their surgical outcomes. As our residents and fellows graduate, their future employers will desire documentation of their medical and surgical proficiency. Medical proficiency has always been demonstrated through medical board licensing examinations; however, other than ACGME requirements of surgical case volume, there are no standardized ways to show proficiency within surgery. With the multitude of surgical simulation programs and heightened technology also allowing video capture of surgical procedures, some institutions have started to document proficiency through successful completion of simulation drills as well as creation of surgical portfolios with video capture.

One hurdle in this process has been the time commitment required by attending physicians to efficiently grade surgical videos of their trainees and to do so in an objective manner. One idea proposed to alleviate these burdens has been to introduce the concept of crowdsourcing to help with scalable assessment of basic surgical skills.

Robotic Training Network

Resident checklist – Phase II: Console training		
1. Create an online account on www.robotictraining.org 2. Maintain training session LOG 3. Maintain OR case LOG 4. Complete training, print components for your portfolio if applicable		
You must complete each step prior to proceeding to the next		
Self-learning		
☐ Read the online module: ☐ Si (S) console	☐ Print the certificate of completion for each module for your portfolio (if applicable for your program)	Date ☐ ___
Dry lab		**Date**
☐ Attend Dry Lab: Console skills ☐ Attend Dry Lab: VR simulation if available (optional)	☐ Score >13/20 for each R-OSATS dry lab skill drill Remember to maintain a log of your training sessions	☐ ___
OR		**Date**
☐ Perform 30 min at console during OR cases as appropriate ☐ Record first console surgery after R-OSATS, and then optional video review with proctor	☐ Record and submit 1st console video after R-OSATS to site coordinator ☐ Optional: review video with proctor ☐ GEARS eval for at least 5 cases Remember to maintain a log of your OR sessions	☐ ___ ☐ ___
Quality improvement		**Date**
Read review articles: ☐ Choosing approach: AAGL position statement, ACOG committee opinion ☐ Error reduction in surgery (Cooper)	☐ Score >80% on post-tests ☐ Complete error-quality improvement exercise for 1 case	☐ ___ ☐ ___
Professionalism		**Date**
☐ Review professionalism eval (PROM) with faculty proctor	☐ One completed faculty evaluation for console surgeon	☐ ___

Figure 38.4 Phase 2 of the Robotic Training Network Robotic curriculum. (Courtesy of Dr. Martin Martino.)

Crowdsourcing is the process of completing tasks by employing large groups of decentralized, independent people providing aggregated feedback (Ranard et al. 2014, Surowiecki 2005). Crowdsourcing has enjoyed broad success in healthcare—discovering protein folding patterns, assisting patients with disabilities, locating automatic defibrillators in major cities, and annotating electronic medical records (Ranard et al. 2014, Savage 2012). Many applications use online labor marketplaces, such as Amazon.com Mechanical Turk™ (Chen et al. 2014), to quickly and cheaply get an anonymous crowd. Crowd-Sourced Assessment of Technical Skills (C-SATS) is a method by which surgical technique can be assessed by crowds of reviewers; some non-medically trained. Because C-SATS can leverage the readily available pool of millions of anonymous online crowdworkers, the disadvantages of using peers and mentors exclusively for skills appraisal including subjectivity and labor-intensiveness are mitigated. Feedback with crowdsourcing is also timely, with feedback provided within minutes of posting surgical performances to be rated and completed within hours (Chen et al. 2014, Holst et al. 2015a, Lendvay et al. 2014, White et al. 2014).

Initial validation of C-SATS was performed by Chen et al., in which a group of 501 crowdworkers' assessments in the domains of bimanual dexterity, depth perception, and efficiency of a singular robotic suturing task were equivalent to a panel of

ten content experts (Chen et al. 2014). Five hundred and one crowdworker assessments, at a cost of $1.00, each, were collected in less than 24 hours, compared to 24 days for the expert reviewers. White et al. then tested if crowds could discriminate levels of skill among a group of 49 surgeons of different robotic surgery experience. They identified excellent correlation ($r = 0.86$) (White et al. 2014) between three expert surgeon assessors and a panel of 30 crowdworkers/performance reviewed. The crowdworkers were "hired" through the Amazon.com Mechanical Turk platform. Both experts and crowds watched de-identified videos of a robotic suturing task and objectively assessed the skill level using domains from the Global Evaluative Assessment of Robotic Skills (GEARS) (Goh et al. 2012). Almost 1700 crowdworkers assessments were completed in less than 9 hours. In another study looking at the role crowds have when assessing urologic surgery residents in a training environment, Holst et al. tested the correlation of technical skills assessments between the "Turker" crowds (50 per video) and three blinded experts. In this study, the investigators recruited three residents of varying PGY-levels and two faculty surgeons to perform a robotic suturing task. The crowds assessed the surgical skill using GEARS with excellent agreement to expert raters (Cronbach's alpha [CA] = 0.92) (Holst et al. 2015a). As these were all dry-lab settings, Holst et al. then sought to test assessment of animate surgical skills. Twelve surgeons of varying skill levels performing a robotic porcine cystotomy (urinary bladder) closure were video recorded and assessed. In this study, the crowds demonstrated excellent ability to rate the performances relative to a panel of expert surgeon raters (CA = 0.93) (Holst et al. 2015b).

Crowdsourcing has been shown to be an alternative to expert review with excellent correlations between assessments. For basic assessments of proficiency, it is a feasible alternative that can be used for increased efficiency and cost-effectiveness. It still faces many barriers, most apparent the adoption and trust from surgeons.

Surgical Portfolios

As trainees are more objectively assessed, training programs have begun to document surgical progress. This has been done in multiple ways, including resident surgical case logs, documentation of surgical skills through evaluations, new evaluations within a simulated environment, and lastly, with surgical portfolios. Surgical portfolios are surgical cases that have been captured on video to allow for assessment of surgical skill, independent and viewer feedback, and to track surgical progress. Surgical portfolios are made by multiple portable, scalable audio and video software. This enhances the ability to review operative cases. Cases can be assessed in real time or after the fact as a means of debriefing and providing feedback on performance. Multi-camera systems also allow for the assessment of other pertinent function in the operating arena including communication, teaching ability, leadership, and teamwork. This is most easily used within laparoscopic and robotic-assisted surgery, but can be used in all surgical platforms. Care is taken, as always, to avoid possibility of patient identification through what is recorded.

With the continuation of surgical proficiency testing, there may be a time when surgical portfolios are used not only by program directors, but future employers wishing to see objective data demonstrating surgical proficiency and excellence.

CONCLUSION

With the advent of new surgical technologies, it is vitally important to use the best teaching methods of the past to create innovative and appropriate methods for the present and future. Surgical training has historically been defined by progressive responsibility in the operating room, mostly subjective assessment of operative skills, and without standard evaluation of technical and cognitive skills related to a given surgical procedure. With these new surgical technologies, the ability to continue to give progressive responsibility in the operating room becomes difficult when there is one surgeon controlling the surgical console. The rapid adoption of the robotic surgical platform has made it necessary for residency and fellowship programs to require validated robotic surgical training curricula into their programs.

The RTN is one current system that is validated that programs have begun to use, but there needs to be global adoption of one system that is best for programs, especially as the specific metrics and outcomes necessary for evaluation and credentialing continue to be defined. With the FRS and Fundamentals of Robotic Gynecologic Surgery currently underway, the future is bright with a possible simulation-based course that will allow for basic proficiency to be taught and assessed at all programs. A disciplined approach to online learning, practice on simulators in addition to graduated intraoperative experience with structured case-by-case evaluation is critical in order to integrate robotic into a training program.

The shift away from many traditional surgical approaches has now placed increased focus on appropriate training and credentialing of many minimally invasive surgical teachings. As more objective data will be used for both training and credentialing, feedback within simulation, video capture of surgical procedures, scalable strategies for objective skills assessment, and surgical portfolios will come to the forefront for appropriate training in minimally invasive surgery.

REFERENCES

Carlin AM. 2007. Effect of the 80-hour work week on resident operative experience in general surgery. *Am J Surg* **193**(3):326–9.

Chen C, White L, Kowalewski T, et al. 2014. Crowd-Sourced Assessment of Technical Skills: A novel method to evaluate surgical performance. *J Surg Res* **187**:65–71.

Goh AC, Goldfarb DW, Sander JC, et al. 2012. Global evaluative assessment of robotic skills: Validation of a clinical assessment tool to measure robotic surgical skills. *J Urol* **187**:247–52.

Holst D, Kowalewski TM, White LW, et al. 2015a. Crowd-sourced assessment of technical skills: An adjunct to urology resident surgical simulation training. *J Endourol* **29**:604–9.

Holst D, Kowalewski T, White LW, et al. 2015b. Crowd-sourced assessment of technical skills (C-SATS): Differentiating animate surgical skill through the wisdom of crowds. *J Endourol* **29**(10):1183–8.

James, J. 2012. Pay-for-performance. Health Affairs. Health Policy Brief. 11 Oct. 2012. Web (accessed July 21, 2015).

Kairys JC. 2008. Journal of American College of Surgeons. *J Am Coll Surg* **206**(5):804–11.

Kane SM. 2010. Duty hour restrictions, ambulatory experience, and surgical procedural volume in obstetrics and gynecology. *J Grad Med Ed* **2**(4):530–5.

Lendvay T, Comstock B, Averch T, et al. 2014. Crowd-Sourced Assessment of Technical Skills (C-SATS): validation through the Basic Laparoscopic Urologic Surgery (BLUS) curriculum, MP27-02. *J Endourol* **28**(S1):P1-A316 [DOI:10.1089/end.2014.3500].

Livingston SA, Zieky MJ. 1982. *Passing Scores: A Manual for Setting Standards of Performance on Education and Occupational Tests.* Princeton, NJ: Educational Testing Service.

Martino M. Robotic Training Network. Curriculum. https://robotictraining.org/curriculum (accessed July 21, 2015).

Medicare.gov. 2015. Linking quality to payment. https://www.medicare.gov/hospitalcompare/linking-quality-to-payment.html (accessed July 21, 2015).

Polavarapu HV. 2013. 100 Years of Surgical Education: The Past, Present, and Future | The Bulletin. American College of Surgeons. Web (accessed July 21, 2015).

Ranard BL, Ha YP, Meisel ZF, et al. 2014. Crowdsourcing–harnessing the masses to advance health and medicine, a systematic review. *J Gen Intern Med* **29**:187–203.

Reznick R, Regehr G, MacRae H, et al. 1997. Testing technical skill via an innovative "Bench Station" examination. *Am J Surg* **180**:226–30.

Savage N. 2012. Gaining wisdom from crowds. *Communications of the ACM* **55**(3):13–5.

Siddiqui NY, Galloway ML, Geller EJ, et al. 2014. Validity and reliability of the robotic objective structured assessment of technical skills. *Obstet Gynecol* **123**(6):1193–9.

Smith R, Patel V, Satava R. 2014. Fundamentals of robotic surgery: A course of basic robotic surgery skills based upon a 14-society consensus template of outcomes measures and curriculum development. *Int J Med Robot* 10:379–384.

Surowiecki J. 2005. *The Wisdom of Crowds.* New York, NY: Anchor.

White L, Kowalewski T, Brand T, et al. 2014. PD6-08 Crowd-sourced assessment of technical skills (C-SATS TM). Fast, economical and accurate assessment of robotic surgery. *J Urol* **191**(4):e133.

Winckel CP, Reznick RK, Cohen R, et al. 1994. Reliability and construct validity of a Structured Technical Skills Assessment Form. *Am J Surg* **167**(4):423–7.

39 Meta-analysis of survival data

Srdjan Saso, Jayanta Chatterjee, Ektoras Georgiou, Sadaf Ghaem-Maghami, Thanos Athanasiou, and Angeles Alvarez-Secord

SURVIVAL DATA IN GYNECOLOGIC ONCOLOGY

Survival analysis is a valuable statistical tool in medicine as it deals with all possible factors that can lead to death of a biological organism (in the case of medicine, a human). It is a collection of statistical procedures that involve the modeling of time-to-event data; therefore the outcome variable of interest is time until an event (*death* being the "event") occurs.

By performing survival analysis in gynecologic oncology (GO), the hope is that valuable questions can be answered, thus allowing us to expand upon the existing knowledge and improve current management protocols for the benefit of patients.

Important questions that one encounters in GO are as follows (Figure 39.1):

a. What is the fraction of the cancer population that will survive past a certain time?
b. At what rate will the patients die or relapse, if they manage to survive?
c. How does a particular type of surgery/management protocol improve or worsen survival odds?
d. Can multiple causes of death or failure be taken into account?

Time-to-event outcomes help to answer such questions by considering three factors: (1) whether an event takes place; (2) the time at which the event occurs, i.e., when the period of observation starts and finishes; and (3) time between response to treatment and recurrence or relapse-free survival time (also called disease-free survival time). However, prior to commencing the analysis, the terms "time" and "event," as well as their relationship to each other, must not be left ambiguous. In GO, a cure for ovarian cancer may not be possible, but it is hoped that a new intervention will increase the duration of survival. Therefore, although a similar number of deaths may be observed, it is hoped that a new intervention will decrease the rate at which they take place, so disease-free survival may not be altered but overall survival is prolonged at a given time.

The aims of this chapter are to introduce an important branch of statistical analysis to the GO surgeon, to demonstrate the relevance of meta-analysis to enlarging and improving the management of gynecologic practice, to focus on survival data meta-analysis and describe the process required to conduct it thoroughly and precisely, to illustrate the drawbacks that can arise when carrying out a survival data meta-analysis, and to discuss alternate meta-analytical methods that can be utilized in the field of gynecologic oncology.

WHAT IS A META-ANALYSIS?

Historically, clinical decisions in GO were derived from two broad medical areas: gynecology and oncology; these decisions were based on personal experience, unquestioned use of methods suggested by senior colleagues, and recommendations from clinical authorities. The progress of absorbing higher forms of evidence into the clinical knowledge base has been slow. This is more evident in surgical practice (which makes up a significant part of the practice within GO) where the proportion of systematic reviews and randomized controlled trials (RCTs) in leading surgical journals stands at 5% (Panesar et al. 2006).

Moral-ethical obligations, legal liability, and health economic rationing have heralded the advent of evidence-based healthcare in the last few decades. To ensure the best possible outcomes for patients, clinicians are increasingly required to implement best practices and continuous quality improvement processes within the clinical environment. This inextricably involves the application of the best available knowledge, usually in the form of scientific research, to guide clinical decision making. Hence, the use of clinical research is no longer an option but a necessity. However, problems remain for a practicing GO clinician as to what constitutes "best available knowledge" and in particular which type of research should be used (Figure 39.2).

Information Overload

With increasing pressures of being a practicing clinician (Royal College of Surgeons of England 2009), two problems remain. One is the ability to synthesize and apply the best evidence to improve patient care, bearing in mind that the average clinician would have to read 19 original articles each day in order to keep up with advances in his/her chosen field (Davidoff et al. 1995). Furthermore, this problem is compounded by the recent information explosion in the biomedical field in the last quarter century as can be evidenced by the dense cornucopia of articles and journals which are now readily accessible and searchable through a variety of online web-based bibliographic databases like PubMed and EMBASE. In addition to the huge volume of literature, its scattered nature poses further problems. Every time a new article appears, readers must compare new findings with the existing scope of evidence to come to a reframed overall clinical conclusion.

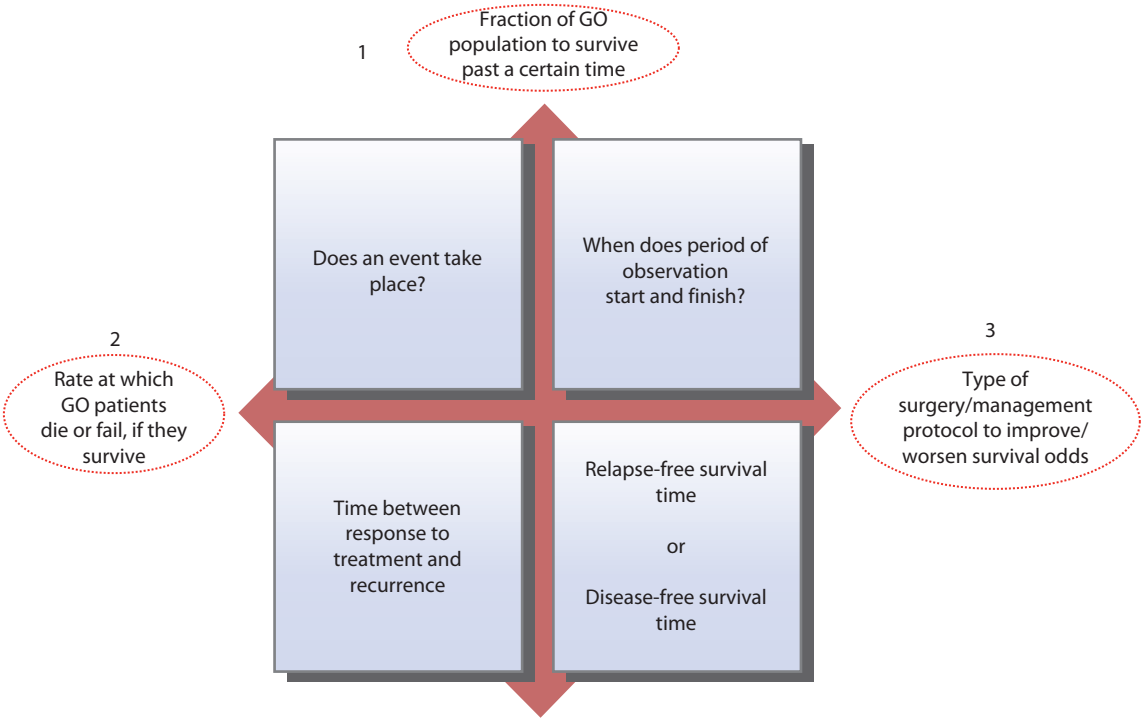

Figure 39.1 Time-to-event outcomes: How to use them to answer cancer survival related questions?

Conflicting Results

The presence of conflicting results among individual research studies does not improve matters. Not only could inconsistent results and conclusions be attributed to the statistical play of chance but it might also be due to the presence of systematic error from poorly designed study methodology. This would entail the need to critically analyze each individual trial for study quality, adding an extra dimension of burden to the clinician.

Narrative Review and its Shortcomings

The narrative review partially resolves the problems above by providing a broad, updated, and authoritative summary of research and opinion by key leaders in a field. However, this type of review brings with it its own attendant problems where a number of review authors can provide differing viewpoints and anti-diametric conclusions from the same source material. This might be attributed to several factors like the use of an assorted mixture of ambiguous review methodologies, the lack of disclosure and transparency in techniques, the inability to statistically combine results, and the inherent introduction of subjective bias presented in the form of "expert" opinion (Williams 1998).

Limitations of RCTs

Although RCTs, when conducted properly, offer one of the more objective methods in determining the true relationship between treatment and outcome, the use of this particular type of study design also carries with it a number of limitations.

One of these limitations is the need for large numbers of participants in a trial, usually ranging from a thousand to tens of thousands of subjects, in order to ensure sufficient statistical power. This is especially so if the treatment effects being studied are small in magnitude but are still deemed clinically useful. This is further compounded by the study of rare diseases of low incidence and prevalence where an RCT might have to be conducted over a prolonged period of time to gather a sufficient number of required subjects for any statistically significant result to be derived. The presence of a latency period between exposure, treatment, and outcome will also necessitate the need for a longer-term follow-up. Hence, although this type of study design is objective and free from bias compared to other study designs, in certain situations it can prove costly in terms of time, manpower, and money.

As all groups do not have such resources in excess at their disposal, compromises are reached whereby trials are conducted anyway in smaller discrete populations. The results from such smaller studies are therefore liable to be statistically insignificant, or at best imprecise, with larger degrees of uncertainty in result estimates. With that, the overall usefulness of such RCTs is reduced.

In addition, the design of an RCT mandates that a standardized population demographic be tested in a controlled environment. In comparison with the true multivariate nature of the "real world" clinical setting, the presence of heterogeneity in ethnicity, age, and geography might make any significant result from RCTs inapplicable.

Insufficient High-Quality Trial Data (In Surgical Research)

A problem more specific to surgical literature lies in the relatively small proportion of high-quality evidence in most surgical journals. The number of surgical RCTs is indeed small, and case reports and series still are the predominant publication type. Even then, within surgical studies, there are also heterogeneous differences in study quality, such as insufficient sample size, unclear methodologies, and the use of non-clinical outcomes of interest (Sauerland and Seiler 2005).

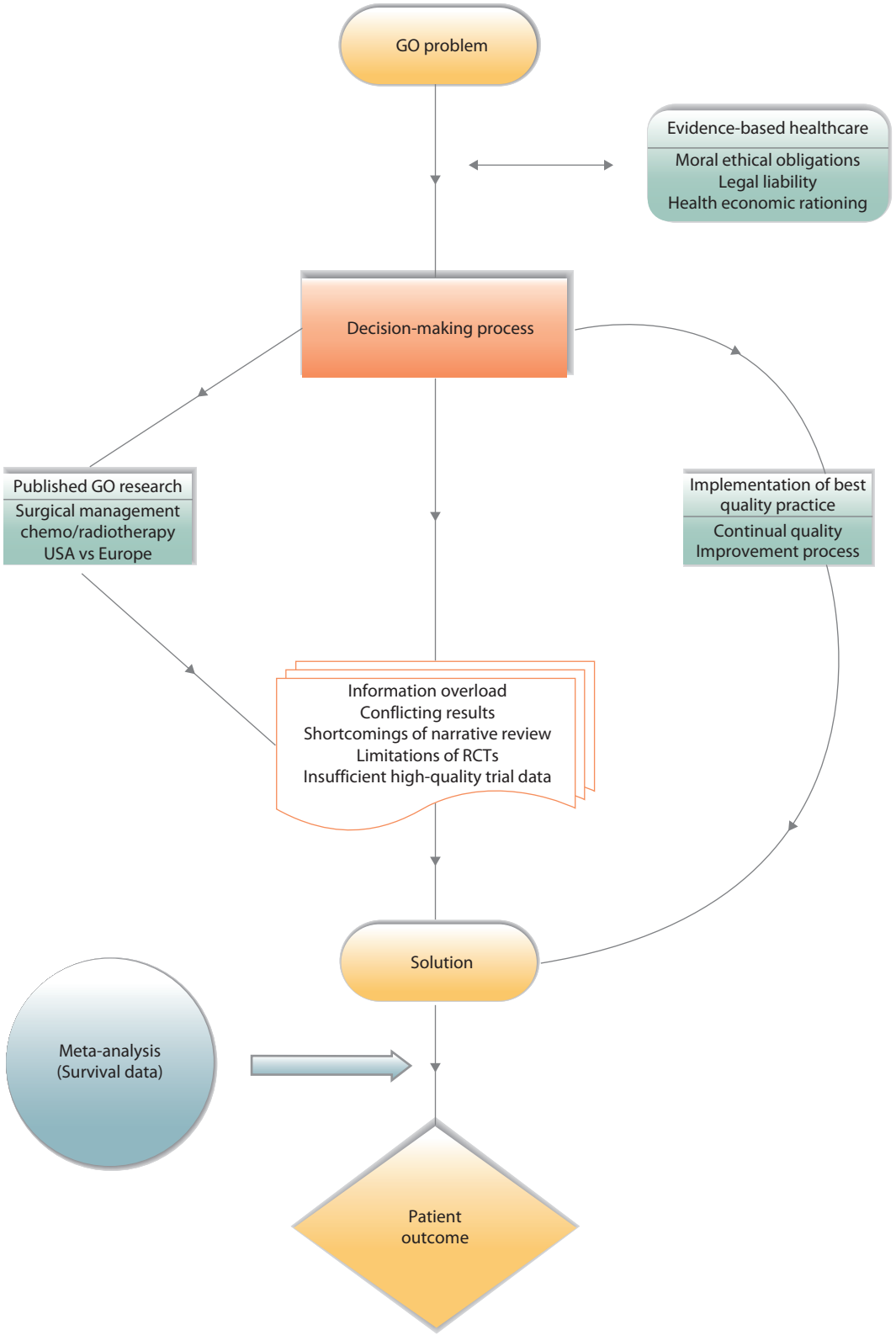

Figure 39.2 How a meta-analysis can aid the decision-making process in gynecologic oncology.

The Solution

It is evident that firstly, a more objective method of summarizing primary research is needed, and secondly, the pitfalls in RCTs must be overcome. Both these facts have spurred the development of a formalized set of processes and methodologies in the form of the systematic review and meta-analysis. In the clinical context, meta-analyses have become an important tool for finding important and valid studies while filtering out the large number of seriously flawed and irrelevant articles. Condensing the results of many trials allows the reader to obtain a valid overview on a topic with substantially less effort involved.

Meta-Analysis Defined

A systematic review is defined as the objective, transparent, and unbiased location and critical appraisal of the complete scope of research in a given topic and the eventual impartial synthesis and if possible, meta-analysis, of individual study findings. Therefore, in order to address a specific research aim, a systematic review collates all evidence that fits pre-specified eligibility criteria.

In a systematic review, two types of synthesis can be performed: a qualitative synthesis where primary studies are summarized, as in a narrative review, and a quantitative synthesis where primary studies are statistically combined. This quantitative synthetic component is termed a meta-analysis: "the statistical quantitative integration of individual study findings to get an overall summary result" (Glass 1976). A common misunderstanding is that a meta-analysis is identical to a systematic review and the terms can be used interchangeably as synonyms. In truth, a meta-analysis is actually a subset component of a systematic review.

A meta-analysis is also not only limited to the summarization of RCT data. Different study designs, data types, and follow-up spans, as illustrated in Figure 39.3, could be also used in a meta-analysis. More details with regard to the usage of meta-analyses most relevant to GO, i.e., meta-analysis of survival data together with its attendant pros and cons, are discussed later. For now, emphasis is given to the aims of meta-analysis in general.

The aims of a meta-analysis are many:

- Critical appraisal of individual studies
- Analysis for presence of and reasons behind between-study variances
- Exposure of areas of research that might be methodologically inadequate and require further refinement
- Exposure of knowledge gaps and areas of potential future research possibilities

Each meta-analysis is composed of a discrete number of steps:

- Formulation of a specific question to be addressed with a clearly stated set of objectives
- Definition of eligibility (inclusion and exclusion) criteria for preliminary studies to be included
- Systematic search which identifies and locates all potentially eligible relevant studies, both published and unpublished
- Critical appraisal of each individual study via the use of explicit appraisal criteria
- Performance of a variety of statistical methods to assess for heterogeneity between studies
- Impartial unbiased analysis and assessment of the validity of the results
- Creation of a structured presentation, and synthesis to state and discuss findings and characteristics of collected information

A meta-analysis can facilitate the synthesis of results for a number of scenarios where the findings of individual studies show: (a) no effect because of a small sample size; (b) varying directions of effect; and (c) effects versus no significant effects.

All of these findings can be commonly encountered among surgical topics. A meta-analysis may serve to combine findings from similar studies to help increase the power to detect statistical differences (Ng et al. 2006).

Advantages over Narrative Reviews

From the above, we conclude that the shortcomings of narrative reviews can be readily improved since: (a) the presence of explicit inclusion and exclusion criteria ensures the comprehensiveness of the review, while in the process minimizing the inclusion of bias within individual studies; (b) the presence of a meta-analysis can provide a quantitative summary of the overall effect estimate; (c) differences between study methodologies

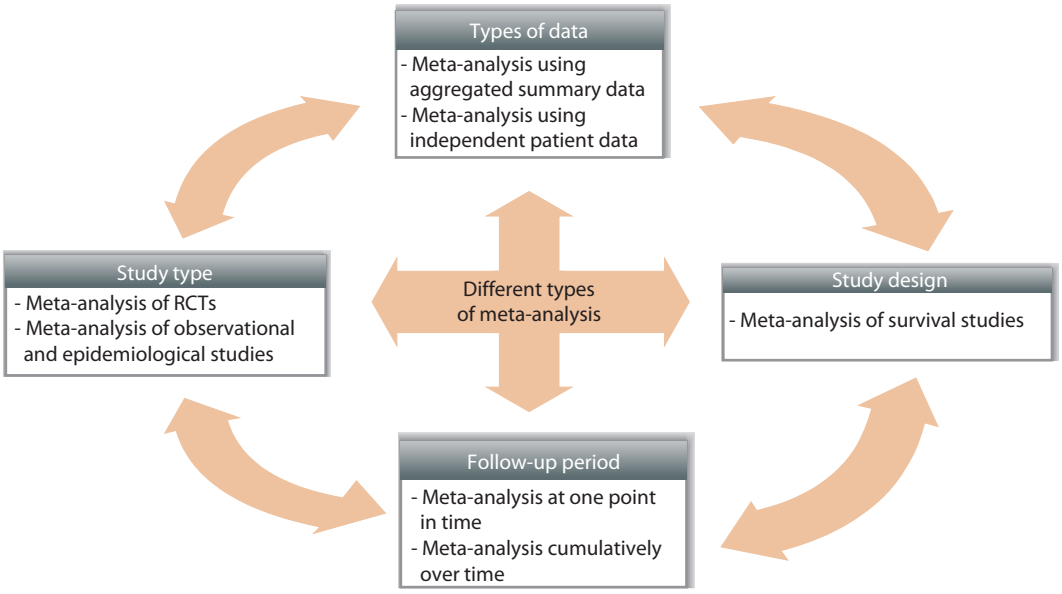

Figure 39.3 What types of meta-analysis can be used in surgical research?

that affect results can be explored; and (d) adherence to a strict scientific design with transparent methodology in analysis ensures objectivity and reproducibility of findings.

Narrative reviews by nature also tend to be generically broad and all-encompassing. The systematic review, in contrast, puts forward specific questions to answer, which increases the applicability of such reviews in the clinical context.

Advantages over Randomized Controlled Trials

The use of a meta-analysis for the purpose of conducting a systematic review enhances the statistical power of a group of RCTs, since the pooling of data from individual studies would increase the study population. With an increase in statistical power comes an increase in the precision of findings, and thereby a reduction in both uncertainty and ambiguity. Systematic reviews can also enhance the applicability of a trial, since the pooling and analysis of data from different RCTs with varied patient groups can reveal any heterogeneity or homogeneity of findings.

Systematic reviews and meta-analyses play an important role in summarizing and application of scientific surgical research data. Their undertaking has become a cornerstone of forming clinical decisions and guidelines, and in the process has given us a better understanding of the areas in need of further research.

Meta-Analysis of Survival Data

Survival data (SD) meta-analysis is a particular type of meta-analysis that attempts to qualitatively assess cancer studies by analyzing the main outcome of interest: "time to an event." As explained above, healthcare interventions in GO aim to prolong disease-free survival in cancer, thereby affecting the time until an event happens, a possible outcome that can be focused on in studies of GO treatments. However, to derive survival data, *time to the event* (rather than whether the event happens) becomes the choice outcome of investigation.

"Time" itself in SD meta-analysis means survival time; this can either be time "survived" from complete remission to relapse or progression, or time from diagnosis to death. SD analysis offers the best statistical method to analyze "time-to-event" data found in GO research mainly because the "event of interest" does not occur in all individuals during a particular follow-up period. Therefore survival data cannot be analyzed in the same way as continuous data, even though time is a continuous variable. This non-observation or non-experience of the "event of interest" by the relevant patients after a period of follow-up is referred to as "censoring"; i.e., patients' survival times are *censored* and this results in the true "time-to-event" being unknown (Tierney et al. 2007).

SD analysis allows a statistician, and in turn a clinician, to deal with this particular problem of censoring. It is assumed that the censoring is uninformative; therefore those patients who are censored (i.e., have been lost to follow-up) have the same survival prospects as those who continue to be followed. Two related functions, the survivor function and the hazard function, can be applied to address and model SD, as well as adequately deal with the issue of censoring. The survivor function represents the probability that an individual survives from the time of origin to some time beyond time *t*. It directly describes the survival experience of a study cohort, and is usually estimated by the Kaplan–Meier method. More importantly, for the purposes of performing an SD meta-analysis, the hazard function gives the instantaneous potential of having an event at a time, given survival up to that time. It is used primarily as a diagnostic tool or for specifying a mathematical model for survival analysis. Time-to-event outcomes are most appropriately analyzed using hazard ratios (HRs), which take into account the number and timing of events, and the time until last follow-up for each patient who has been censored. We shall deal with these aspects in greater detail in the next section (Tierney et al. 2007).

Odds ratios (ORs) or relative risks (RRs) are mathematical quantities applied in more generalized forms of meta-analysis. They measure the number of events and are appropriate for measuring dichotomous outcomes, but are less suitable for analyzing time-to-event outcomes. Dichotomous measures in a meta-analysis of time-to-event outcomes leads to additional problems. For example, the process can involve combining trials reported at different stages of maturity, with variable follow-up, resulting in an unreliable and difficult to interpret type of estimate. Also, if individual trials do not contribute data at each time point, the final estimate can be greatly misleading. Finally, if the time points are subjectively chosen by the systematic reviewer or selectively reported by the trialist, one can see how this could lead to the problem of bias (Tierney et al. 2007).

CONDUCTING A SURVIVAL DATA META-ANALYSIS

Importance of Careful Planning

A valid SD meta-analysis requires the same careful planning as any other research study, with particular attention necessary to develop details of design and implementation (Figure 39.4) (Berman and Parker 2002).

Essentially, there are two goals to any type of meta-analysis. One is to summarize the available data and the other is to explain the variability between the studies. Ideally, all studies being meta-analyzed should have similar patient characteristics and similar outcomes of interest. In reality, a certain degree of variability is expected between studies, and this is the impetus for performing a meta-analysis (Berman and Parker 2002). Variability is assessed by subgroup analysis, heterogeneity assessment, and sensitivity analysis, all of which add "flavor" to the meta-analysis.

The steps involved in a detailed research protocol for an SD meta-analysis are no different than for any other type of meta-analysis:

- Definition of study objectives and formulation of gynecological oncology problem
- Establishment of inclusion and exclusion criteria
- Collection and analysis of data
- Reporting of results

Defining the Objectives of the Study

The first step is to identify the problem. This includes specifying the oncological disease, management, and population of interest, the specific treatments or exposures studied, and the various clinical or biological outcomes investigated.

Defining the Population of Studies to be Included

In order to solve a distinct problem, a discrete and objective statement of inclusion and exclusion criteria for studies can

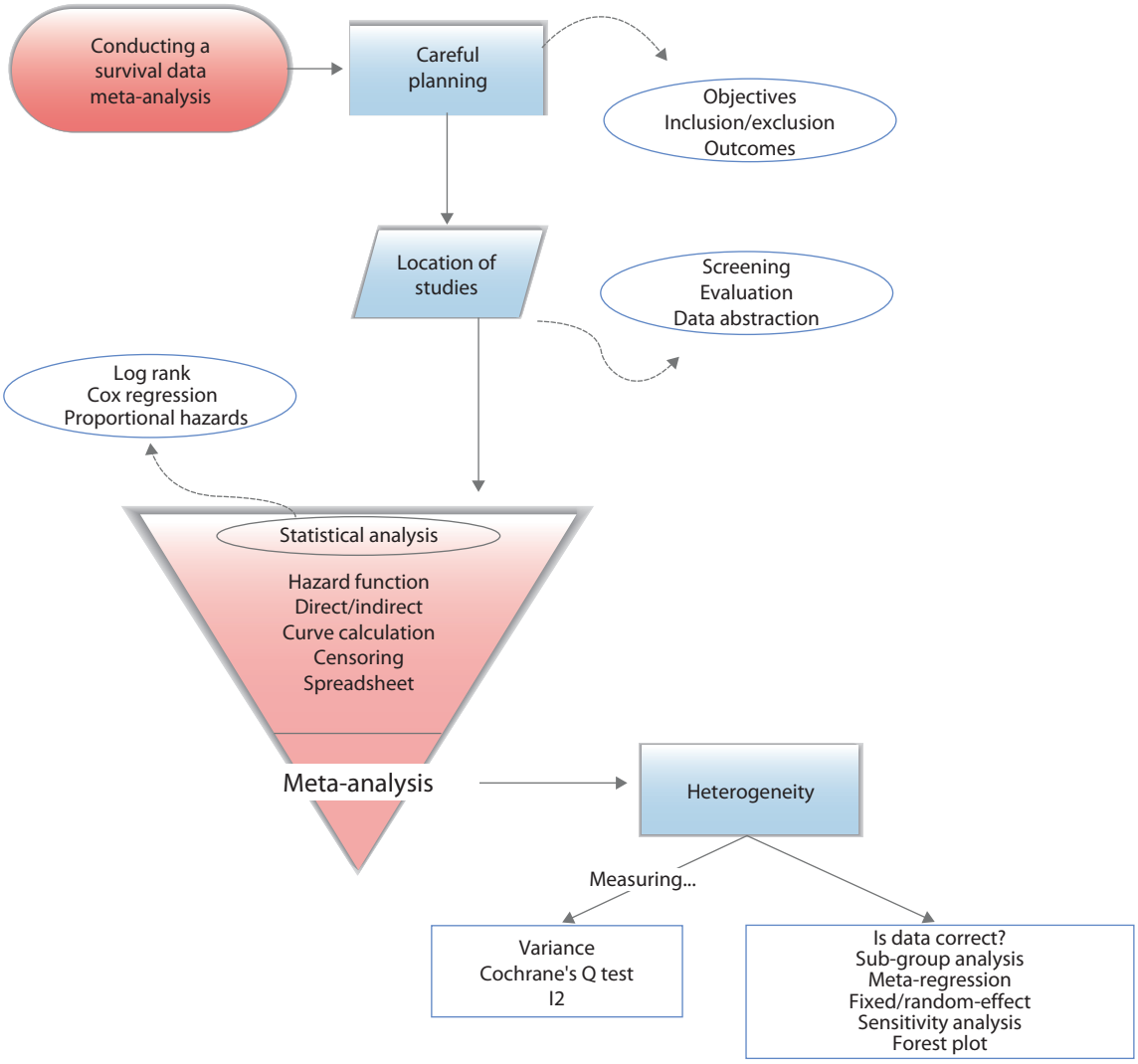

Figure 39.4 Conducting a survival data meta-analysis.

be created. This is crucial in a meta-analysis, helping to eliminate selection bias. These criteria need to be specified in the SD meta-analysis protocol in advance. Any inclusion criteria must include the following.

Study Type

It must be decided from the onset whether only RCTs will be included, although there is constant debate and research with regard to this (Stroup et al. 2000, Thompson and Pocock 1991). A hierarchy of evidence has been developed which allows for different types of studies to be included in the analysis. Naturally, the lower the level of evidence of a type of study, the lower the validity of the meta-analysis (Olkin 1995). For more advanced types of meta-analysis, different study designs can also be included. This is termed a "taleo-analysis," which although deemed the best of both worlds, has its own limitations and is outside the scope of this work.

Patient Characteristics

These include age, gender, and ethnicity, presenting condition, comorbidities, duration of cancer, and method of diagnosis.

Treatment Modalities

For the condition in question, the allowable treatment type (surgery, chemotherapy, radiotherapy, novel modalities), dosage, duration, and conversion from one treatment to another should be addressed.

Defining the Outcome Measures

Most studies have multiple outcome measures. The protocol for the SD meta-analysis should specify the outcomes that will be studied (Berman and Parker 2002). There are two schools of thought. The researcher can either focus on one or two primary outcomes or make it a "fishing expedition" and assess as many outcomes as possible.

Locating All Relevant Studies

This is by far the most important, frustrating, and time-consuming part of the meta-analysis. A structured search strategy must be used. This usually involves starting with databases such as NLH Medline, PubMed, EMBASE, CINAHL, and even Google Scholar. There are different search strategies for the

various databases, and effective use must be made of MeSH headings, synonyms, and the "related articles" function in PubMed. It is worth getting a tutorial with a librarian on how to obtain high-yield searches that include most of the required (published) studies.

Screening, Evaluation ,and Data Abstraction

A rapid review of manuscript abstracts will eliminate those that are fit for exclusion because of inadequate study design, specific population, and duration of treatment or study date. If the published material is just an abstract, there must be sufficient information to evaluate its quality. There must also be summary statistics to put into the meta-analysis, available either from the written material or in writing from the investigator. It is essential that when the available written information is insufficient for the meta-analysis, strenuous efforts be made to contact the principal investigator to obtain the information required in order to reduce the effect of publication bias. This becomes even more important for material that has not been formally published and can only be obtained from the principal investigator (Berman and Parker 2002).

The next step is to collect the full papers. The data will then have to be extracted and added to a predesigned data extraction form. The use of two independent observers to extract the data helps to avoid errors. Extraction of all patient demographics and baseline characteristics from the included studies and clinical outcomes of interest follows. A table incorporating all the extracted data can then be created that shows all the variables and their values from all the studies included in the meta-analysis. In addition, it is essential to ascertain how well matched the studies for various variables are. This is done by scoring them accordingly and noting the overall quality of the studies. No consensus on this issue exists in meta-analysis literature. Quality scores can be used in several ways: as a cutoff, with the meta-analysis including only studies above a predetermined minimum score; as a weighing value, with studies with higher quality scores being given more weight in the analysis; or as a descriptive characteristic of the study, used in explaining study variability and heterogeneity (Jadad et al. 1996, Moher et al. 1995). Blinding observers to the names of the authors and their institutions, the names of the journals, sources of funding, and acknowledgments can lead to more consistent scores (Jadad et al. 1996).

Statistical Methods for Calculating Overall Effect

SD can be analyzed in several ways, using *log-rank tests* and *proportional hazards/Cox regression*, with the obtained results then used for meta-analysis. Once analyzed, data should ideally be combined before commencing with meta-analytical work. Four methods for combining SD exist: (1) iterative generalized least-squares, (2) meta-analysis of failure-time data with adjustment for covariates, (3) non-linear regression, and (4) log relative risk. However, explanation of the above is beyond the scope of this chapter.

Hazard Function and Cumulative Hazard Function

SD meta-analysis can be performed using dichotomous outcomes. They can be created from the data (e.g., death at particular time intervals: 3 months, 1 year, 3 years, 5 years) and subsequently analyzed as such. This avoids the problem of censoring, and if all the data is collected, the actual analysis is not a burdensome task. However, this approach can only be used when all participants have been followed up to or beyond the time point used for the analysis.

For this reason, SD meta-analysis is most appropriately performed with hazard ratios (HR) as the effective measure of choice. Conventionally labeled λ, the hazard function (from which one derives HR) is defined as the event rate at time t conditional on survival until time t or later (that is, $T \geq t$). The hazard function is always positive, $\lambda(t) \geq 0$, and its integral over $[0,\infty]$ must be infinite, thus allowing the hazard function to increase or decrease. HRs involve the number and timing of events, as well as SD that has been censored. The ratio can be estimated from specific methods that carefully manipulate published or other summary data (Parmar et al. 1998, Tierney et al. 2007, Williamson et al. 2002). This can be done from existing data, which if available to estimate an odds ratio (OR) or relative risk (RR), will also be sufficient to calculate a HR.

Performing a Meta-Analysis Based on Hazard Ratios

To perform a meta-analysis based on HRs, one must first estimate an HR from each trial, followed by pooling the calculated HRs in an overall meta-analysis. This conveniently follows the approach of more common meta-analyses of other effect measures, such as the RR or OR.

One can use two different methods to arrive at the intended target:

1. A fixed-effect meta-analysis of HRs can use the following equation derived from Peto's method (Tierney et al. 2007, Yusuf et al. 1985):

$$\text{Pooled logHR} = \left(\sum \text{logrank observed} - \text{expected events}\,(O-E)\right) / \left(\sum \text{logrank variance}\,(V)\right)$$

   where $\sum$ denotes "sum of"; the *logrank observed minus expected events* $(O - E)$ and the *logrank variance* (V) are derived from the number of events and the individual times to event on the research arm of each trial.
2. Alternatively, one can use *variance of the logHR* (V^*) and the *log HR* to apply the "inverse variance approach" (Parmar et al. 1998, Tierney et al. 2007):

$$\text{Pooled logHR} = \left(\sum \log \text{HR}/V^*\right) / \left(\sum 1/V^*\right)$$

Therefore if the following measures are presented in a trial report: HR, V, logHR, V^*, O, and/or E, one can employ these statistics to perform a fixed-effect and random-effect meta-analysis. However, if not reported, it would be necessary to estimate the above statistics for each trial in order to combine them in a meta-analysis.

Calculation of Summary Statistics from Trial Reports

First, V and V^* can be derived from each other (Tierney et al. 2007):

$$V^* = 1/V \text{ and } V = 1/V^*$$

where V = logrank variance and V^* = variance of the logHR

Tierney et al. (2007) have published a statistical instruction "manual" where the authors describe some of the methods which can be used to calculate an HR by extracting information on the effects of interventions presented in a number of different ways. They specifically demonstrate how the summary statistical data presented in trial reports can be used to estimate the *O-E*, *V*, *V**, HR, and logHR when these values are not listed.

We now list these methods in a hierarchical order, pointing out which summary statistics, when reported, are enough to work out the others as well as the all-important HR, thus permitting a GO clinician to perform an SD meta-analysis. The direct methods are preferable because they make no assumptions.

"Direct" Calculation

1. Trial report presents **O & E** on research and control arm
2. Trial report presents **O & E** on research arm and **log rank V**

"Indirect" Calculation

3. Trial report presents **HR** and **confidence intervals (CIs)**
4. Trial report presents **HR** and **events in each arm** (and the randomization ratio is 1:1)
5. Trial report presents **HR** and **total events** (and the randomization ratio is 1:1)
6. Trial report presents **HR**, **total events**, and **numbers randomized on each arm**
7. Trial report presents ***P*-value** and **events in each arm** (and the randomization ratio is 1:1)
8. Trial report presents ***P*-value** and **total events** (and the randomization ratio is 1:1)
9. Trial report presents ***P*-value**, **total events**, and **numbers randomized on each arm**

"Kaplan–Meier" Curve Calculation

10. Trial report presents **Kaplan–Meier curve** and **information on follow-up**
11. Trial report presents **Kaplan–Meier curve** and **numbers at risk**

The issue of "censoring" forces an analysis to undergo a necessary adjustment. This will mean that a clinician performing an SD meta-analysis will have to choose between the two curve methods, depending on which method is more reliable to address the adjustment issue. If both curve methods are possible, the following factors can help decide which method to opt for: (a) report/estimation of minimum and maximum follow-up; (b) report of the number at risk at how many time intervals; and (c) event rate between those time points. Further research is required to assess how well all of the methods perform according to variations in trial size, lengths of follow-up, or event rates. Also, in order to optimize the use of available data, a combination of the two curve methods would be welcome (Tierney et al. 2007).

The resulting summary statistics calculated from the above methods can then be used in the SD meta-analysis procedures found in statistical and meta-analysis software. It is important to state that a number of these methods will be required for most of the trials reported. Thus, more than one method can be adequately used for a particular trial. Importantly, they should be used in preference to using a pooled OR or RR or a series of ORs or RRs at fixed time points, which in turn improves the interpretation of systematic reviews and "time-to-event outcome"; i.e., SD meta-analyses.

The formulae employed to perform the above calculations as well as the pros and cons of such methods are explained in further detail in the actual report (Tierney et al. 2007). Appendix A describes a Microsoft Excel spreadsheet developed by Tierney et al. that calculates the summary statistics and therefore allows a clinician to avoid the laborious task of performing all the calculations by hand for each trial (a potentially error-prone and time-wasting process).

Heterogeneity between Study Results

Variance between the overall effect sizes in each study might not be due to random sampling variation but instead could be due to the presence of other factors inherent within individual studies. This effect size variation due to slightly different study designs is termed heterogeneity and is defined as the presence of variability among studies included in a meta-analysis. Three different types of heterogeneity exist in literature: (1) clinical heterogeneity (variability in the participants, interventions, and outcomes studied); (2) methodological heterogeneity (variability in study design and risk of bias); and (3) statistical heterogeneity (variability in the intervention effects being evaluated in the different studies), usually a consequence of clinical or methodological diversity, or both, among the studies (The Cochrane Collaboration 2002).

Clinical variation will lead to heterogeneity if the intervention effect is affected by the factors that vary across studies; most obviously, the specific interventions or patient characteristics. In other words, the true intervention effect will be different in different studies. Statistical heterogeneity manifests itself in the observed intervention effects being more different from each other than one would expect due to random error (chance) alone (The Cochrane Collaboration 2002).

Measuring Heterogeneity

There are three ways to measure heterogeneity. First, one can assess the between-studies variance: τ^2. However, this depends mainly on the particular effect size metric used. The second is Cochrane's *Q*-test, which follows a chi-square distribution to make inferences about the null hypothesis of homogeneity. The problem with Cochrane's *Q*-test is that it has poor power to detect true heterogeneity when the number of studies is small. Because neither of the above methods has a standardized scale, they are poorly equipped to make comparisons of the degree of

homogeneity across meta-analyses (Huedo-Medina et al. 2006). A third more useful statistic for quantifying inconsistency is I^2 [= $[(Q - df)/Q] \times 100\%$], where Q is the chi-squared statistic and df is its degrees of freedom (Higgins et al. 2003). This statistic is easier to utilize because it defines variability along a scale-free range as a percentage from 0% to 100%. This describes the percentage of the variability, and in effect estimates what is due to heterogeneity rather than sampling error (chance). Heterogeneity could be considered substantial when this value is greater than 50%. The importance of the observed value of I^2 depends on (a) magnitude and direction of effects and (b) strength of evidence for heterogeneity (e.g., P value from the chi-squared test, or a CI for I^2). The theory behind the use of the I^2 statistic lies in its value of recognizing that statistical heterogeneity is inevitable, therefore moving the focus away from testing whether heterogeneity is present to assessing its impact on the meta-analysis.

Addressing Heterogeneity

A GO clinician performing an SD meta-analysis needs to have several strategies that he/she can use in order to deal with (statistical) heterogeneity identified among a group of studies included in that particular meta-analysis (The Cochrane Collaboration 2002). The description of these strategies, their application, and a step-by-step guide for their use in the context of a meta-analysis are beyond the scope of this book, but are listed here as a guide for the GO surgeon wishing to investigate further:

1. Check that the data inserted is correct
2. Do not perform the meta-analysis
3. Explore heterogeneity (subgroup analysis and metaregression)
4. Fixed-effect/random-effect meta-analysis
5. Sensitivity analysis
6. Graphical display: Forest Plot

Conducting a Meta-Analysis in the Surgical Context

The main differences between meta-analysis in surgical fields such as GO and in other fields originate from the reproducibility of treatments and variations in practice that are difficult to compare. The outcomes of a surgical procedure depend on the level of experience of an operating surgeon. This is not the case in other areas of research such as drug trials, where the intervention is consistent and the drug acts in a uniform manner. Moreover, standardization and reproducibility in surgical techniques employed by the surgeons is not always consistent. Also, poor outcomes are less likely to be reported, which further adds to publication bias (Egger et al. 2001). The experience of a surgeon is one of the key confounders during comparative trials involving interventions. Less experienced surgeons have been reported to have relatively poorer outcomes (Krahn et al. 2006). These issues have the propensity to add to study heterogeneity, thus compromising the validity of a meta-analysis of clinical trials in surgery.

Similarly, early meta-analytical assessment of a new procedure or technique may give a misleading picture of its efficacy because of issues such as lack of competence of surgeons. Competence is achieved after performing a set of tasks repeatedly. Factors determining competence include experience, equipment, and time. Procedural performance continues to improve until a plateau phase is reached. This constitutes a traditional "learning curve."

The year of publication of a study is a significant determinant of heterogeneity, as population characteristics and outcome data may change over time. Also, developments in technology and technical expertise may translate into unfavorable outcomes over a defined period. All these factors need to be considered, especially in surgical disciplines where new technologies and techniques are continuously developed and the learning curve is overcome progressively. Increasing accumulation of evidence with time improves the integrity of results reported by a meta-analysis (Lau et al. 1998).

PITFALLS IN CONDUCTING AN SD META-ANALYSIS

Although the aim of a meta-analysis is to reduce uncertainty, there are instances in which the opposite can be true. In the hierarchy of evidence, the systematic review is placed rightly at the top. However, similar systematic reviews with opposite conclusions or those that contradict well-powered high quality double-blind RCTs are still possible (Petticrew 2003).

Conflicting Results between Meta-Analysis Compared to Large-Scale RCTs

Two important questions need to be addressed. The first is whether meta-analyses of small trials agree with the results of large trials. No absolute definition exists of what constitutes a large trial, so separating small trials from large trials is not easy. Moreover, when considering the bigger picture, all trials add to the current base of evidence. The extent to which small trials agree or disagree with larger ones is a multifactorial process. Selection bias tends to skew the results. Large trials appearing in high-impact journals may have been selected because they provide new insight into the merits and weaknesses of a particular treatment. There may also be less consistency for secondary end-points than for primary end-points in different trials.

The second important question is whether meta-analyses can in fact validly substitute large trials. It is known that meta-analyses and large trials tend to disagree 10% to 23% of the time, beyond chance. Clinical trials are likely to be heterogeneous, since they address different populations with different protocols. Patients, disease, and treatments are likely to change over time. Future meta-analyses may find an important role in addressing potential sources of heterogeneity rather than always trying to fit a common estimate among diverse studies. With this, meta-analyses and RCTs must be scrutinized in detail for the presence of bias and diversity.

Why Does Bias Exist in Meta-Analysis?

Most of the factors responsible for bias are because of assumptions used when combining RCTs. The assumptions are that: (a) results of trials are true approximations to the actual true value of the outcome of study, and are different between trials due to the presence of random chance and not due to bias; (b) trials selected for combination are representative of all trials possible whether published or unpublished; and (c) studies

being combined are sufficiently homogenous in population and methodology such that they are combinable in the first place.

Types of Pitfalls in Conducting an SD Meta-Analysis

The statistical methods employed to analyze time-to-event outcomes for individual trials explained above do not remove the list of problems faced by systematic reviews and SD meta-analyses:

- Publication bias and other forms of reporting bias
- Variable quality of included RCT studies
- Bias and skew due to the presence of small study effects
- Selection bias/personal bias in the selection of studies
- Heterogeneity between individual studies

IMPACT OF BIAS ON SURVIVAL DATA META-ANALYSES

Bias

Bias primarily affects internal validity and is defined as "any process at any stage of inference tending to produce results that differ systematically from [their] true values" (Campbell 1957). It refers to "systematic error," the effect of misleading conclusions from multiple replications of the same study. Sampling variation, however, leads to different effect estimates following above replications despite "correct answers" on average. This is known as "random error" and is because of imprecision, a term not to be confused with bias/risk of bias.

Therefore, bias can cause a systematic overestimation or underestimation in outcome which leads to the garbage in, garbage out (GIGO) effect on meta-analytic results. Hence in the conduct of a meta-analysis, a key assumption will be that any variability between individual RCTs is due to random variation and not from the presence of bias.

The presence of bias and the extent to which it affects a particular study is usually related to flaws in methodological analysis, conduct, and design of clinical trials. It is more appropriate, however, to focus on "risk of bias," a more suitable phrase, because results of a study can occasionally be unbiased despite methodological flaws. In addition, variation in the results of included studies can be explained more accurately by differences in risk of bias. These differences will highlight the more rigorous studies with more valid conclusions and will indirectly help us to avoid false positive/negative conclusions.

Bias is especially of concern within small-powered unpublished studies, as the methodological quality in smaller trials might not be as vigorous as compared to larger ones where more time, effort, and money might have been involved in the trial design. Moreover, as small studies might not be published, their underlying methodology might not be assessed with as close scrutiny as during the editorial peer review process in journal publications.

Bias related to methodology design can be of five different kinds: selection, performance, detection, attrition bias, and reporting bias (Figure 39.5).

- *Selection bias:* Occurs when candidates in a study are preferentially selected into one group compared to another based on prior knowledge of their pre-existing medical condition.
- *Performance bias:* Occurs if additional treatment interventions are provided preferentially in one treatment group compared to another.
- *Detection/Assessment bias:* Arises if the knowledge of patient assignment influences the assessment of outcome. Yet again, blinding of the assessor/observer is the solution.

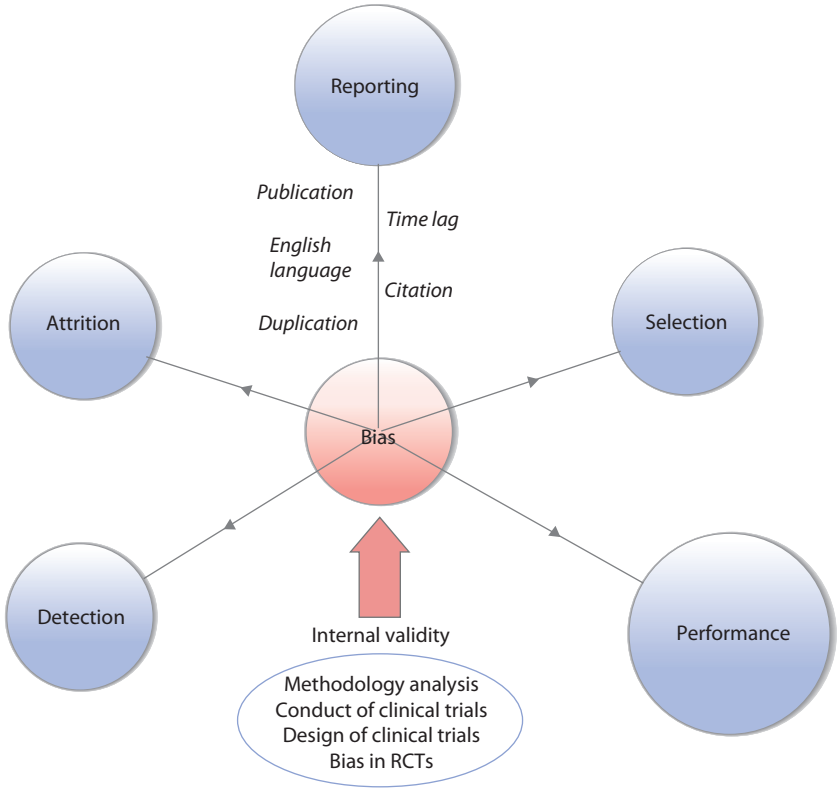

Figure 39.5 Types of bias encountered in survival data meta-analysis.

- *Attrition bias:* Arises where deviations from protocol and loss to follow-up lead to the exclusion of patients after they have been allocated to their treatment groups, causing a skew in aggregate treatment effect.
- *Reporting bias:* Occurs when systematic differences between reported and unreported variables are found. Several forms of reporting bias exist and will be dealt with in more detail in the sections below on publication bias, time lag bias, english language bias, citation bias, duplication bias and outcome reporting bias.

Assessing Potential Bias Inherent in RCTs

The use of high quality trials in a meta-analysis, ideally prospective randomized double-blind controlled trials with an intention-to-treat policy during results reporting, would eliminate many forms of bias.

The solution to selection bias is randomization, which will create groups that are equally comparable for any known or unknown potential confounding factors. Adequate *randomization* in the use of pre-generated allocation sequences and concealment of allocation would ensure a standardized group of patients in both treatment and control arms. Ideally, randomization should be instituted where neither the investigator nor the patient knows the allocation so that they are unable to guide which type of treatment should be used.

Randomization, coupled with *double blinding*, where both patients and investigators are prevented from knowing which group each patient is allocated to, would prevent detection and performance bias. The use of objective compared to subjective measurable outcomes would also further make a trial less prone to assessment bias (Campbell 1957).

To reduce attrition bias, an intention-to-treat, or "per-protocol," policy could be used. An intention-to treat policy dictates that all randomized patients should be included in the analysis and kept in their original groups, regardless of their adherence or noncompliance to the study protocol or loss to follow-up. Conversely, a per-protocol policy is where only patients who fulfil all protocol directives are included in the analysis.

As a per-protocol analysis tends to ignore patients who have ceased treatment due to possible adverse outcomes, an intention-to-treat policy is generally recommended. However, an intention-to-treat protocol also depends on the use of assumptions to determine the eventual outcome of patients' loss to follow-up. It has been recommended that the conduct of both forms of analysis and any underlying comparative differences between them would give the best level of available knowledge (Campbell 1957).

The *Cochrane Handbook for Systematic Reviews of Interventions* also describes various methods for assessing bias. It describes a tool called a "domain-based evaluation," in which critical assessments are made separately for different domains (Figure 39.6). Each type of domain, described below, assesses a specific type of bias (Higgins and Green 2008).

- *Sequence generation:* A well-designed RCT incorporates and specifies a statistically sound rule for allocating a specific intervention to each patient. This rule has to be based on a chance (random) process (e.g., computer random number generator, coin

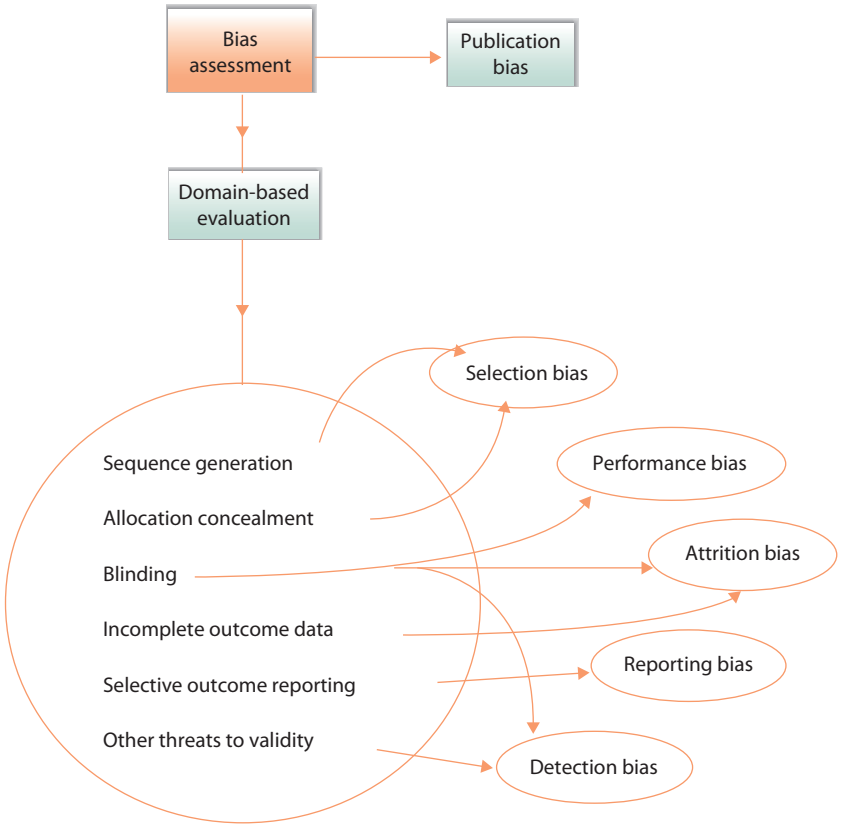

Figure 39.6 Domain-based evaluations to assess potential bias.

tossing, shuffling envelopes) and must generate an allocation sequence, thereby allowing an assessment of whether it produces comparable groups. Both this and the next domain could only score positively when assessing RCTs.

- *Allocation concealment:* Method employed to conceal the above allocation sequence in sufficient detail to determine whether allocations could have been predicted in advance, or during, enrollment. For example, using telephone or web-based randomization or sequentially numbered, sealed envelopes.
- *Blinding of participants, personnel, and outcome assessors:* Measures used to remove prior knowledge of which type of intervention a patient received from the patient undergoing the surgery and from the surgeon performing the operation.
- *Incomplete outcome data:* Lack of completeness of outcome data during the follow-up period.
- *Selective outcome reporting:* Study protocol, including the main aims and outcomes of interest, is either incomplete or written with insufficient clarity. Not all of the pre-specified outcomes are reported in the pre-specified way.
- *Other potential threats to validity:* Of interest is a detailed description of the surgical methods employed, including whether patients were operated on by one or more surgeons and in one or more hospitals, and the diagnostic methods applied to calculate the necessary outcomes (i.e., techniques and personnel).

Publication Bias

So far, only bias related to actual gathering of data have been considered, i.e., methods involved in setting up the trial. Reporting bias is, on the other hand, related to the results' publication process. "Publication bias" is the main subgroup, occurring when the publication of research is reliant upon the nature and direction of results. If the research that appears in the published literature is systematically unrepresentative of the population of completed studies, publication bias occurs. This leads to the preferential publication of certain types of trials compared to others, resulting in a fraction of studies being published in an indexed journal, leaving a larger body of research in the form of incomplete draft manuscripts, presentations, and abstracts unpublished. With this, a vast amount of research data could be omitted from indexed bibliographic databases, and thus becomes difficult to locate. This data eventually is concealed away from systematic reviewers such that not all possible clinical trials could have been included within a meta-analysis of a topic. The end result is a meta-analysis which might not be truly representative of all valid studies undertaken ending in the development of spuriously precise but inaccurate summary findings (Sterne et al. 2001). Rather frustratingly, wrong conclusions can then be drawn by readers and reviewers with dangerous consequences (e.g., use of falsely deemed safe and effective treatment).

Why Does Publication Bias Exist?

Even though there is no consistent relationship between the publication of a study with study design, methodological quality, study size, or number of study centers, the publication of a trial is more likely when it shows either a statistically significant large effect in the outcome for a new treatment (a positive trial) or when compared to existing treatments (a non-inferiority trial). The publication of a trial is less likely when there are nonsignificant findings, results with small effect sizes, or negative findings (a negative trial) (Sterne et al. 2001).

Reasons for Publication Bias in Negative Trials

Nonsignificant findings or negative findings are less likely to be published due to:

- Editorial censorship of uninteresting findings
- Subjective peer review
- Conflicts of interests
- Self-censorship dealing with publication bias

BENEFITS OF SURVIVAL DATA META-ANALYSES

A well-conducted systematic review is an invaluable tool for practitioners. A GO specialist can occasionally feel overwhelmed when trying to decide on the best management protocol for a particular cancer, especially if trying to compare between research in the United States and the UK/Europe. The sheer volume of GO literature often leads the surgeon to prefer summaries of information to publications of original investigations. The former type of evidence keeps the surgeon abreast of the goings-on on a particular GO topic. If deemed to be of high quality, a particular survival data meta-analysis can define the boundaries of what is known (Figure 39.7).

We should also acknowledge that meta-analysis (with all its subtypes) is one of the main pillars of "evidence-based health care" and can be used to make clinical, professional, and policy decisions. First, it can be extremely useful in health technology assessments and cost-effectiveness analysis. Second, meta-analyses identify gaps in GO research and identify beneficial or harmful cancer protocols. Researchers need such meta-analyses to summarize existing data, refine hypotheses, estimate sample sizes, and help define future research agendas. Without these, promising leads may be missed or studies of questions that have been already answered may be embarked upon. Industry is particularly interested in meta-analyses as it helps to direct resources to viable and beneficial health interventions.

Administrators and purchasers need integrative publications to help generate clinical policies that optimize clinical outcomes using available resources. For consumers and health policymakers who are interested in the bottom line of evidence, systematic reviews and meta-analyses can help harmonize conflicting results of research. They can be used as the basis for other integrative articles produced by policymakers, such as risk assessments, practice guidelines, economic analyses, and decision analyses.

ASSESSING THE QUALITY OF A META-ANALYSIS

Two instruments are commonly used to assess the quality of a meta-analysis: Quality of Reporting of Meta-analyses (QUOROM) checklist and Overview Quality Assessment Questionnaire (OQAQ) scale (Figure 39.7) (Shea et al. 2001).

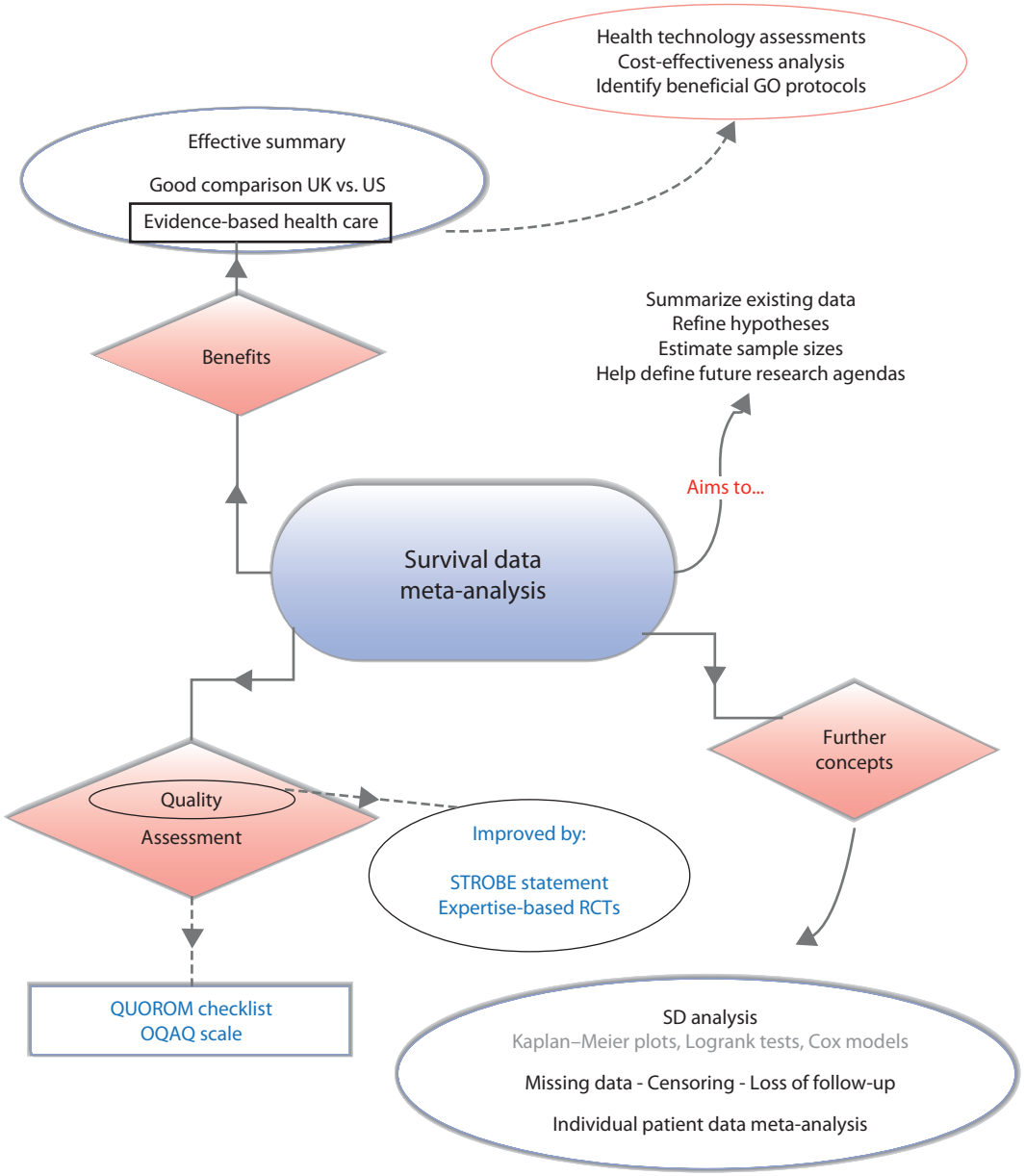

Figure 39.7 Improvements, benefits, and further concepts of survival data meta-analysis.

The QUOROM statement assesses the quality of reporting. It comprises a checklist and flow diagram and was developed using a consensus process designed to strengthen the reliability of the estimates it yields when applied by different assessors. It estimates the overall reporting quality of systematic reviews. The checklist asks whether authors have provided readers with information on 18 items, including searches, selection, validity assessment, data abstraction, study characteristics, quantitative data syntheses, and trial flow. It also asks whether authors have included a flow diagram with information about the number of RCTs identified, included and excluded, and the reasons for any exclusions. Individual checklist items included in this instrument are also answered in the following manner: "yes," "no," or "partial/cannot tell" (Moher et al. 1999).

The OQAQ scale has strong face validity, provides data on several essential elements of its development, and has an available published assessment of its construct validity. The OQAQ scale measures across a continuum using nine questions (items 1–9) designed to assess various aspects of the methodological quality of systematic reviews and one overall assessment question (item 10). When the scale is applied to a systematic review, the first nine items are scored by selecting either "yes," "no," or "partial/cannot tell." The tenth item requires assessors to assign an overall quality score on a 7-point scale (Oxman 1994).

IMPROVING THE QUALITY OF GYNECOLOGIC ONCOLOGY META-ANALYSES

The inclusion of RCTs in the process of meta-analysis can be invaluable in improving its quality. The advantages are self-evident; when conducted properly, they offer one of the more objective methods in determining the true relationship between GO treatment and outcome and are free from bias compared to other study designs (Figure 39.7).

Other benefits are more specific to the surgical practice of GO. "Expertise-based RCT" is a recent technique that offers a solution to overcoming existing biases in surgical trials and can

be applied in GO. In this type of trial, a surgeon with expertise in one of the GO procedures being evaluated is paired with a surgeon with expertise in the other procedure who should ideally be from the same institution. Subjects are randomized to treatments and treated by a surgeon who is an "expert" in the procedure. This study overcomes some of the challenges associated with traditional surgical RCTs, including the caveat that surgeons who wish to participate in traditional RCTs must be willing to perform both techniques and that a lack of expertise or belief in one of the interventions under evaluation may undermine the validity and applicability of the results (Devereaux et al. 2005). A recent survey of orthopedic surgeons found that most would consider this type of study design, as it may decrease the likelihood of procedural crossovers and enhance validity because unlike the conventional RCT, there is a low likelihood of differential expertise bias (Bednarska et al. 2008).

"Observational studies" make up a significant proportion of the existing GO surgical literature, and more specifically meta-analyses. It must be remembered that much of the research into the cause of diseases relies on cohort, case-control, or cross-sectional studies. Also, observational studies can generate significant hypotheses and have a role in delineating the harms and benefits of interventions. To ensure the robustness of reporting observational studies, the Strengthening the Reporting of Observational Studies in Epidemiology (STROBE) statement was created. It aims to assist authors when writing up analytical observational studies, support editors and reviewers when considering such articles for publication, and help readers when critically appraising published articles (von Elm et al. 2007). All these steps will add to the quality of data used in future (GO) surgical meta-analyses.

FURTHER CONCEPTS IN SURVIVAL ANALYSIS

As already described, most analyses of SD use primarily Kaplan–Meier plots, log rank tests, and Cox models. Prior to proceeding with a meta-analysis of SD manuscripts, it is worth considering limitations that might hinder an accurate portrayal of the final conclusions of each manuscript (Figure 39.7).

One of the most common problems encountered when developing survival cancer models is missing data. Trial data is reported in such a way that individuals without complete covariate data are usually omitted. This results in a final analysis with reduced power, and more importantly, with an unrepresentative subset of patients. Therefore, if substantial missing data are found, methods that could accommodate such a finding should be considered. The most straightforward improvement is a simple recommendation that authors of research papers try to be explicit about the amount of missing data for each variable and indicate how many patients did not have complete data (Clark et al. 2003). More robust is a recent powerful tool which has become increasingly available (Van Buuren et al. 1999). Multiple imputation is a framework method in which missing data are imputed or replaced with a set of plausible values. Several data sets are then constructed, each being analyzed separately, and their results are combined while allowing for the uncertainty introduced in the imputation (Clark et al. 2003).

However, this method must not be looked at as a panacea. The assumption that a model relating data absence to other measured covariates, as well as survival, exists and can be specified is inherent in the imputation method. Researchers should be aware that such assumptions are not able to be tested, and can apply sensitivity analysis instead to assess the robustness of results (Clark et al. 2003).

Another significant problem that can arise is the extent to which unmeasured factors may affect survival time because of the impossibility of knowing whether all important prognostic factors have been measured (Clark et al. 2003). Such an omission leads to the introduction of bias into the model, reduction of the predictive ability of a model, and exhibition of a large variability in patient survival. For example, omissions can occur when some individuals have a shared exposure, such as an environmental factor, which cannot be measured yet ensures that their outcomes cannot be considered independent. Such situations are encountered in multicenter and cluster randomized trials (Yamaguchi et al. 2002), and the variation between and within groups labels them "multilevel." Random-effect models that are widely used in meta-analysis can be applied to allow covariate effects to vary across groups (O'Quigley and Stare 2002). We also note that if a trial does not adjust for an important and omitted prognostic variable, the estimated treatment effect in a randomized trial may be biased even when that variable is balanced between the treatment groups (Chastang et al. 1988, Clark et al. 2003, Schmoor and Schumacher 1997).

Finally, in the authors' opinion, the exploration of cancer relapses may be more informative than focusing only on the time until the first; therefore analysis of recurrent events can make an important contribution to the understanding of the survival process.

Authors sometimes attempt to explain the above limitations because they want to "keep things simple for the readership," or there is "lack of computer software with which to perform the statistical tests." Both types of reasoning are flawed. The most important factor when conducting a statistical analysis is to ensure that the analysis applied is appropriate for the particular question in mind and that it adequately represents the survival experience of patients in the study. More advanced survival methods may admittedly convey a less straightforward message, but could allow a better understanding of the survival process. Also, recent software packages that are used more by statisticians but less by medical staff are so designed to incorporate complex statistical models.

We would like to point out that prior to conducting a meta-analysis, one must first understand and be able to interpret many and varied methods required to analyze SD. The assumptions made prior to applying the appropriate statistical methods should be clear to the relevant personnel and one must not hesitate to request help from a statistician if more complex methods are required.

META-ANALYSIS AND SOFTWARE

The process involved in conducting a meta-analysis, including the benefits and drawbacks (mainly bias and internal and external validity) of the method, has extensively been described in the literature (Saso et al. 2011). Currently, the optimum methodology involves the use of specialized software packages, which have doubled over the last decade. The choice of package is dependent on use requirements. Pre-existing commercial general statistical program suites

like SAS, STATA, and SPSS have been enhanced by the provision of add-on third-party macro-programs which provide a limited set of basic functions for meta-analysis. Stand-alone packages are purposely built for meta-analysis and tend to have a greater variety of functions available and greater methods of input, processing, and output modes. Some software is free, such as "RevMan," provided by the Cochrane Center. Others are commercial (Figure 39.7).

EVALUATING SURVIVAL DATA IN THE CONTEXT OF CLINICAL DECISION MAKING

Systematic reviews and meta-analyses can be very useful in developing treatment recommendations in clinical practice. Health care providers ideally base clinical decisions on evidence-based practice. Evidence-based practice refers to the integration of the best research evidence in helping individual patients make decisions about their care based on their personal values and beliefs. The systematic reviews described in this chapter represent the culmination of the best research evidence available and are valuable resources for clinical decision-making in GO.

Evidence-based practice includes several steps: (1) assess the patient, (2) ask the question, (3) acquire the evidence, (4) appraise the evidence, and (5) apply to the patient. Acquiring the appropriate resource(s) to address the patient question and appraising the evidence are critical steps in this process. The evidence will need to be appraised for its validity and applicability. When appraising study results, the oncology provider should interpret results in the context of the study design and limitations (Duke University Medical Center, http:// guides.mclibrary.duke.edu/c.php?g=158201&p=1036021).

Study appraisal can be challenging for several reasons. The statistical information provided should be evaluated to discern not only the statistical significance of the results, but also the clinical significance, or magnitude of the effect. Clinical significance is not clearly defined and may vary based on individual interpretation. For instance, clinical significance may refer to a large proportion of patients improving, a large magnitude of change, improvement in functioning, ≥50% reduction in symptoms, and/or it may be based on individual judgment. The effect size and confidence intervals can be useful measures of magnitude of effect and study precision. The narrowness of the confidence interval provides information regarding the precision of the estimate. Wide confidence intervals, even when the results are statistically significant, may indicate that the sample size was too small. Furthermore, evaluating the value of the surgery may be more difficult when confidence intervals are wide.

The hazard ratio expresses the relative risk of reduction and should be evaluated relative to the control arm and the absolute risk reduction achieved. The hazard ratio compares the entire distribution of the study groups over the specified time period. In contrast, median values provide a benchmark for descriptive clinical purposes but only a glimpse at one time point.

It is also important to assess the data used in systematic reviews when evaluating clinical relevance; for instance, for study designs and use of subgroup analyses. Subgroup analyses may provide useful information regarding therapeutic options when they are properly performed. Subgroup analyses may identify the consistency and magnitude of treatment effects among different groups of patients. However, over interpretation of exploratory post-hoc subgroup analyses should be avoided, and credibility appraised cautiously. It is also important to recognize improper subgroups, those that group patients characterized by a variable measured after randomization and potentially affected by treatment, when interpreting study results. With regard to study designs, healthcare providers should be cognizant of differences between superiority, equivalence, and non-inferiority experimental designs. For instance, non-inferiority cannot be claimed in a clinical trial that used a superiority statistical design unless the authors pre-stated a margin of equivalence.

After a critical appraisal of study results and limitations as well as clinical significance, the provider is ready to apply the findings. The integration of the research evidence with clinical expertise, as well as patient values and preferences using evidence-based practice, will hopefully assist with decision-making and optimize clinical outcomes.

CONCLUSION

Like primary research, meta-analysis of SD involves a stepwise approach to arrive at statistically justifiable conclusions. It has the potential to provide an accurate, quantitative appraisal of the literature. It may objectively resolve controversies. The greatest challenge in conducting a meta-analysis on a clinical topic is often the lack of available data on the subject because there are few high-quality published studies with an acceptable degree of heterogeneity.

With regard to a meta-analysis of SD, the extraction of accurate data in order to derive a log HR is difficult. This can be explained by the process: (a) estimations via mathematical conversions from the provided summary data, of which there might not be enough of sufficient quality in trial reports to derive out HR; and (b) direct measurements from a Kaplan–Meier survival curve, which can possibly introduce random measurement error and hence reduces the accuracy of results.

If meta-analyses are to continue to have a role in surgical decision-making, a key area in GO, clinicians need to be able to perform, assess, compare, and communicate the quality of meta-analyses, particularly in areas where several meta-analyses are available.

APPENDIX A

Instructions on how to apply the calculations spreadsheet in order to facilitate the computational aspects for calculating a HR and/or associated statistics (summarized from Tierney et al. 2007).

The user enters:

- All reported summary statistics
- Data extracted from Kaplan-Meier curves

The spreadsheet produces:

- The HR, 95%CI, lnHR, V, and O-E by all possible methods
- Censoring using the minimum and maximum follow-up or the reported numbers at risk, to obtain similar summary statistics

- Graphical representations of the input data for comparison with the published curves, to assist with data extraction or to highlight data entry errors
- Results from all methods in a single output screen, to facilitate comparison

REFERENCES

Bednarska E, Bryant D, Devereaux PJ, et al. 2008. Orthopaedic surgeons prefer to participate in expertise-based randomized trials. *Clin Orthop Relat Res* **466**:1734–44.

Berman NG, Parker RA. 2002. Meta-analysis: Neither quick nor easy. *BMC Med Res Methodol* **9**:10.

Campbell DT. 1957. Factors relevant to the validity of experiments in social settings. *Psychol Bull* **54**:297–312.

Chastang C, Byar D, Piantadosi S. 1988. A quantitative study of the bias in estimating the treatment effect caused by omitting a balanced covariate in survival models. *Stat Med* **7**:1243–55.

Clark TG, Bradburn MJ, Love SB, et al. 2003. Survival analysis part IV: Further concepts and methods in survival analysis. *Br J Cancer* **89**:781–6.

Davidoff F, Haynes B, Sackett D, et al. 1995. Evidence based medicine: A new journal to help doctors identify the information they need. *BMJ* **310**:1085–6.

Devereaux PJ, Bhandari M, Clarke M, et al. 2005. Need for expertise based randomised controlled trials. *BMJ* **330**:88.

Duke University Medical Center. What is Evidence-Based Practice (EPB)? http://guides.mclibrary.duke.edu/c.php?g=158201&p=1036021.

Egger M, Smith GD, Schneider M. 2001. Systematic reviews of observational studies. In: M. Egger M, Smith GD, Altman D, editors. *Systematic Reviews in Healthcare*. British Medical Association, pp. 211–227.

Evidence-Based Medicine Working Group. 1992. Evidence-based medicine: A new approach to teaching the practice of medicine. *JAMA* Nov 4;**268**(17):2420–5.

Glass GV. 1976. Primary, secondary and meta-analysis of research. *Educ Res* **5**:3–8.

Higgins J, Green S. 2008. *Cochrane Handbook for Systematic Reviews of Interventions*. Version 5.0.0 ed. Oxford: The Cochrane Collaboration.

Higgins JP, Thompson SG, Deeks JJ, et al. 2003. Measuring inconsistency in meta-analyses. *BMJ* **327**:557–60.

Huedo-Medina TB, Sanchez-Meca J, Marin-Martinez F, et al. 2006. Assessing heterogeneity in meta-analysis: Q statistic or I2 index? *Psychol Methods* **11**:193–206.

Jadad AR, Moore RA, Carroll D, et al. 1996. Assessing the quality of reports of randomized clinical trials: Is blinding necessary? *Control Clin Trials* **17**:1–12.

Krahn J, Sauerland S, Rixen D, et al. 2006. Applying evidence-based surgery in daily clinical routine: A feasibility study. *Arch Orthop Trauma Surg* **126**:88–92.

Lau J, Ioannidis JP, Schmid CH. 1998. Summing up evidence: One answer is not always enough. *Lancet* **351**:123–7.

Moher D, Cook DJ, Eastwood S, et al. 1999. Improving the quality of reports of meta-analyses of randomised controlled trials: The QUOROM statement. Quality of reporting of meta-analyses. *Lancet* **354**:1896–1900.

Moher D, Jadad AR, Nichol G, et al. 1995. Assessing the quality of randomized controlled trials: An annotated bibliography of scales and checklists. *Control Clin Trials* 16:62–73.

Ng TT, McGory ML, Ko CY, et al. 2006. Meta-analysis in surgery: Methods and limitations. *Arch Surg* **141**:1125–30.

Olkin I. 1995. Meta-analysis: Reconciling the results of independent studies. *Stat Med* **14**:457–72.

O'Quigley J, Stare J. 2002. Proportional hazards models with frailties and random effects. *Stat Med* **21**:3219–33.

Oxman AD. 1994. Checklists for review articles. *BMJ* **309**:648–51.

Panesar SS, Thakrar R, Athanasiou T, et al. 2006. Comparison of reports of RCTs and systematic reviews in surgical journals: Literature review. *J R Soc Med* **99**:470–72.

Parmar MKB, Torri V, Stewart L. 1998. Extracting summary statistics to perform meta-analyses of the published literature for survival endpoints. *Stat Med* 17:2815–34.

Petticrew M. 2003. Why certain systematic reviews reach uncertain conclusions. *BMJ* **326**:756–8.

Royal College of Surgeons of England. Implementing the EWTD: College Response. Available from http://www.rcseng.ac.uk/publications/docs/ewtd_communicaion.html/attachment_download/pdffile (accessed April 1, 2009).

Sackett DL, Rosenberg W, Muir Gray J, et al. 1996. Evidence based medicine: What it is and what it isn't. *BMJ* **312**.

Saso S, Panesar SS, Siow W, et al. 2011. Systematic review and meta-analyses in surgery. In: Darzi A, Athanasiou T, editors. *Evidence Synthesis in Healthcare: A Practical Handbook for Clinicians*. Berlin Heidelberg: Springer-Verlag, pp. 67–113.

Sauerland S, Seiler CM. 2005. Role of systematic reviews and meta-analysis in evidence-based medicine. *World J Surg* **29**:582–7.

Schmoor C, Schumacher M. 1997. Effects of covariate omission and categorization when analysing randomized trials with the Cox model. *Stat Med* **16**:225–37.

Shea B, Dube C, Moher D. 2001. Assessing the quality of reports of systematic reviews: QUOROM statement compared to other tools. In: Egger M, Smith G, Altman D, editors. *Systematic Reviews in Health Care: Meta-Analysis in Context*. BMJ Publishing. pp. 122–9.

Sterne JA, Egger M, Smith GD. 2001. Systematic reviews in health care: Investigating and dealing with publication and other biases in meta-analysis *BMJ* **323**:101–5.

Stroup DF, Berlin JA, Morton SC, et al. 2000. Meta-analysis of observational studies in epidemiology: A proposal for reporting. Meta-analysis Of Observational Studies in Epidemiology (MOOSE) group. *JAMA* **283**:2008–12.

The Cochrane Collaboration. 2002. *Diversity and heterogeneity: Identifying statistical heterogeneity*. The Cochrane Collaboration open learning material 2002 [cited; Available from http://www.cochrane-net.org/openlearning/HTML/mod13-3.htm.]

Thompson SG, SJ Pocock. 1991. Can meta-analyses be trusted? *Lancet* **338**:1127–30.

Tierney JF, Stewart LA, Ghersi D, et al. 2007. Practical methods for incorporating summary time-to-event data for meta-analysis. *Trials* **8**:16.

Van Buuren S, Boshuizen HC, Knook DL. 1999. Multiple imputation of missing blood pressure covariates in survival analysis. *Stat Med* **18**:681–94.

von Elm E, Altman DG, Egger M, et al. 2007. The Strengthening the Reporting of Observational Studies in Epidemiology (STROBE) statement: Guidelines for reporting observational studies. *Lancet* **370**:1453–7.

Williams CJ. 1998. The pitfalls of narrative reviews in clinical medicine. *Ann Oncol* **9**:601–5.

Williamson PR, Tudur Smith C, Hutton JL, et al. 2002. Aggregate data meta-analysis with time-to-event outcomes. *Stat Med* **21**:3337–51.

Yamaguchi T, Ohashi Y, Matsuyama Y. 2002. Proportional hazards models with random effects to examine centre effects in multicentre cancer clinical trials. *Stat Methods Med Res* **11**:221–36.

Yusuf S, Peto R, Lewis JA, et al. 1985. Beta blockade during and after myocardial infarction: An overview of the randomized trials. *Prog Cardiovasc Dis* **27**:335–71.

40 Pain management

Andrew Lawson and Paul Farquhar-Smith

INTRODUCTION

This chapter deals with the management of pain in gynecological malignancy. It does not deal with the management of pain arising from surgical intervention but with pain arising from the effects of the tumor and its treatment (Figure 40.1).

Pain from gynecological malignancy is common. Over 60% of patients with ovarian cancer experienced pain before diagnosis or recurrence. Physical and social function is adversely affected, and pain is also associated with higher distress levels.

Pain in patients may be caused by

1. Direct effects of tumor
2. Treatment of cancer and cancer symptoms; e.g., radiotherapy-induced plexopathy, chemotherapy-induced neuropathy, and constipation secondary to opioid drug administration
3. Secondary problems from malignancy; e.g., muscle spasm and musculoskeletal problems after prolonged immobilization

Patients may therefore complain of different types of pain. These pains can be divided into nociceptive and neuropathic pain. Nociceptive pain (such as caused by tumor erosion or muscle spasm) may be sharp and stabbing, cramping, or throbbing. However, compared to somatic pain, nociceptive pain from the viscera tends to be less localized and can be referred. Neuropathic pain (resulting from a lesion in or damage to the nervous system) is often described as shooting, lancinating, or burning and is often associated with paresthesias and dysesthesias. Local infiltration by tumor into nerves can cause visceral neuropathic pain. Pain generally increases in severity with increasing tumor mass, later in the course of the disease and with metastatic disease. For organs involved in gynecological malignancy, like other viscera, noxious stimuli include distension, smooth muscle contraction, inflammation, and ischemia. Gynecological tumors may become ischemic and necrotic and result in pain. Moreover, some tumors release inflammatory mediators as they invade other structures, thus increasing the noxious potential. Tumor involvement with a hollow viscus can cause pain from distension and muscle contraction. Bowel obstruction is especially associated with ovarian cancer and is an important source of pain.

VISCERAL PAIN PHYSIOLOGY

Anatomy to Explain Clinical Features

Sensory primary afferent neurons that arise in visceral organs are predominantly C and Aδ fibers (somatic sensory primary afferent includes Aβ fibers). Furthermore, the total number of primary afferents is only 5% of their somatic counterparts, probably since the visceral system does not require accurate localization. Pelvic viscera also receive dual innervation from sympathetic and parasympathetic systems. The nociceptive system for the visceral gynecologic organs undergoes primary (in the visceral organ) and secondary (central) sensitization, similar to the somatic system. Inflammation and the release of mediators of the inflammatory soup provides the main impetus that increases activation and sensitization of the nociceptive neurons increasing the afferent input into the spinal cord that drives the development of central sensitization. Visceral central sensitization may be more easily induced than somatic since the N-methy-D-aspartate (NMDA) receptor is involved in unsensitized spinal transmission and therefore more readily activated by primary sensitization. This process is augmented by recruitment of silent afferents, sensory neurones quiescent (or "silent") in the resting state but activated by inflammation, which may account for up to 90% of the total number of visceral primary afferents.

Similar central processes mediate the development of referred pain whereby pain from the viscera is perceived to be in a superficial somatic site. Moreover, pain from one viscus can exacerbate pain from another by a "viscero-visceral sensitization" mechanism. For example, pain from uterine cancer is exacerbated by pain from bowel obstruction.

The consequence of these mechanisms is that pain from gynecological malignancy is poorly localized: pain from a specific lesion may exist in several areas, migrate to different areas, and be referred superficially. Autonomic induced symptoms of sweating and tachycardia may be associated with these pains. Furthermore, distension, ischemia, and tumor-induced inflammation more readily induce the proalgesic effects of central sensitization, potentially increasing the pain burden in these patients.

Pain from Compression of Pelvic Structures

The female pelvic organs are in close proximity to a wide variety of structures within the pelvis, both neurological and vascular. Thus local infiltration by a cervical, endometrial, and/or ovarian tumor may cause pain due to pressure on any of the structures within the pelvis. The pelvis acts as a conduit for the neurovascular supply of the lower limbs, and consequently nerve involvement may occur at sites of entry and exit from the pelvis as well as within. For example, the sciatic nerve may be affected by malignant infiltration at the point formation at the level of the nerve roots in the sacral plexus. The femoral nerve on the pelvic sidewall may be damaged due to either hematoma or malignant infiltration, as may the obturator nerve. Pressure or obliteration of the lymphatic drainage may produce lymphedema of the lower limb. Compression of the venous supply to the lower limb may produce venous edema leading to swelling that may be painful. Although metastatic spread to bone is relatively rare in gynecological malignancy, tumors can invade bone directly.

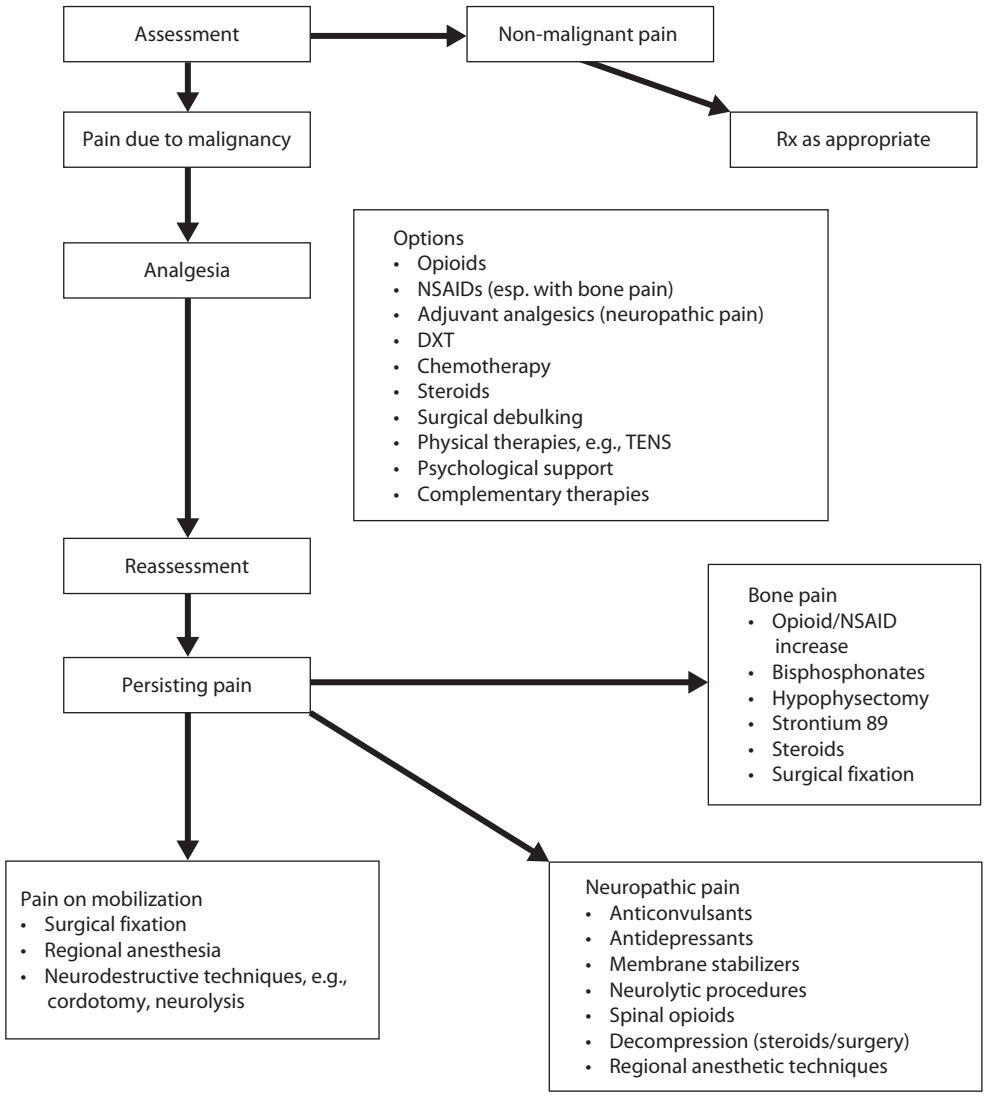

Figure 40.1 Algorithm for the management of continuing pain in patients with gynecological malignancy. DXT, deep x-ray therapy; NSAID, nonsteroidal anti-inflammatory drug; TENS, transcutaneous electrical nerve stimulation.

INITIAL MANAGEMENT OF PAIN

In patients with gynecological malignancy who have not had a curative surgical procedure, it is unlikely that simple analgesics alone will provide satisfactory pain relief. In the author's opinion, patients such as these who have pain should be treated with strong opioid analgesics from the start. Slow-release morphine preparations and/or immediate release oral morphine preparations remain the gold standard of pain relief in patients with malignant disease. There is no convincing evidence that any of the newer analgesics have significant advantages over morphine. In the UK and in other parts of the world, diamorphine (diacetylmorphine, heroin) is commonly used as an analgesic agent. Table 40.1 lists opioid drugs and dosage regimens. Opioids may also be given by the subcutaneous route either intermittently or using a syringe driver. Fortunately, effective management of pain is achievable for the majority of patients with gynecological malignancy who are using opioid-based analgesic drugs in combination with drugs for the treatment of neuropathic pain. For those with pain resistant to standard treatments, perseverance and referral to a specialist at a chronic pain center is likely to result in an improved quality of life.

Table 40.1 Opioid Drugs in Severe Pain Equianalgesic Dose for 70-kg Adults

Drug	IM (mg)	PO (mg)	Interval (hrs)
Diamorphine	5	N/A	2–3
Hydromorphone	1.5	7.5	2–3
Methadone	10	10–15	8–48
Morphine	10	40–60	2–4
Oxycodone	N/A	30	4–6

To optimize analgesia, patients should at the same time be prescribed non-opioid analgesics. Paracetamol (acetaminophen) is widely prescribed in the UK and overseas and has the advantage of being available without prescription. Patients with bone infiltration may also respond to nonsteroidal anti-inflammatory drugs such as indomethacin, diclofenac, and ketorolac, although the evidence for this remains limited. Care should be taken in patients with impaired renal, hepatic, or cardiovascular function and in those who have reversible airway obstruction. Steroids may be beneficial in reducing the compressive effects of tumors.

NEUROPATHIC PAIN

Patients who have nerve involvement may well respond to the usage of antidepressant, anticonvulsant, and membrane-stabilizing agents, although direct evidence in cancer patients is scarce. Pain due to radiation damage to the lumbosacral plexus is likely to be resistant to standard analgesic techniques and in such circumstances antineuropathic agents may be the first-line drugs of choice.

INTERVENTIONAL TECHNIQUES IN GYNECOLOGICAL MALIGNANCY

Epidural and Spinal Opioids

Where standard routes of analgesic administration have failed, the epidural route using a percutaneous epidural catheter can provide optimal analgesia. The benefits of opioid administration by the spinal route have been acknowledged for some time and there is clear evidence that some patients find epidural analgesia of a higher quality with a diminished incidence of unwanted side effects such as nausea, drowsiness, and constipation. Epidural catheters can be inserted percutaneously and brought out through the skin or attached to a number of subcutaneous administration devices (Figure 40.2). Subcutaneous pumps have been used to facilitate epidural and spinal analgesia, as have subcutaneous ports through which opiates can be given on a daily or more frequent basis.

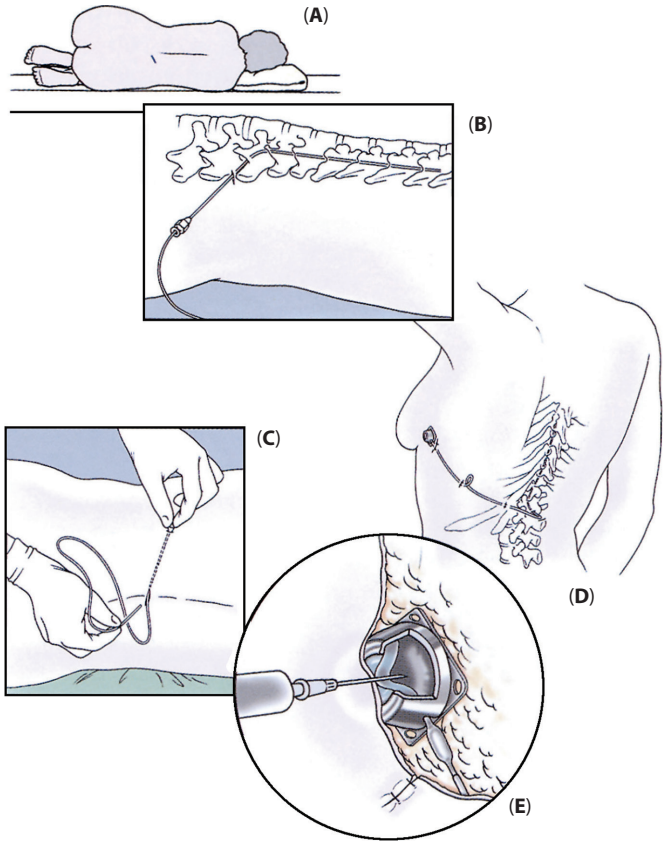

Figure 40.2 Insertion of tunneled epidural catheter. (**A**) Position of patient: insertion marked at L2. (**B**) Insertion of 16-gauge epidural catheter via a Tuohy needle. (**C**) Second incision over eleventh rib allows the catheter to be moved over the anterior chest wall. (**D**) Portal attached to catheter after tensioning loop and second tunnel. (**E**) Injection technique.

Many opioids currently on the market have been used in the epidural space, but the most commonly used are morphine and (in the UK) diamorphine. Opiates have been given also in combination with local anesthetic drugs to improve the quality of analgesia. This may be particularly helpful in end-of-life cases where there is extreme and intractable pelvic and neuropathic pain. Drugs such as clonidine, midazolam, and baclofen have also been given epidurally in such circumstances.

Superior Hypogastric Plexus Block (Neurolytic)

The superior hypogastric plexus is formed by the union of the lumbar sympathetic chains in branches of the aortic plexus in combination with the parasympathetic fibers originating in the ventral routes of S2–S4, which form the pelvic splanchnic nerve, some fibers of which ascend from the inferior hypogastric plexus to join the superior hypogastric plexus. The superior hypogastric plexus is situated anterior to the lower part of the body of the fifth lumbar vertebra and the upper part of the sacral promontory. It is retroperitoneal and is often called the presacral nerve. The superior hypogastric plexus gives off branches to the ovarian plexuses.

Technique

The patient is placed prone and two 20- or 22-gauge needles are advanced from a point roughly 5 to 7 cm lateral to the L4/L5 interspace to a point just anterior to the L5/S1 interspace. These needles are inserted under fluoroscopic or CT guidance, and injected contrast material demonstrates that the needles are anterior to the vertebral body and not in any of the vascular structures. Following aspiration, neurolytic solution of aqueous phenol (6%) 8 to 10 mL is injected, or for local anesthetic blockade, 10 to 20 mL 0.5% bupivacaine (Figure 40.3).

Blockade of Ganglion Impar

Ganglion impar block has been described for the treatment of intractable perineal and pelvic pain where the sympathetic nerve seems to predominate. The ganglion impar is a retroperitoneal structure located at the level of the sacrococcygeal junction. The technique involves placement of a needle through the skin under x-ray control to lie anterior to the coccyx close to the sacrococcygeal junction. Retroperitoneal location of the needle is demonstrated by the injection of contrast medium. Local anesthetic and/or neurolytic solutions can then be injected. Care must be taken to ensure that puncture of the rectum and accidental trans-bone injection into the epidural space are avoided (Figure 40.4).

Presacral Neurectomy

Presacral neurectomy has been used for the control of intractable pelvic pain, whether due to malignancy or chronic pelvic pain syndromes. The technique involves the division of the superior hypogastric plexus at the L5/S1 region as described above. The presacral nerves can be divided as an open procedure or via the laparoscope. Laparoscopic presacral neurectomy is probably the technique of choice (Figures 40.5 and 40.6). Bowel preparation may be useful preoperatively to decompress the bowel. Under direct vision, an incision is made in the peritoneum over the lateral sacral promontory

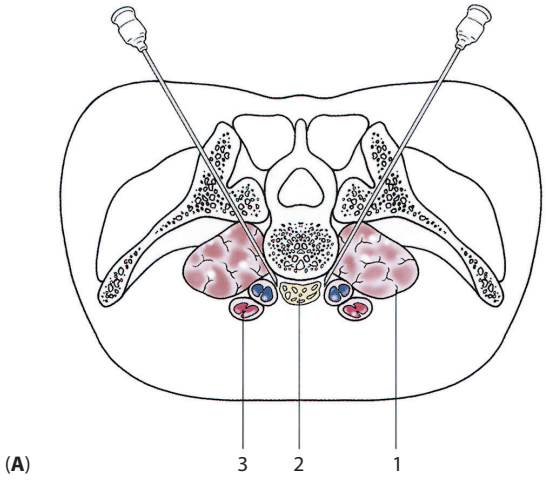

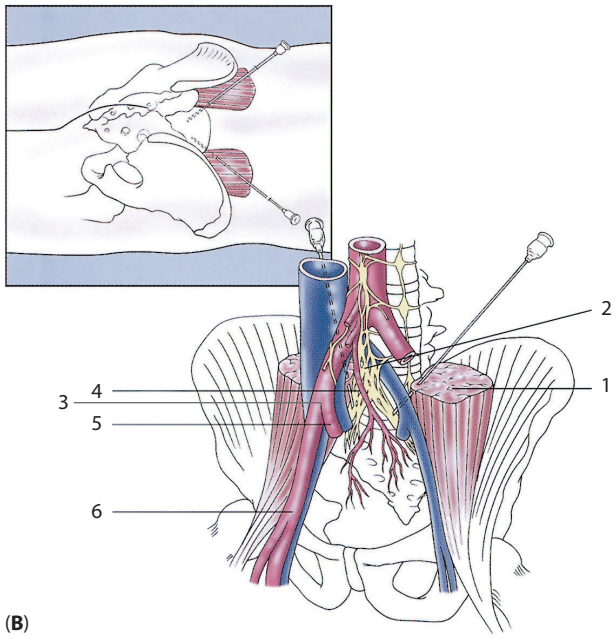

Figure 40.3 Superior hypogastric plexus block. (**A**) Sagittal section at L5. (**B**) Pelvic anatomy. 1: Psoas major muscle; 2: superior hypogastric plexus; 3: bifurcation of iliac vessels; 4: superior rectal artery; 5: internal iliac artery and vein; 6: external iliac artery and vein.

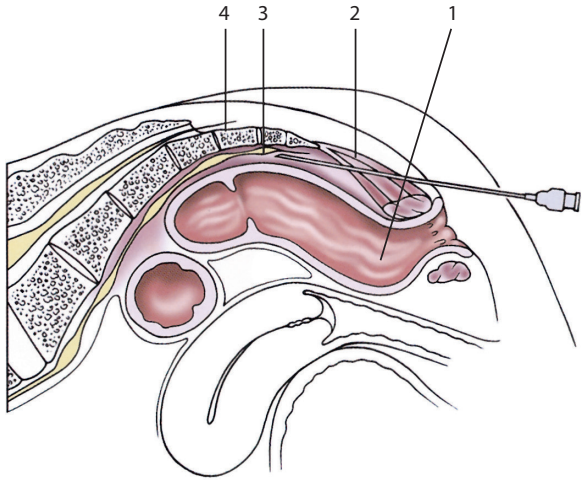

Figure 40.4 Blockade of ganglion impar. 1: Rectum; 2: anococcygeal ligament; 3: ganglion impar; 4: sacrococcygeal junction.

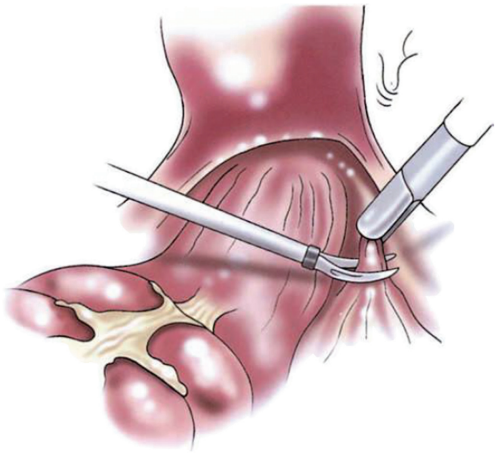

Figure 40.5 Presacral neurectomy: opening the presacral space.

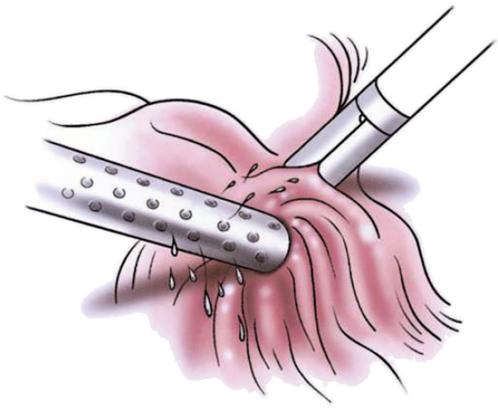

Figure 40.6 Presacral neurectomy: opened spaces.

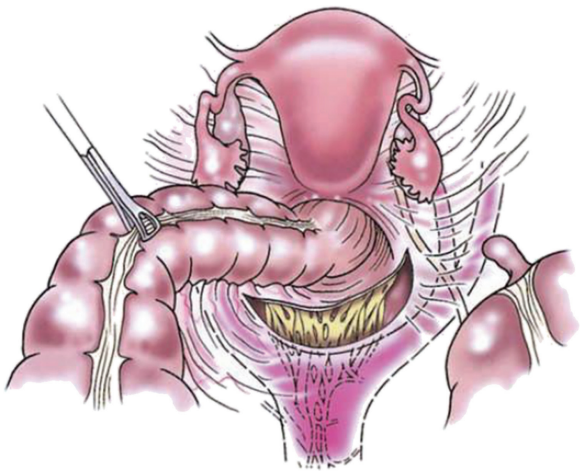

Figure 40.7 Sacral plexus exposed.

and dissecting forceps are used to dissect out the hypogastric plexus. It may then be ligated, cut, or cauterized (Figure 40.7).

BIBLIOGRAPHY

Hanks G, Cherny NI, Christakis NA, et al., eds. 2010. *Oxford Textbook of Palliative Medicine*. 4th ed. Oxford University Press.

Hester J, Sykes N, Peat S, eds. 2011. *Interventional Pain Control in Cancer Pain Management*. Oxford University Press.

Sickandar S, Dickenson A. 2012. Visceral pain: The ins and outs, the ups and downs. *Current Opin Support Pall Care* **6**(1):17–26.

Smith JR, Del Priore G. 2016. *Women's Cancers; Pathways to Living*. Imperial College Press.

Sykes N, Bennett, Yuan CS, eds. 2008. *Clinical Pain Management*. 2nd ed. Cancer Pain. London: Hodder Arnold.

41 Palliative care

Sarah Cox and Catherine Gillespie

WHAT IS PALLIATIVE CARE?

The World Health Organization defines palliative care as "an approach that improves the quality of life of patients and their families facing the problem associated with life-threatening illness, through the prevention and relief of suffering by means of early identification and impeccable assessment and treatment of pain and other problems, physical, psychosocial and spiritual" (WHO 2017).

Modern palliative care has evolved from terminal care to a more dynamic multidisciplinary approach that tries to address priorities from the individual patient's perspective. It recognizes that some patients will need palliative care input from diagnosis or soon after. It places emphasis on the need to support the family and carers and to continue that support into bereavement. Above everything is the concept of enabling people to "live well" despite having a fatal diagnosis.

Specialist palliative care requires a team approach to identify and address the issues that are having a negative impact on the patient's quality of life. Specialist palliative care teams are now available as a resource to most hospitals, primary care teams, and specialist inpatient units or hospices.

The clinical nurse specialist in gynecologic oncology complements the palliative care team in the cancer unit or cancer center. They will often have met the patient in the early stages of their disease and will be key in providing continuity of care, as they tend to be the most consistent health professional involved in the patient's management. They will liaise between health professionals and be an important source of information and emotional support to patients throughout their treatment. Hospices collect together a wide range of disciplines with specialist expertise to provide emotional, practical, and financial help as well as medical and nursing care. Social workers are essential to help with such complex problems as psychosocial counseling, financial and housing issues, immigration, preparing young families for loss, and bereavement support. Occupational therapists help patients cope with sometimes rapidly increasing disability, and may enable patients to remain in their own homes for longer. Physiotherapists are essential to maximize mobility and to teach relaxation techniques and non-pharmacological management of breathlessness. Specialized care may also be available from psychologists, clergy, spiritual advisors, art and music therapists, dieticians, pharmacists, and complementary therapists, with volunteers to support them all.

Hospices usually have a small number of inpatient beds with a high staff-to-patient ratio. Admissions may be for terminal care but around 40% of patients are discharged back home after a few weeks of symptom control or psychological support. This is an important statistic to emphasize to patients who may feel referral to hospice is the "first nail in the coffin." Women affected by gynecological malignancy may benefit from the outpatient services available at many hospices, which might include a day center, complementary therapy such as massage, appointments with dieticians, or being reviewed by a palliative care doctor in an outpatient clinic. Hospices may be a useful alternative to consider for women with advanced disease who require medical interventions such as drainage of ascitic fluid or blood transfusion.

Specialist palliative care is also available to patients at home, and works alongside the primary care team. Community palliative care teams work across the UK in a network of interlocking catchment areas. Teams are often based in a hospice and will consist of nurse specialists ("Macmillan nurses" when funded by that charity) with medical, paramedical, and social work input. Nurse specialists in the community complement the input of primary care and social services with specialist advice on symptom control, information, and support. They will communicate closely with other health professionals such as the general practitioner and the hospital gynecologic oncology team about the patient's condition. They are also in a position to reflect with the patient on issues about their illness and possible treatment options.

WHEN IS PALLIATIVE CARE RELEVANT TO THE WOMAN WITH GYNECOLOGICAL CANCER?

Palliative care is usually considered appropriate when curative treatment is no longer possible. However, there is evidence to suggest that women experience distressing physical and psychological effects during and after successful treatment for gynecological cancer. Persistent difficulties with pain, fatigue, bladder and bowel dysfunction, and sexual problems were reported in a group of disease-free patients. Half were depressed and 39% reported persistent psychosocial difficulties (Steginga et al. 1997). Palliative care should therefore be available on the basis of need at all points along the patient pathway. Particularly emotional or symptomatic difficulties may be experienced around the time of diagnosis, during active chemotherapy or radiotherapy, at relapse, and in advanced disease.

The UK National Cancer Standards recognize the important role of palliative care in gynecological oncology and expect there to be representation from the specialist palliative care team at the gynecologic cancer multi-disciplinary team meeting (National Cancer Action Team 2008).

Sexual dysfunction or psychosexual problems can arise either as a direct result of gynecological cancer or as a result of its treatment. Surgery, radiotherapy, and chemotherapy may influence the physical ability to have and gain pleasure from sexual intercourse, while altered body image may impact upon a women's ability to enjoy the emotional side of sexual activity. Despite this, the need to feel close to people both physically and emotionally will remain, and women will need support in order to come to terms with their altered sexual function.

Ovarian cancer is often diagnosed at an advanced stage, with 50% of women presenting with stage III or IV disease (NCRAS 2015). Other gynecological malignancies usually present earlier but may progress despite treatment. Clinical problems arising commonly in advanced ovarian cancer include malignant bowel obstruction and recurrent ascites. Ureteric obstruction and renal failure are not unusual in end-stage cervical cancer. Decisions around appropriate treatment in these situations will often involve input from the palliative care team. Prognosis depends on patient characteristics and staging of the particular cancer, but ovarian cancer represents the fourth most common cause of cancer death in women. End-of-life issues may include ethical dilemmas, consideration of place of care, and support for the family into bereavement. Support should be available for staff around the loss of a patient.

GENERAL PRINCIPLES OF PALLIATIVE CARE

A palliative care interview will involve taking a medical history with particular attention to symptoms, insight and understanding, family and social history, and medications both current and previous. Assessment should also identify psychological and spiritual concerns and anxieties about the present or future. It may be possible to discuss wishes around future care including advanced refusal of treatment and preferred place of death. The concerns of the family and carers also need to be heard and discussed.

Symptom Management

It is important to determine the likely cause of any symptoms and to assess their relative significance to the patient in order to plan management. It is common for individuals to have multiple symptoms or problems, and a full history should be taken for each. Not all symptoms may be due to the main disease. Symptoms may be because of secondary effects of the illness (for example, weakness or debility), because of side effects of treatment, or because of unrelated concurrent illness. Symptoms also interact with emotional, social, and spiritual problems, so that pain can be exacerbated by worry, lack of information, fears, anxiety, or any unresolved matters.

Investigations should be considered to aid diagnosis and guide treatment. However, if an individual is too frail to receive treatment for a specific problem, invasive tests to diagnose that problem are usually not warranted.

There are many reports of symptom prevalence in mixed populations of cancer patients, but very little published on symptoms associated with advanced gynecological malignancies (Table 41.1). Symptom surveys vary depending on the stage of disease, but even in cancer center outpatient populations treatable symptoms are very common (Lidstone et al. 2003).

Symptomatic or palliative management embraces an enormous range of interventions from teaching breathing techniques to disease-modifying management like surgery. The common intention with such treatment is not to cure the patient but to make them better, if only for a while. This principle can be applied to every management decision and used to weigh risks against the potential benefit. Treatment decisions need to be individualized and reviewed frequently. It is sensible to minimize the number of medications in order to aid compliance.

Table 41.1 Prevalence of Symptoms in Advanced Cancer and Ovarian Cancer

Symptom	Advanced Ovarian Cancer*
Pain	69%
Anorexia	44%
Weakness	28%
Breathlessness	
Confusion	
Nausea	47%
Vomiting	50%
Constipation	13%
Dry mouth	13%
Depression	16%

* Cox S, unpublished.

Disease-Modifying Palliative Treatment

In the treatment of gynecologic cancer, surgery, radiotherapy, and chemotherapy are the most commonly used forms of disease-modifying treatment. They may be offered even when cure is not possible to improve quality of life or because they offer the chance of prolonged life.

Nonpharmacological Treatment

Examples of nonpharmacological treatment approaches include:

- Breathing control techniques for breathlessness
- Relaxation techniques for anxiety
- Dietary modifications for anorexia
- Provision of a pressure-relieving mattress for debilitated patients
- Acupuncture or TENS for the relief of pain
- Provision of a quiet and supportive environment for agitated or distressed patients

Prescribing for Symptom Control

The aim when prescribing for persistent symptoms is to render the patient symptom-free. Appropriate drugs must therefore be taken regularly rather than on an ad hoc basis. Each new drug should be perceived to have benefits which outweigh potential side effects in the context of the patient's condition. It is good practice to avoid polypharmacy; regular review will allow drugs to be stopped that are no longer necessary or helpful. Both patients and carers need clear, concise guidelines to ensure maximum cooperation. Drug regimens should ideally be written out in full for patients and families, and patient's self-medication charts are a useful adjunct to this. Where patients and families are easily confused by treatment regimens, this should be reviewed to reduce the number of drugs/tablets. Compliance may be further aided by the use of a dosette box, which can be filled by a relative or pharmacist. Patients and carers also benefit from a clear plan of action should a current

management plan not be working, and know who to contact and how to contact them. The patient should have an appropriate identified key worker at all stages of their cancer journey—this is particularly important in the palliative care setting.

Breathlessness

Breathlessness may become more severe in the last weeks of life, and is often difficult to control. It has many potential causes including pleural effusion, pulmonary embolism, muscle weakness, anemia, pneumonia, chronic heart failure, chronic obstructive pulmonary disease, and/or psychological distress. Consideration should be given to treating reversible causes if the benefit of doing so outweighs the burden to the patient. The goal of symptomatic treatment is to improve the subjective sensation as experienced by the patient, rather than to improve abnormalities in blood gas or pulmonary function. Difficulty breathing is often associated with a high level of anxiety, which exacerbates the problem. Patients may need to reduce their expectations and adapt their home environment to make daily activities more manageable. General measures include ensuring that the patient is comfortable, upright positioning, and providing information and reassurance. Teaching breathing exercises can give some feeling of control. Oxygen can be helpful, especially where there is hypoxia, but similar effects can be achieved by a stream of air, which produces less practical difficulties. If there is some reversible airway obstruction, bronchodilators may be useful. Opioids can improve exercise tolerance in advanced airway limitation and reduce the sensation of breathlessness. Benzodiazepines are central sedatives and can also relieve the unpleasant feeling of dyspnea. Corticosteroids may be helpful where dyspnea results from a large tumor mass.

Anorexia

Anorexia is very common in advanced malignancy. It may be associated with considerable weight loss, which may be a source of distress to affected women and their relatives. Loss of appetite also results in loss of the social activity of eating with friends and family. Evidence exists to show the ineffectiveness of aggressive nutritional support in very advanced cancer. Women should be advised to try small portions and dietary supplements. Corticosteroids and progestogens can be used to stimulate appetite where appropriate.

Nausea and Vomiting

Management of nausea and vomiting will be most effective if a cause can be identified and treatment targeted appropriately. Symptoms may result from gastric irritation or poor gastric emptying because of massive ascites or significant hepatomegaly. Bowel obstruction will often result in vomiting. Raised intracranial pressure should be suspected if there is early morning nausea and vomiting associated with headache and drowsiness or confusion. Since each of these causes has a different mechanism and is mediated by different receptors, specific antiemetics should be chosen. Oral administration may not be effective, and parenteral routes (for example, continuous subcutaneous infusion) should be considered at an early stage.

Constipation

Constipation is a common cause of discomfort in advanced cancer. Causes include inactivity, weakness, dehydration, diminished food intake, low-fiber diet, and drugs. In addition, there may be direct or indirect effects of the cancer such as hypercalcemia or bowel obstruction. Patients who are able to should be encouraged to drink plenty of fluids, eat appropriately, and move about. However, in advanced malignancy these measures are usually inadequate by themselves, and a laxative such as polyethylene glycol (Movicol) will need to be taken daily. With fecal impaction, rectal intervention will be required as well to initiate bowel movement.

Anxiety and Depression

Anxiety and depression are common in advanced cancer and may be underdiagnosed. Risk factors for the development of depression include previous depressive episodes and uncontrolled pain. Biological symptoms such as loss of appetite and weight, poor sleep, and lethargy are unhelpful in making the diagnosis, as they occur with advanced cancer itself. Loss of interest or pleasure and hopelessness may be more discriminating symptoms in this population. Treatment with antidepressants may allow the patient to achieve a better quality for the remainder of her life.

CLINICAL CHALLENGES FOR PALLIATIVE CARE IN GYNECOLOGY ONCOLOGY

Advanced gynecological cancer presents a range of clinical challenges for the multiprofessional team. For example, women with advanced cervical cancer may go into renal failure as a result of bilateral ureteric obstruction. It may be possible to decompress one kidney with a nephrostomy tube and then attempt placement of a J-J stent into the ureter. However, in some cases extrinsic compression makes stenting unsuccessful, or of short-lived benefit. Overaggressive treatment may result in a woman spending much of her limited time in a hospital. The multiprofessional team needs to work closely with the patient and carers and health professionals in the community to make the best decision.

Malignant Bowel Obstruction

Malignant bowel obstruction is a common feature of advanced gynecological malignancy. Retrospective and postmortem surveys give prevalence rates of 5% to 51% (Ripamonti and Bruera 2002). Malignant bowel obstruction is the most frequent cause of death in ovarian cancer. In these patients, obstruction may be of the small or large bowel, or, most commonly, at multiple sites. The pathophysiology of obstruction is usually by extrinsic compression from mesenteric, omental, and pelvic masses with intra-abdominal adhesions. Contributing factors may include inflammatory edema, fecal impaction, fatigue of intestinal muscles, and constipating effect of the drugs.

Clinical presentation may vary depending on the level of the obstruction but is usually subacute with a relapsing and remitting course (Figure 41.1).

Surgery should be considered in all patients with malignant bowel obstruction. In advanced malignancy, surgery will be



Figure 41.1 Plain abdominal x-ray showing malignant bowel obstruction in a woman with advanced ovarian cancer.

palliative and symptom control may be possible using less invasive means. Most studies of surgery in malignant bowel obstruction have been retrospective, and conclusions are difficult to draw. Postoperative morbidity and mortality figures vary widely, with re-obstruction rates from 10% to 50%. Symptomatic relief is said to be achieved in 42% to over 80% (Feuer et al. 1999). Advanced age, medical frailty, and poor nutritional status may mitigate against operative treatment. The presence of ascites or palpable abdominal masses are poor prognostic signs. Previous abdominal radiotherapy or chemotherapy are associated with poorer outcomes from surgery. Treatment options must be honestly discussed with the patient and her carers in order to come to an appropriate decision.

Relief of symptoms can be achieved pharmacologically in a majority of patients. Symptoms are usually a combination of nausea and vomiting, continuous abdominal pain, and/or abdominal colic. Stimulant laxatives should be stopped and prokinetic drugs such as metoclopramide used with caution. Appropriate antiemetics are given parenterally, usually subcutaneously by continuous infusion. To this infusion can be added a strong opioid such as morphine for constant pain and hyoscine butylbromide for intestinal colic. Patients should be allowed to eat and drink as they choose. Thirst is rarely a problem, but subcutaneous or intravenous fluids can be given if needed. Symptoms can be controlled this way in about 75% of patients with malignant obstruction. In the remainder, other measures will be needed which may include the addition of the somatostatin analog, octreotide, corticosteroids, or nasogastric intubation (Mangili et al. 1996). Conservative management with nasogastric intubation and intravenous hydration is appropriate prior to surgery but is not otherwise recommended. A more conservative regime can be managed in the patient's home by the primary care team with specialist palliative care support. Being at home at the end of life is an important goal for many women with cancer, and achieving the preferred place of care for a patient is a central priority of the National End of Life Care Strategy (DH 2008).

Recurrent Malignant Ascites

Ovarian cancer is the commonest cause of malignant ascites, occurring in about 30% of patients with ovarian cancer at diagnosis and around 60% at the time of death. In ovarian cancer, the ascites is usually associated with peritoneal metastases. Less commonly, the fluid may be chylous or can accumulate as a result of portal hypertension in the presence of massive liver metastases. Malignant ascites is not such a poor prognostic sign in a woman with ovarian cancer as in other tumor types because of the potential for response to chemotherapy (Mackey and Venner 1996).

Malignant ascites causes symptoms including anorexia, nausea, abdominal distension and pain, dyspnea, and fatigue. It can have a negative impact on a woman's body image—she may be treated as if she were pregnant and repeatedly asked when is the baby due. Knowing her diagnosis, these sorts of comments can be devastating (Figure 41.2).

Symptoms may be treated empirically as suggested above, but often the best way to gain relief is to drain some of the ascites. Much debate exists over how to make paracentesis most effective. There is an evidence base to guide our practice but it relates largely to cirrhotic ascites. In undiagnosed cases, a full history and examination will precede imaging and diagnostic tap of the ascitic fluid (Figure 41.3).



Figure 41.2 Tense abdominal ascites as a presenting feature of ovarian cancer.



Figure 41.3 Ascitic drain for symptom relief in a woman with advanced ovarian cancer.

In cases of malignant ascites where active treatment is not able to prevent recurrence, the mainstay of treatment is repeated drainage. Symptomatic paracentesis gives good relief of symptoms in 90% of patients. Potential complications include ascitic leaking, infection, and hypovolemia if large volumes are withdrawn. When draining cirrhotic ascites, it is usual to provide intravenous fluid replacement with colloids to prevent symptomatic hypovolemia. This is not common practice in the treatment of ascites caused by ovarian cancer. There is no accepted standard rate of drainage or total volume but an average target is 5 L. The drain should be removed as soon as possible to limit the chance of infection and reduce the time spent as an inpatient. Draining to dryness is sometimes advocated, although ascitic fluid is likely to recur and the burden of this treatment is greater.

In patients requiring frequent ascitic drainage the placement of an indwelling peritoneal catheter provides an effective and well-tolerated alternative (NICE Medical Technology Guidance 2012).

The use of diuretics is also associated with controversy (Becker et al. 2006). Small studies have supported the use of a combination of loop diuretics and spironolactone to delay reaccumulation of ascitic fluid. Diuretics appear to be most effective when liver metastases are present.

COMMUNICATING WITH THE FAMILY AND WITH OTHER PROFESSIONALS

In palliative care, the patient and their family or those important to them are regarded as the unit of care. However, this does not mean that carers should be given information before patients, and professionals need to follow the patient's wishes. The fears, anxieties, and concerns of the carer can be explored and their more intimate knowledge of the person drawn out. It may also be helpful to discuss with the family the strain that the situation is placing on them, and ways in which services and the professionals may help.

One of the common concerns of patients in hospitals and in the community is that of receiving mixed messages from different professionals. It is important that all of the team involved in the care of the patient and family are kept fully informed of the important decisions and wishes of the patient and their family or carer. If people are at home and different services are visiting, the carer or patient can sometimes feel that they have a full-time job coordinating which services arrive when. It is important in these instances to identify a key worker for that patient and family who helps to take on some of the role of coordination and advocacy so that the patient and the carer receive the services and benefits to which they are entitled. Similarly, in hospitals patients and carers may ask for information from different nurses and doctors, depending on who is with the patient at one time. There may also be different teams involved. This may be particularly likely with palliative care patients, who may be seeing members of the hospital palliative care team as well as their own doctors. When the circumstances and condition of the patient change rapidly, it is especially important that all the team is kept urgently informed of relevant changes in the treatment plans or in the person's condition or wishes. Frequent multidisciplinary team discussions and joint consultation with the patient and their carers may be valuable.

THE DYING PATIENT

The publication in the UK of the National End of Life Care Strategy (DH 2008) encourages healthcare professionals to work with their patients to discuss and plan for their care toward the end of their life. Most deaths from gynecological cancer can be predicted in advance and therefore planned for and actively managed. Sudden death from associated causes such as pulmonary embolism or sepsis can occur, and then the focus is on supporting the relatives.

It can be difficult to recognize that a patient is dying when they have been very slowly deteriorating. It is especially difficult to acknowledge approaching death among the team when a relationship has been built up with the woman over a period of time. It may feel like an admission of failure to suggest discussions about preparing for death, but there may be important issues that need to be addressed. Individualized plans of care for the dying should be developed to improve care of the dying patient (LACDP 2014).

Women with advanced disease may ask if they are dying, and sensitive honesty is required in answering them. It may be that the medical and nursing team recognize a deterioration and can reflect this to the patient and her family. She can then choose whether to take up an offer of further information. Some women will understand that bad news is available and choose not to pursue it or suggest that their family is told instead.

Information allows patients to plan for their limited future, including where they would prefer to die, and to deal with "unfinished business." This may include financial plans such as making a will, practical issues such as formalizing a power of attorney and making a living will, or spending precious time with loved ones. Where there are children involved, there are particular issues to consider including how to tell them what is happening, how to leave a living written or video memory, and sometimes who will be their guardian.

Recognition that a woman is entering the terminal phase of her illness is also important for the healthcare team. Investigations and treatments which had previously been appropriate may no longer be in the best interests of the patient. A multitude of decisions will need to be made including about continuing chemotherapy, treating new infections, tube feeding, and cardiopulmonary resuscitation. Different patients will want different levels of involvement in such decision making.

As death approaches, patients will become weaker, sleepier, and lose their appetite. They will spend longer periods of time in bed and then longer asleep. They need good nursing care to avoid skin breakdown, and good oral care to prevent mouth discomfort. Blood tests, x-rays, and routine recordings such as blood pressure measurement become unhelpful and should be discontinued. Oral medication becomes more difficult to tolerate and can be cut down and then stopped. Symptomatic drugs must be continued, and may be given by continuous subcutaneous infusion, which is more comfortable than the intravenous route and can be managed by the nursing staff. Pain, nausea, agitation, and bubbly breathing can occur toward the end of life, and drugs should be prescribed to be given subcutaneously for each of these symptoms. Fluids are not routinely given at the end of life, although this needs to be assessed on an individual basis together with the family.

The healthcare team should be available regularly to talk with family and friends, who often find the bedside vigil emotionally and physically exhausting. They may receive important support from a few minutes conversation a day with one of the team. They will need an explanation for changes as they happen and in advance if they can be predicted. Inquiries should be made about the patient's spiritual beliefs to allow them and their families to benefit from this support. Support for the family in their bereavement may be available from the palliative care team or locally through the general practitioner or national bereavement agency.

REFERENCES

Becker G, Galandi D, Blum H. 2006. Malignant ascites: Systematic review and guideline for treatment. *Eur J Cancer* **42**(5):589–97.

Department of Health (DH). 2008. End of Life Care Strategy: Promoting high quality care for all adults at the end of life. London: Department of Health.

Feuer D, Broadley K, Shepherd J, et al. 1999. Systematic review of surgery in malignant bowel obstruction in advanced gynecological and gastrointestinal cancer. The Systematic Review Steering Committee. *Gynecol Oncol* **75**(3):313–22.

Leadership Alliance for the Care of Dying People (LACDP). 2014. One chance to get it right—Improving people's experience of care in the last few days and hours of life. Available online at www.gov.uk/government/uploads/system/uploads/attachment_data/file/323188/One_chance_to_get_it_right.pdf.

Lidstone V, Butters E, Seed P, et al. 2003. Symptoms and concerns amongst cancer outpatients: Identifying the need for specialist palliative care. *Palliat Med* **17**(7):588–95.

Mackey J, Venner P. 1996. Malignant ascites: Demographics, therapeutic efficacy and predictors of survival. *Can J Onc* **6**(2):474–80.

Mangili G, Franchi M, Mariani A, et al. 1996. Octreotide in the management of bowel obstruction in terminal ovarian cancer. *Gynecol Oncol* **61**(3):345–8.

National Cancer Action Team. 2008. National Cancer Peer Review Programme. Manual of Cancer Standards 2008: Gynaecological Cancer Measures. London: Department of Health.

NCRAS (National Cancer Registration and Analysis Service). 2015. Cancer breakdown by Stage. Stage breakdown by CCG 2015. NCRAS. Available online at http://www.ncin.org.uk/publications/survival_by_stage.

NICE Medical Technology Guidance. 2012. The PleurX peritoneal catheter drainage system for vacuum-assisted drainage of treatment resistant recurrent malignant ascites.

Ripamionti C, Bruera E. 2002. Palliative management of malignant bowel obstruction. *Int J Gynecol Cancer* **12**(2):135–43.

Steginga S, Dunn J. 1997. Women's experiences following treatment for gynaecological cancer. *Onc Nurs Forum* **24**:1403–8.

WHO (World Health Organisation). 2017. Definition of palliative care. WHO. Available online at http://www.who.int/cancer/palliative/definition/en/.

42 Doctor–patient communication

J. Richard Smith, Krishen Sieunarine, Mark Bower, Gary Bradley, and Giuseppe Del Priore

INTRODUCTION

Unlike most of this book, this final chapter does not concern itself with practical surgical techniques; instead, it looks at the communication between the patient and her gynecologic oncologist. Entire books have been devoted to this subject and it may seem presumptuous even to attempt to address this in a brief chapter. However, we feel that the bare bones of good communication are extremely simple and may be summed up as imparting the truth and nothing but the truth in a compassionate manner. A very much fuller discourse is available through Smith and Del Priore (2015).

In gynecologic oncology, patients face a frightening diagnosis and an uncertain future. It is increasingly recognized that patients wish to know their diagnosis and to be kept informed of the progress of treatment. This has resulted in a revolution in the approach to patient–doctor communication. The era of professional paternalism, protecting patients from the diagnosis and remaining unrealistically optimistic to the dying patient, is over. With this change in approach has come a realization that effective communication skills are not innate, but can be taught, learned, retained, and used to improve patient care. More and more healthcare professionals, including gynecologic oncologists, are receiving training in communication with patients, their families, and other professionals.

This increased communication with cancer patients has costs to healthcare professionals, which need to be appreciated and addressed. Improved communication brings healthcare professionals closer to the patient and may increase feelings of inadequacy when faced with unsolvable issues and of failure when patients die. Gynecological oncologists dealing with dying patients and their families risk burnout; although the medical profession is notoriously resistant to external help, a team spirit, adequate training through communication workshops, and peer support are important elements in tackling this problem.

Many junior doctors identify breaking bad news as their greatest fear and their top problem in communicating with patients. In many cases, doctors continue to carry this anxiety with them through years of clinical practice. Why do doctors fear breaking bad news? Obviously, the information causes pain and distress to our patients and their relatives, making us feel uncomfortable. We fear being blamed and provoking an emotional reaction. Breaking bad news reminds us of our own mortality and fears of our own death. Finally, we often worry about being unable to answer a patient's difficult questions since we never know what the future holds for either our patients or ourselves. Breaking bad news to patients should not involve protecting them from the truth but rather imparting the information in a sensitive manner at the patient's own pace. The setting for this conversation should be considered carefully. A confidential, quiet, and comfortable location should be used rather than a busy gynecology ward with neighboring patients eavesdropping. An open-ended, interruption-free period of at least 20 to 30 minutes should be allocated and the patient should be asked if she wishes anyone else to be present. Many patients will already be aware of how serious their condition is and will have guessed the diagnosis. Thus, an initial screening question asking what the patient believes to be the matter may change the interview from breaking to confirming bad news. Subsequently, the conversation may be viewed as a series of cycles repeated for each piece of information imparted. An initial warning shot from the doctor ("I'm afraid that the biopsy result was not normal") should be followed by a pause to enable the patient to respond. Further information can then be given and the patient again asked if she wishes to know any more. In this way it is the patient, not the doctor, who determines the quantity of information delivered and who controls the pace of the conversation without realizing it.

Prognostication with respect to duration of remaining life and the quoting of 5-year mortality statistics is rarely helpful. Few of us are able to explain the implications of skewed distributions, medians, and confidence intervals in a way that is easily understood by or meaningful to patients. Moreover, many of us have enough optimism to believe that we will fall on the lucky side of whatever statistic is quoted, and of course, we might just be right. The last thing that we should do is to destroy all hope. Patients may ask for predictions as to length of or guarantees of survival, often hoping for reassurance. In these circumstances, it is always easier to give false reassurance, but the temptation must be avoided as you will not be doing your patient a favor in the long run. Despite these restrictions, all consultations ideally should end on a positive note, the motto being "never say never." Even in the bleakest of situations, setting short-term achievable goals leaves patients with aims for the future and hope. This maxim applies to both the patient and—where the patient agrees—the next of kin. It is always helpful to leave the patient with a further opportunity for discussion, especially about the dozens of questions which arise in the patient's mind and may be generated by her discussions with relatives and friends. We have always given patients our telephone numbers so that further discussion can be facilitated.

It is desirable to communicate at each stage in a private setting and preferably to the patient and her next of kin at the same time. Failing this, a discussion should take place with the patient and be followed at a future date by a joint consultation between doctor, patient, and her next of kin. It is rarely appropriate to allow relatives to "protect" the patient by withholding information or over-optimistically lying. These issues can become particularly difficult when dealing with cultural differences, particularly if the patient does not speak English.

Table 42.1 The Four-Cusp Approach to Patient Communication

	Cusp 1	Cusp 2	Cusp 3	Cusp 4
Status	Potentially curable	Living with cancer	Pre-terminal	Terminal
Duration	Weeks to years	Months to years	Weeks to months	Days
Treatment	Radical surgery Adjuvant therapy	Palliative chemotherapy or radiotherapy	Supportive care	Terminal care
Aims	Cure Prolong survival	Prolong survival/cure Improve QoL	Improve QoL	Improve QoL End-of-life issues

Abbreviation: QoL, quality of life.

This act of collusion needs to be explored with relatives, on the basis that the patient needs to understand what is happening to her. With careful negotiation, including an acknowledgment of the views of the relatives, access to the patient can usually be secured to determine the patient's own understanding of her illness. It is then common to discover that the patient is well aware of the diagnosis and herself colluding to spare the relatives. In such circumstances, honest discussion may reduce anxiety and resolve the relationship difficulties within the family.

In addition to keeping the patient abreast of developments, it is vital to involve the whole multidisciplinary team so that the patient and her relatives hear the same message from all the healthcare professionals. The roles of individuals in the team and their boundaries of care may lead to friction within teams. Philosophical differences in treatment approaches need to be explored. Frequent team meetings and open discussion that avoids a hierarchical structure will enhance team spirit and reduce tensions. Occasionally, an external facilitator may be helpful to coordinate such meetings. The role of the oncology nurse is vital in these circumstances, as they are often seen by the patient as accessible and sympathetic, without the formality of the "specialist oncologist."

The following pages set out a four-cusp approach, which may be useful in discussions on treatment strategies and prognosis (Table 42.1). We have been surprised at how often patients have taken away the scraps of paper used to demonstrate this four-cusp approach. In addition, we have noticed that our junior staff who frequently lack experience in talking through those difficult issues with patients find this a helpful framework. The cusps are illustrated by case examples. We used to refer to cusps 1, 2, 3, and 4, but a couple of our patients were upset because they confused cusps with "staging" and since then we have referred to the four cusps as A, B, C, and D.

THE "FOUR-CUSP" APPROACH

Cusp A: Potentially Curable

The first cusp applies to most patients from the time of the first visit to the clinic when the surgeon imparts the probable diagnosis and discusses with the patient the plan of action to achieve staging and hopefully removal of the tumor. It is rare to feel totally confident that a tumor is incurable before surgery; one may suspect it, but rarely can one know until the histology is confirmed and the staging completed. An honest appraisal of the possibilities is required, coupled with a plan of action. This should include date of surgery, length of time in hospital, and when final and definitive histological and cytological reports will become available. It is almost always possible to achieve these results within 2 to 4 weeks of the first visit to the clinic. The patients thus know they will have a good idea of where they stand by a specific date. The concept of cancer staging should be explained, and that the stage and type of tumor will influence the necessity for further treatment with radiotherapy or chemotherapy. We usually explain that if we achieve treatment by surgery alone there is a presumption of cure. This, however, can only be confirmed by the passage of time, and the longer all remains well, the higher is the likelihood that cure has been achieved. A high level of positivity and a buoyant approach are usually applicable both before and after surgery for those with complete resection of tumor, although the need for careful follow-up and the possibility of relapse should be discussed. This step-by-step approach can be utilized throughout the care of the patient and helps the patient to understand that the whole of care cannot be determined at the first visit. Constant and regular communication is the hallmark of good care.

Case 1

A woman is referred to the gynecological oncology clinic with postcoital bleeding and a suspected cervical cancer. On examination, a small cervical tumor is found which is approximately 2 to 3 cm in diameter. The uterus and cervix are mobile and there are no other detectable abnormalities. A colposcopy and biopsy are performed.

Following the examination, the consultation should continue, usually by asking the patient if she has any idea what she thinks the diagnosis might be. Many patients will state their worst fear, namely cancer; others will say they have no idea. This is generally the point at which to communicate that you also believe the diagnosis to be one of cancer and that the biopsy will confirm or exclude this within the next few days. It is then possible to say that the initial examination suggests that this is an eminently curable cancer, and to outline the plan of action: first, the patient will be admitted on a specific date within the next 1 to 2 weeks for staging of the tumor, and on a subsequent date, probably within the next 2 weeks, for definitive surgery. Explain that there are four stages of cervical cancer, that stage I is the best and stage IV the worst, but all can be cured. Tell the patient that the first admission will take 1 day and will deliver an answer which she will probably know later that same day. Explain that you believe the tumor to be stage I and therefore highly curable, probably by surgery alone, but possibly requiring further treatment with chemoradiotherapy. Ask the patient to have her next of kin present at the post-staging ward round if they are not

there at the clinic. The patient should be invited to ask any questions and encouraged to write down any questions she thinks of when she is home and to ask them when she is admitted.

It is our practice to copy the letter written to the referring doctor to the patients themselves. We undertook a survey of patient acceptability of this practice, and over 100 patients surveyed all believed it was helpful and none chose not to receive further copies of future letters. This is now a UK-wide policy, although not universally practiced. Carefully organized and coordinated staging protocols allow women rapid access to results, reducing delays, and hence minimizing the anxiety caused by waiting for results. The patient will have the usual prestaging investigations, such as radiographic scans, and will then be admitted for staging; if for any reason results are delayed, this only further increases anxiety.

The operation is then performed, and either the same day or the following day an explanation is given. A few days later the full histological picture is given.

> *Scenario 1:* The histology report shows complete resection of a 2-cm well-differentiated squamous carcinoma with adequate resection margins and negative nodes.

This patient can be told that you believe cure has been achieved, and while long-term follow-up is warranted, you expect to see her in the clinic for the next 5 to 10 years (depending on individual protocol) and to discharge her from care at this time "fit and well." At the end of the 5 years, she enters the "cured" circle; i.e., she is more likely to develop a new cancer than a recurrence of her old one.

> *Scenario 2:* The histology report shows complete resection of a moderately differentiated squamous cervical carcinoma with 3 positive metastatic nodes out of 40 removed.

This information is imparted and the patient is told that although there is complete removal of tumor further treatment is required with combination chemoradiotherapy. Such patients can be told that you believe cure is likely and that this is a "belt and braces [suspenders]" approach, but that there is no denying they do have a higher chance of relapse than if their nodes had been negative. The concept of adjuvant therapy following radical surgery may be explained as an "insurance policy" to mop up any tumor cells that could have escaped the surgery. It is always valuable to have the radiotherapeutic member of the multidisciplinary team (MDT) to explain the details of the treatment. She is in cusp B but with a high chance of long-term cure; i.e., we are aiming that after 5 years she will return to cusp A, the cured circle. However, psychologically she will be living with her disease.

Case 2

A 55-year-old woman is referred by her general practitioner with abdominal swelling which she has noted in the last few weeks. She has no other symptoms. Abdominal examination reveals fluid in the abdomen on percussion. Vaginal examination is suggestive of a mass arising from the right adnexa, probably ovarian in origin, and nodules are felt in the pouch of Douglas.

The patient is informed that there are findings suggestive of an ovarian mass and that these require urgent investigation. The patient should be told that you suspect cancer and that the investigations you are about to request will go some way to eliciting a diagnosis.

I would do the risk of malignancy index (RMI; see Chapter 21) immediately during the clinic to give the patient an early idea of what the likely diagnosis is.

Hematological and biochemical tests are ordered, as are tumor markers, an ultrasound scan with color flow Doppler, and a computed tomography (CT) scan of abdomen and pelvis to detect lymphadenopathy; a magnetic resonance imaging (MRI) of pelvis is also ordered. The patient is reviewed shortly thereafter and the RMI is used. The findings are highly suggestive of a stage IC ovarian cancer. Staging of ovarian cancer is explained to the patient, together with the fact that there are three possible outcomes from the operation which will be communicated to her immediately postoperatively:

- Complete macroscopic resection of tumor (R0)
- Resection of tumor down to nodules less than 1 cm in diameter (R1)
- Inadequate debulking (R greater than 1)

The last two possibilities seem unlikely, bearing in mind the optimistic findings of the investigations. Full staging will be arrived at a few days after surgery when all the cytologic and histologic results will be available. Patient consent is obtained for a total abdominal hysterectomy, bilateral salpingo-oophorectomy, omentectomy, ± pelvic para-aortic lymph node dissection and debulking as required.

> *Scenario 1:* At surgery a smooth-walled cyst is found with some free fluid in the pelvis. There is no evidence of any tumor elsewhere in the abdomen on macroscopic examination.

Postoperatively, the patient can be told that she falls into the first category (fully macroscopically resected tumor), and a few days later the histological report confirms a well-differentiated ovarian epithelial carcinoma with negative cytology from washings and peritoneum. The lymph nodes are free of tumor. The patient is informed that she has a stage IA tumor and should have no further problems. She remains at cusp A.

> *Scenario 2:* At surgery the abdomen is opened and 500 mL of straw-colored fluid is aspirated and sent for cytology. Abdominal exploration reveals small studs of tumor on the diaphragm and a small omental deposit. A total hysterectomy, bilateral salpingo-oophorectomy, and omentectomy are performed with no residual tumor left at the end of the operation.

The patient is informed postoperatively that she falls into the second category, namely tumor debulked (R0), and that she probably has a stage III tumor, depending on results, and almost certainly will require further treatment. A few days later the histologic and cytologic reports confirm that this clinical impression was correct. The patient is informed, and chemotherapy planned. She should be informed that she has now entered cusp B, "living with cancer," and that she may regain cusp A following chemotherapy—this is the goal of the treatment but that only time will tell.

Cusp B: Living with Cancer

Cusp B is for treated patients who are in remission but are less likely to be cured (i.e., "living with cancer") but not terminal. Again, a positive approach is appropriate, but the long-term goals are less optimistic. The patient should be informed that it is impossible to determine how long she will remain in remission, that we certainly have many patients who are alive many years after chemotherapy and a few who have returned to cusp A (i.e., presumed cured). Sadly, we also have some who have not survived as long. The golden rule is that the longer one is in complete remission, the better the prospects become. The biggest difficulty is that neither the patient nor the doctor knows which category she is in until time elapses, but it is important that both can see that it is well worth following through with treatment. The patient described in scenario 2 above then undergoes chemotherapy.

> *Scenario 1:* The patient goes into complete remission for 5 years.

This patient is one of the lucky ones and has returned to cusp A—the cured circle.

> *Scenario 2:* The patient goes into complete remission which lasts for 3 years and then at the follow-up joint oncology clinic is found to have a raised serum level of CA125 and a palpable nodule in the pouch of Douglas. Staging investigations reveal radiologic evidence of a solitary nodule. She therefore has a second laparotomy. Complete excision of the tumor is achieved, followed by a further course of chemotherapy. Again, the patient enters complete remission.

She can be told that she appears to have a relatively non-aggressive tumor and can expect to remain in the second cusp for a good time longer.

> *Scenario 3:* Following first-line chemotherapy the patient achieves a partial remission which lasts for 5 months when she re-presents at follow-up to the joint oncology clinic with a rising serum CA125 level and abdominal swelling. Radiologic investigation suggests that there are widespread metastatic peritoneal nodules.

This patient may be given the choice of whether to be observed until she develops symptoms or have second-line chemotherapy. The role of chemotherapy is to palliate symptoms rather than prolong survival in this context, and the balance between the possible benefits and toxicities of the chemotherapy should be explored with the patient. The patient declines further chemotherapy and then deteriorates over the next few weeks. She needs to be informed that she has moved to cusp C.

Cusp C: Pre-Terminal Phase

The third cusp applies to patients with virtually no chance of cure, who have entered the "pre-terminal phase." It is important that the patient is informed and made aware that she has a limited time left to her, and that she is given the opportunity to "put her house in order"—see relatives and friends, make a will, etc. No patient should ever be told that there is nothing more that can be done for her. She should be informed that while she has virtually no chance of cure, and aggressive treatments to obtain cure are not appropriate, there are plenty of measures available to ameliorate symptoms such as pain, nausea, or upset bowels. The therapies that are appropriate at this phase of the disease are supportive measures to improve the quality of her life without causing toxicity.

> *Scenario:* A patient with carcinoma of the cervix presents 3 years after radical radiotherapy for a stage III tumor. She is passing urine permanently from the vagina. On investigation and examination under anesthesia she is found to have extensive recurrence of tumor both in the para-aortic region and on the pelvic sidewall. In addition, she has a large irreparable cystovaginal fistula. She also has deteriorating renal function.

The patient is informed that she has recurrent cancer and there are no curative treatments available. She says she had guessed that anyway and is clearly very angry. She is then asked the vital question for cusp C, what in addition to the fact that she is dying is most bothering her? To this she replies that she accepts death as inevitable and this does not make her angry—what makes her angry is her permanent incontinence which is preventing her from going out and seeing family and friends. She is referred to the interventional radiologist, and bilateral nephrostomy tubes are inserted, which render her dry. The patient goes home and returns 4 weeks later, in a terminal condition. She has entered cusp D. She does, however, inform us that she has had a great 4 weeks, been to the pub every day and seen all her friends. She dies 24 hours later. This decision highlights the importance of not denying patients palliative care even of a complex surgical nature at this time.

An example that could be regarded as non-medical was a patient who was in our ward coming very close to the terminal phase of her disease. She appeared very agitated and when asked "what, apart from cure, she would wish for if she could wave a magic wand?" The answer came back "I have papers at home which I would like to burn and I can't get home." The nurse in charge of her ward was duly informed of this and arranged an ambulance and a nurse to accompany the patient to her house where the papers were retrieved from the loft and burned. The patient returned to hospital much more at peace and was able to move to the terminal phase (cusp D). She died within a few days, mentally at peace.

Cusp D: Terminal Phase

The terminal phase of life lasts from hours to days, and all interventions are only designed to "ease the passing." Patients generally need not be told that this is where they have arrived, although the relatives may need help in understanding it. Care is focused on emotional support rather than medical intervention, and frequently most of the patient's medication can be stopped apart from analgesia. The death of a patient whose physical symptoms are well controlled and who is spiritually calm is an achievable goal to which we should all strive.

BEREAVEMENT/GRIEF*

Bereavement is by definition the process we go through when we suffer loss of something or someone very special to us.

* This section was originally based on Smith JR, Del Priore G. 2009. *Women's Cancers Pathways to Healing*. London: Springer.

In terms of this book, it applies to the women diagnosed with cancer who are coping with the loss that this entails, and to the relatives of the women who will sadly succumb to their disease.

At the time of diagnosis there is an enormous range of emotions at play. These include denial, anger, grief, depression, aggression, numbness, etc. There is no doubting that at that first consultation numbness and disbelief will be the strongest emotion, and the patient may think, "why me? I've done nothing to deserve this, I've eaten healthily, not smoked, not drank, it can't be true." However, over the next few days/weeks when the management plan is clarified, there is the coping with loss of organs if surgery is planned—this may involve loss of fertility or feelings of loss of womanhood—and a true bereavement process unfolds. If this is the first major illness encountered, there will also be the feeling of loss of invincibility. We all feel invincible, it will never happen to us, until it does—and that is a terrible shock. Anger may center on "why me? Why have I been dealt this hand of cards?" If one is religious one may wonder why God has allowed this to happen.

Traditionally, bereavement has been seen in the step-wise progression suggested by Elisabeth Kübler-Ross, from denial to anger to grief to bewilderment to depression to acceptance and hope. Things will never be the same again but life can go on, albeit differently. A different model encompassing the same emotions is the "Tapestry of Bereavement/Landscape of Grief" (Figure 42.1). This model was developed by the Reverend Gary Bradley, founder and chairman of the Westminster Bereavement Association. The analogy here is with a graphic poster. When one buys a poster, there are various features one may have first noticed, but as the poster hangs on the wall, over time one notices different aspects until after some time one may hardly notice the poster at all, even though it is still there. If one moves the poster, however, it instantly becomes more visible.

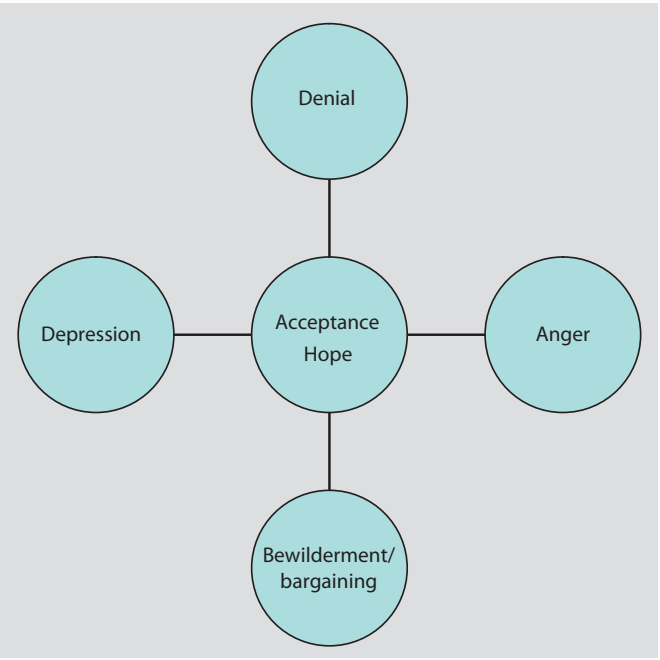

Figure 42.1 The "Tapestry of Bereavement/Landscape of Grief." This model shows the various emotions cropping up not in any particular order but more randomly, with some predominating at one point and others at another. Hopefully, progress is made to "acceptance and hope." Over time, all of the parts of the tapestry fade, and while they do not disappear, the tapestry becomes the new reality.

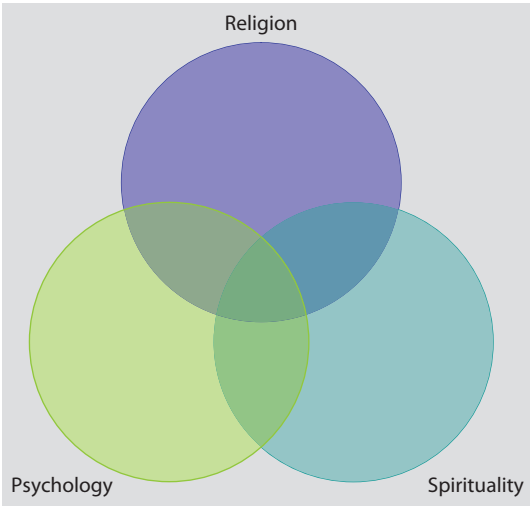

Figure 42.2 Venn diagram of spirituality, religion, and psychology.

This may all appear somewhat negative, but one of the amazing and heartening things many people say is that their cancer diagnosis finally gave them great inner strength and that they went on to do things that they know they would not otherwise have done—this is the concept of winning through losing—a very difficult place to get to, but something that can be genuinely empowering for the individual.

For those who lose a spouse, relative, or close friend, the same range of emotions will occur and the tapestry is similar.

The "tapestry," by its flexibility and its ability to fade and then come back into focus, may be a useful model for patients.

This process, particularly when one arrives at hope and acceptance, ties in with the Venn diagram of psychology, spirituality, and religion. These are areas that most patients will choose to further explore.

SPIRITUALITY, RELIGION, AND PSYCHOLOGY

This is a very difficult area to enter into with one's patients. While it is perfectly acceptable to discuss psychology, spirituality and religion are, to a degree, taboo subjects for today's doctors and nurses. However, showing a patient the Venn diagram in Figure 42.2 often allows opening of the conversation. The patient can be invited to say which, if any, or possibly more than one, suits her way of thinking. Recently JRS, in consultation, asked a patient this question. She said "I have all three covered. My brother is a priest. I see myself as quite a spiritual person and I have already booked up to see a psychologist!" This individual is likely to cope better with her cancer diagnosis than the individual who rejects all three approaches. Allowing the patient to express her views allows suitable onward referral.

BIBLIOGRAPHY

Boyle DCM, Lee M-J. 2008. *Fast Facts: Religion and Medicine*. Oxford: Health Press.

Fallowfield LJ. 1993. Giving sad and bad news. *Lancet* **341**:476–8.

Maguire P, Faulkner A. 1988a. Communication with cancer patients: 1. Handling bad news and difficult questions. *Br Med J* **297**:907–9.

Maguire P, Faulkner A. 1988b. Communication with cancer patients: 2. Handling uncertainty, collusion and denial. *Br Med J* **297**:972–3.

Nordin A, ed. 1999. *Gynaecological Cancer. Patient Pictures*. Oxford: Health Press.

Slevin ML. 1987. Talking about cancer. How much is too much? *Br J Hosp Med* **38**(1):56–9.

Smith JR, Del Priore G. 2009. *Women's Cancers Pathways to Healing*. London: Springer.

Smith JR, Del Priore G. 2015. *Women's Cancers Pathways to Living*. London: IC Press.

Index

Page numbers followed by f and t indicate figures and tables, respectively.

Abdomen
  abdominal hysterectomy, 184
  and pelvic vasculature, 255, 256f
  surgical anatomy, 27–28
  transverse rectus muscle cutting incision, 73f
  vertical subumbilical incision, 73f
Abdominal radical hysterectomy (ARH), 79, 109, 184
Abdominal radical trachelectomy (ART), 94, 100, 150, 181
Abdominal repairs, urogenital fistula
  transperitoneal repair, 249, 249f
  transvesical repair, 249, 249f
  ureteric reimplantation, 249–250, 250f
Absolute uterine factor infertility (AUFI), 153
2014 ACC/AHA perioperative cardiac risk guidelines, 8–10
Acetowhite epithelium, 70f
Acquired immune deficiency syndrome (AIDS), 5
Acquired vaginal defects, classification, 260, 261f
Actinomycosis, 240
Active clinical risk factors of cardiac disease, 8–9
Acute small bowel obstruction, 223
Additional plastic surgery procedures
  defect sites
    groin/suprapubic, 267
    pelvic cavity, 267
    perineum, 268
    vagina, 268
  flap options
    ALT, 268, 268f
    gluteal flap, 269, 269f
    omental flap, 269
    PTF, 269–270, 270f
    sartorius flap, 270
    tensor fascia lata (TFL), 270–271
  general considerations
    execution of the surgical plan, 267
    goals of reconstruction, 267
    reconstructive options and alternatives, 267t
    treatment history, 266–267
  traditional reconstructive options and their limitations
    gracilis flap, 266
    local skin flaps, 266
    rectus abdominis flap, 266
    skin grafts, 266
Adductor muscles, 130
Adenocarcinoma, 88
Admission for surgery
  checklist, 2f
ADNEX, 62–63
Adnexal mass, malignant and benign, 44–45, 51f
Adrenal suppression, 16–17
Advanced disease, surgical techniques for
  appendectomy, 158–159, 159f
  bowel resection, 157
  en bloc resection, 157–158, 158f
  liver nodules excision, 161, 161f
  maximum surgical effort, 157
  omentectomy, 160–161, 160f
  splenectomy, 159, 159f, 160f
Advancement flaps, 260
Advancement rectal sleeve procedure, 252
Adventitia, 26f
α-fetoprotein (AFP), 63
Afferent reflex fibers, 32f
Alcohol-based skin preparations, 175
Allis clamps, 222
Allocation concealment, 312
Alpha-2 agonists, 12
Alpha-fetoprotein and human chorionic gonadotropin, 63
ALT, *see* Anterolateral thigh flap (ALT)
Altered sensorium, 233
Ambulation, 3
American Congress of Obstetricians and Gynecologists (ACOG), 292
Amoxicillin/clavulanic acid, 20, 118
Anal and rectovaginal fistula repair
  laying open of fistula track, 251
  rectal advancement flap, 251, 251f
  transabdominal, 253
  transanal, 252
  transperineal, 251–252, 252f
  transvaginal, 252
Anatomical consideration, VRT
  cardinal (Mackenrodt) ligament, 88
  uterosacral ligaments, 88
  uterovaginal endopelvic fascia, 88
  vascular supply, 88
Anesthesia, 103
Angiotensin-converting enzyme (ACE) inhibitors, 12
Angiotensin-receptor blocker (ARB), 12
Anorexia, 324
Antenatal anonymous surveys, 5
Anterior superior iliac spine (ASIS), 268
Anterolateral thigh flap (ALT), 268, 268f
Antibiotics, 4, 5, 21, 23, 24, 71, 103, 243, 253
  broad-spectrum, 20, 21, 118
  intravenous, 20, 22
  preoperative use of oral, 20, 224
  prophylactic, 5, 22, 94, 175, 253
Anticoagulation, 4, 12, 13, 255, 258, 279
Antimesenteric enterotomy, 197
Antimesenteric staple line, 222, 222f
Antiplatelet therapy, 12
Antispasmolytics, 46
Antithrombin III, 13
Anxiety and depression, 324
Aortal compression, 278
Aortic bifurcation, 255, 256f
Apolipoprotein A1, 62
Apparent diffusion coefficient (ADC), 37
Apparent early-stage disease, surgery for, 161, 161f
Appendectomy, 158–159, 159f, 189, 190f, 228–229
  bipolar electrodesiccation, 189, 190f
Arci tendinei, 111
Arcuate line, 32f
Arcus, 25, 26f
Arcus tendineus fascia pelvis, 26f
Arcus tendineus levatoris ani, 26f
Argon beam coagulation, 166
Argon beam coagulator, 165
ARH, *see* Abdominal radical hysterectomy (ARH)
Arista, 165
ART, *see* Abdominal radical trachelectomy (ART)
Arterial injury, 174
Arterial ligation, 277–278, 277f
Arteries, iliac and uterine, 97f
Ascites, 174
ASIS, *see* Anterior superior iliac spine (ASIS)
Aspirin, 3
Atherosclerosis, 28
Atrial fibrillation (AF), 12
Attrition bias, 311
AUFI, *see* Absolute uterine factor infertility (AUFI)
Auscultation, 21
Autoantibodies, 64
Autoimmune skin dystrophy, 273–274
Autologous tissue, 255, 258
Azidothymidine (AZT), 5

Babcock
  clamp, 201
  grasping forceps, 202
Baclofen, 319
Bakri balloon, 276–277
Balloon tamponade, 276–277

Barium
enema, 242
meal, 242
Bence-Jones proteins, 60
Benzodiazepines, 324
Bereavement, 331–332, 332f
Beta human chorionic gonadotropin (bhCG), 63, 65
Bias
attrition, 311
detection/assessment, 310
meta-analysis of survival data, 310–311, 310f
performance, 310
potential bias inherent in RCTs, 311–312, 311f
publication, 312
reporting, 311
selection, 310
survival data, meta-analysis, 310–311, 310f
Biclamp®, 87
Bilateral gracilis myocutaneous flaps, 264, 264f
Bilateral ligation, 277
Bilateral permanent nephrostomies, 239
Bilateral salpingo-oophorectomy, 185
Bimanual massage, uterine compression sutures, 275
Biopsy, 34
Bipolar electrodesiccation, 191, 203
Bipolar sealing, 171
Bladder biopsy
cystoscopy and stenting, 59
Bladder drainage, 253
Bladder pillars, 26f, 91f
sections, 91
Bleeding, risk of, 2, 3t
"Bleed-through" radioactivity, 135
Blinding of participants, personnel, and outcome assessors, 312
Blind-loop syndrome, 223
Blood-borne infections, preventions, 6–7
Blood-borne pathogens, 5
risk factors for transmission, 7t
Blue dye, mapping, 132–134, 140–141
B-Lynch suture technique, 275–276, 276f
B2 microglobulin, 62
Boari flap, 232, 233f
Bones and cutaneous landmarks, surgical anatomy, 33
Bonney scissors, 125
Bowel complications, surgery, 20–22
Bowel loops, 221
Bowel management, 253
Bowel obstructions, 21
Bowel resection, 157, 163
Brachytherapy, 102
endometrial cancer
medically inoperable endometrial brachytherapy, 289
postoperative vaginal cuff brachytherapy, 286–289
by malignancy
cervical cancer, 283–286
techniques
dose rate, 282
interstitial brachytherapy, 282
intracavitary brachytherapy, 282
vaginal cancer, 289–290
vulvar cancer, 290
Breathlessness, 322, 323, 324
Broad-spectrum antibiotics, 20, 21, 118; *see also* Antibiotics
Brooke stitches, 234–235
Bulky lymph node, 218

Caesarean hysterectomy, 278–279
Calcium channel blockers, 12
Calf VTE, 4; *see also* Venous thromboembolism (VTE)
Caliber red Robinson catheter, 166
Cancer antigen 125 (CA125), 60–61, 62, 63, 65
Cancer antigen (CA) 19-9, 63
Cancer field theory, 109
Cancer treatments impact on female fertility, 148
Carbon dioxide insufflator, 170
Carcinoembryonic antigen (CEA), 63
Carcinoma of endometrium, 34
computed tomography, 35–36
imaging, role of, 34
magnetic resonance imaging, 36–39
positron emission tomography-CT (PET-CT), 39
ultrasound, 34–35
Carcinoma of the uterine cervix, 110
Cardiac arrhythmias, 9
Cardiac risk, perioperative, 8
Cardinal and uterosacral ligaments, 192
Cardinal ligaments, 76f
Cardinal ligaments (Kocks), 25, 26f, 89f, 91–92
Catheters
central venous catheters, complications and management of, 180, 180t–182t
epidural, 319, 319f
Hickman, 175, 180
maintenance and access of, 179–180, 180f
Malecot, 235
Sengstaken, 277
temporary balloon, 279–280
tip occlusion, 180
tunneled epidural, 319, 319f
Catheter-related infections, 175
Catheter-related injuries, 240
Cavitron ultrasonic aspirator, 161
Cavitron ultrasonic surgical aspirator (CUSA), 165
Celio-Schauta, *see* Laparoscopically assisted vaginal radical hysterectomy (LAVRH)
"Cell Saver" technology, 279
Censoring, 305
Centers for Disease Control and Prevention (CDC), 5
Central venous catheters, complications and management of, 180, 180t–182t
Central venous lines, 175
Centrum tendinum, 27
Cephalic vein, 28f
Cervical adenocarcinoma, 64
Cervical cancer, 64, 95, 169; *see also specific cancer*
brachytherapy
anesthesia, 284
classical tandem and ovoid insertion procedure, 284, 286t
CT-based brachytherapy, 283
dose and quality implants, 283
fiducial markers, 285
GEC-ESTRO, 286, 288t
goal, 283
high-risk clinical target volume (HR-CTV), 283
image-based brachytherapy, 283
intracavitary brachytherapy applicator, 283–284, 285–286
intraoperative x-rays, 286
milligram radium equivalent-hours, 283
MRI-based brachytherapy, 283
uterine perforations, 285
vaginal packing, 286
well-positioned tandem and ovoid applicator, 286, 287t
computed tomography, 39–41
FDG PET-CT, 43–44
FIGO Staging, 39, 40t
imaging, role of, 39
magnetic resonance imaging, 41–43
patients, 109
sentinel lymph node biopsy, 140–143
ultrasound, 39
Cervical intraepithelial neoplasia (CIN), 95, 123
Cervical suture, 99f
Cervical vascular supply, 89f
Cervix, zonal anatomy, 42f
Checklist
admission for surgery, 2f
coordinator, 1
Chemotherapeutic drugs, 4
Cherney incision, 23
Chest tube, 166
Child-Turcott-Pugh (CTP) classification, 17
Choriocarcinomas, 184
Chrobak clamps, 90f
Chylous retroperitoneum, 174
Ciprofloxicin, 20
Circulating tumor DNA (ctDNA), 64
Circumflex iliac artery, 29f
Cirrhotic ascites, 326
Cisplatin chemotherapy, 283
Clavulanic acid, 118
Clindamycin, 20

Clinical decision making
meta-analysis of survival data in, 315
Clinical practice guidelines (CPG), 9
Clonidine, 319
Cobalt-60 unit, 282
Cobb periosteal dissector, 120, 120f
Cochrane Handbook for Systematic Reviews of Interventions, 311
Collateral drainage, 255
Colonoscope, 56f
Colonoscopy
inflammatory bowel disease, 243
Colostomy, formation, 227
Colpectomy, 123
endoscopic approach for, 124
Colposcopic punch biopsy, 69
Colpotomy, 114f
Complications, surgery, 20
bowel complications, 20–22
wound complications, 22–24
Compression suture postoperative complications, 276
Computed tomography (CT), 34, 35, 102, 128
cervical cancer, 39–41
endometrial cancer, 35–36
fistula repair, 242
ovarian malignancy, 45–46
vaginal cancer, 48–52
Cone biopsy, 69, 71f
anatomic considerations
bony landmarks, 69
innervation, 69
muscles involved, 69
vascular supply, 69
indications, 69
surgical procedure
loop electrosurgical excision, 69–70
scalpel "cold knife" cone, 70–71
Congestive obstructive pulmonary disease (COPD), 15
Connatal peritoneal adhesions, 110
Connective tissue body, 25
Connell stitch, 225, 225f
Conservative crystalloid replacement, 155
Constipation, 324
Contrast-enhanced CT, 35, 36f
Coronary artery disease (CAD), 8
perioperative cardiac assessment for, 11f
Corpus intrapelvicum, 25, 26f
Corticosteroids, 324
Council on Resident Education in Obstetrics and Gynecology (CREOG), 294
Cribriform fascia, 127
Crohn's disease, 240
Crowd-Sourced Assessment of Technical Skills (C-SATS), 298–299
Crowdsourcing for proficiency assessment, 296–299
Crush artifacts, 123
Cryopreservation, ovarian tissue, 149
processing, 149
tissue harvesting, 148–149
C-SATS, *see* Crowd-Sourced Assessment of Technical Skills (C-SATS)
CT (T12–L1), 28
CT-based brachytherapy, 283
Cutaneous advancement flaps, 260
Cutdown technique
checking placement of catheter, 179
connecting the port to the catheter, 179, 179f
creating a tunnel for the catheter, 179, 179f
internal jugular cutdown, 178
making the pocket for the port, 178, 178f
peritoneal access device without concurrent laparoscopy or laparotomy, 179
venous access via the cephalic vein, 178, 178f
Cystography, 242
Cystoscope/cystoscopy, 58f, 230
fistula repair, 242–243, 243f
Cystoscopy and stenting
indications, 57–58
instrumentation
flexible cystoscope, 58
rigid cystoscope, 58
operative procedure
bladder biopsy, 59
flexible cystoscope, 59
rigid cystoscope, 58
ureteric catheterization and stenting, 59
postoperative care, 59
preoperative preparation, 58
Cytokeratin 19, polymerase chain reaction (PCR) testing for, 137f
Cytoreduction
surgery for advanced, 165
upper abdominal, *see* Upper abdominal cytoreduction

Dacron, 258
1-deamino-8-Darginine vasopressin (dDAVP), 17
Debulking, 164–165
Decision-making
clinical, meta-analysis of survival data in, 315
in gynecologic oncology, 303f
Deep circumflex iliac artery, 28f
Deep venous thrombosis (DVT), 1, 169, 179–180, 258
Defect sites
groin/suprapubic, 267
pelvic cavity, 267
perineum, 268
vagina, 268
Deltoid-pectoral triangle, 33
Depression and anxiety, 324
Desiccation, 210
Detection/assessment bias, 310
Dextrans, 3
Diabetes-associated perioperative risk, 15
Diabetes mellitus, 15–16
Diagnosis
endometrial cancer, 34
ovarian and fallopian tube cancer, 62–63
Diaphragmatic disease, 164
Diaphragmatic swabs for cytology, 156
Diaphragm resection (DR), 163, 164
Dichotomous measures in meta-analysis, 305
Diffusion-weighted imaging (DWI), 36–37
Diffusion-weighted whole-body imaging with background body signal suppression (DWIBS), 43
Digital rectal examination (DRE), 55
Direct clamping, 255
Disease-modifying palliative treatment, 323
Dissection and repair in layers, urogenital fistula, 245–246
Distal exteriorization, 200
Distal pancreatectomy, 164
Doctor–patient communication
bereavement, 331–332, 332f
external facilitator, 329
four-cusp approach
cusp A: potentially curable, 329–330
cusp B: living with cancer, 331
cusp C: pre-terminal phase, 331
cusp D: terminal phase, 331
psychology, 332, 332f
religion, 332, 332f
spirituality, 332, 332f
Dog-ears, 123
Doppler flow ultrasonography, 184
Dose rate, brachytherapy, 282
Drug-eluding stent (DES), 10
Dual prophylaxis, 13
Duodenum, 27f
Duplex ultrasonography, 13
Dye tests, intestinal fistulas, 241
Dying patient, palliative care, 326–327

Early menarche, 34; *see also* Menstrual cycle
Early stage disease (FIGO IA-IB1), 283
EBRT, *see* External beam radiotherapy (EBRT)
Electrocardiogram (ECG), 9, 177
Electrosurgery, 202
Elliptical skin paddle, 269
EMBASE, 301
Embryo or oocyte cryopreservation, 148
En bloc resection, 157–158, 158f
End colostomies, 223
Endoanal ultrasound scans
fistula repair, 242
Endocervical curettage (ECC), 92
Endocrinologic risk, assessment
adrenal suppression, 16–17
diabetes mellitus, 15–16
thyroid dysfunction, 16
End-of-life, palliative care, 323; *see also* Palliative care

Endo-GIA, 167
Endometrial adenocarcinoma with myometrial invasion, 38f
Endometrial cancer, 34, 65, 169
  computed tomography, 35–36
  diagnosis, 34
  FIGO staging, 35f
  imaging, role of, 34
  magnetic resonance imaging, 36–39
  medically inoperable endometrial brachytherapy, 289
  positron emission tomography-CT (PET-CT), 39
  postoperative vaginal cuff brachytherapy, 286–289
  staging, 215–216
  ultrasound, 34–35
Endometrial cavity, 36
Endometriosis, 191
Endopelvic fascia, 25
End-organ dysfunction, 21
Endoscopy
  approach for colpectomy, 124
  fistula repair, 242–243
Endovascular catheterization technique, 280
End stage renal disease (ESRD), 17
End-to-end anastomosis (EEA) stapling instruments, 197
End-to-end circular stapling device (EEA), 225–227
Enhanced recovery after surgery (ERAS), 224
Epidural and spinal opioids, 319
Epidural catheters, 319, 319f; *see also* Catheters
Epithelialization, 23
Epithelial ovarian cancer (EOC), 60
  advanced disease, surgical techniques for
    appendectomy, 158–159, 159f
    bowel resection, 157
    en bloc resection, 157–158, 158f
    liver nodules excision, 161, 161f
    maximum surgical effort, 157
    omentectomy, 160–161, 160f
    splenectomy, 159, 159f, 160f
  apparent early-stage disease, surgery for, 161, 161f
  cytoreduction surgery for advanced, 165
  germ cell and stromal tumors of the ovary, 161
  interval debulking surgery, 161
  palliative surgery, 161
  preoperative assessment, 156
  preoperative investigations, 156
  primary laparotomy, 156–157
  second-look surgery, 161
  splenectomy, 164
Epithelioid trophoblastic tumors (ETTs), 184
Erythropoetin, 17
Euglobulin lysis, 1
European Organisation for Research and Treatment of Cancer (EORTC), 161
European Society of Gynecologic Oncology, 166
Evicel®, 22
Evidence-based healthcare, 301
Examination under anesthesia (EUA), 34
Excretion urography, 241–242, 242f
Execution of the surgical plan, 267
Exenteration, 117
Exenterative surgery, 102
  operative procedure, 104–105
    anterior exenteration, 105–107
    pelvis, empty, 107
  patient assessment, 102
    absolute contraindications, 102–103
    exenteration, 103
    intraoperative assessment, 103–104
    preoperative preparation, 103
    relative contraindications, 103
  patient selection, 102
  postoperative care, 107–108
Exophytic lesion, 93f
Expected intraoperative hemorrhage, 279
Expertise-based RCT, 313–314
Exposure-prone procedures (EPP), 5
Extensive bulky nodes, 167
External beam radiotherapy (EBRT), 282
External facilitator, doctor–patient communication, 329
External iliac artery, 28f
Extra-anatomic bypass, 255
Extracellular tissue matrix (ECTM), 148, 150
Extra-pelvic lymph nodes, 102

Fascial dehiscence, 24
Fascial planes in groin incisions, 129
Fasciocutaneous neurovascular pudendal thigh flaps, 264–265, 265f
Fat transfer
  adverse events, 273
  clinical applications and experience, 273–274
  methods, 273
Fatty tissue, 111, 111f
FDG PET-CT
  cervical cancer, 43–44
  endometrial cancer, 39
Fecaluria, 240
Federation of Gynecology and Obstetrics (FIGO), 34, 39
Fee-for-performance, 293
Ferric subsulfate, 70
Fertility preservation
  abnormality, 187
  conservative therapy, 186
  failure rate, 187
  fertility sparing surgery, 186
  frozen section assessment, 187
  gynecological malignancies, 187
  limitations, 187
  modified Strausmann procedure (MSP), 186–187
  ultrasound scan (USS), 187
Fertility-sparing procedure, 101
Fertility-sparing radical trachelectomy, 94
Fertility sparing surgery, 186
Fetus and umbilical cord clamping, 280
2-(F-18) Fluor-2-deoxy-D-glucose positron emission tomography (18 FGD PET), 34
F-18 2-Fluoro-2-deoxy-D-glucose (FDG), 39
Fibrosis, 28
FIGO staging system
  cervical cancer, 39, 40t
  IB to IIA, 109, 110
  ovarian cancer, 47t
  vaginal cancer, 52t
  vulval cancer, 52t
Finland hysterectomy (FINHYST) series, 230
Fistula repair
  etiology and epidemiology
    classification, 240–241
    genital fistulae, etiology of, 240t
    inflammatory bowel disease, 240
    malignancy, 239
    obstetric causes, 239
    postoperative fistula, risk factors for, 240t
    radiation, 239
    surgical causes, 239
  investigations
    biochemistry and microbiology, 241
    dye studies, 241
    endoscopy, 242–243
    examination under anesthesia, 242
    imaging, 241–242, 242f
  operative technique
    anal and rectovaginal fistula repair, 251–253
    interposition grafting, 250–251
    urogenital fistula repair, *see* Urogenital fistulas
  postoperative management
    antibiotics, 253
    bladder drainage, 253
    bowel management, 253
    fluid balance, 253
    mobility and thromboprophylaxis, 253
    subsequent management, 253
  preoperative management
    intestinogenital fistula, 244
    urogenital fistula, 243–244
  presentation, 241
  surgical treatment, general principles of
    dissection, 245, 245f
    instruments, 245
    route of repair, 244–245
    suture materials, 245
    timing of repair, 244

Fistulography, 242
Flap options
  anterolateral thigh flap (ALT), 268, 268f
  gluteal flap, 269, 269f
  omental flap, 269
  posterior thigh flap (PTF), 269–270, 270f
  sartorius flap, 270
  tensor fascia lata (TFL), 270–271
Flexible cystoscope
  cystoscopy and stenting, 58, 59
Flexible sigmoidoscope
  sigmoidoscopy, 55, 57
Flexible sigmoidoscopy, 55
FloSeal®, 22
Fluid balance, 253
Foley catheter, 85
Four-cusp approach
  cusp A: potentially curable, 329–330
  cusp B: living with cancer, 331
  cusp C: pre-terminal phase, 331
  cusp D: terminal phase, 331
Frozen section assessment, 187
Full-thickness cutaneous advancement flaps, 260–261, 261f
Full-thickness resection (FTR)
  diaphragm, 165
Functional capacity, 9
Fundamentals of Robotic Gynecologic Surgery (FRGS), 296
Fundamentals of Robotic Surgery (FRS), 296

Gambee interrupted inverted seromucosal technique, 222–223, 223f
Ganglion impar block, 319
Garbage in, garbage out (GIGO) effect, 310
Gastric artery, 28f
Gastrocolic ligament, 27f
Gastroduodenal artery, 28f
Gastrointestinal anastomosis stapling instruments, 196–197
Gastrointestinal endoscopy, 55
Gastrointestinal surgery
  large intestine surgery, 223–229
  small bowel, 220–223
  stomach, 220
GEARS, *see* Global Evaluative Assessment of Robotic Skills (GEARS)
Gelfoam®, 22, 165
Genital fistulae, etiology of, 240t
Genital metacompartment, 117
Genitofemoral nerve, 29f, 127
Germ cell and stromal tumors of the ovary, 161
Gestational trophoblastic disease (GTD), 64, 184
Gestational trophoblastic neoplasia (GTN), 64, 184
Gestational trophoblastic tumors, 64, 184
Global Evaluative Assessment of Robotic Skills (GEARS), 299
Gluteal flap, 269, 269f
Gluteal thigh flap, 269–270, 270f
Goals of reconstruction, 267
GOG-173, 128
Gonadal artery, 28f
Gonadotoxic chemotherapy agents, 148
Gore-Tex graft, 166
Gracilis flap, 263–264, 263f, 264f
  traditional reconstructive options and their limitations, 266
Gracilis muscle, 250
Graves' disease, 16
Greater omentum, 27f
Groin/suprapubic
  defect sites, 267
GROINSV-1, 128
GROningen INternational *Study* on *Sentinel nodes* in Vulvar cancer (GROINSS-V), 138
Gross tumor volume (GTV), 283
GTD, *see* Gestational trophoblastic disease (GTD)
GTN, *see* Gestational trophoblastic neoplasia (GTN)
Gynecological malignancies, 34
Gynecologic intracavitary brachytherapy, 282
Gynecologic oncology, 3
  surgeons, 27
  survival data in, 301
Gynecologic Oncology Group (GOG) protocol, 138
Gyrus bipolar cutting forceps, 165

Habib probe, 165
Hand-held wall suction, 69
Handsewn anastomosis, 221
Hand-sutured colonic anastomoses, 224–225, 225f
Harmonic scissors, 73, 74
Hartmann pouch, 200
Hazard function and cumulative hazard function, 307
Hazard ratios (HRs), 305, 307–308
Health economic rationing, 301
Heart failure (HF), 8
Hematologic risk, assessment
  thromboembolic disease, 12–13
Hematoxylin and eosin (H&E) staining, 137
Hemoclips, 73
Hemofiltration, 279
Hemostatic agents, 165
Hemothorax, 179
Heparin-induced thrombocytopenia (HIT), 13
Heparinization, 13
Heparin to prophylax, 169
Hepatectomy, 166
Hepatic artery, 28f
Hepatic risk, assessment, 17
Hepatitis B e antigen (HBeAg), 6
Hepatitis B virus (HBV), 5
Hepatitis C virus (HCV), 5, 6
Heterogeneity
  addressing, 309
  measurement, 308–309
  between study results, 308
Heterotopic ovarian transplantation, 150–151
Hickman catheters, 175, 180
High dose rate (HDR), 282
High-grade serous carcinoma (HGSC), 60
High molecular weight dextran, 3
High-risk clinical target volume (HR-CTV), 283
Hormone replacement therapy, 34
Hospices, palliative care, 322
Hot Shears™, 216
Human chorionic gonadotropin (hCG), 64–65
  levels, 184
  negative germ cell tumors, 63
Human epididymis protein 4 (HE4), 61
Human immunodeficiency virus (HIV), 5
Human papilloma virus, 39
Humidification during surgery
  hypothermia, 208–209
  insufflation gas on
    pain, 210
    postoperative adhesions, 210–211
    recovery time, 211
  laparoscopic surgery, 208
  open surgery, 211
  peritoneum physiology, 208
  tissue damage, 209
Hydatidiform molar pregnancy, 184
Hydro-dissection, 163–164
Hyperalimentation, 21
Hypercellular tumors, restricted diffusion, 37
Hyperthyroidism, 16
Hypoalbuminemia, 224
Hypogastric (internal iliac) arteries, 255
Hypogastric midline laparotomy, 110, 110f
Hypogastric nerves and proximal inferior hypogastric plexus, 113f
Hypogastric plexus, 69
Hypothalamic pituitary axis (HPA), 16
Hypothermia, 208
  humidification during surgery, 208–209
Hysterectomy, 169, 191, 278–279
  anatomic considerations, 190–191
  laparoscopically assisted vaginal hysterectomy, 189–190
  laparoscopic hysterectomy, 189–190
  surgical procedure, 191–193, 191f–193f
  therapeutic benefit, 186, 186f
  total laparoscopic hysterectomy, 189–190
Hysteroscopy, 34

Ileal conduit, 234–235
Ileal ureter, 232–233
Ileocolic arteries, 28

Ileo- or colovaginal fistulas, 244
Iliac artery, ligation of the internal, 119f
Iliac bifurcation, 80f
Iliac lymph basins, 109
Iliohypogastric nerve, 29f
Ilioinguinal nerve, 29f
IMA, *see* Inferior mesenteric artery (IMA)
Imaging
  of cervical cancer, 39
  of endometrial cancer, 34
  vaginal cancer, 47
Immunosuppressive therapy, 154
Implantable cardioverter defibrillators (ICDs), 10
Implantable electronic device (IED), 9
Incision, 123
Incomplete outcome data, 312
Independent Review Board (IRB)-approved research project, 155
Indiana pouch, 235–236, 236f
Indocyanine green (ICG), 135–136
Indwelling red rubber catheter, 236
Indwelling ureteric stenting, 231
Infection
  control, 5–6
  prophylaxis, 1, 4–5
Infectious complications, 174
Inferior epigastric artery, 28f, 29, 29f
Inferior hypogastric plexus, 112
Inferior mesenteric artery (IMA), 28, 28f, 171
  supply blood, 255
Inferior rectal artery, 28f
Inferior vena cava (IVC) filters, 12, 27, 258, 258f
Infertility, 34
Inflammatory bowel disease, 240
Infrarenal (IR) nodes removal, 171
Infundibulopelvic ligaments, 104f, 105, 111, 119
Inhibin and anti-mullerian hormone, 63–64
Insufficient high-quality trial data, 302
Insufflation gas
  on pain, 210
  on postoperative adhesions, 210–211
  on recovery time, 211
Intention-to treat policy, 311
Intercalated (secondary) lymph nodes, 109
Intermediate cardiac risk factors, 9t
Intermittent manual occlusion, 278
Intermittent pneumatic compression (IPC), 13
Internal iliac artery, 28f, 29f
Internal jugular vein, 28f
Internal pudendal artery, 28f
International normalized ratio (INR), 12
International Ovarian Tumor Analysis (IOTA) simple rules, 44, 45t
Interposition grafting
  Gracilis muscle, 250
  martius graft, 250
  omental pedicle grafts, 250
  peritoneal flap graft, 250–251
Interstitial brachytherapy, 282
Interval debulking surgery, 161
Interventional radiologic (IR) procedures, 279
Interventional techniques in gynecological malignancy
  epidural and spinal opioids, 319
  Ganglion impar block, 319
  presacral neurectomy, 319–321, 320f
  superior hypogastric plexus block (neurolytic), 319
  technique, 319
Intestinogenital fistula, 244
  route of repair, 245
  timing of repair, 244
Intraabdominal cytoreduction, 166
Intra-abdominal tumor debulking, 164
Intra- and extraabdominal metastatic deposits, 156, 157f
Intracavitary applicators, 282, 283f
Intracavitary brachytherapy, 282
Intracorporeal and extracorporeal stapling, 197
Intraembryonic coelom (embryonic body cavity), 27
Intraoperative bowel injuries, 20
Intraoperative cell salvage (ICS) systems, 279
Intraoperative detection, 135
Intra-operative radiation therapy, 102
Intrapelvic fascia, 25
Intraperitoneal access devices, 175
Intra peritoneal (IP) chemotherapy, 164
Intrathoracic cytoreductive surgery, 166
Intraumbilical trocar, 201
Intravenous antibiotics, 20, 22
Invasive cervical carcinoma, 41
Ipsilateral vasodilatation, 31
Ischemic and necrotic tumor, 317
Ischiosacral ligament, 26f
Isthmus, 88

"Kaplan–Meier" curve calculation, 308
Kelly clamp, 170
Kho™ rings, 216

Laparoscopically-assisted vaginal hysterectomy (LAVH), 79, 196
Laparoscopically assisted vaginal radical hysterectomy (LAVRH), 79–80
  surgical procedure, 80
    endpoints, indications, 86
    laparoscopic operation, 80–81
    postoperative course, complications, 86
    vaginal surgery, 81–86
Laparoscopic bowel surgery, 196
Laparoscopic lymphadenectomy
  cervical carcinoma, 169
  complications, 173–174
  endometrial carcinoma, 169
  left inframesenteric aortic nodes harvesting, 171–172, 171f–172f
  opening the space, 170–171, 170f
  ovarian carcinoma, 169
  pelvic nodes harvesting, 173, 173f
  pneumoretroperitoneum, 171
  postoperative management, 173
  preparation, 169
  right aortic nodes resecting, 172–173
  surgical outcomes, 173
  technique, 169–170, 170f
Laparoscopic pelvic lymphadenectomy, 95
Laparoscopic presacral neurectomy, 319–321, 320f
Laparoscopic surgery
  humidification during surgery, 208
  minimally invasive surgery, 293
Laparoscopy
  appendectomy, 189
  hysterectomy, 189–193
  laparoscopic bowel surgery, 196–197
  left hemicolectomy, 199–200
  loop ileostomy, 197–198
  lymphadenectomy, 202–206
  omentectomy, 195–196
  palliative end colostomy, 200–202
  radical hysterectomy, 193–195
  right hemicolectomy, 198–199
Laparotomy, 110, 110f, 158, 184
  closure, 115f
Large intestine surgery
  anatomic considerations, 223–224
  end colostomies, 223
  indications, 223
  loop colostomies, 223
  ovarian cancer debulking, 223
  surgical procedures
    adequate mobility, 227
    appendectomy, 228–229
    colostomy formation, 227
    Connell stitch, 225, 225f
    end-to-end circular stapling device (EEA), 225–227
    enhanced recovery after surgery (ERAS), 224
    hand-sutured colonic anastomoses, 224–225, 225f
    hypoalbuminemia, 224
    loop colostomy, 228
    oral antibiotic prophylaxis, 224
    resection and anastomosis, 224
    single-layer anastomosis, 225, 225f
    stoma in "rosebud" fashion, 228, 228f
    stoma placement, 227
Late menopause, 34; *see also* Menstrual cycle
Lateral femoral cutaneous nerve, 29f
Laterally extended endopelvic resection (LEER), 117, 118f
  ontogenetic surgical anatomy, 117–118
  pelvic floor and sidewall, 119f
  surgical procedure
    contraindications, 118
    indications, 118
  technique, 118–121
Laterovesical ligament, 26f

LAVRH, *see* Laparoscopically assisted vaginal radical hysterectomy (LAVRH)
Learning curve effect, 86
LEER, *see* Laterally extended endopelvic resection (LEER)
Left hemicolectomy
  anatomic considerations, 199
  EEA stapling device, 200, 200f
  hand-port device, 199, 200f
  indications, 199
  sigmoid colon, 199, 200f
  surgical procedure, 199–200
Left upper quadrant (LUQ), 215
Legal liability, 301
Lesion, identification, 123
Lesser omentum, 27f
Levator animuscle, 111
Lichen sclerosus (LS), 273–274
Ligamentous mesometrium, 109
  dissection, 114f
Ligamentum latum, 111
Ligamentum ovarii propium, 111
Ligamentum rotundum, 111
Ligasure®, 87
LigaSure device, 165
Linear stapling device, 189, 201
Liquid biopsy, 64
Liver, 27f
  nodules excision, 161, 161f
  resection, 163
Local anesthesia, 70
Local infiltration by tumor, 317
Locally advanced disease (FIGO IB2-IVA and/or node positive), 283
Local skin flaps
  traditional reconstructive options and their limitations, 266
Logistic regression model 2 (LR2), 62–63
Logothetopulos pack, 279
Loop colostomies, 223, 228
Loop electrosurgical excision procedure (LEEP), 69
Loop excision of the transformation zone (LETZ), 69
Loop ileostomy, 197–198, 198f
Low dose rate (LDR), 282
Lower abdominal subcutaneous tissue, 151
Low-molecular weight heparin (LMWH), 3, 12, 13
Lumbar spinal nerves, 31
Lymphadenectomy, 72
  anatomic considerations
    para-aortic nodes, 202
    pelvic nodes, 202, 204f
  indications, 202
  surgical procedure
    para-aortic lymphadenectomy, 202–203, 204f–205f
    pelvic lymphadenectomy, 204–206, 205f
Lymphatic mapping, 132, 133
Lymphatic spread in ovarian cancer, 30f
Lymph node
  metastases, 30
  sampling, 185
Lymphogranuloma venereum, 240
Lymphotrophic dyes, 132

"Macmillan nurses," 322
Macromolecular tumor, 61
Magnetic resonance imaging (MRI), 34, 102
  cervical cancer, 41–43
  endometrial cancer, 36–39
  fistula repair, 242
  ovarian malignancy, 46
Major adverse cardiac events (MACE), 8
Major cardiac risk factors, 9t
Malecot catheter, 235; *see also* Catheters
Malignancy, fistula repair, 239
Malignant ascites, 325–326, 325f
Malignant bowel obstruction, 324–325
Malignant invasive moles, 184
Malignant tumors, 117
Management, 185–186
Marginal artery of Drummond, 200
Martius graft, 250
Massive transfusion protocols, 278–279
Maximum surgical effort, 157
McBurney incision, 170
Measles, 240
Menstrual cycle; *see also* Early menarche; Late menopause
  endometrial cavity, 36
  ultrasound, 34–35, 35f
Mesentery, 27f
Mesoappendix, 27
Mesoesophagus, 27
Mesogastrium, 27
Mesosalpinx, 111
Mesoureteral mobilization II°, 113f
Mesureteral mobilization I°, 111f
Meta-analysis of survival data, 305
  advantages over narrative reviews, 304–305
  advantages over RCTs, 305
  benefits of, 312
  bias, 310–311, 310f
  in clinical decision making, 315
  conflicting results, 302
  decision-making process in gynecologic oncology, 303f
  definition, 301, 304
  information overload, 301
  insufficient high-quality trial data, 302
  narrative review, 302
  pitfalls in conducting, 309–310
  potential bias inherent in RCTs, 311–312, 311f
  publication bias, 312
  quality of, 312–313, 313f
  quality of gynecologic oncology, 313–314
  RCTs limitations, 302
  and software, 314–315
  solution, 303
  in surgical context, 309
Metabolic abnormalities, urinary diversion, 233
Metabolic equivalents, 10t
Meticulous sterile technique, 180
Metronidazole, 20, 118
Metzenbaum scissors, 83, 83f, 90
Micro-Breiski retractor, 83
Midazolam, 319
Milligram radium equivalent-hours, 283
Minimally invasive surgery
  American Board of Surgery (ABS), 293
  demonstrating surgical excellence
    crowdsourcing for proficiency assessment, 296–299
    surgical portfolios, 299
  fee-for-performance, 293
  global and procedure-specific skills assessment tools, 294
  global rating scale of operative performance, 294t
  innovative training networks and validation of skills
    Fundamentals of Robotic Surgery (FRS), 296
    robotic training network, 295–296, 295f–298f
  laparoscopic surgery, 293
  methods of assessment in residency programs, 293–294
  OB-GYN educational programs, 293
Minor cardiac risk factors, 9t
Mixed malignant Mullerian tumors (MMMT), 34
Mobility and thromboprophylaxis, 253
Model of end-stage liver disease (MELD), 17
Modified Strausmann procedure (MSP), 186–187
Monofilament suture, 166
Monsel's solution, *see* Ferric subsulfate
Moral-ethical obligations, 301
MRI-based brachytherapy, 283
MSP, *see* Modified Strausmann procedure (MSP)
Müllerian compartment, 109, 110, 110f, 112f
Multi disciplinary team (MDT), 330
Muscles, surgical anatomy, 32–33
Muscular incision, 121
Myocardial infarction (MI), 8, 9
Myocardial Infarction and Cardiac Arrest (MICA), 9
Myocutaneous flap, 264, 264f, 267

Nasogastric tube suctioning, 21
National End of Life Care Strategy, 325
National Surgical Quality Improvement Program (NSQIP), 9
Nausea and vomiting, 324
Needle excision of the transformation zone (NETZ), 69

Needlestick injuries, 5
precautions available to, 7t
Neoadjuvant chemotherapy, 94
Neobladders, 235, 235f
Neovaginal pouch, 264, 265f
Nerves, surgical anatomy, 31–32
Neuropathic pain, 317, 319
Neurovascular plate, 25
Nil per orum (NPO), 21
N-methy-D-aspartate (NMDA) receptor, 317
Nociceptive pain, 317
Nocturnal incontinence, 234
Noma vaginae, 240
Nonpharmacological treatment, 323
Nuclear magnetic resonance (NMR) imaging, 128

Obesity, 1, 13, 22, 34, 65, 103, 174, 220, 289
OB-GYN educational programs, 293
Objective Structured Assessments of Technical Skills (OSATS), 294–295
Oblique aponeurosis, 131f
Obstetric causes
fistula repair, 239
Obstetric fistulas, 243
Obstructive sleep apnea, 15
Obturator artery, 28f
Obturator fossa, 74f, 75f
Obturator muscle, 111
Occupational therapists, palliative care, 322
Odds ratios (ORs), 305
Omental bursa, 27, 27f
Omental flap, 269
Omental pedicle grafts, 250
Omental pelvic floor, 107f
Omentectomy, 160–161, 160f, 163
anatomic considerations, 195
surgical procedure, 195–196, 195f–196f
uterine papillary serous adenocarcinoma, 195
Omentum, mobilization, 107
Ontogenetic surgical anatomy, 109–110, 110f
Oophorectomy, 191
Open surgery
humidification during surgery, 211
Open ureteric reimplantation, 232
Operation, phases
anesthesia, before induction of, 1
sign out, 1
time out, 1
Operative technique, fistula repair
anal and rectovaginal fistula repair
laying open of fistula track, 251
rectal advancement flap, 251, 251f
transabdominal, 253
transanal, 252
transperineal, 251–252, 252f
transvaginal, 252
interposition grafting
Gracilis muscle, 250
martius graft, 250
omental pedicle grafts, 250
peritoneal flap graft, 250–251
urogenital fistula repair, *see* Urogenital fistulas
Opiates, 319
Opioids, 324
Optimal cytoreductive surgery, 163
OQAQ, *see* Overview Quality Assessment Questionnaire (OQAQ) scale
Oral antibiotic prophylaxis, 224
Oral anticoagulation, 4; *see also* Anticoagulation
Orthogonal planar x-rays, 283
Orthotopic neobladder, 235, 235f
OSATS, *see* Objective Structured Assessments of Technical Skills (OSATS)
Osteomyelitis, 273
Ovarian and fallopian tube cancer, 60
Ovarian arteries, 29
Ovarian granulosa cell/sex cord/stromal tumors, 63
Ovarian malignancy (cancer), 44, 169, 218; *see also specific cancers*
computed tomography, 45–46
debulking, 223
magnetic resonance imaging, 46
palliative care, 323
pelvic imaging, 44
PET-CT, 46–47
tumor markers in, 60
CA125, 60–61
human epididymis protein 4 (HE4), 61
ultrasound, 44–45
Ovarian pedicles, 96
Ovarian tissue
cancer treatments impact on female fertility, 148
cryopreservation, 149
processing, 149
tissue harvesting, 148–149
transplantation, 149–150
forearm, 151
heterotopic ovarian transplantation, 150–151
lower abdominal subcutaneous tissue, 151
pelvic orthotopic transplantation, 150
Overview Quality Assessment Questionnaire (OQAQ) scale, 312–313

P53, 64
PAC, 175
Pain management
algorithm for, 318f
initial management, 318–319
interventional techniques in gynecological malignancy
epidural and spinal opioids, 319
Ganglion impar block, 319
presacral neurectomy, 319–321, 320f
superior hypogastric plexus block (neurolytic), 319
technique, 319
ischemic and necrotic tumor, 317
local infiltration by tumor, 317
neuropathic pain, 317, 319
nociceptive pain, 317
in patients, 317
visceral pain physiology
anatomy to explain clinical features, 317
pain from compression of pelvic structures, 317
Palliative care
anorexia, 324
anxiety and depression, 324
breathlessness, 324
clinical challenges for palliative care in gynecology oncology
malignant bowel obstruction, 324–325
recurrent malignant ascites, 325–326
communicating with the family and with other professionals, 326
constipation, 324
definition, 322
disease-modifying palliative treatment, 323
dying patient, 326–327
nausea and vomiting, 324
nonpharmacological treatment, 323
symptom control, 323–324
symptom management, 323
woman with gynecological cancer, 322–323
Palliative end colostomy
anatomic considerations, 200–201
indications, 200
surgical procedure, 201–202, 201f–202f
Palliative end sigmoid colostomy, 200
Palliative surgery, 161
PA-LND, *see* Para-aortic lymph node dissection (PA-LND)
Pancreas, 27f
Para-aortic lymphadenectomy, 202–203, 204f–205f
Para-aortic lymph nodes, 104
Para-aortic lymph node dissection (PA-LND), 216–217
Paracervical ligament, 85f
Paracolpium, 25, 26f
Paramesonephric–mesonephric complex, 109
Parametrium, 73f, 98f
Parangium hypogastricum (Pernkopf), 25
Pararectal fossa, 29f
Pararectal spaces, 26f, 76f, 77f
Paratissue (Stoeckel) parametrium, 25
Paravesical fossa, 29f
Paravesical space, 26f, 73f
Parenchymal liver metastases, 49

Parietal pelvic fascia, 25
Partial thromboplastin (PTT), 22
Patchy ischemia, 28
Pelvic adhesions, 191
Pelvic and aortic lymphadenectomy, 169
Pelvic and para-aortic node assessment, 104f
Pelvic carcinoma, 102
Pelvic cavity
  defect sites, 267
Pelvic fascia
  surgical anatomy, 25–27, 26f
Pelvic floor musculature, 105
  closure, 106f
Pelvic imaging
  carcinoma of endometrium, 34
    computed tomography, 35–36
    imaging, role of, 34
    magnetic resonance imaging, 36–39
    positron emission tomography-CT (PET-CT), 39
    ultrasound, 34–35
  cervical cancer
    computed tomography, 39–41
    FDG PET-CT, 43–44
    imaging, role of, 39
    magnetic resonance imaging, 41–43
    ultrasound, 39
  ovarian malignancy, 44
    computed tomography, 45–46
    magnetic resonance imaging, 46
    PET-CT, 46–47
    ultrasound, 44–45
  vaginal cancer, 47
    computed tomography, 48–52
    imaging, 47
    ultrasound, 48
    vulval cancer, 47–48
Pelvic ligaments, 25
Pelvic lymphadenectomy, 74f, 95, 96, 204–206, 205f
  in microinvasive carcinomas, 96f
Pelvic lymph nodes, 79
  basins, 110f
Pelvic malignancies
  localized recurrence of, 218
Pelvic masses in pregnancy, 218
Pelvic orthotopic transplantation, 150
Pelvic peritoneum, 89f
Pelvic sidewall spread, 103
Pelvic spaces, surgical anatomy, 25–27
Pelvic splanchnic, 31
  nerves, 27
Pelvic venous plexuses, 30
Pelvic viscera, 317
Percutaneous coronary intervention (PCI), 10t
Percutaneous (seldinger) technique
  dilating the skin incision/passing the catheter, 177, 178f
  internal jugular access, 176–177
  needle insertion, 176
  passing the guide wire, 177
  subclavian vein access, 176
Performance bias, 310; *see also* Bias
Perineal and vaginal reconstruction, 270
Perineal incisions, 106
Perineum
  defect sites, 268
Perioperative beta-blockade, 12
Perioperative cardiac assessment for CAD, 11f
Perioperative hyperglycemia, 15
Perioperative medical management, 10–12
Perioperative pulmonary complications
  intraoperative factors, 15t
Peritoneal adhesions, 119
Peritoneal biopsy, 191
Peritoneal flap graft, 250–251
Peritoneal incisions, 110, 110f
Peritoneal ligaments, 27
Peritoneal recesses/gutters, 27
Peritoneum, 72
Peritoneum physiology
  humidification during surgery, 208
Per-protocol analysis, 311
Pfannenstiel incision, 23
Pharmacological prophylaxis, 2
Phenazopyridine, 241
Placental site trophoblastic tumors (PSTT), 65, 154, 184
  bilateral salpingo-oophorectomy, 185
  hydatidiform molar pregnancy, 184
  hysterectomy, therapeutic benefit, 186, 186f
  lymph node sampling, 185
  management, 185–186
  pathology, 185
  total abdominal hysterectomy (TAH), 185
Plastic reconstructive procedures
  anatomic considerations
    bony landmarks, 260
    muscles involved, 260
    nerve supply, 260
    vascular supply, 260
  indications, 260, 261f
  surgical procedure
    fasciocutaneous neurovascular pudendal thigh flaps, 264–265, 265f
    full-thickness cutaneous advancement flaps, 260–261, 261f
    gracilis flap, 263–264, 263f, 264f
    rectus abdominis flap, 261–263, 262f, 263f
Plastic surgery procedures
  defect sites
    groin/suprapubic, 267
    pelvic cavity, 267
    perineum, 268
    vagina, 268
  flap options
    anterolateral thigh flap (ALT), 268, 268f
    gluteal flap, 269, 269f
    omental flap, 269
    posterior thigh flap (PTF), 269–270, 270f
    sartorius flap, 270
    tensor fascia lata (TFL), 270–271
  general considerations
    execution of the surgical plan, 267
    goals of reconstruction, 267
    treatment history, 266–267
  traditional reconstructive options and limitations
    gracilis flap, 266
    local skin flaps, 266
    rectus abdominis flap, 266
    skin grafts, 266
Plastic surgical procedures, 104
Pneumaturia, 240
Pneumoperitoneal pressure, 206
Pneumoperitoneum-induced desiccation, 208
Pneumothorax, 179
Polydioxal or chromic Endoloop sutures, 189
Polyglactin 910 (Vicryl) suture, 197
Polyglactin tie, 159
Polymerase chain reaction (PCR) testing for cytokeratin 19, 137f
Polypectomy
  sigmoidoscopy, 57
Polytetrafluoroethylene, 258
Port-a-Cath (PAC), 175
Porta hepatis, 163
Port placement, robotic surgery, 218f
Ports types, 175
Positron emission tomography-CT (PET-CT)
  endometrial cancer, 39
  ovarian malignancy, 46–47
Posterior superior iliac spine (PSIS), 269
Posterior thigh flap (PTF), 269–270, 270f
Post-hysterectomy vault fistula, urogenital fistula, 245, 246f–247f
Post-micturition residuals, 86
Post-neurulation development, 117
Postoperative fistula, risk factors for, 240t
Postoperative glycemic control, 16
Postoperative infection, risk factors for, 5t
Postoperative mortality, 165
Postpartum hemorrhage (PPH), 279
  arterial ligation, 277–278
  balloon tamponade, 276–277
  hysterectomy, 278–279
  intraoperative cell salvage (ICS) systems, 279
  uterine artery embolization /occlusion, 279–280
  uterine compression sutures, 275–276
Postpartum hysterectomy, 278–279
Postsynaptic fibers, 31
Potential bias inherent in RCTs, 311–312, 311f
Potential threats to validity, 312
PPH, *see* Postpartum hemorrhage (PPH)

Premature ventricular contractions (PVCs), 177
Preoperative assessment, 156
Preoperative cardiac evaluation algorithm, 10t
Preoperative imaging, ureteric injury, 231
Preoperative investigations, 156
Preoperative workup, 8
  2014 ACC/AHA perioperative cardiac risk guidelines, 8–10
  cardiac risk, perioperative, 8
  endocrinologic risk, assessment
    adrenal suppression, 16–17
    diabetes mellitus, 15–16
    thyroid dysfunction, 16
  hematologic risk, assessment
    thromboembolic disease, 12–13
  hepatic risk, assessment, 17
  perioperative medical management, 10–12
  perioperative therapy, 10
  pulmonary risk, assessment, 13–15
  renal risk, assessment, 17
Presacral neurectomy, 319–321, 320f
Presacral node removal, 74f
Pressure-controlled anesthesia, 215
Presurgical Papanicolaou (Pap) smear, 69
Preterm labor (PTL), 70
Prevesical space, 26f
Primary laparotomy, 156–157
Procedural-based risk, 10t, 13
Proctoscopy, 55
  inflammatory bowel disease, 243
  sigmoidoscopy, 55
Progestogens, 324
Progression free survival (PFS), 164
0-Prolene suture, 166
Prophylactic antibiotics, 15, 22
Prophylaxis, 15
Prostate lung colorectal and ovarian cancer screening trial (PLCO), 61
Protein C, 13
Protein S, 13
Prothrombin (PT), 22
Proximal parametrium, 91–92
Pseudo-aponeurosis, 82
PSIS, *see* Posterior superior iliac spine (PSIS)
Psoas hitch, 232
Psoas muscle, 29f
PSTT, *see* Placental site trophoblastic tumors (PSTT)
Psychology, doctor–patient communication, 332, 332f
PTF, *see* Posterior thigh flap (PTF)
Publication bias, 312; *see also* Bias
PubMed, 301
Pubovesical ligament, 26f
Pudendal artery, external, 28f
Pulmonary complications
  risk factors, 165
Pulmonary embolism (PE), 1, 13, 258
Pulmonary function testing (PFT), 15
Pulmonary rehabilitation, 15
Pulmonary risk, assessment, 13–15
Pulmonologic-associated procedural-based risk, 13–15
Pulsed dose rate (PDR), 282

Quality of gynecologic oncology, 313–314
Quality of Reporting of Meta-analyses (QUOROM) checklist, 312–313
QUOROM, *see* Quality of Reporting of Meta-analyses (QUOROM) checklist

Radiation, fistulas, 248, 248f
  repair, 239
Radiation therapy, 282
Radical abdominal hysterectomy, 72
  surgical procedure, 72–78
Radical abdominal trachelectomy, 95
  anatomical considerations, 95
  FIGO staging, 95
  oncological considerations, 96
  operative procedure, 96–100
  post-operative consideration, 100
  vascular considerations, 95–96
Radical cervical hysterectomy, 95, 193–195, 193f–195f, 217–218
Radical hysterectomy operation, 80
Radical parametrectomy, 217–218
Radical trachelectomy, 93, 217–218
Radical vaginal hysterectomy, 79, 80, 89f
Radical vaginal trachelectomy, 95
Radical vaginectomy, 123
Radical vulvar surgery, 127
  anatomic considerations
    blood supply, 127
    lymphatic drainage, 127
    lymph drainage, routes of, 127
    nerve supply, 127
  indications, 127–128
    en bloc dissection, 128
    lymphatic spread and nodal involvement, 128
    pelvic node dissection, 128
  surgical procedure
    adductor muscles, 130
    deep dissection, 129–130
    Fascial Planes in the Groin Incisions, 129
    operative procedure, 128
    patient preparation, 128
    pelvic node dissection, 131
    saphenous vein, division, 129
    skin incision, 128
    thromboembolic prophylaxis, 128
    vulval incision, 130–131
Radioactive colloid injections, 134
Radiocolloid, 141–143
Radionuclides, characteristic of, 135t
Ray-Tec sponge, 217
Real-time intraoperative sonography, 176
Receiver operating characteristics (ROC), 62
RECIST, 63
Rectal biopsy
  sigmoidoscopy, 57
Rectal bleeding, 55
Rectal fascia, 89f
Rectal tumors, 55
Rectouterine peritoneum incision, 113f
Rectovaginal fistulas, 241, 244
Rectovaginal space, 26f
Rectovesical pouch, 29f
Rectum, 26f
  at sigmoidoscopy, 57f
Rectus abdominis flap, 261–263, 262f, 263f
  traditional reconstructive options and their limitations, 266
Recurrent malignant ascites, 325–326
Red blood cell washing device, 279
Regional flaps, 259
Region of interest (ROI), 39
Relative risks (RRs), 305
Religion, doctor–patient communication, 332, 332f
Renal artery, 28f
Renal function, urinary diversion, 233
Renal risk, assessment, 17
Reporting bias, 311; *see also* Bias
Resection and anastomosis, 224
Residual pneumonthorax, 165
Retrograde pyelography, 242, 242f
Retroinguinal lacuna vasorum, 111
Retroperitoneum, 119f, 169–170
Retrorectal space, 26f
Revised Cardiac Risk Index (RCRI), 9
RevMan, 315
Right hemicolectomy
  anatomic considerations, 198
  hepatocolic ligament, 199, 199f
  indications, 198
  right-colic and ileocolic vessels, 199, 199f
  surgical procedure, 199
Rigid cystoscope
  cystoscopy and stenting, 58
Rigid sigmoidoscopy, 55, 56–57
Risk classification system, 14f
Risk of malignancy index (RMI), 44–45, 62, 156, 157f
Risk of ovarian cancer algorithm (ROCA), 61
Risk of ovarian malignancy algorithm (ROMA), 62
Risk reducing salpingooophorectomy (RRSO), 62
Rivaroxaban, 3
Roberts clamps, 73
Robot-assisted Da Vinci Xi® minimally invasive surgery technique, 150
Robotic-Objective Structured Assessments of Technical Skills (R-OSATS), 295
Robotic surgery, 104
  advantages and disadvantages, 214
  operative entry, 215

operative room setup, 214
patient positioning and related anesthesia requirements, 214–215
pelvic masses in pregnancy, 218
port placement, 218f
radical hysterectomy, 217–218
radical parametrectomy, 217–218
radical trachelectomy, 217–218
surgical procedures
endometrial cancer staging, 215–216
instruments, 216
surgical tips, 216–217
uses of robotic platform, 218
Robotic training network (RTN)
benchmark scoring, 296
curriculum, 296f
phase 1 curriculum, 296, 296f, 297f
phase 2 curriculum, 296, 296f, 298f
Robotic-Objective Structured Assessments of Technical Skills (R-OSATS), 295–296
simulation drill, 295
surgical skills, 295–296, 295f
Robotic ureteroureterostomy, 232
Rochard retractor, 165
Rosebud stitch, 201f, 202
Round ligament inserting into internal inguinal ring, 29f
Route of repair
intestinogenital fistula, 245
urogenital fistula, 244
Routine cystoscopy, 230
RTN, *see* Robotic training network (RTN)

Sacral plexus, 31
Sacrogenital fold of uterosacral ligament, 29f
Sacrospinous ligament, 26f
Safety needle holder, 6f
Sagittal and axial-oblique T2-weighted MR scans, 37f, 38f, 39f
Salpingo-oophorectomy, 191
Sarcomas, 34
Sartorius flap, 270
Saucerization
urogenital fistula, 246–247, 247f
Schauta operation, 81f
Schistosomiasis, 240
Sciatic nerve, 317
Second-generation cephalosporin, 20
Second-look surgery, 161
Selection bias, 310; *see also* Bias
Selective outcome reporting, 312
Self-catheterization, 86
Sengstaken catheter, 277; *see also* Catheters
Sentinel lymph nodes (SLN), 80
Sentinel lymph node biopsy (SLNB), 48, 132
clinical experience
cervical cancer, 140–143
uterine cancer, 143–145
vulvar cancer, 137–140
historical perspective, 132
lymphatic mapping, 132
mapping techniques
blue dye, 132–134
indocyanine green and near-infrared fluorescence imaging, 135–137
radiocolloid, lymphoscintigraphy, and intraoperative gamma counters, 134–135
Sentinel nodes, 132, 137f
technique, 128
Septic shock with hypotension, 21
Sequence generation, 311–312
Serum creatinine levels, 17
Sexual dysfunction or psychosexual problems, gynecological cancer, 322
SGAP flap, *see* Superior gluteal artery perforator (SGAP) flap
Sheath/balloon catheter system, 280
Short tau inversion sequence (STIR), 36
Side-to-side anastomosis, 236
Side-to-side enteroenterostomy, 223
Siemens IMMULITE, 64
Sigmoid colon, 201–202, 201f
Sigmoid colostomy, 200
Sigmoid mesentery, 158
Sigmoid mesocolons, 27
Sigmoidoscopy, 56f
indications, 55
inflammatory bowel disease, 243
instrumentation
flexible sigmoidoscope, 55
proctoscopy, 55
rigid sigmoidoscope, 55
operative procedure
flexible sigmoidoscope, 57
polypectomy, 57
rectal biopsy, 57
rigid sigmoidoscope, 56–57
postoperative care, 57
preoperative preparation, 55
Signal intensity cervical cancer, 42f
Single direct transumbilical puncture, 169–170
Single-layer anastomosis, 225, 225f
Single photon emission computed tomography (SPECT-CT), 135–136, 136f
Skin grafts
traditional reconstructive options and their limitations, 266
Skin islands, 262, 262f
SMA (L1–L2), 28
Small bowel, gastrointestinal surgery
anatomic considerations, 220–221
small intestine layers, 221, 221f
surgical procedures
acute small bowel obstruction, 223
Allis clamps, 222
antimesenteric staple line, 222, 222f
blind-loop syndrome, 223
bowel loops, 221
clamps positioning, 221, 221f
double-layer closure, 222
Gambee interrupted inverted seromucosal technique, 222–223, 223f
handsewn anastomosis, 221
side-to-side enteroenterostomy, 223
small bowel anastomosis, 222
thoracoabdominal (TA) stapler, 222, 222f
vascular arcades, 221
Small bowel anastomosis, 222
Small intestine, 27f
mesentery, 27
Small lacerations of the major vessels, 255–256
Small or large bowel bypass, 196–197
Solitary splenic metastasis, 156, 157f
Specialist palliative care, 322
Speculum blades, 70f
Spencer Wells clips, 129
Spinal analgesia, 319
Spirituality, doctor–patient communication, 332, 332f
Splanchnic nerves, 31
Spleen ± distal pancreas, 163
Splenectomy, 159, 159f, 160f, 164
Splenic artery, 28f
Splenic flexure, 164
Squamocolumnar junction, 70f
Squamous cell, 88
carcinoma, 137f
antigen, 64
Standardized uptake values (SUV), 39
Steri-Strips, 23
Stomach, 27f
Stomach, gastrointestinal surgery
anatomic considerations, 220
gastrostomy tube with Malecot urologic catheter, 220, 221f
indications, 220
surgical procedures, 220
Stoma in "rosebud" fashion, 228, 228f
Stoma placement, 227
Strengthening the Reporting of Observational Studies in Epidemiology (STROBE) statement, 314
Stripping, 165
Subacute postpartum
bleeding, 280
hemorrhage, 279
Subclavian vein, 28f
Subsequent management, fistula repair, 253
Suction drainage, 253
Superficial circumflex iliac artery, 28f
Superficial epigastric artery, 28f
Superior gluteal artery perforator (SGAP) flap, 269
Superior hypogastric plexus, 29f, 111f
Superior hypogastric plexus block (neurolytic), 319
Superior mesenteric artery (SMA), 28, 28f

Superior vena cava (SVC), 28f, 30
Supra- and infracolic omentectomy, 163
Supracervical hysterectomy, 278–279
Surgical anatomy, 25
  abdomen, upper part, 27–28
  bones and cutaneous landmarks, 33
  muscles, 32–33
  nerves, 31–32
  pelvic fascia, 25–27
  pelvic spaces, 25–27
  vascular supply, 28–31
Surgical causes
  fistula repair, 239
Surgical cervical cancer therapy
  TMMR, 115
Surgical portfolios, 299
Surgical procedures and surgeons, 1
  diagnosis, 4
  infection
    control, 5–6
    prophylaxis, 4–5
  prevention
    of blood-borne infection, 6–7
    and risk assessment, 1–3
    and treatment, 3–4
  thromboembolic disease, 1
  treatment, 4
Surgicel, 165
SURGIFLO, 22
Survival data
  based on hazard ratios, 307
  careful planning, 305
  concepts in, 314
  in gynecologic oncology, 301
  hazard function and cumulative hazard function, 307
  heterogeneity
    addressing, 309
    measurement, 308–309
    between study results, 308
  locating all relevant studies, 306–307
  meta-analysis, 305
    advantages over narrative reviews, 304–305
    advantages over RCTs, 305
    benefits of, 312
    bias, 310–311, 310f
    in clinical decision making, 315
    conflicting results, 302
    decision-making process in gynecologic oncology, 303f
    definition, 301, 304
    information overload, 301
    insufficient high-quality trial data, 302
    narrative review, 302
    pitfalls in conducting, 309–310
    potential bias inherent in RCTs, 311–312, 311f
    publication bias, 312
    quality of, 312–313, 313f
    quality of gynecologic oncology, 313–314
    RCTs limitations, 302
    and software, 314–315
    solution, 303
    in surgical context, 309
  objectives of the study, 305
  outcome measures, 306
  patient characteristics, 306
  population of studies to be included, 305–306
  screening, evaluation, and data abstraction, 307
  statistical methods for calculating overall effect, 307
  study type, 306
  summary statistics from trial reports, 308
  treatment modalities, 306
SutureCut™ needle driver, 216
"Swiss cheese theory" of risk, 1
Symptomatic or palliative management, 323
Symptom control, palliative care, 323–324
Symptom management, palliative care, 323
Systematic error, 310
Systematic review, 304
Systemic heparin, 255

Tagged-amplicon deep sequencing (TAm-Seq), 64
TAH, *see* Total abdominal hysterectomy (TAH)
TAH/BS0, 163
Taleo-analysis, 305
Tamoxifen, 34
TDTE, *see* Transdiaphragmatic thoracic exploration (TDTE)
Teletherapy, 102
Temporary balloon catheter, 279–280
Tensor fascia lata (TFL), 270–271
TFL, *see* Tensor fascia lata (TFL)
Therapeutic pelvic lymph node dissection, 111f, 114f
Thoracoabdominal (TA) stapler, 222, 222f
Thoracocentesis, 33
Three-swab test, 241
Thrombin, 22
Thromboembolic disease, 12–13
Thromboembolic prophylaxis, 70
Thromboprophylactic therapy, 12
Thromboprophylaxis, 12
Thyroid dysfunction, 16
Thyroid-stimulating hormone, 16
Thyroxine (T4), 16
Timing of repair
  intestinogenital fistula, 244
  urogenital fistula, 244
Tisseal®, 22, 165, 166
Tissue damage
  humidification during surgery, 209
TMMR, *see* Total mesometrial resection (TMMR)
Total abdominal hysterectomy (TAH), 185
Total mesometrial resection (TMMR), 109
  ontogenetic surgical anatomy, 109–110
  pathological evaluation, 115
  surgical procedure
    contraindications, 110
    indications, 110
    technique, 110–115
    treatment goals, 110
Trachelectomy specimen, 93, 93f
Traditional reconstructive options and their limitations
  gracilis flap, 266
  local skin flaps, 266
  rectus abdominis flap, 266
  skin grafts, 266
Trampoline, 107
Transabdominal laparoscopic approach, 169
Transabdominal placement, 277
Transdiaphragmatic decompression of pneumothorax (TDDP), 165
Transdiaphragmatic thoracic exploration (TDTE), 166
Transferrin, 62
Transperitoneal repair, urogenital fistulas, 249, 249f
Transplantation, ovarian tissue, 149–150
  forearm, 151
  heterotopic ovarian transplantation, 150–151
  lower abdominal subcutaneous tissue, 151
  pelvic orthotopic transplantation, 150
Transplant medicine, 154
Transthyretin (prealbumin), 62
Transvaginal ultrasound (TVS), 34, 35, 61
Transverse colon, 27f
Transverse ligament of collum (Mackenrodt), 25
Transverse mesocolon, 27f
Transverse muscle cutting incisions, 78
Transverse skin incision, 178
Transverse vesical fold, 29f
Transvesical repair, urogenital fistulas, 249, 249f
Treatment history, 266–267
Triiodothyronine (T3), 16
"Triple incision" technique, 129, 129f
Trophoblastic disease, surgical management of
  fertility preservation, 186–187
  management, 184
  placental site trophoblastic tumors, 184–186
Trophoblastic pseudotumor, 184
Tuberculosis, 240
Tube thoracotomy, 33
Tumor, node, metastasis (TNM) classification, 34
Tumor-associated antigens, 60

Tumor debulking, 157
Tumor-derived proteins, 64
Tumor-free resection margin, 109
Tumor-free tissue, 109
Tumor-free vaginal margin, 110
Tumor markers, 60
  alpha-fetoprotein and human chorionic gonadotropin, 63
  CA-19-9, 63
  carcinoembryonic antigen, 63
  cervical cancer, 64
  differential diagnosis and prognosis, 62–63
  endometrial cancer, 65
  future, 64
  gestational trophoblastic tumors/neoplasia, 64
  human chorionic gonadotropin (hCG), 64–65
  indications for screening, 61–62
  inhibin and anti-mullerian hormone, 63–64
  ovarian and fallopian tube cancer, 60
  in ovarian cancer, 60
    CA125, 60–61
    human epididymis protein 4 (HE4), 61
  prognosis, 63
  squamous-cell carcinoma antigen, 64
  treatment and recurrence, 63
  vulvar and vaginal cancer, 65
Tumor-specific antigens, 60
Tunneled epidural catheter, 319, 319f
Two-dye test, 241

Ulcerative colitis, 240
Ultracision®, 87
Ultrasmall superparamagnetic iron oxide (USPIO), 48
Ultrasonography
  fistula repair, 242
Ultrasound, 128
  cervical cancer, 39
  endometrial cancer, 34–35
  menstrual cycle, 35f
  ovarian malignancy, 44–45
  vaginal bleeding, 34, 35
  vaginal cancer, 48
Ultrasound scan (USS), fertility preservation, 187
Umbilicus, 32f
Unfractionated heparin (UH), 3, 12, 13
Unilateral adnexectomy, 161
Universal precautions, 1
Upper abdominal cytoreduction
  diaphragm, 164–165
  liver, 165–166
  perinephric region, intestine, mesentery, and lymph nodes, 166–167
  spleen, 164
  thorax, 166
Ureter, 29f, 89f
  identification and mobilization, 90–91
Ureteral injury, 174
Ureteric catheterization and stenting
  cystoscopy and stenting, 59
Ureteric fistulas, 241, 242
Ureteric injury
  anatomy, 231–232
  Boari flap, 232, 233f
  ileal ureter, 232–233
  management, 231, 231f
  preoperative imaging, 231
  prevention and detection, 230
  psoas hitch, 232
  risk factors, 230
  ureteroureterostomy, 232, 232f
Ureteric reanastomosis, 218
Ureteric reimplantation, urogenital fistulas, 249–250, 250f
Ureteric tunnels, 75f, 97f
  roof division, 125
Ureterointestinal anastomosis, 234
Ureteroneocystotomy, 218
Ureteroureterostomy, 232, 232f
Ureterovesicovaginal lesion, 242, 242f
Ureters, 111, 124
Urethrovesical fascia, 89f
Urinary bladder, 26f
  voiding, 86
Urinary diversion
  altered sensorium, 233
  ileal conduit, 234–235
  Indiana pouch, 235–236, 236f
  metabolic abnormalities, 233
  orthotopic neobladder, 235, 235f
  patient preference, 233–234
  quality of life and age, 233–234
  renal function, 233
Urine leakage, 86
Urogenital fistulas, 241, 243–244
  abdominal repairs
    transperitoneal repair, 249, 249f
    transvesical repair, 249, 249f
    ureteric reimplantation, 249–250, 250f
  dissection and repair in layers, 245–246
  post-hysterectomy vault fistula, 245, 246f–247f
  route of repair, 244
  saucerization, 246–247, 247f
  timing of repair, 244
  vaginal repair procedures in specific circumstances, 247–248, 248f–249f
Urogenital ridge metacompartment, 117
Urologic procedures
  ureteric injury, 230–233
  urinary diversion, 233–237
Uterine arteries, 28f, 71, 75f, 81f, 89, 89f, 97, 97f
Uterine artery embolization /occlusion
  endovascular catheterization technique, 280
  expected intraoperative hemorrhage, 279
  fetus and umbilical cord clamping, 280
  interventional radiologic (IR) procedures, 279
  postpartum hemorrhage, 279
  sheath/balloon catheter system, 280
  subacute postpartum bleeding, 280
  subacute postpartum hemorrhage, 279
  temporary balloon catheter, 279–280
Uterine cancer, 42
  pain from, 317
  sentinel node biopsy, 143–145
Uterine cervix, 72, 110, 117, 119f
Uterine compression sutures
  bimanual massage, 275
  B-Lynch suture technique, 275–276, 276f
  compression suture postoperative complications, 276
  uterine tamponade balloon, 275
Uterine ligation sutures, 278
Uterine papillary serous adenocarcinoma, 195
Uterine sarcomas, 37
Uterine tamponade balloon, 275
Uterine transplantation
  ethical considerations, 153
  future considerations, 153
  historical considerations, 153
  lessons from transplant surgery, 153–155
Uterine vascularity, 184
Uterocervico, 98f
Utero-ovarian arteries, 277
Utero-ovarian vascular supply, 88
Uterosacral ligament, 26f
Uterovaginal cancer, 121
Uterovaginal endopelvic fascia, 88
Uterovaginal fascia, 89f
Uterovaginal plexus, 69
Uterovesical pouch, 29f
Uterus, arteries, 95

Vacuum-assisted closure (VAC), 24
Vagina, 26f
  based on defect type I, 260, 261f
  defect sites, 268
  division, 77f
    in stages, 81–82
  lymphatic drainage, 134f
Vaginal arteries, 30
Vaginal assisted laparoscopic radical hysterectomy, 87
Vaginal brachytherapy (VBT), 282
Vaginal cancer, 47
  brachytherapy, 289–290
  computed tomography, 48–52
  imaging, 47
  ultrasound, 48
  vulval cancer, 47–48
Vaginal cuff, 82, 82f
  preparation, 89–90, 90f
Vaginal fornix, 25

Vaginal hematoma, 81
Vaginal hysterectomy, 4, 6
Vaginal intraepithelial neoplasia (VAIN), 47, 123
Vaginal introitus, 31
Vaginal margin, infiltration of, 81f
Vaginal mucosa, 77, 123
  prophylactic cervical cerclage and closure, 92
Vaginal obturator, 282
Vaginal radical hysterectomy (VRH), 79
Vaginal radical trachelectomy (VRT), 88
  anatomical consideration
    cardinal (Mackenrodt) ligament, 88
    uterosacral ligaments, 88
    uterovaginal endopelvic fascia, 88
    vascular supply, 88
  indications, 88
  procedure
    anatomical relationship, 89
    bladder pillars, sections, 91
    cervical appearance, 93
    excision of specimen, 92
    identification of vesicouterine space, 90
    opening of paravesical space, 90
    proximal parametrium, 91–92
    trachelectomy specimen, 93
    ureter, identification and mobilization, 90–91
    vaginal cuff preparation, 89–90
    vaginal mucosa, prophylactic cervical cerclage and closure, 92
  results, 93
    fertility results, 94
    obstetrical results, 94
    oncologic results, 93
Vaginal repair procedures in specific circumstances, 247–248, 248f–249f
Vaginal vault, 192–193
Vaginectomy, 123
  abdominal procedure, 124
    complications, 125
    instruments, 124
    operation, 124–125
    postoperative care, 126
    preoperative preparation, 124
  anatomic considerations, 123
  preoperative assessment, 123
  vaginal procedure
    Instruments, 123
    operation, 123–124
    postoperative care, 124
Valvular stenosis, 9
Vascular and peritoneal access devices
  anatomic considerations, 175
  catheters, maintenance and access of, 179–180, 180f
  central venous catheters, complications and management of, 180, 180t–182t
  complications, 180, 180t–182t
  contraindications, 175
  cutdown technique
    checking placement of catheter, 179
    connecting the port to the catheter, 179, 179f
    creating a tunnel for the catheter, 179, 179f
    internal jugular cutdown, 178
    making the pocket for the port, 178, 178f
    peritoneal access device without concurrent laparoscopy or laparotomy, 179
    venous access via the cephalic vein, 178, 178f
  indications, 175
  percutaneous (seldinger) technique
    dilating the skin incision/passing the catheter, 177, 178f
    internal jugular access, 176–177
    needle insertion, 176
    passing the guide wire, 177
    subclavian vein access, 176
  ports types, 175
  preoperative evaluation and testing, 175
  surgery, 176
  surgical procedure, 175
  venous access, 176
Vascular arcades, 221
Vascular defects and injuries treatment
  anatomic considerations, 255
  arterial control and repair, 255–257, 257f
  indications, 255
  inferior vena cava filters, 258, 258f
  vascular patches, 258
  venous control and repair, 258
Vascular dissection, 121
Vascular elastic slings, 184
Vascular mesometrium, 109, 112
  sealing, 112f
  separation, 112f
Vascular patches, 258
Vascular plexus, 88
Vascular supply, surgical anatomy, 28–31
Vasculature of the groin, 255, 256f
VATS, *see* Video-assisted thoracic surgery (VATS)
VBT, *see* Vaginal brachytherapy (VBT)
Venous access
  catheters, 175
  vascular and peritoneal access devices, 176
Venous and lymphatic drainage, 201
Venous control and repair, 258
Venous thromboembolism (VTE), 1, 12, 258
  calf, 4
  risk factors, 2t
Ventilation–perfusion scans, 4
Vertical rectus abdominis myocutaneous (VRAM) flap, 266
Vesicouterine and vesicocervical spaces, 75f
Vesicouterine ligament, 109
Vesicouterine peritoneal fold, 112
Vesico-uterine space, 90f
Vesicouterine vessel connections, 112
Vesicovaginal fistula, 242
Vesicovaginal space, 26f, 82, 82f
Vessel repair, 255
Video-assisted thoracic surgery (VATS), 166
Visceral central sensitization, 317
Visceral pain physiology
  anatomy to explain clinical features, 317
  pain from compression of pelvic structures, 317
Visceral pelvic fascia, 25
Viscero-visceral sensitization, 317
Vitagel®, 22
VRT, *see* Vaginal radical trachelectomy (VRT)
VTE, *see* Venous thromboembolism (VTE)
Vulval cancer
  vaginal cancer, 47–48
Vulvar cancer, 65
  brachytherapy, 290
  sentinel lymph node biopsy, 137–140
Vulvar intra-epithelial neoplasm (VIN), 130f
V-Y advancement flap, 269, 269f
V-Y procedure, 261, 262f

Wallace (refluxing) and Le Duc (non-refluxing) techniques, 234
Warfarin, 3, 4, 12
Web (Meigs), 25
Web-based bibliographic databases, 301
WHO Surgical Safety Checklist and Implementation Manual, 1
Woman with gynecological cancer, palliative care in, 322–323
Wound complications, surgery, 22–24

Zeppelin clamps, 262
Z-plasty, 246, 260, 261f
Zumi™ uterine manipulator, 216